

# Handchirurgie Mikrochirurgie Plastische Chirurgie

December 2010 · Volume 42 · Page 379–385

[www.thieme-connect.de/ejournals](http://www.thieme-connect.de/ejournals)

**Reprint**



## **BEAULI™ – A New and Easy Method for Large-Volume Fat Grafts**

K. Ueberreiter, J. G. von Finckenstein, F. Cromme,  
C. Herold, U. Tanzella, P. M. Vogt

**Publisher and Copyright:**

© 2010 by  
Georg Thieme Verlag KG  
Rüdigerstraße 14  
D-70469 Stuttgart  
ISSN 0722-1819

Reprint with the permission  
of the publishers only

# BEAULI™ – A New and Easy Method for Large-Volume Fat Grafts

## BEAULI™ – eine neue Methode zur einfachen und zuverlässigen Fettzell-Transplantation

### Authors

K. Ueberreiter<sup>1</sup>, J. G. von Finckenstein<sup>2</sup>, F. Cromme<sup>3</sup>, C. Herold<sup>4</sup>, U. Tanzella<sup>3</sup>, P. M. Vogt<sup>5</sup>

### Affiliations

Affiliation addresses are listed at the end of the article

### Key words

- breast supplementation
- autologous fat grafts
- breast reconstruction
- BEAULI
- liposuctions

### Schlüsselwörter

- Mammaaugmentation
- Fettzell-Transplantation
- Mammarekonstruktion
- BEAULI
- Liposuction

submitted 27.5.2010

accepted 28.9.2010

### Bibliography

DOI <http://dx.doi.org/10.1055/s-0030-1267913>  
 Handchir Mikrochir Plast Chir 2010; 42: 379–385  
 © Georg Thieme Verlag KG  
 Stuttgart · New York  
 ISSN 0722-1819

### Correspondence

**Dr. Klaus Ueberreiter**  
 Asklepios Klinik Birkenwerder  
 Division for Plastic and  
 Aesthetic Surgery  
 Hubertusstraße 12–22  
 16547 Birkenwerder  
 k.ueberreiter@asklepios.com

### Abstract

After numerous experiments with free-fat transfer since 1893 [1], many promising methods and results of large-volume fat grafts have been published recently [2–6]. A common disadvantage was the time of the procedure and a lack of proof of efficiency. In 2007 we developed with the BEAULI™ method (Berlin autologous lipotransplantation) a new and reliable procedure to collect larger amounts of transplantable fatty tissue. It was evaluated in a prospective clinical study with 85 patients in 2 centres in Germany, the overall number of transplantations amounting to 216 treated breasts. Indications were general lack of breast volume, either genuine or acquired in the course of surgical procedures. The fat was harvested with the BEAULI™ method, which consists in general of the harvest of very small fat particles by means of water-assisted liposuction (body-jet®, human med AG, Germany) and reinjection of the fat after separation from superfluous water by means of the Lipo-Collector®. All procedures were performed in a standardised pattern, measurements were taken preoperatively, at day 1 postop, after 1 week, 4 weeks, 3 months, 6 months and then to be continued yearly. An MRI of the breasts was taken preop and 6 months postoperatively, the longest follow-up is 30 months. Operation time was (on average) 1.5 h. In every case a definite increase of the volume of the fatty layer in the treated areas was observed. We saw no macroscopic oily cysts, in 2 cases there were 3 months after the operation some palpable subcutaneous nodules which proved to be granulomas. The volume control of 35 aesthetic patients by means of BrainLab™ Software and MRI could verify a permanent take rate of  $76 \pm 11\%$  of the grafted fat. In aesthetic patients generally 2 (80%) fat-grafting procedures with an average gain in volume of 1/2 bra cup size or 100–150 mL) per procedure were re-

### Zusammenfassung

Nach vielzähligen Versuchen in der freien Verpflanzung von körpereigenem autologem Fettgewebe seit 1893 [1] besteht in den letzten Jahren aufgrund zahlreicher Publikationen zu dem Thema sowie der Entwicklung neuer Techniken ein hohes Interesse an dieser Erweiterung des plastisch chirurgischen Behandlungsspektrums. Gleichzeitig fehlte ein Verfahren zur Gewinnung und Verpflanzung größerer Volumina in kurzer Zeit. Ein solches neues Verfahren zur einfachen und zuverlässigen Gewinnung größerer transplantabler Fettmengen Verfahren steht seit Oktober 2007 mit der BEAULI™ (Berlin Autologous Lipotransfer) Methode zur Verfügung. In einer prospektiven klinischen Studie wurden seit Oktober 2007 in 2 Zentren in Deutschland 85 Patientinnen mit Gewebedefizit im Bereich der Brust durch Eigenfetttransplantation behandelt. Die Summe aller Transplantationen (Behandlung jeweils einer Brust) lag Ende April bei 216. Das Fett wurde dabei durch die BEAULI™ Methode gewonnen. Diese basiert auf der Gewinnung kleinster Fettpartikel mittels Wasserstrahl assistierter Liposuction (mit dem „body-jet®“ der Fa. human med AG, Schwerin) und anschließender Separierung des Fettanteiles mit dem LipoCollector®. Die Operationen wurden standardisiert durchgeführt, präoperativ sowie 6 Monate postoperativ wurde ein MRT der Mamma angelegt sowie klinische Kontrolluntersuchungen präop, an Tag 1 postop, nach 1 Woche, 4 Wochen, 3 Monaten und 6 Monaten. Nach Möglichkeit schließen sich Nachbeobachtungen im Jahresrhythmus an. Der längste Beobachtungszeitraum liegt derzeit bei 30 Monaten. Die durchschnittliche OP Dauer betrug 1,5 Stunden. Bei allen Patienten kam es zu einer deutlichen Vermehrung des subcutanen Fettgewebes. Der gemessene Zugewinn lag bei  $76 \pm 11\%$  des transplantierten Fettes nach volumetrischer Auswertung der MRT Bilder von

quired. After implant removal, satisfaction was usually reached after only a single procedure, for complete reconstruction after cancer surgery 4–5 grafting sessions were necessary. An extension of the skin envelope as well as improvement of existing scars were observed.

## Introduction

100 years have elapsed since the first published description of an adipose tissue transplantation by Neuber [1] and of a partial breast reconstruction through injection of autologous adipose tissue by Holländer [2]. Following a series of publications during the pre-World War II period [3–6] the topic receded almost to being forgotten. An outstanding exception in the subsequent years is the study by Peer [7]. Only after liposuction was introduced by Fischer and in particular by Illouz [8] did adipose tissue transplantation come into vogue [9–12]. However, in 1987 an ASRPS “Ad Hoc Committee on New Procedures” rejected fat transplantation in the breast without a basis of evidence [13]. This position has only recently been revised [14].

There was a strong upswing in scientific investigation of the subject with the publication of research by von Chajchir [15,16], Coleman [17–19], Delay [20,21], Rigotti [22,23]. More recently, numerous groups of researchers in different countries have experimented with autologous fat transplantation in the breast. In Germany, one of such groups is the DGPRAC [24]. All previous methods have encountered a severe limitation – the duration of the operation itself. The original technique (LipoStructure) used by Coleman [19] in aesthetic bilateral breast enlargement took at least 5–7 h. Other approaches are associated with rather high costs (BRAVA), have sometimes had only a low rate of fat integration, or provide no real proof of an effective integration rate. Another currently discussed question is supplemental tissue grafting with fat stem cells (ADSC) [25]. These cells are isolated from the adipose tissue through enzymatic digestion and mechanically, and later added to the fatty graft tissue. The integration rate is improved through greater angiogenesis. However, this hypothesis still lacks evidence-based proof. Furthermore, the duration of the fat cell transplantation procedure is considerably lengthened (by at least 2 h) and costs are significantly raised. Its wide clinical use does not currently seem to be feasible.

Whenever a rather large portion of the transplanted fat is discarded because of poor perfusion (tissue clumping), it should be noted that not all the necrotic cells are carried off by macrophages, but undergo a confluence into oil cysts through the lack of contact with well perfused tissue following autolysis of the cell membrane, and then can become calcified, as several publications have described [26].

The objective of this research therefore was to develop a technique for cell-friendly harvesting of fat cell particles which would considerably reduce operation time and concomitantly result in a high integration rate among the transplanted fat cells.

35 Patientinnen. Bei Entfernungen von Silikonimplantate nach Kapsel Fibrose wurde von den Patienten in der Regel nicht mehr als eine Fetttransplantation gewünscht, obwohl die transplantierten Mengen zum Teil deutlich unter Volumina der entfernten Silikonimplantate lagen. Im ästhetischen Bereich lag der Schnitt bei 2 Transplantationen, womit etwa eine Körbchengröße gewonnen werden konnte (d.h. etwa ½ Körbchen bzw. 100–150 ml) je Transplantation). Für einen kompletten Wiederaufbau der Brust nach Ablatio sind 4–5 Transplantationen erforderlich. Eine weitere Beobachtung lag in der starken Verbesserung der Narbenqualität und einer kontinuierlichen Aufdehnung des Hautmantels.

Since 2005 we have been conducting water-jet assisted liposuction (WAL) and made the harvested fat available for fat cell research in the Franz Vollhardt Clinic of Charité Hospital, Berlin. The harvest of vital cells was found comparable to that under the Coleman technique. A vessel for the sterile separation of the adipose tissue from the tumescence solution was developed in 2007 through a series of tests in collaboration with human med AG, Schwerin, which is now being marketed under the name LipoCollector™. The method was termed simply BEAULI (Berlin Autologous Lipotransfer) to enable future international comparison of the different methods on the market.

## Selection of Patients

Non-smoking patients with a BMI between 20 and 30 were included. All patients desired improvement in breast size and at the same time refused to undergo a conventional breast augmentation procedure. They received a detailed explanation of the possible risk of formation of oil cysts and calcifications.

## Method

First, all patients were measured for height, weight, jugulum-mamilla distance (JMD) and maximum circumference of each breast, measured from the medial to the lateral attachment; standardised photo documentation (mirror image) was added. All data were collected on a specific questionnaire.

Data on the areas suctioned, the amount of graft used, distribution subcutaneously or in the pectoral muscle, and the results of centrifugation were recorded in a separate operative protocol. The postoperative data (height, weight, measurement for the JMD, maximum circumference of each breast – measured from the level of the anterior axillary line over the mamilla to the medial attachment – and postoperative pain scale) were recorded on the day following the operation, after 1 week, 1 month, 3 months, and 6 months.

Liposuction was performed on the day of the operation, preferably from areas of the abdomen and flanks and on the outside and inside of the thighs. The area for harvesting was selected according to the wishes of the patients. The area to be suctioned was first infiltrated with the body-jet® using a Klein standard tumescence solution (composition: 500 mg lidocaine, 1 mg adrenalin and 12.5 ml sodium bicarbonate 8.4% in a 1 l solution) [27] and liposuction was started without a waiting period. Infiltration and liposuction were performed with the same solution. The solution was warmed to 35° to prevent excessively rapid

cooling and consequent damage to the fat cells. Furthermore, it is more pleasant for subjects if several litres of cold solution are not also chilling their bodies.

The liposuction procedure involved the application of a pulsing water jet on the body-jet® device – with the setting at Level 1 – and constant irrigation with the tumescence solution and negative pressure, which was limited to  $-0.5$  bar. The pressure limitation was selected after pilot studies following centrifugation of the aspirate indicated that the proportion of clear oil increased in step with a rise in suction pressure. Suction pressure less than  $-0.5$  bar led to frequent blockage of the suction channel and much less efficiency in fat harvesting. The cannula used was the 3.8 mm body-jet® Rapid cannula with effective suction apertures of 0.9 mm. These narrow apertures enable harvesting of equally small fat cell structures which also integrate well.

The same step included the separation of the fat in the LipoCollector™ from the aqueous elements (● Fig. 1) so that the amount of residual fluid in the mixture was equivalent to that after 10 min decanting.

The LipoCollector™ basically consists of a prefilter to remove fibrous elements which could choke the thin injection cannulas. The fat flushed out by continual irrigation is separated from the excess fluid by means of a sieve in the LipoCollector.

The fluid is then suctioned off and the separated washed fat remains sterile on the operating table for later use.

An average of 60 min was needed (including prefiltration) to harvest 600 ml of transplantable clear adipose tissue.

The harvested fat was then suctioned from the container with the BEAULI™ extraction cannula and 50 cm<sup>3</sup> syringes. These are left upright for 10 min in a stand on the table and fluid settling at the base is removed in 10 cm<sup>3</sup> syringes before transfer. Direct reinjection from the 10 cm<sup>3</sup> syringes utilises BEAULI injection cannulas. Reinjection is made via a small, approx. 5 cm, laterocaudal stab incision of the breast. All segments of the breast are accessible from the incision because of the length of the cannula. Fat infiltration is performed *exclusively in the area of the subcutaneous adipose tissue and the pectoral muscle*. The adipose tissue is usually distributed so that about two-thirds is placed in the area of subcutaneous fat and about one-third intrapectorally. The pectoral muscle was probed by palpating bluntly against the nearest rib with the cannula and then performing the injection directly above the ribs while maintaining constant contact with them.

Care was taken during distribution of the fat to ensure that the tissue was not subjected to excessive tension, to avoid application of additional pressure around the fat cells. The individually grafted (net) fat amount ranged between 120 cm<sup>3</sup> and 292.5 cm<sup>3</sup> with a mean of 184.4 cm<sup>3</sup>.

To calculate the exact volume obtained through fat transplantation, two 10 cm<sup>3</sup> syringes from the graft series were centrifuged at 3000 rpm for 3 min. The readable proportions of free oil and clear fluid were then recorded in the operative protocol (● Fig. 2). The proportion of clear grafted fat (= net fat percentage) was used as the basis for volume assessment.

The postoperative follow-up involved the administration of an oral antibiotic for 3 days. A cotton pad was applied for 2 days to avoid pressure on the breast and to cool the tissue. A compression brace was placed on the graft harvesting areas. Wearing of a compression bra and avoidance of physical exertion were not necessary.

## Results



Between 1 October, 2007 and 31 March, 2010 a total of 85 patients were treated with autologous fat grafts for breast augmentation with this method (● Table 1). The indications were a desire for aesthetic enlargement, reconstruction after partial or total mastectomy, or capsular fibrosis after silicone implants in combination with refusal of implants.

36 patients who had undergone aesthetic augmentation were evaluated for volume on MRI since they presented too many individual factors after implant removal or reconstruction.

Analysis of the clinical follow-up record gave the following results: mean operation time (incision-to-suturing): 92 min with a significantly declining trend. Currently, the operation time stands at approximately 1 h.

The postoperative course of the jugulum-mamilla distance is shown in ● Table 2. The mean increase is about 1 cm or 7% (● Table 2).

● Table 3 shows the change in single breast circumference over the assessment period. The mean increase is about 1.7 cm or 9.2% (● Table 3).

The development of breast circumference over an assessment period of 6 months is shown in ● Fig. 3. It appears that measurement of the particular circumference of each breast from the anterior axillary line to the medial attachment over the

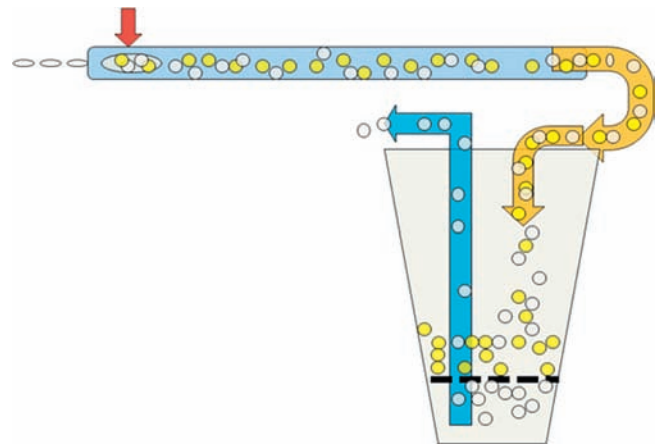


Fig. 1 LipoCollector (diagram).

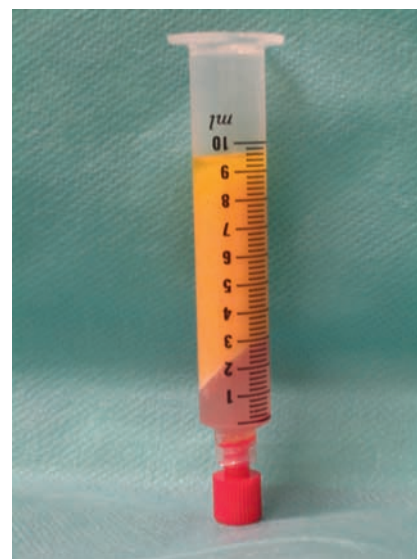

Fig. 2 Centrifuged material.

largest circumference does not in fact represent an exact measuring criterion, but overall it gives a good indicator of the resorption behaviour of the fat. Similar development can be seen in the jugulum-mamilla distance (◉ Fig. 4). The measurements correlate with the clinical observation that no further volume loss occurs after postoperative month 3. We are therefore able to provide future patients with more precise information on the course to be expected.

The course of pain sensitivity over the assessment period is shown in ◉ Table 4. Significant haematoma formation in the breast area was not found. Pain was predominantly localised to the graft harvesting area.

The mean content of pure fat obtained after centrifugation at 3000 rpm for 3 min stayed very constant at 68% (range 60–72%).

### Volumetric Assessment

Regarding the MRI assessment of volume, we refer to the article by Herold in the same journal [28]. MRI seems to be the currently superior method for the provision of real-time proof of structural changes, cost benefit, and precision of results even though calculations of volume are also possible by photographic methods [29].

The examinations were performed with T1 weighting in the breast coil. The first examination was preoperative (◉ Fig. 5a), the second came 6 months after the grafting procedure (◉ Fig. 5b). A comparison of 72 MRI scans performed at least 6 months after the intervention showed a mean adipose tissue integration rate of  $76 \pm 11\%$ .

Therefore, the mean net increase in breast volume was equivalent to approximately 50% of the injected gross volume (68% fat content  $\times$  76% integration rate  $\approx$  50%). This represents an actual mean gain in volume of 100–120 ml from each graft procedure.

**Table 1** Patients.

	Patients	Procedures	MRI 6 months	MRI 12 months
reconstruction	21	41	1	
aesthetics	52	152	36	8
capsular fibrosis	12	23	6	
total	85	216	43	

**Table 2** Change in jugulum-mamilla distance over the assessment period.

Time of measurement	Pre-operative	Day 1 postop.	Week 1 postop.	Week 4 postop.	Month 3 postop.	Month 6 postop.
distance (cm)	19.02	21.78	21.72	21.22	20.80	20.77

**Table 3** Change in single breast circumference over the assessment period (mean, in cm).

Time of measurement	Pre-operative	Day 1 postop.	Week 1 postop.	Week 4 postop.	Month 3 postop.	Month 6 postop.
distance (cm)	14.4	16.2	16.4	15.8	15.4	15.4

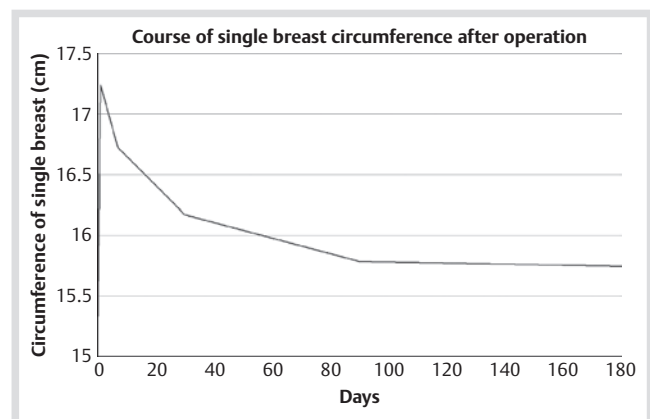
### Discussion



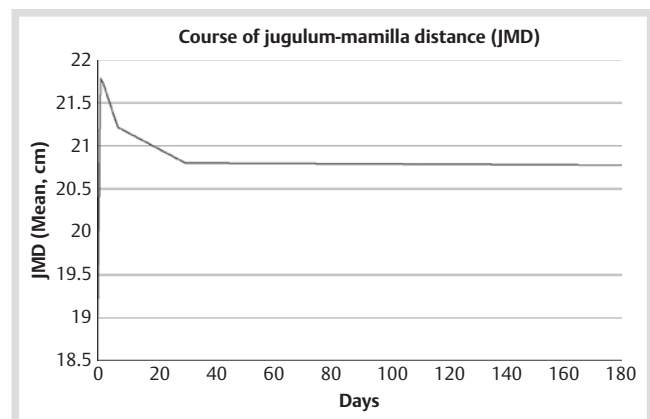
In the 100 plus years that have elapsed since the first published description of a free adipose tissue graft in the breast and in many years of post-procedure observation [17, 20, 30, 31] no significant negative effects, especially possible cancer occurrences, have been reported [32]. Ever since the basic possibility of performing adipose tissue transplantation has stopped being challenged, the foremost question has been that of completing the intervention within an acceptable period of time. Important factors for success include a tissue-friendly procedure, a low suction level, and the distribution of the smallest adipose tissue particles in a well perfused recipient site [1, 19, 33]. The Lipo-Structure™ method pioneered by Coleman meets these requirements, but is very time-consuming when the amount of grafting to be done is large.

We have shown that with the water-jet assisted Liposuction (WAL) all these requirements can be met – and this in a much shorter time.

1. Through continual irrigation with water liposuction becomes possible with very small apertures (0.9 ml/millimetre) and low suction pressure (0.5 bar).
2. Centrifugation of the harvested fat can be omitted since the mean residue of 30% fluid permits easy reinjection with 10 cm<sup>3</sup> syringes and leads to a uniform distribution of the fat in the tissue.
3. The mean duration of the intervention at 92 min for a bilateral breast enlargement is not significantly longer than the



**Fig. 3** Development of breast circumference over 6 months.



**Fig. 4** Mean development of the jugulum-mamilla distance.

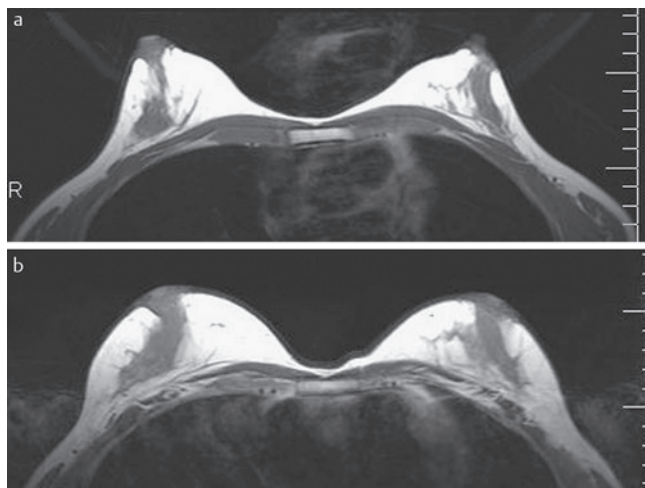
time for conventional enlargements with implants. In this case, the liposuction associated with the intervention must be considered a separate procedure.

Nearly all interventions were performed on an outpatient basis and under local anaesthesia with sedation (remifentanyl).

In the postoperative course only minor symptoms in the breast area were reported; in individual cases there was some significant haematoma formation. The intervention was so low in stress for the patients that most (over 80%) decided on a second fat cell transplantation. The very simple measuring method for

**Table 4** Course of pain sensitivity over the assessment period (visual analogue scale 0–10).

Time of measurement	Pre-operative	Day 1 postop.	Week 1 postop.	Week 4 postop.	Month 3 postop.	Month 6 postop.
analogue scale 1–10	0	3	2	0	0	0



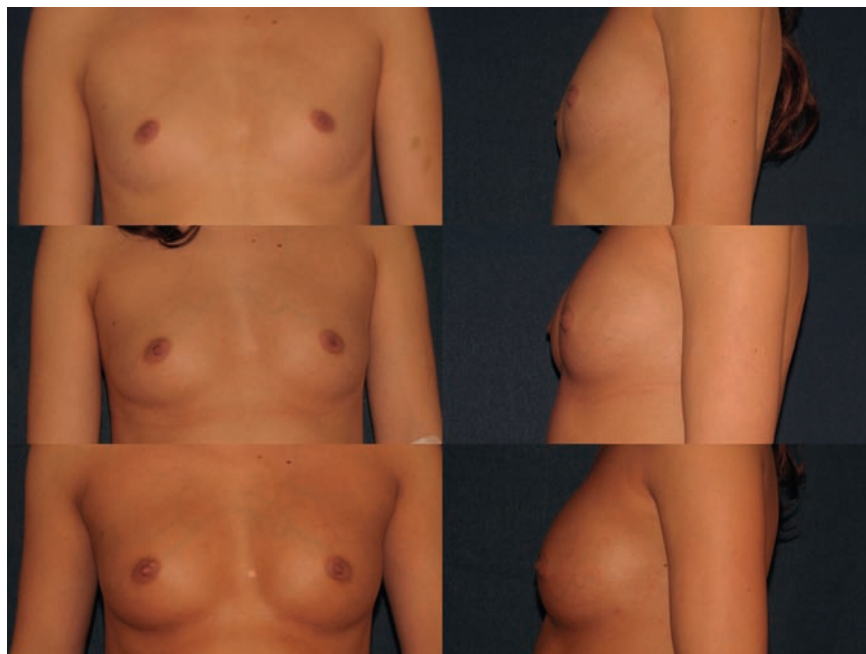
**Fig. 5** a, b MRI before and 6 months after lipotransfer of 180 ml (right) and 210 ml (left) (gross amounts).

the breast circumference and the jugulum-mamilla distance is indeed inexact in individual cases and subject to fluctuation according to researcher, but a comparison of mean values clearly demonstrates significant trends over the postoperative course which correlate well with the clinical picture and permit us to take a position on the postoperative outcome. Further resorption beyond month 3 clearly did not occur.

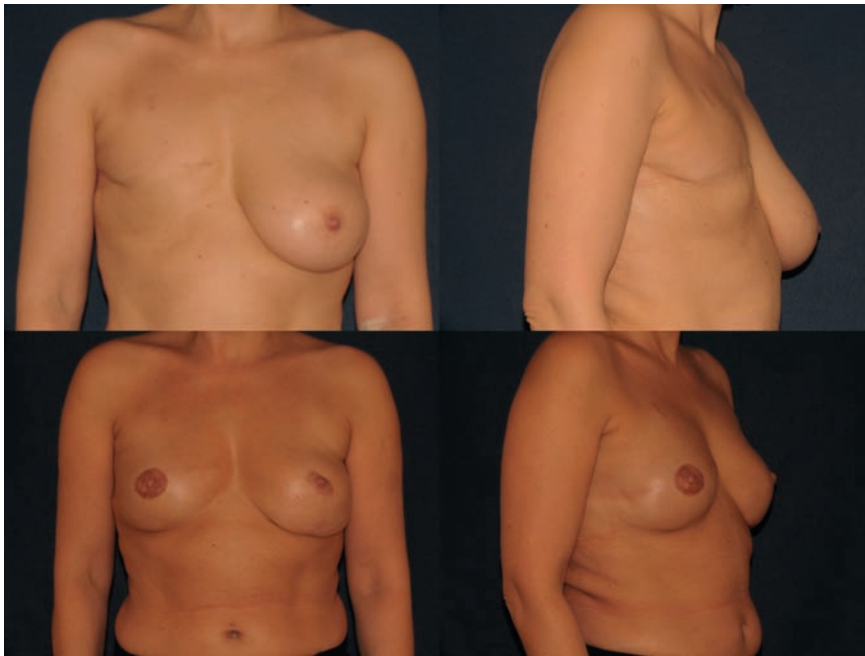Infections were not observed at all; 2 patients presented subcutaneous granulomas (histologically confirmed), which did not require any special treatment. Macroscopically detectable oil cysts were not observed on the MRI, and palpation explorations were unremarkable except in 2 patients with subcutaneous granuloma formation (histologically confirmed).

Since the thickness of subcutaneous adipose tissue is individually very variable and often hardly detectable in patients with very small breasts, only a small volume amount could be introduced at the first augmentation (approx. 200–250 ml gross incl. residual fluid from the tumescence solution). We basically decided therefore to implant fat cells in the subcutaneous and intramuscular areas exclusively. This was based on 2 fundamental considerations:

1. Even in tissue-friendly grafting of very small particles the formation of oil cysts or calcifications cannot be definitively excluded. With the use of (digital) mammography or MRI such changes can now be easily distinguished from malignant changes. This distinction is also further enabled if the aetiology can be traced on the basis of the tissue layer in which they are detected.
2. In terms of survival – quoad vitam – 1 woman in 10 today is faced with the risk of developing breast cancer. Since we all possess a strong tendency to create associations (even those non-existent medically), we should assume that in the case of patients treated with autologous fat some will develop breast cancer in later life. This originates, however, in the glands and therefore outside the subcutaneous adipose tissue. It seems safer, especially in the case of a new method, to cut off at the outset any false conclusions relating to a prior operative intervention. Furthermore, autologous fat transplantation after breast cancer is more acceptable than in the case of a primary



**Fig. 6** Situation 1 year after the last intervention with a 2-stage graft of 220 and 240 ml gross (150 and 165 ml net) respectively in the space of 6 months.



**Fig. 7** Breast reconstruction with 4 grafts 6 months after the last intervention.

augmentation. In our current state of data, an increased risk of cancer through fat transplantation is not supported [32].

3. The pectoral muscle is much more porous in structure and easily absorbs 50 ml adipose tissue in a session. It also enables a better projection. Intramuscular distribution of the fat immediately above the ribs is achievable via the lateral caudal incision with use of the long injection cannula.

In the case of augmentation with an aesthetic indication only, usually 2 grafts (85% of subjects) and in only a few cases 3 interventions were desired. Since a net mean volume increase per graft of 125 ml (1/2 cup size) is attainable, the volume increase obtained matches that of an implant. 1 patient with a very small breast desired a third graft (• Fig. 6).

It was clear from the outset that a satisfactory result would not be attainable with a single graft in patients seeking breast reconstruction after mastectomy since the existing layer of tissue was very small (1–3 cm) to act as a receiving site. In this case, 3–5 grafts were planned and performed (• Fig. 7). The repeat interventions were also well tolerated since these interventions are associated with very little morbidity.

In the case of a second or further augmentation a proportionately greater amount of graft material could be implanted because of the now-existing expansion of the receiving site. We will report on this topic in a separate publication.

The measurements of breast circumference gave a good idea of the course of the postoperative development. The greatest swelling occurred after 1 week, with relatively rapid regression by week 4. After 3 months no further changes were observed. The method is best suited for those patients who are primarily seeking a moderate increase in breast size, but for whom liposuction has its own importance. For patients with a BMI under 18 the method is unsuitable, and likewise if a subject desires the greatest possible size from 1 operation (“from A to C”).

The potential of the method is very promising in cases of definitive implant removal after capsular formation, total or partial reconstruction after mastectomy, or in general corrections of volume deficits; it opens up new horizons in plastic surgery.

**Conflict of Interest:** None



#### **Klaus Ueberreiter**

Born in Berlin on 20 July, 1955. 1975–1976: Development project volunteer in Rhodesia/ Zimbabwe; here he decided to pursue a career in Medicine. 1976–1983: Medical studies at the Free University of Berlin. Study for medical licence 1982 to

1983 in Berlin and Comarapa (Bolivia); doctoral thesis title: *Parasitic infestation and general living conditions of school-children in a rural area of Bolivia*. Conferral of degree with magna cum laude. 1983–1985: Residency in the Recovery/ Poison Unit in Charlottenburg Hospital, Free University of Berlin. 1985–1993: Dept. of Surgery, Dominicus Hospital, Consultant in Surgery. 1993–1995: Division of Plastic Surgery, Dominicus Hospital. 1995–1997: Member of the Continuing Education Committee, Medical Council of Berlin. 1995–1997: Division of Plastic, Hand and Breast Surgery, Schlosspark Clinic, Berlin. 1997: Division of Plastic-Hand-Restorative Surgery, Severe Burns and Trauma Centre, Medical University, Hannover. 1998: Consultant in Plastic Surgery. 1998: Head of the Division of Plastic Surgery, Asklepios Clinic Birkenwerder near Berlin. 1998: European Board Certified Plastic Surgeon.

#### **Affiliations**

<sup>1</sup> Asklepios Klinik Birkenwerder, Abteilung für Plastische und Ästhetische Chirurgie, Birkenwerder

<sup>2</sup> Klinikum Starnberg, Abteilung für Plastische und Ästhetische Chirurgie, Starnberg

<sup>3</sup> Asklepios Klinik Birkenwerder, Plastische Chirurgie, Birkenwerder

<sup>4</sup> Medical School Hannover, Plastic, Hand- and Reconstructive Surgery, Hannover

<sup>5</sup> Medizinische Hochschule Hannover, Klinik für Plastische, Hand- und Wiederherstellungs-chirurgie, Zentrum für Schwerbrandverletzte, Hannover

## References

- 1 Neuber G. Über die Wiederanheilung vollständig vom Körper getrennter, die ganze Fettschicht enthaltender Hautstücke. In: *Zbl f Chirurgie* 1893; 30: 16
- 2 Holländer E. Über einen Fall von fortschreitendem Schwund des Fettgewebes und seinen kosmetischen Ersatz durch Menschenfett. In: *Münch Med Wochenschr* 1910; 57: 1794–1795
- 3 Lexer E. Free Transplantation. *Ann Surg* 1914; 60: 166–194
- 4 Wederhake K. Über die Verwendung des menschlichen Fettes in der Chirurgie. In: *Berl Klin Wochenschr* 1918; 66: 47
- 5 Joseph J. Nasenplastik nebst einem Anhang über Mammaplastik. Berlin 1929
- 6 Lexer E. Die gesamte wiederherstellungschirurgie. 2. aufl. ed. Leipzig: J. A. Barth; 1931; 2 v
- 7 Peer L. Loss of weight and volume in human fat graft, with postulation of a “cell survival theory”. In: *Plast Reconstr Surg* 1950; 5: 217–230
- 8 Illouz YG. Body contouring by lipolysis: a 5-year experience with over 3000 cases. *Plast Reconstr Surg* 1983; 72: 591–597
- 9 Bircoll M. Autologous fat transplantation to the breast. *Plast Reconstr Surg* 1988; 82: 361–362
- 10 Bircoll M. Autologous fat transplantation. *Plast Reconstr Surg* 1987; 79: 492–493
- 11 Bircoll M. Cosmetic breast augmentation utilizing autologous fat and liposuction techniques. *Plast Reconstr Surg* 1987; 79: 267–271
- 12 Bircoll M, Novack BH. Autologous fat transplantation employing liposuction techniques. *Ann Plast Surg* 1987; 18: 327–329
- 13 Report on autologous fat transplantation. ASPRS Ad-Hoc Committee on New Procedures, September 30, 1987. *Plast Surg Nurs* 1987; 7: 140–141
- 14 Gutowski KA. Current applications and safety of autologous fat grafts: a report of the ASPS fat graft task force. *Plast Reconstr Surg* 2009; 124: 272–280
- 15 Chajchir A, Benzaquen I. Fat-grafting injection for soft-tissue augmentation. *Plast Reconstr Surg* 1989; 84: 921–934; discussion 935
- 16 Chajchir A, Benzaquen I. Liposuction fat grafts in face wrinkles and hemifacial atrophy. *Aesthetic Plast Surg* 1986; 10: 115–117
- 17 Coleman SR, Saboeiro AP. Fat grafting to the breast revisited: safety and efficacy. *Plast Reconstr Surg* 2007; 119: 775–785; discussion 777–786
- 18 Coleman SR. Structural fat grafts: the ideal filler? *Clin Plast Surg* 2001; 28: 111–119
- 19 Coleman SR. Structural fat grafting. *Aesthet Surg J* 1998; 18: 386, 388
- 20 Delay E, Garson S, Tousson G et al. Fat injection to the breast: technique, results, and indications based on 880 procedures over 10 years. *Aesthet Surg J* 2009; 29: 360–376
- 21 Delay E, Delaporte T, Sinna R. [Breast implant alternatives]. *Ann Chir Plast Esthet* 2005; 50: 652–672
- 22 Rigotti G, Marchi A, Sbarbati A. Adipose-derived mesenchymal stem cells: past, present, and future. *Aesthetic Plast Surg* 2009; 33: 271–273
- 23 Rigotti G. Lipoaspirated stem cells may not have been placed in ischemic tissue: reply. *Plast Reconstr Surg* 2008; 122: 680–681
- 24 Rennekampff HO, Reimers K, Gabka CJ et al. Möglichkeiten und Grenzen der autologen Fetttransplantation – „Consensus Meeting“ der DGPRAC in Hannover, September 2009. *Handchir Mikrochir Plast Chir* 2010; 42: 137–142
- 25 Brayfield C, Marra K, Rubin JP. Adipose stem cells for soft tissue regeneration. *Handchir Mikrochir Plast Chir* 2010; 42: 124–128
- 26 Pulagam SR, Poulton T, Mamounas EP. Long-term clinical and radiologic results with autologous fat transplantation for breast augmentation: case reports and review of the literature. *Breast J* 2006; 12: 63–65
- 27 Klein JA. Anesthesia for liposuction in dermatologic surgery. *J Dermatol Surg Oncol* 1988; 14: 1124–1132
- 28 Herold C, Ueberreiter K, Cromme F et al. MRT-Volumetrie der Mamma zur Kontrolle der Fettresorptionsrate nach autologem Lipotransfer. *Handchir Mikrochir Plast Chir* 2010; 42: 129–134
- 29 Eder M, Kovacs L. [Commentary on the article of Herold et al.: The use of mamma MRI volumetry to evaluate the rates of fat survival after autologous lipotransfer]. *Handchir Mikrochir Plast Chir* 2010; 42: 135–136
- 30 Chan CW, McCulley SJ, Macmillan RD. Autologous fat transfer – a review of the literature with a focus on breast cancer surgery. *J Plast Reconstr Aesthet Surg* 2008; 61: 1438–1448
- 31 Illouz YG, Sterodimas A. Autologous fat transplantation to the breast: a personal technique with 25 years of experience. *Aesthetic Plast Surg* 2009; 33: 706–715
- 32 Rigotti G, Marchi A, Stringhini P et al. Determining the Oncological Risk of Autologous Lipoaspirate Grafting for Post-Mastectomy Breast Reconstruction. *Aesthetic Plast Surg* 2010
- 33 Illouz YG. The Fat Cell “Graft”: A New Technique to Fill Depressions. In: *Plastic and reconstructive surgery* 1986; 122–123