

# Use of Nitrous Oxide in Dermatology: A Systematic Review

ERICA A. BROTZMAN, DO,\* LAURA F. SANDOVAL, DO,\*† AND JONATHAN CRANE, DO\*†‡

---

**BACKGROUND** Many dermatologic procedures are painful and can be distressing to patients.

**OBJECTIVE** To determine whether nitrous oxide has been used in dermatology and whether literature supports its use in terms of providing analgesia and anxiety associated with dermatologic procedures.

**METHODS** A search of PubMed and Cochrane databases was conducted through July 15, 2016, to identify studies involving nitrous oxide use in dermatology.

**RESULTS** Eight studies were identified and reviewed. The use of nitrous oxide/oxygen mixture resulted in a significant reduction in pain when used for photodynamic therapy, botulinum toxin therapy for hyperhidrosis of both the palms and axilla, aesthetic procedures involving various laser procedures, and in the treatment of bed sores and leg ulcers. However, pain scores were higher when nitrous oxide/oxygen was used in the debridement of chronic ulcers when compared with the use of topical anesthesia. In addition, nitrous oxide has been reported effective at reducing pain in hair transplants, dermabrasion, excision and repairs, and pediatric procedures.

**CONCLUSION** Current literature provides some evidence that nitrous oxide, used alone or as adjunct anesthesia, is effective at providing analgesia for many dermatologic procedures. Nitrous oxide has many potential applications in dermatology; however, further evidence from randomized controlled trials is needed.

*The authors have indicated no significant interest with commercial supporters.*

---

Nitrous oxide (N<sub>2</sub>O) has been a widely used analgesic/anesthetic agent for over 150 years. Considered both safe and effective for dental and pediatric procedures, its use outside these specialties is not commonly recognized.<sup>1-3</sup> N<sub>2</sub>O has been used as a component of general anesthesia, but questions regarding long-term neurologic and cardiovascular sequelae have led to concerns. Recent reviews of N<sub>2</sub>O use in general anesthesia and the ENIGMA II trial have restored confidence in the long-term safety of the agent.<sup>4,5</sup> Although the use of N<sub>2</sub>O is most notable for its use in dentistry, its use in specialties such as urology and gastroenterology, is now being appreciated.<sup>6,7</sup>

The gas itself is tasteless, with a slightly fruity odor. It is absorbed quickly from the lungs and diffuses into plasma. There are no significant effects on the major

body systems with the exception of the central nervous system. Its mechanism of action includes stimulation of the beta endorphin system and antagonism of the NMDA receptor, resulting in effectiveness as an analgesic and anxiolytic.<sup>4</sup> Other advantages of N<sub>2</sub>O include its easily controllable duration of action, rapid onset and recovery, low side-effect profile, and patient satisfaction and convenience. The drug is expelled from the lungs within minutes after discontinuation, allowing the patient to fully recover quickly and permitting the patient to drive home safely.

Many dermatologic procedures are painful and can be distressing to patients. Local anesthesia is the primary method of anesthesia used for common office-based procedures in dermatology including biopsies, surgery, and cosmetic procedures. However, local

\*Campbell University School of Osteopathic Medicine, Buies Creek, North Carolina; †Department of Dermatology, Sampson Regional Medical Center, Clinton, North Carolina; ‡DermOne, Wilmington, North Carolina

© 2018 by the American Society for Dermatologic Surgery, Inc. Published by Wolters Kluwer Health, Inc. All rights reserved.  
ISSN: 1076-0512 • *Dermatol Surg* 2018;44:661-669 • DOI: 10.1097/DSS.0000000000001464

anesthesia alone may not always adequately control pain and anxiety. The purpose of this study is to perform a systematic review to determine whether nitrous oxide has been used in dermatology and whether literature supports its use in terms of providing analgesia and sedation associated with dermatologic procedures.

## Methods

To identify studies regarding the use of N<sub>2</sub>O in dermatology, a search of PubMed and Cochrane databases was conducted using the key words: “nitrous oxide and dermatology” and “nitrous oxide and dermatologic.” The search was limited to clinical trials published through July 15, 2016. Articles using N<sub>2</sub>O in combination with general anesthesia or conscious sedation for skin procedures were excluded, as these methods of anesthesia are not readily used or available in general and surgical dermatology. This search yielded 43 results, and after the publications were reviewed for content, relevance, and duplicates; a total of 7 articles were selected (Figure 1). One full text article was not available in English, and Google Translate was used to translate the full text from German into English. References from each article were reviewed to identify additional studies not captured from the literature search and 1 additional article was selected. From each study, data on sample size, type of procedure performed, outcomes including

efficacy in terms of reduction in pain and/or achievement of sedation, adverse effects (AEs), and safety were reviewed.

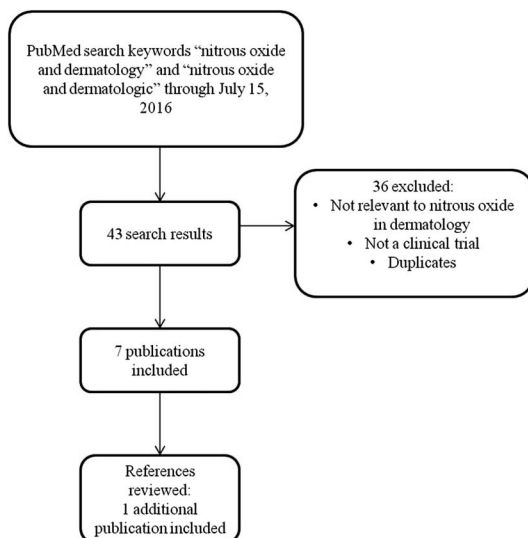
## Results

The authors' literature search identified 8 clinical trials using N<sub>2</sub>O in dermatology (Table 1). Procedures studied included photodynamic therapy (PDT), botulinum toxin for hyperhidrosis of the axilla and palms, laser procedures, debridement of chronic ulcers and bed sores, hair transplants, dermabrasion, excisions and repairs, and pediatric procedures in combination with benzodiazapines. All studies reviewed, except for the use of N<sub>2</sub>O for debridement of chronic ulcers, favored the use of N<sub>2</sub>O.

## Outcomes

Five of the 8 studies reported changes in pain using a validated measurement instrument such as the Visual Analog Scale (VAS), the Verbal Rating Scale (VRS), the Verbal Scale of Pain Intensity (VSPI), or the *L' échelle Comportementale pour Personnes Agées* (ECPA, a behavior scale to evaluate pain in non-communicating adults).

Fink and colleagues<sup>8</sup> evaluated the effect of N<sub>2</sub>O/oxygen inhalation mixture on pain intensity during PDT treatment of actinic keratoses. All patients received PDT using 5-aminolevulinic acid, and all patients received oral analgesics, 800-mg ibuprofen 30 minutes before treatment. The treatment area was additionally cooled by means of a cold air fan. Patients reporting a VAS  $\geq 6$  when treated with PDT on 1 cheek ( $n = 39$ ) were given the option of inhaled N<sub>2</sub>O/oxygen mixture (using 50% concentration N<sub>2</sub>O and 50% oxygen) for treatment on the contralateral cheek on the following day ( $n = 30$ ). The mean VAS for PDT without N<sub>2</sub>O was 7.8 compared with a mean VAS of 3.5 for PDT with N<sub>2</sub>O. The mean VAS reduction was 4.2 ( $p < .001$ ), an overall reduction in pain of 55.2% using N<sub>2</sub>O during treatment. N<sub>2</sub>O also significantly decreased the number of interruptions of PDT treatment. There were 50 interruptions in treatment without N<sub>2</sub>O versus 9 interruptions using N<sub>2</sub>O, an 82% reduction in treatment interruptions. In addition,



**Figure 1.** Flowchart of literature search.

TABLE 1. Outcomes From Dermatologic Studies Using Nitrous Oxide

Study (No. of Patients)	Type of Study	Procedure Performed	Pain Outcomes	Other Outcomes
Fink and colleagues <sup>8</sup> (n = 71)	Prospective, single-center, controlled, observational	Photodynamic therapy for actinic keratoses	VAS before N <sub>2</sub> O: 7.8; after N <sub>2</sub> O: 3.5, mean pain reduction of 4.2 (55.2%, <i>p</i> < .001).	82% reduction in therapy interruptions secondary to pain. Increased treatment satisfaction.
Paracka and colleagues <sup>9</sup> (n = 13)	Open-label, observational, intraindividual	Botulinum toxin injections for hyperhidrosis	Significant reduction in injection site pain with N <sub>2</sub> O. Axilla: VAS reduced from 55.7 to 12.8 ( <i>p</i> = .0002). Palms: VAS reduced from 60.0 to 13.3 ( <i>p</i> = .0001).	All patients insisted that subsequent treatments include N <sub>2</sub> O.
Drosner <sup>10</sup> (n = 24)	Prospective, open-label, observational	Multiple aesthetic laser procedures	Significant decrease in treatment pain with N <sub>2</sub> O; VAS reduced from 6.6 to 2.9 ( <i>p</i> = .000).	23/24 patients preferred N <sub>2</sub> O for their next treatment, even at an increased cost.
Claeys and colleagues <sup>12</sup> (n = 41)	Randomized, multicenter, open-label	Debridement of leg ulcers	Increase pain in N <sub>2</sub> O group vs topical anesthetic group; VAS of 5.9 vs 3.68, respectively ( <i>p</i> < .001).	More frequent procedure interruptions secondary to pain in N <sub>2</sub> O group. Significant sedation was measured in N <sub>2</sub> O group.
Paris and colleagues <sup>11</sup> (n = 34)	Randomized, crossover, open-label	Care of bedsores and varicose ulcers	Reduction in pain in both N <sub>2</sub> O arms; morphine arm ECPA + 5.2 vs N <sub>2</sub> O arm -0.3 and N <sub>2</sub> O + morphine -0.6 ( <i>p</i> < .01).	
Otley and Nguyen <sup>15</sup> (n = 8)	Prospective, observational	Pediatric dermatologic procedures (excisions, biopsies, and pulsed dye laser)	Not reported	Effective sedation to complete all 11 procedures when N <sub>2</sub> O was used in combination with oral benzodiazepines.
Sadick and Militana <sup>13</sup> (n = 200)	Prospective, observational	Hair transplantation surgery	Substudy (50 pts): 94% of patients preferred N <sub>2</sub> O vs valium in terms of pain reduction.	
Maloney and colleagues <sup>14</sup> (n = 47)	Observational	Multiple dermatologic procedures (dermabrasion, excision/repair, hair transplants, and laser)	Most patients favored N <sub>2</sub> O.	46/47 patients would request N <sub>2</sub> O again. 45/47 said that it should be used more often by dermatologists.

VAS, visual analog scale.

patient satisfaction was reported using the Treatment Satisfaction Questionnaire for Medication (TSMQ), which showed a median score of 68.7% (very satisfied) for effectiveness, 95.6% (extremely satisfied) for side effects, 89.3% (extremely satisfied) for convenience, and 75.5% (very satisfied) for global satisfaction.

In a study of botulinum toxin therapy for hyperhidrosis, Paracka and colleagues<sup>9</sup> evaluated the effectiveness of inhaled N<sub>2</sub>O at reducing injection site pain (ISP) for treatment of the axilla and/or palms. Thirteen patients participated and had both the axilla ( $n = 11$ ) and/or palms ( $n = 3$ ) treated, 1 with and 1 without N<sub>2</sub>O. The N<sub>2</sub>O/oxygen inhalation mixture was started 5 minutes before the botulinum toxin injections and was stopped immediately after the procedure. For patients treated for axillary hyperhidrosis, there was a significant reduction in ISP when N<sub>2</sub>O was used based on both VAS scores and VSPI scores  $55.7 \pm 12.7$  to  $12.8 \pm 7.5$  ( $p = .002$ ) and  $4.1 \pm 0.03$  to  $0.7 \pm 0.05$  ( $p = .003$ ), respectively. Similar improvement in ISP was seen in treatment of the palms, with N<sub>2</sub>O reducing the VAS from  $60.0 \pm 10.0$  to  $13.3 \pm 5.8$  ( $p = .0001$ ) and the VSPI from  $5.0 \pm 0$  to  $1.3 \pm 0.5$  ( $p = .021$ ). In addition, all patients preferred the use of N<sub>2</sub>O for future botulinum toxin treatments.

Drosner and colleagues evaluated the use of inhaled N<sub>2</sub>O for pain reduction during various aesthetic procedures.<sup>10</sup> This prospective, open-label, observational study included 24 patients who completed a total of 46 treatments; however, pain was only measured in 26 of the treatments using the VAS scale. Procedures included facial rejuvenation with fractionated radio-frequency or CO<sub>2</sub> laser ( $n = 16$ , all these patients also received lidocaine gel 30% and some used cold air, dexketoprofen, or midazolam), intense pulse light treatment for rosacea ( $n = 16$ ), tattoo laser treatment ( $n = 8$ , cold air used in 7 treatments), treatment of hemosiderosis ( $n = 1$ , cold air used) with Q-switch Nd:YAG, nonablative fractional laser with Er:glass for acne scars ( $n = 4$ , all also received lidocaine 30% gel, 3 used cold air), or hyperpigmentation ( $n = 1$ , lidocaine gel 30% and cold air used). Patients completed the first half of their treatment without N<sub>2</sub>O and were then provided inhaled N<sub>2</sub>O half-way through the procedure until the conclusion, using an on-demand sys-

tem. For patients' receiving their first treatment ( $n = 21$ ), N<sub>2</sub>O reduced pain on the VAS score from 6.5 to 2.8 ( $p = .000$ ). For patients' receiving their second treatment ( $n = 5$ ), pain was reduced from 6.7 to 3.1 ( $p = .0230$ ). Overall reduction in VAS score for all treatments was 6.6 to 2.9 (.000). Pain intensity was reduced in all but 1 treatment. All patients except one, when questioned said that they would prefer future treatments with the use of N<sub>2</sub>O, regardless of the increased cost to the patient.

The efficacy of inhaled N<sub>2</sub>O, with or without oral morphine, was evaluated in the care of bedsores and ulcers in a randomized, cross-over, multicenter, prospective, open-label pilot study by Paris and colleagues<sup>11</sup> In this study, 34 elderly inpatients received morphine (1 mg/10 kg subcutaneous), N<sub>2</sub>O plus morphine, or N<sub>2</sub>O alone, each for 2 days for total study duration of 6 days. Lesions treated included bedsores ( $n = 28$ ) or varicose ulcers ( $n = 6$ ). Outcomes reported included a significantly higher pain scale for the treatments with morphine using the ECPA compared with treatments with N<sub>2</sub>O or N<sub>2</sub>O plus morphine ( $+5.2 \pm 8.6$ ,  $-0.3 \pm 8$ , and  $-0.6 \pm 7.4$ , respectively,  $p < .01$ ). There was not a significant difference in pain between the N<sub>2</sub>O and N<sub>2</sub>O with morphine groups. There were similar differences in the global heteroevaluation scale (a nurse evaluation rating patient comfort during procedure) and the DOLOPLUS-2 scales (a behavior pain assessment for patients with cognitive impairment). There were not enough data to evaluate the VAS scores.

The final article reviewed that used a pain measurement instrument to assess changes in pain was a randomized, multicenter, open-label study by Claeys and colleagues which compared inhaled N<sub>2</sub>O to lidocaine-prilocaine cream in the debridement of chronic leg ulcers.<sup>12</sup> Debridements were performed daily for up to 14 days. Forty-one patients were randomized and included in the analysis, with 20 patients randomized to receive N<sub>2</sub>O during multiple debridements (95 total debridements) and 21 patients randomized to receive lidocaine-prilocaine cream during debridements (114 total debridements); however, not all patients completed the study, with 12 discontinuing early. In contrast to the previous studies, pain based on the VAS

score was significantly higher in the N<sub>2</sub>O group compared with the topical analgesic, 5.29 versus 3.68, respectively (95% confidence interval [CI] 1.14–2.09;  $p < .001$ ). Similarly, on the VRS scale, debridement with N<sub>2</sub>O was scored 2.87 compared with 1.71 with lidocaine–prilocaine cream (95% CI 0.57–1.04;  $p < .001$ ). There was no significant difference in the duration of each debridement session between the groups or in the number of days of debridement. The N<sub>2</sub>O group requested early interruption of debridement procedures because of pain and discomfort more frequently (26 cases) than in the lidocaine-prilocaine cream arm (12 cases),  $p < .002$ . Extent of sedation was measured in the N<sub>2</sub>O group using the Ramsay sedation score which changed significantly from an average score of 1.99 (0.43 SD) before the N<sub>2</sub>O inhalation to an average score of 2.23 (0.72 SD),  $p = .003$ .

In a study by Sadick and Militana<sup>13</sup> evaluating the use of N<sub>2</sub>O in hair transplantation, the efficacy of its use at reducing pain was measured according to patient preference of anesthesia. A total of 400 hair transplants were completed in 200 patients using inhaled N<sub>2</sub>O before an infiltration of lidocaine/epinephrine, with side-effect profiles obtained from all 200 patients. In a subset of 50 of these patients, the first transplant session was conducted using oral valium 10 mg and Dermajet injection of 1% lidocaine before the infiltration of lidocaine/epinephrine. In the second session, the same patients underwent transplantation using N<sub>2</sub>O as an inducing agent before the lidocaine/epinephrine infiltration. In terms of pain level, 94% of the patients (47 vs 3) preferred the N<sub>2</sub>O to the valium/ Dermajet.

A 1980 study using N<sub>2</sub>O for various dermatologic surgical procedures similarly reported efficacy in terms of patient preference.<sup>14</sup> Forty-seven patients underwent procedures such as dermabrasion ( $n = 7$ ), excision and repair ( $n = 29$ ), laser treatment ( $n = 2$ ), and hair transplantation ( $n = 9$ ). In all procedures, patients received N<sub>2</sub>O by nasal or oral route, up to 70% N<sub>2</sub>O concentration (only 5 patients received over 40% concentration) before administration of local anesthesia (except with dermabrasion in which refrigerants were used instead) and continued to completion of the procedure. All but 4 patients felt that their experience

was pleasant and 46 of the 47 patients would request the use of N<sub>2</sub>O in the future. Forty-five patients felt that N<sub>2</sub>O should be used as adjunct therapy by dermatologist more often.

The final article reviewed was a study using inhaled N<sub>2</sub>O in combination with oral benzodiazepines for sedation during pediatric dermatologic procedures.<sup>15</sup> Eight pediatric patients underwent 11 procedures including excisions ( $n = 6$ ), biopsies ( $n = 1$ ), and pulse dye laser therapy ( $n = 4$ ). Sedation regimes included N<sub>2</sub>O administered at concentrations between 20% and 50% and the use of midazolam ( $n = 7$ ), diazepam ( $n = 1$ ), or lorazepam ( $n = 3$ ). Patients additionally received topical eutectic mixture of local anesthetics ( $n = 2$ ) and/or local anesthesia ( $n = 10$ ). Efficacy at reducing pain was not reported, instead authors reported on the efficacy at achieving adequate sedation, with 7 episodes rated as excellent sedation, 3 as good sedation, and 1 episode as fair to poor response. The fair to poor response was reported for the fourth procedure in a patient who had 3 previous pulse dye laser treatments for a wart and anxiety was believed to have escalated with repeated treatments. The combination of N<sub>2</sub>O and benzodiazepine provided effective sedation to complete all 11 procedures, and patients and parents were reported to be satisfied with the sedation.

### **Adverse Effects**

All 8 studies reviewed reported on AEs. All AEs were mild and generally limited to time of inhalation, with the exception of the combination regimes using benzodiazepines or morphine where duration of the effects of these drugs is longer than that of N<sub>2</sub>O. Common AEs from pooled data were laughter, euphoria, nausea, and dizziness (Table 2).

The greatest amount of data on AEs from a single study was obtained from the study by Sadick and Militana<sup>13</sup> evaluating the effects of N<sub>2</sub>O in 200 hair transplant patients. The most commonly reported AE was mood lability in 36 patients (18%), followed by nausea in 12 patients (5%) and dizziness in 5 patients (2.5%). Mood lability was further described as laughter (78%), dissociation from surroundings

**TABLE 2. Most Common Adverse Effects From Nitrous Oxide (n = 298)<sup>3,8,9</sup>**

<i>Adverse Effects</i>	<i>No. of Patients (%)</i>
Mood lability	64 (21)
Laughter (28)	
Dissociation from surroundings/ euphoria (19)	
Anxiety (8)	
Sensation of inebriation (3)	
Crying (2)	
Fear of losing control (2)	
Hysteria (1)	
Delusions (1)	
Nausea	14 (5)
Dizziness	14 (5)
Vertigo	4 (1)
Meaningless/disjoined verbal expressions	4 (1)
Stopped nitrous oxide due to uneasy feeling	4 (1)
Vomiting	2 (<1)

(42%), anxiety (14%), crying (3%), hysteria (3%), and delusions (3%).

### **Safety**

In the studies reviewed, 5 used monitoring of oxygen saturation through pulse oximetry during the use of the inhaled N<sub>2</sub>O.<sup>10–13,15</sup> In addition, vital signs (heart rate and blood pressure) were monitored in 4 studies.<sup>11–13,15</sup>

Patients maintained oxygen saturation during treatment with N<sub>2</sub>O, except 1 case of a short drop in saturation to 87% in the Drosner and colleagues' aesthetic study.<sup>10</sup> In addition, in the study of treatment of bedsores and ulcers, which only recorded oxygen saturation at the beginning and end of the procedure, there were significant differences in the saturation before and after treatment in the 2 arms of the study that used N<sub>2</sub>O; however, further details were not reported. Vitals similarly were reported to remain stable in all studies except a slight increase in systolic and diastolic arterial pressure after ulcer debridement in both groups in the Claeys and colleagues<sup>12</sup> study and in the N<sub>2</sub>O group, there was also an increase in partial oxygen saturation and heart rate after the painful procedure. There was also a significant change in arterial pressure between the beginning and end of treatment in the morphine group in the care of bedsores and ulcers.<sup>11</sup>

### **Discussion**

The use of N<sub>2</sub>O is well established in dentistry; however, its potential use in other specialties is now being recognized. Studies now support the use of N<sub>2</sub>O for procedures including, but not limited to, colonoscopies, cystoscopies, prostatic biopsy, lithotripsy, bone marrow aspiration, venous cannulation, and liver biopsy.<sup>6,7,16,17</sup> The authors' literature search provides evidence that the use of N<sub>2</sub>O may have a place in providing analgesia and sedation during painful dermatologic procedures, with the majority of the studies reviewed supporting this. All the clinical trials reviewed favored the use of N<sub>2</sub>O in procedures ranging from facial rejuvenation, PDT, hair transplantation, and pediatric procedures, with the exception of 1 of the 2 studies evaluating the use of N<sub>2</sub>O for pain during debridement of ulcers. This study by Claeys and colleagues<sup>12</sup> found that the use of topical anesthesia was superior to the use of inhaled N<sub>2</sub>O for debridement of leg ulcers. It is not possible, however, to conclude from this article whether N<sub>2</sub>O does or does not provide some analgesia because the study did not compare the use of N<sub>2</sub>O/oxygen mixture to oxygen alone, it can only be concluded that N<sub>2</sub>O is not as effective as topical anesthesia. In fact, the study evaluating N<sub>2</sub>O compared with morphine for pain control during treatment of bedsores and ulcers found that N<sub>2</sub>O provided greater analgesia than morphine.<sup>11</sup> The treatment of chronic ulcers can be particularly painful, and as Claeys and colleagues emphasized, neither the lidocaine–prilocaine cream nor N<sub>2</sub>O completely managed pain. A combination of the 2 was suggested, and in fact, the majority of the studies reviewed, N<sub>2</sub>O was used as an adjunct tool for control of pain, used most commonly in conjunction with local anesthesia. Studies to further clarify a potential role for the use of N<sub>2</sub>O in the treatment of ulcers would be of benefit.

In addition to the publications identified in this review, a few other articles deserve mention and show further potential uses for N<sub>2</sub>O in dermatology. Several publications discuss the use of N<sub>2</sub>O in combination with tumescent anesthesia for procedures such as liposuction or venous ablation. No clinical trials were found studying the use of N<sub>2</sub>O for liposuction; however, 2 articles recommend its use as adjunct to tumescent

local anesthesia based on antidotal experience.<sup>18,19</sup> Although not captured in the authors' literature search, Meier and colleagues<sup>20</sup> studied the use of N<sub>2</sub>O during the administration of tumescent local anesthesia for endovenous laser ablation. The N<sub>2</sub>O group ( $n = 30$ ) reported a statistically significant lower mean pain score compared with control group ( $n = 30$ ). Another study not captured in the authors' search is a randomized, placebo-controlled, double-blind trial using N<sub>2</sub>O for minor eyelid surgery.<sup>21</sup> Although not all procedures included in this study were applicable to dermatology, many of the procedures are routinely performed such as excisional biopsy of benign and malignant lesions and xanthelasma excision. In this study, where 50 patients received N<sub>2</sub>O before and during injection of local anesthesia and 50 patients received air, there was no significant difference in the pain score or the discomfort score between the groups. Nandi and Howard list the use of Entonox N<sub>2</sub>O as a method of anesthesia for painful procedures in children older than 6 years with epidermolysis bullosa.<sup>22</sup> Finally, although based on anecdotal experience, the authors of this review have found the use of N<sub>2</sub>O as adjunct anesthesia for fractionated CO<sub>2</sub> procedures to be of benefit in terms of providing anesthesia and sedation, and patient satisfaction is high. It has replaced the need for anxiolytics in most cases and because the recovery is quick (generally accepted recovery times are 5–10 minutes; however, some studies have found that return to baseline psychomotor functions occurs within 30 minutes), it allows the patient to safely drive themselves home.<sup>23,24</sup>

Adverse effects associated with N<sub>2</sub>O have been well documented in literature. A systematic review of literature by Pedersen and colleagues found that N<sub>2</sub>O is particularly safe for short procedures (under 15 minutes), and that serious and potential serious AEs rarely occur (less than 0.5% of cases), whereas minor AEs occur in 4% to 8% of cases.<sup>25</sup> In a large pediatric study which included 5,799 children, the most common minor AEs included nausea (1.6%), vomiting (2.2%), and diaphoresis (0.4%).<sup>25,26</sup> Nine patients (0.14%) had potentially serious AEs including 4 patients who experienced brief oxygen desaturation from 79% to 89%, and 3 other children experienced brief (less than 3 minutes), generalized

tonic–clonic seizures (2 patients had previous history of seizures). Similar minor AE profiles were reported in the dermatologic studies reviewed here. Adverse effects were mild and transient and well tolerated by patients. In terms of safety monitoring, the majority of the studies (5/8) used monitoring of oxygen saturation with pulse oximetry, and half of the studies additionally monitored vital signs. Authors of these studies emphasized that although the use of N<sub>2</sub>O is safe, it is not without risks, and stressed the importance of monitoring to avoid and/or detect complications. There has in fact been a death reported in a patient receiving N<sub>2</sub>O for liposuction surgery, performed by a dermatologist, when the patient was unintentionally given 100% N<sub>2</sub>O instead of 100% oxygen.<sup>19</sup> The patient was not monitored by pulse oximetry. Four of the more recent studies reviewed used a 50% N<sub>2</sub>O/50% oxygen mixture, with gas delivered through an on-demand valve activated by a patient's inspired breath, preventing hypoxia during administration and minimizing the risk of over sedation (Livopan or Entonox; Linde Gas Therapeutics, Unterschleißheim, Germany).<sup>8–11,27</sup> This newer system is marketed as providing added safety and appropriate for many settings where rapid and controlled pain management is needed. As Pederson and colleagues emphasize in their systematic review, the safety of fixed 50% N<sub>2</sub>O/50% oxygen mixture for procedural sedation has been supported in literature by several large studies.<sup>25,26,28,29</sup> The authors of this review have experience using the Livopan and have found the machine easy to use and safe; they too implement monitoring of oxygen saturation in all patients.

Dermatologists choosing to use N<sub>2</sub>O should be aware of a few contraindications for its use. Patients, providers, and assistants should not be pregnant, as it is contraindicated in the first trimester of pregnancy. Other relative contraindications include nasal obstruction, chronic obstructive pulmonary disease, active cystic fibrosis, recent tympanic membrane surgery, claustrophobia, intoxication, and others.<sup>15</sup>

Limitations in the studies reviewed include small sample size in most of the studies. In addition, only 5 of the 8 studies included the use of a validated measurement instrument to assess pain. Furthermore, randomization

and adequate control groups in the studies were lacking, resulting in a low level of evidence.

Future, well-designed, randomized clinical trials are needed to provide evidence in support of the use of N<sub>2</sub>O in dermatology. Its use has many potential beneficial applications in dermatology, especially in the area of pediatric procedures, where children often require general anesthesia even for minor procedures. Currently, even without strong evidence to support its use, it is recommended and being used for many dermatologic procedures, as seen in this review. The use of N<sub>2</sub>O is even recommended in the 2016 UK guidelines for the management of Stevens-Johnson syndrome/toxic epidermal necrolysis in adults with less than 10% body surface involvement for procedures such as dressing changes and bathing that may require supplementary analgesia, although they do grade the strength of this recommendation as a D.<sup>30</sup>

## Conclusion

Overall, N<sub>2</sub>O shows promise as an adjunctive agent for control of pain in dermatologic procedures, albeit studies are sparse and well-designed randomized controlled studies are lacking. The studies identified and reviewed provided evidence supporting the efficacy of using inhaled N<sub>2</sub>O for a range of dermatologic procedures. Adverse effects were tolerable and the treatment is safe. The authors feel that N<sub>2</sub>O may prove beneficial in dermatology for pediatric procedures, Mohs surgery, cosmetic laser procedures, and any other procedure where the patient may require sedation or adjunct anesthesia in addition to local anesthesia. The cost (the authors estimate the cost to be approximately \$20 dollars per procedure), time to administer/recover, the need to monitor, and the risk versus benefit, albeit the costs and risks are minimal, may not justify the use of N<sub>2</sub>O for minor day to day procedures such as biopsies, excisions, and cosmetic procedures such as injection of neurotoxins and fillers. Future randomized controlled trials are needed to substantiate its clinical utility and better define its niche in dermatology.

## References

- Hennequin M, Collado V, Faulks D, Koscielny S, et al. A clinical trial of efficacy and safety of inhalation sedation with a 50% nitrous oxide/oxygen premix (Kalinox) in general practice. *Clin Oral Investig* 2012; 16:633–42.
- Mohan R, Asir VD, Shanmugapriyan EV, Ebenezer V, et al. Nitrous oxide as a conscious sedative in minor oral surgical procedure. *J Pharm Bioallied Sci* 2015;7:S248–50.
- Kanagasundaram SA, Lane LJ, Cavalletto BP, Keneally JP, et al. Efficacy and safety of nitrous oxide in alleviating pain and anxiety during painful procedures. *Arch Dis Child* 2001;84:492–5.
- de VK, Sneyd JR. Nitrous oxide: are we still in equipoise? A qualitative review of current controversies. *Br J Anaesth* 2013;111:877–85.
- Leslie K, Myles PS, Kasza J, Forbes A, et al. Nitrous oxide and serious long-term morbidity and mortality in the evaluation of nitrous oxide in the gas mixture for anaesthesia (ENIGMA)-II trial. *Anesthesiology* 2015;123:1267–80.
- Aboumarzouk OM, Agarwal T, Syed Nong Chek SA, Milewski PJ, et al. Nitrous oxide for colonoscopy. *Cochrane Database Syst Rev* 2011:CD008506.
- Young A, Ismail M, Papatsoris AG, Barua JM, et al. Entonox(R) inhalation to reduce pain in common diagnostic and therapeutic outpatient urological procedures: a review of the evidence. *Ann R Coll Surg Engl* 2012;94:8–11.
- Fink C, Uhlmann L, Enk A, Gholam P. Pain management in photodynamic therapy using a nitrous oxide/oxygen mixture: a prospective, within-patient, controlled clinical trial. *J Eur Acad Dermatol Venereol* 2016;31:70–4.
- Paracka L, Kollwe K, Dengler R, Dressler D. Botulinum toxin therapy for hyperhidrosis: reduction of injection site pain by nitrous oxide/oxygen mixtures. *J Neural Transm (Vienna)* 2015;122:1279–82.
- Drosner M. Nitrous oxide—oxygen analgesia in aesthetic dermatology. *Hautarzt* 2013;64:435–42.
- Paris A, Horvath R, Basset P, Thiery S, et al. Nitrous oxide-oxygen mixture during care of bedsores and painful ulcers in the elderly: a randomized, crossover, open-label pilot study. *J Pain Symptom Manage* 2008;35:171–6.
- Claeys A, Gaudy-Marqueste C, Pauly V, Pelletier F, et al. Management of pain associated with debridement of leg ulcers: a randomized, multicentre, pilot study comparing nitrous oxide-oxygen mixture inhalation and lidocaine-prilocaine cream. *J Eur Acad Dermatol Venereol* 2011;25:138–44.
- Sadick NS, Militana CJ. Use of nitrous oxide in hair transplantation surgery. *J Dermatol Surg Oncol* 1994;20:186–90.
- Maloney JM III, Coleman WP III, Mora R. Analgesia induced by nitrous oxide and oxygen as an adjunct to local anesthesia in dermatologic surgery. Results of clinical trials. *J Dermatol Surg Oncol* 1980;6:939–43.
- Otley CC, Nguyen TH. Conscious sedation of pediatric patients with combination oral benzodiazepines and inhaled nitrous oxide. *Dermatol Surg* 2000;26:1041–4.
- Hjortholm N, Jaddini E, Halaburda K, Snarski E. Strategies of pain reduction during the bone marrow biopsy. *Ann Hematol* 2013;92:145–9.
- Meskine N, Vullierme MP, Zappa M, d'Assignies G, et al. Evaluation of analgesic effect of equimolar mixture of oxygen and nitrous oxide inhalation during percutaneous biopsy of focal liver lesions: a double-blind randomized study. *Acad Radiol* 2011;18:816–21.
- Bird G, Albert C. Nitrous oxide as an adjunct in tumescent liposuction. *J Cosmet Dermatol* 2005;4:267–71.
- Klein JA. Anesthesia for liposuction in dermatologic surgery. *J Dermatol Surg Oncol* 1988;14:1124–32.
- Meier TO, Jacomella V, Clemens RK, Amann-Vesti B. Nitrous oxide/oxygen inhalation provides effective analgesia during the



- administration of tumescent local anaesthesia for endovenous laser ablation. *Vasa* 2015;44:473–8.
21. Bhatt R, Child V, Kurli M, Musadiq M, et al. Use of inhaled nitrous oxide for minor eyelid surgery: a placebo-controlled study. *Orbit* 2003; 22:177–82.
  22. Nandi R, Howard R. Anesthesia and epidermolysis bullosa. *Dermatol Clin* 2010;28:319–24.
  23. Trojan J, Saunders BP, Woloshynowych M, Debinsky HS, et al. Immediate recovery of psychomotor function after patient-administered nitrous oxide/oxygen inhalation for colonoscopy. *Endoscopy* 1997;29: 17–22.
  24. Herwig LD, Milam SB, Jones DL. Time course of recovery following nitrous oxide administration. *Anesth Prog* 1984;31:133–5.
  25. Pedersen RS, Bayat A, Steen NP, Jacobsson ML. Nitrous oxide provides safe and effective analgesia for minor paediatric procedures—a systematic review. *Dan Med J* 2013;60:A4627.
  26. Zier JL, Liu M. Safety of high-concentration nitrous oxide by nasal mask for pediatric procedural sedation: experience with 7802 cases. *Pediatr Emerg Care* 2011;27:1107–12.
  27. Linde Healthcare Products & services. Livopan brochure general. Summary of product characteristics. Available from: [http://www.linde-healthcare.se/internet.lh.lh.swe/en/images/LIVOPAN%20brochure%20general%20\(16%20pp.\)580\\_110632.pdf?v=1.0](http://www.linde-healthcare.se/internet.lh.lh.swe/en/images/LIVOPAN%20brochure%20general%20(16%20pp.)580_110632.pdf?v=1.0). Accessed September 14, 2016.
  28. Annequin D, Carbajal R, Chauvin P, Gall O, et al. Fixed 50% nitrous oxide oxygen mixture for painful procedures: a French survey. *Pediatrics* 2000;105:E47.
  29. Onody P, Gil P, Hennequin M. Safety of inhalation of a 50% nitrous oxide/oxygen premix: a prospective survey of 35 828 administrations. *Drug Saf* 2006;29:633–40.
  30. Creamer D, Walsh SA, Dziewulski P, Exton LS, et al. UK guidelines for the management of Stevens-Johnson syndrome/toxic epidermal necrolysis in adults 2016. *J Plast Reconstr Aesthet Surg* 2016;69:e119–53.

---

Address correspondence and reprint requests to: Laura F. Sandoval, DO, Department of Dermatology, Sampson Regional Medical Center, 1099 Medical Center Drive, Wilmington, NC 28401, or e-mail: lsandovaldo10@gmail.com