

Dermatologic Diseases Not to Dismiss

Arkansas Dermatological Society

Edward W. Cowen, MD, MHS
 Head, Dermatology Consultation Service
 National Institutes of Health



1

Conflicts of interest: none

2

Anesthesiology:
 99% boredom/1% terror

Dermatology:
 99% common diseases/1% diseases not to
 (dis)miss

3

'Diagnostic Medical Truisms'



- Occam's razor
 - 'Diagnostic parsimony'
 - Fewest possible causes to account for all the patient's symptoms
- Hickam's dictum
 - Patients can have as many diseases as they want
 - Statistically: multiple common diseases vs. one rare disease

'If you hear hoof-beats, think of horses, *not* zebras'

4



5

Case 1

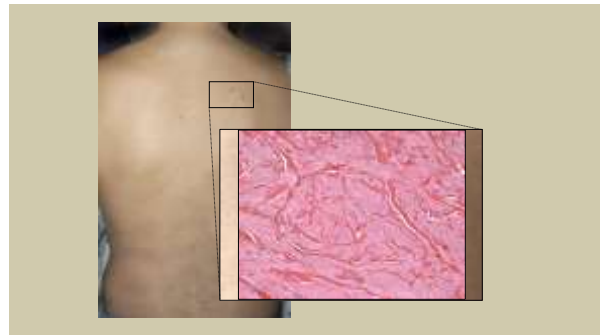
- When is a 'benign' nodule not so benign?

6

Case #1

33 yo male with nodules on the back for 10 years

7



8

Multiple cutaneous leiomyomas

- Trunk and extremities
- Mean age onset 25 yrs
- Increased number over time
- 92% pain, paresthesia

Am. J Hum Genet. 2003;73:95.

9

Diagnosis made!

10

Hereditary Leiomyomatosis and Renal Cell Cancer (HLRCC)

- 1973: Multiple cutaneous and uterine leiomyomas (MCUL): "Reed Syndrome"
 - Autosomal dominant
 - Cutaneous leiomyomas
 - Uterine leiomyomas
- 2001: Launenon "HLRCC"
 - Cutaneous, uterine leiomyomas
 - Papillary type II renal cell cancer
 - North American kindreds (35%)

Acta Derm Venereol 1973;53:409; PNAS 2001;98:3387; J. Med. Genet. 2006;43:523-526

11

Heritable RCC syndromes and skin

- Hereditary leiomyomatosis renal cell carcinoma (HLRCC)
- von Hippel-Lindau syndrome (VHL) → capillary malf. (head/neck)
- BAP1 syndrome (uveal, cutaneous melanoma, mesothelioma)
- Birt-Hogg-Dubé syndrome (BHD) → FF, TD, acrochordons


J Urol 2003;170:2163.

12

Hereditary Multiple Fibrofolliculomas With Trichodiscomas and Acrochordons

Arthur R. Birt, MD, PhD, FRCR, FRCR (Genitourinary), FRCR (Genitourinary), FRCR (Genitourinary), FRCR (Genitourinary), FRCR (Genitourinary), FRCR (Genitourinary), FRCR (Genitourinary)

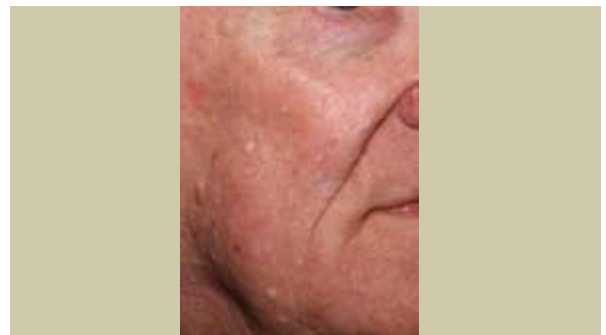From: Birt et al., Arch Dermatol-Vol 113, Dec. 1977



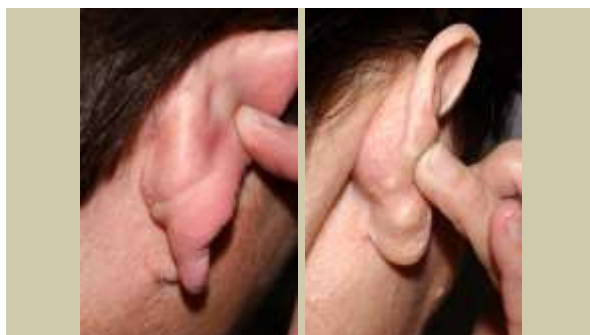Fibrofolliculomas Multiple acrochordons

Multiple renal tumors
Pulmonary cyst/
pneumothorax

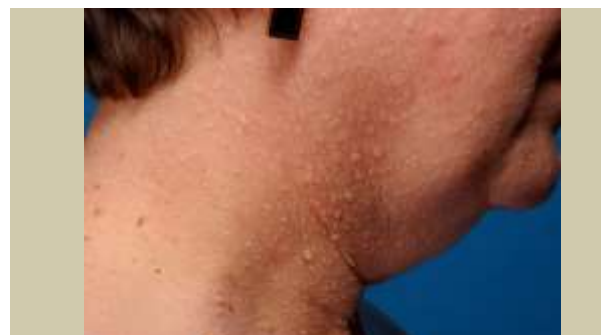13



14

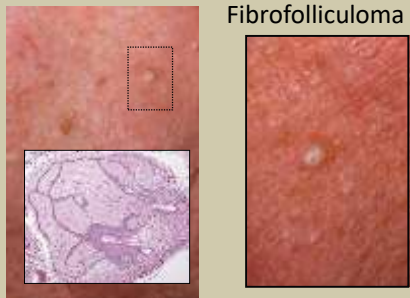


15



16



Fibrofolliculoma



17

Birt-Hogg-Dube:Genetics

- Autosomal dominant
- 2001: *BHD* gene, chr. 17p11.2
- 2002: "Folliculin"
 - 64 kDa protein

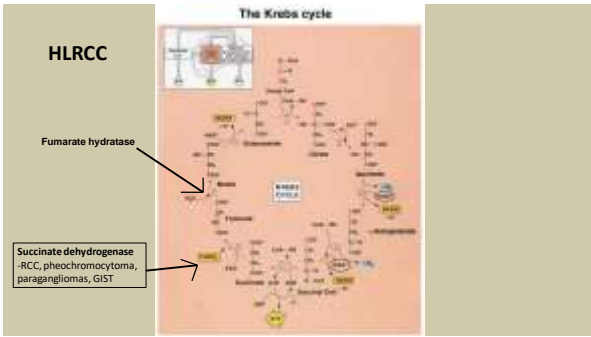



A mutation in the canine *BHD* gene is associated with hereditary multifocal renal cystadenocarcinoma and nodular dermatofibrosis in the German Shepherd dog

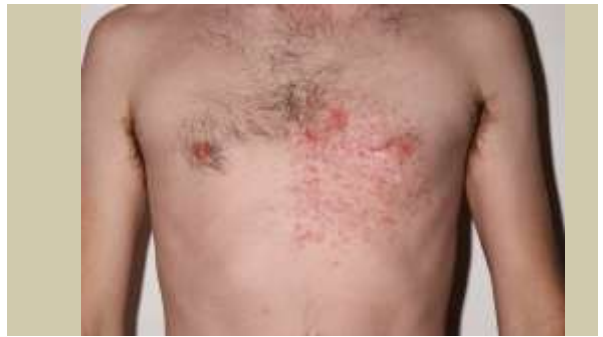From: Lippman, J., Ramirez O., Campbell, C., Etzel, F., Koberav, A., Asak, S., ... (2002)

Am J Hum Genet 2001;69:976; Cancer Cell 2002;2:167

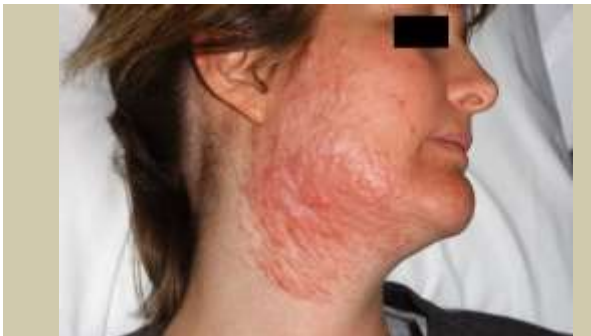18



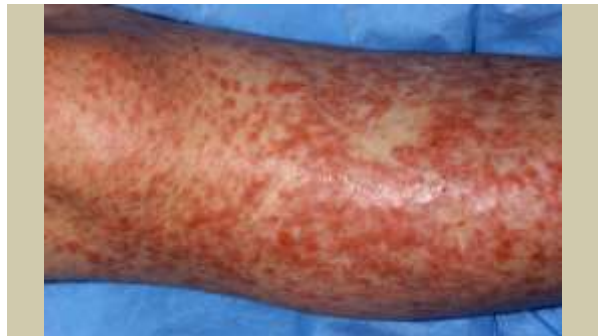19



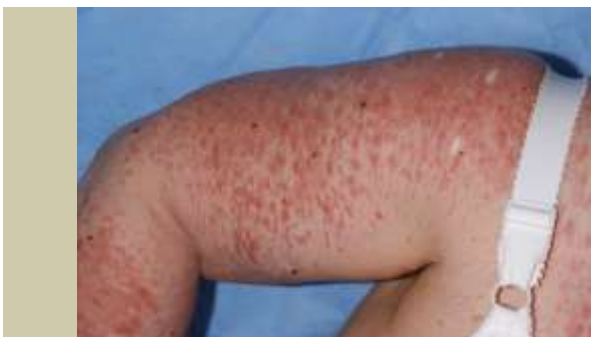20



21



22



23

HLRCC: uterine leiomyomas

- 46/47 women
- Hysterectomy
 - 57% age 30
 - 87% overall

Uterine leiomyomas: red
Cutaneous leiomyomas: blue

www.humpath.com Am J Hum Genet 2003;73:95.

24

How many leiomyomas is too many?

- Major criterion
 - Multiple cutaneous leiomyomas, with at least one histologically confirmed lesion
- Minor criteria
 - Solitary cutaneous leiomyoma and family history of HLRCC
 - In women, onset of severely symptomatic uterine fibroids before age 40
 - Type II papillary renal cell cancer before age 40
 - First-degree family member who meets one of the above-mentioned criteria
- **The presence of multiple cutaneous leiomyomas indicates a high likelihood of HLRCC. The diagnosis of HLRCC is suspected if ≥ 2 minor criteria are present.**

UpToDate. Accessed April 2019.

25

Case #1 Take home points

- Leiomyoma = HLRCC
- Perform full skin exam
- Obtain careful/family history
 - Painful lesions
 - Fibroids/hysterectomy
 - RCC
- Early renal screening/surveillance = life-saving
 - CT, MRI

26

Case 2

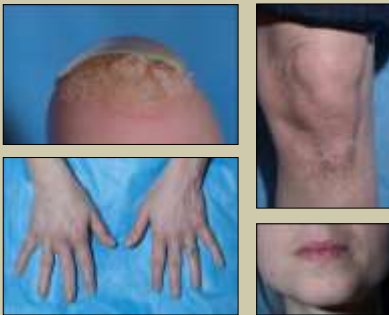- When a 'wart' is not just a 'wart'?

27

Case #2

"Healthy" 23 year old, warts since age 9
1 year post-partum, MBA student

28

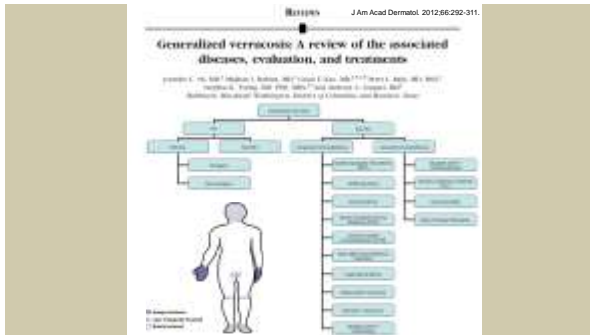

29

Case 2

- Imiquimod, cimetidine, squaric acid, laser Tx, LN2, tretinoin
- Treated in past with isotretinoin → improvement
- ? Report of low Ig
- Hx of VIN2/3, CIN2 (age 20)
- Hx of recurrent otitis media, arm/leg cellulitis
- Fam Hx: father → warts; maternal family hx leukemia (great aunt, g-mother, 2nd cousin)
- How much would you work up this patient?

30



31

GATA2 deficiency: "MonoMAC"

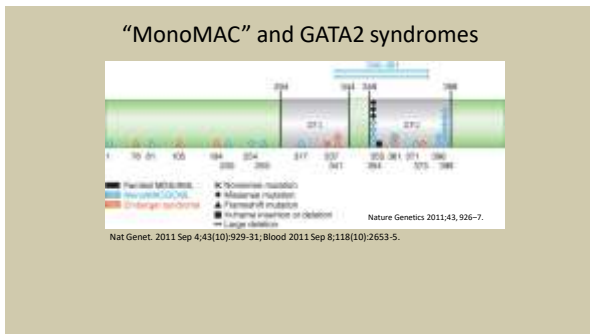
Autosomal dominant and sporadic monocytopenia with susceptibility to mycobacteria, fungi, papillomaviruses, and myelodysplasia

Blood. 2010;115:1519-1529

Primary immunodeficiency with variable age of onset

1. Profound monocytopenia (B, NK-penia)
2. Non-Tb mycobacteria, HPV, fungal infections
3. 10/18 malignancy
 - MDS/leukemia (9), vulvar CA, metastatic melanoma, Bowens, leiomyosarcoma

32



33

Emberger S.

- Primary lymphedema
- SN hearing loss
- AML
- HPV infection
- Anogenital dysplasia

Mutations in GATA2 cause primary lymphedema associated with a predisposition to acute myeloid leukemia (Emberger syndrome)

34

GATA 2 deficiency

Spinner et al. Blood 2014;123:809-21.

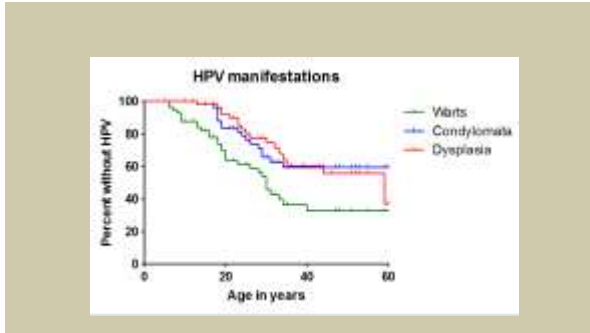
35

GATA2 deficiency: NIH cohort

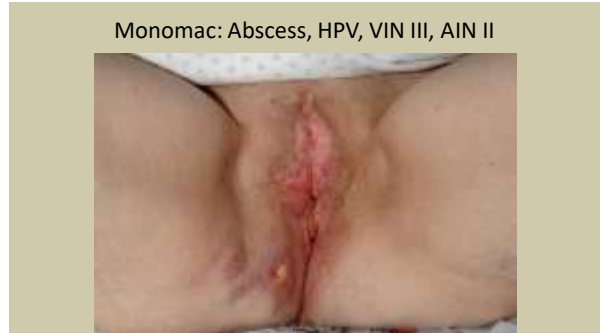- 57 patients (1992-2013)
 - 51% symptomatic by age 20 = late onset PID
 - 42/50 bone marrow → MDS (hypocellular)
 - Infections
 - HPV: 63%
 - HSV1/2: 16%, severe VZV: 11%, EBV: 11%, CMV: 4%
 - NTM: 53% (slow and rapid)
 - Bacterial: 49% (bacteremia 21%, skin/soft tissue 19%, C. difficile colitis 9%)
 - Fungal: 16% (aspergillosis 9%, histoplasmosis 5%)

Blood 2014;123:809-21.

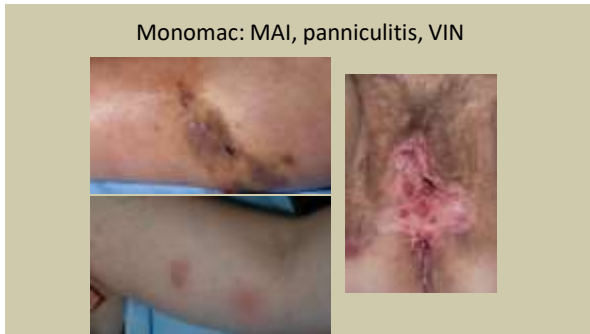36



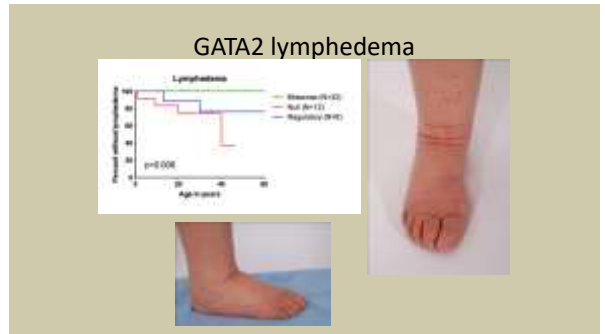
37



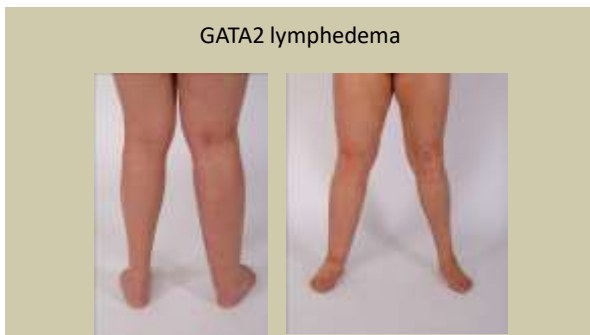38



39



40



41

- Case 2: follow-up
- Presented at NIH Derm Rounds Feb 2013
 - CBC: 0.05 monocytes (0.24-0.86K/uL)
 - Peripheral blood: 8-10% blasts
 - Bone marrow: 15% blasts (MDS/AML)
 - Dx: GATA2/Monomac w/ MDS/AML
 - March 13: induction chemoTx (ARA-C, idarubicin)
 - April 2013: 28% circulating blasts (2nd induction: ARA-C, clofarabine)
 - May 29, 2013: Allogeneic HSCT (unrelated donor)
 - June 25, 2013: Stage IV skin, liver, gut → deceased

42

Case #2: Take home points

- Aggressive HPV, lymphedema, MDS/AML, infection hx
- B, NK, monocytopenia → strongly suggestive of GATA2 deficiency
- 'Undefined' PID, marrow failure, MDS' could be GATA2
- Pediatric MDS/JMML (8/51)
 - Blood ASH Abstracts 2012:1699.
- Idiopathic CD4 lymphocytopenia (6/14)
 - Blood 2013;121:822-9.
- Aplastic anemia (5/99)
 - Blood ASH Abstracts 2012:3488.

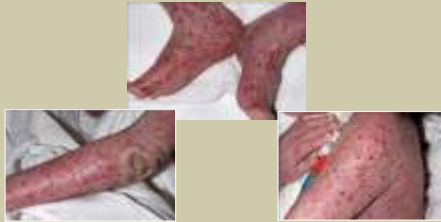43

Case 3

- When it is more than just 'really bad eczema'...

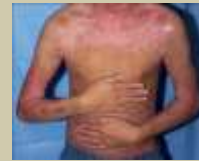44

- 8 year-old girl recalcitrant dermatitis (bx-proven)



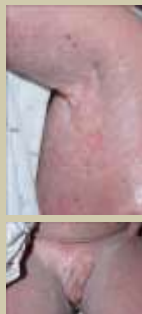45

- History
 - Atopic hx: anaphylaxis (maxipime); food allergy
 - Infections: pneumonia, bacteremia, line infections
 - M-Skeletal: no retained teeth, pathologic f(x), or scoliosis
 - Family hx: two affected brothers, parents healthy



46

- Diagnosis?
 - Complete physical evaluation
 - Oral exam: teeth, palate, tongue
 - No hyperextensibility
 - Genitalia/skin folds
 - Bacterial, viral cultures: MRSA, HSV
 - Skin biopsy: dermatitis NOS
 - Laboratory evaluation:
 - IgE: 14,500 (0-90 IU/ml)
 - Eos: 1.472 (0-0.77k/ul); 22%



47

- Severe atopic with MRSA, eczema herpeticum, Job syndrome...or something more?

LETTERS **Job syndrome** 2007:448-1058.

Dominant-negative mutations in the DNA-binding domain of STAT3 cause hyper-IgE syndrome

2007:357-1608.


STAT3 Mutations in the Hyper-IgE Syndrome



48

STAT3 Hyper IgE S.: facial appearance

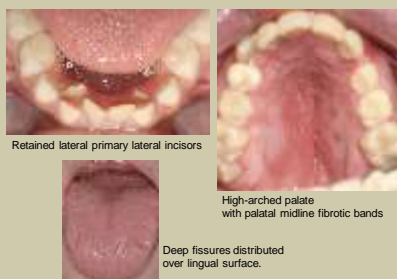
- Broad nasal root with fleshy nasal tip
- Coarse features with 'doughy' subcutaneous tissue
- Prominent wide forehead; prognathic pointed chin



Oral Diseases 14, p.73-81, January 2008

49

STAT3 Hyper IgE S.: oral findings (75%)



Retained lateral primary lateral incisors

High-arched palate with palatal midline fibrotic bands

Deep fissures distributed over lingual surface.

50

Table 2. Immunohistologic characteristics of Hyper IgE syndrome (HIES)	
Retention of primary teeth (71)	
Chondrolysis face (51)	
Mitral valve prolapse (71)	
Scoliosis > 20 degrees (61)	
Hypersensitivity to	
Oral mucosal and gingival abnormalities (71)	
Hypertrophic esophageal stenosis, malabsorption (61)	
Staphylococcus aureus (10)	
Candida albicans (10)	
Actinomyces israelii (10)	

Freeman et al. Oral Dis 2009;15:2-7.



51

Nov 2009;361:2046-55. *THE NEW ENGLAND JOURNAL OF MEDICINE*

ORIGINAL ARTICLE

Combined Immunodeficiency Associated with DOCK8 Mutations

Chen Zhenqiang, M.D., Jernmuh C. Chen, M.P.H., Jun Y. Lanfear, M.D., Alexander T. Sweetser, M.D., Steve Jeng, Ph.D., Anandita J. Tandon, M.D., Hideo I. Matsuda, D.D.S., Jun Chen, M.D., Shiro I. Taniuchi, M.D., Hideo Imai, M.D., Steven M. Holland, M.D., and Helen C. Su, M.D., Ph.D.

- Typical STAT3 HIES features:
 - Recurrent sinopulmonary infections
 - Recurrent *Staphylococcus aureus* skin infections
 - Elevated serum IgE
 - Severe chronic dermatitis
- Atypical features:
 - Lymphopenia
 - Asthma, severe food allergies/anaphylaxis
 - Severe cutaneous viral infections
 - Vulvar, facial, anal SCC

52

DOCK8 immunodeficiency: impetigo



53

DOCK8 immunodeficiency: dermatitis

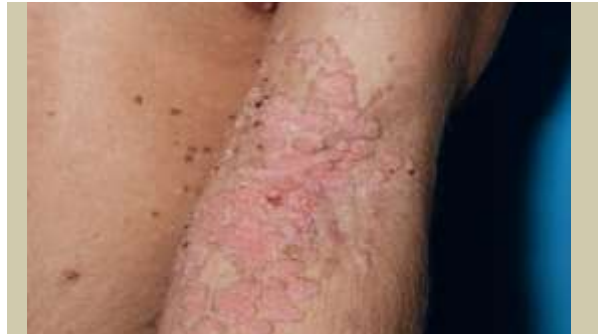

54

DOCK8 immunodeficiency:
cutaneous features

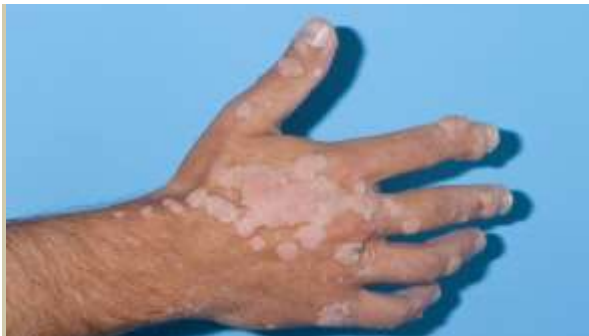Clinical or laboratory feature	Patients affected (%)
Atopic dermatitis	91
Asthma	41
Allergies	63
Bacterial skin infections	78
Mycobacterium chelonae	22
Any viral infection	88
HSV	47
HPV	36
MCV	41
VZV	22

Su HC. Curr Opin Allergy Clin Immunol 2010;10:515-520.

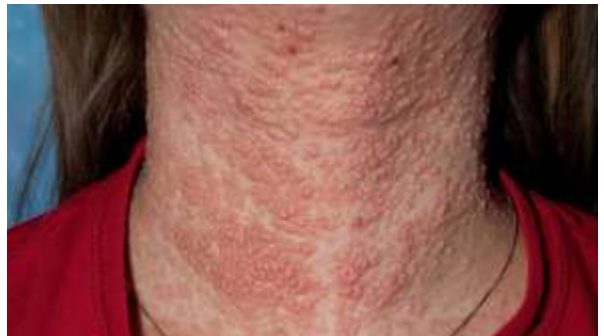

55

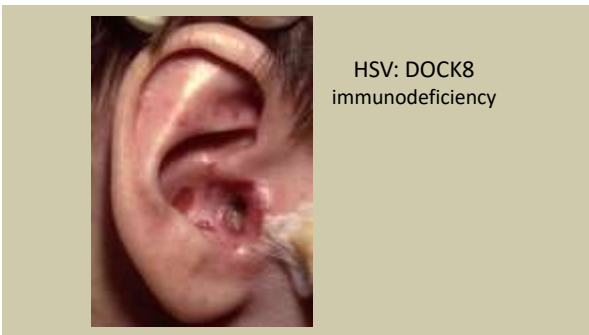
56



57

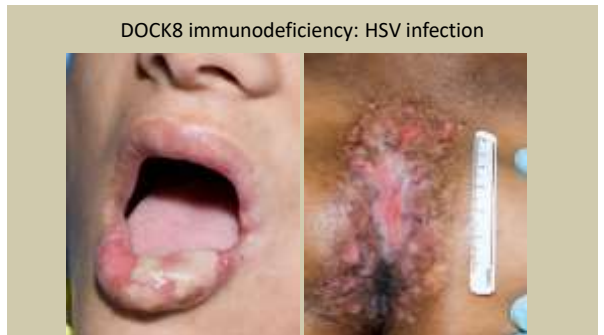

58



HSV: DOCK8
immunodeficiency

59

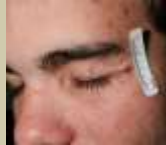

DOCK8 immunodeficiency: HSV infection

60

DOCK8 vs. STAT3 Hyper IgE clinical features

DOCK8	
	Patients affected (%)
Newborn rash	24
Coarse facies	0
Retention of primary teeth	5
Joint hyperextensibility	11
Minimal trauma fractures	5
Malignancies	
Squamous cell carcinoma	19
Lymphoma	10

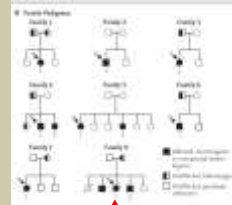


Chu E, et al. Arch Dermatol 2012;148:79-84.

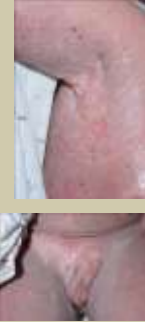SCC- 20yo w/ DOCK8

61

DOCK8



N Engl J Med 2009;361:2046-55.



62

DOCK8-associated mortality

Age (yrs)	Cause of Death
1 21	Metastatic anal squamous cell carcinoma
2 18	Cutaneous T cell lymphoma
3 13	Vulvar squamous cell carcinoma
4 18	Acinetobacter baumannii sepsis
5 26	Presumed lymphoma
6 22	Transplant complications

Consider Transplant Early!

63

2012 Jan 17 (Epub ahead of print)

Letter to the Editor

Successful bone marrow transplantation for DOCK8 deficient hyper IgE syndrome

J All Clin Immunol 2010;126:1304

ORIGINAL ARTICLE

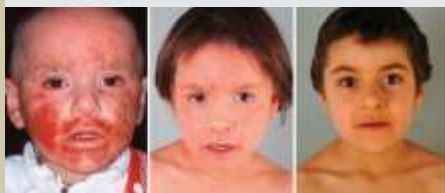Curative treatment of autosomal-recessive hyper-IgE syndrome by hematopoietic cell transplantation

Stöckel C, Hübner M, Kretschmer M, et al.

64

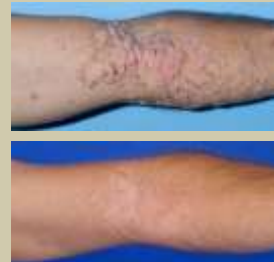Successful Long-Term Correction of Autosomal Recessive Hyper-IgE Syndrome due to DOCK8 Deficiency by Hematopoietic Stem Cell Transplantation

Erfolgreiche hämatopoetische Stammzelltransplantation bei autosomal rezessivem Hyper-IgE-Syndrom mit DOCK8-Defizienz



65

DOCK8 combined immunodeficiency: 20 yo extensive HPV pre/post HSCT



66

Final case

- Not *every* rash after bone marrow transplant is graft-versus-host disease

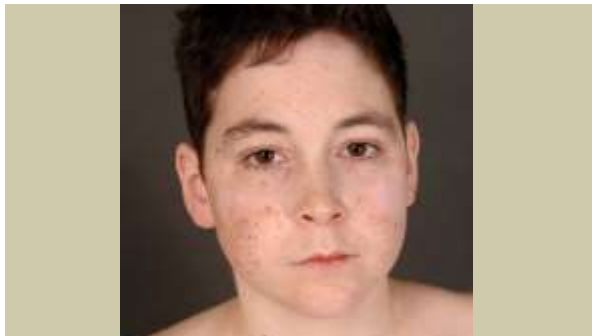67

15 year old boy

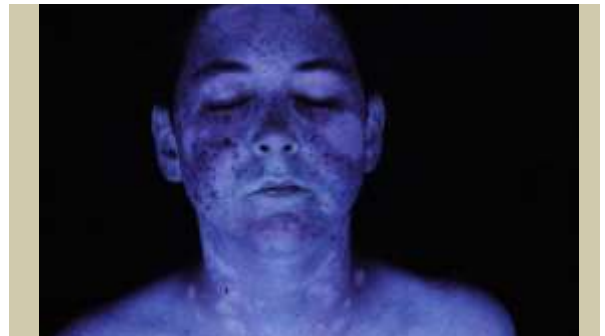- Age 6:
 - Metastatic rhabdomyosarcoma
- Age 12: nonmyeloablative PBSCT
 - Day 8: acute skin GVHD
 - Day 100: lichen planus-like cGVHD
 - 20 months: vitiligo-like depigmentation



68



69




70



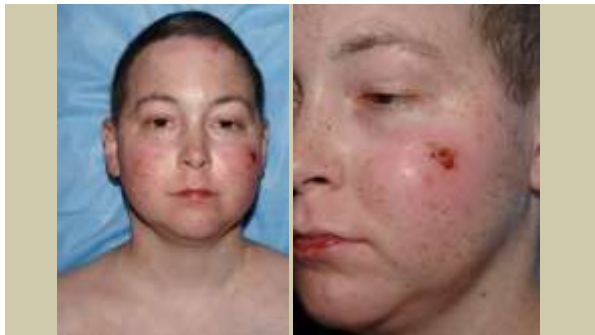71

New rash

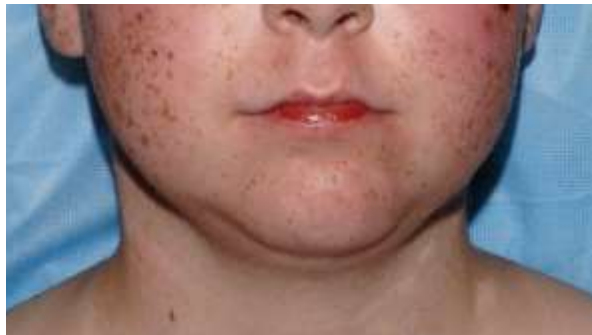- Age 6: metastatic alveolar rhabdomyosarcoma
- Age 12: nonmyeloablative PBSCT
 - Day 8: acute skin GVHD
 - Day 100: lichen planus-like cGVHD
 - 20 months: vitiligo-like depigmentation
 - 34 months: intense erythema of forehead, malar cheeks, upper extremities and feet
 - Returns to NIH for presumed flare of cGVHD



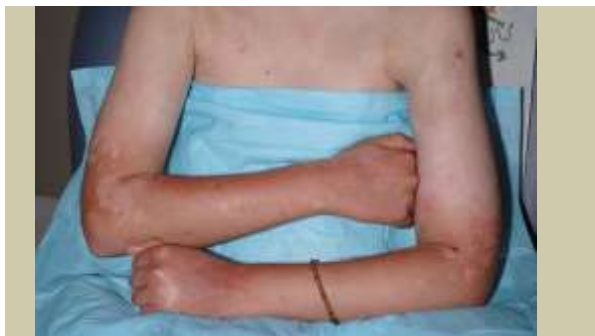72



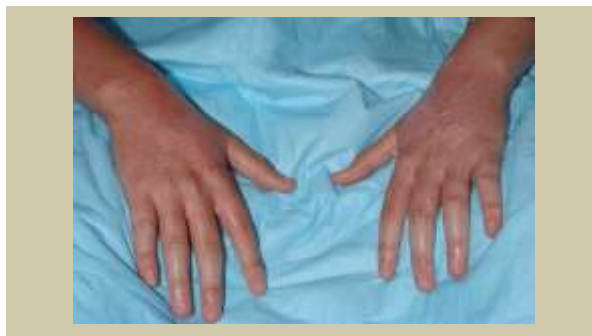73



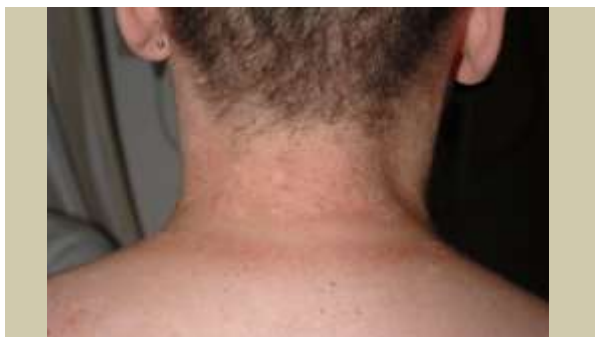74



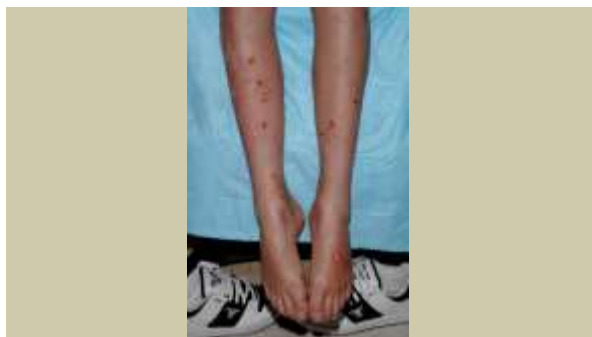75



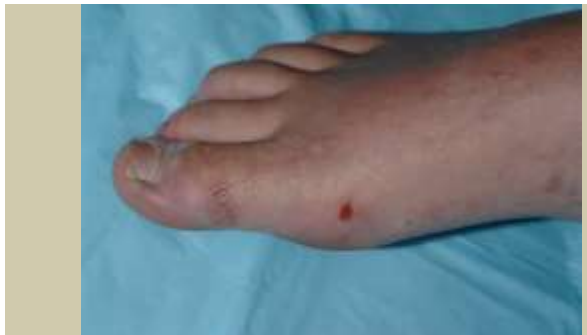76



77



78



79

GvHD
Graft-versus-host disease

Diagnostic dermatologic criteria

- Poikiloderma
- Lichen planus-like features
- Lichen sclerosus-like features
- Morphea-like sclerosis
- Scleroderma-like sclerosis
- Eosinophilic fasciitis-like features

Distinctive dermatologic criteria

- Depigmentation
- Scaling, papulosquamous scalp lesions
- New onset scarring or non-scarring scalp alopecia
- Nail dystrophy
 - Longitudinal ridging, splitting, brittleness
 - Onycholysis
 - Pterygium unguis
 - Anonychia

Filpovich et al. Biol Blood Marrow Transplant 2005;11:945-56;
Jagasia et al. Biol Blood Marrow Transplant 2015;21:389-401.

80

Voriconazole-induced phototoxicity

- Voriconazole 200mg QD two weeks prior to onset for presumed pulmonary aspergilliosis

- Dx: phototoxicity/pseudoporphyria cutanea tarda
- Tx: voriconazole replaced with posaconazole
 - Strict photoprotection instituted
 - F/u 3 weeks later: resolution of bulle/erythema improved

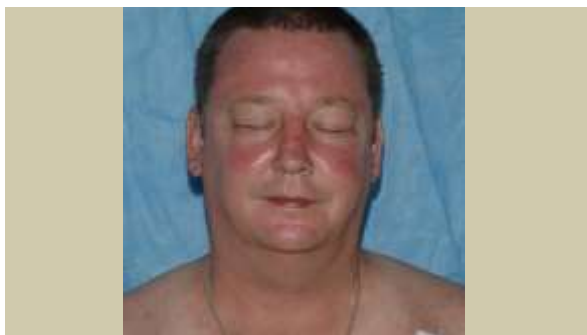81

Voriconazole

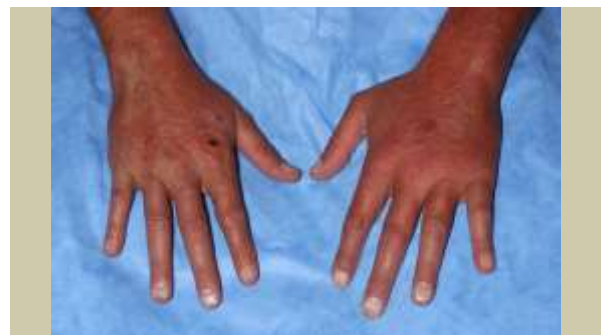- 2nd generation oral triazole
- FDA approval 2001
 - Invasive aspergillosis
 - Candidemia, esophageal and disseminated candidiasis
- Side effect profile
 - Vision changes (20%); hallucinations (15%)
 - “Skin reactions” (attributable to drug: 7%)
 - Photosensitive rash (2%) → 30% (personal experience)

http://www.fda.gov/cder/rdmt/infos/01/briefing/379262_01_P1a1a.pdf

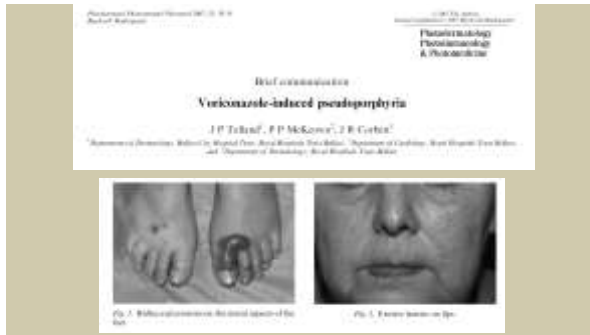
82



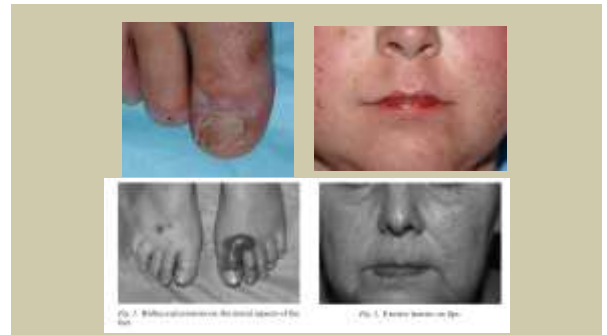83




84



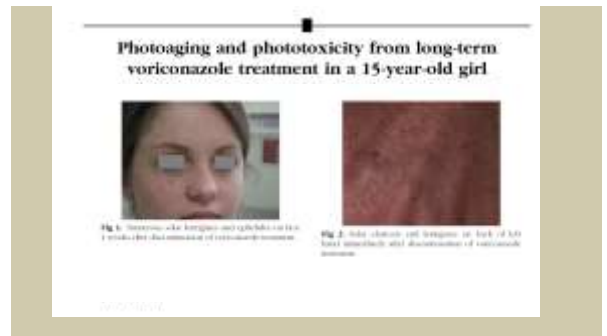85



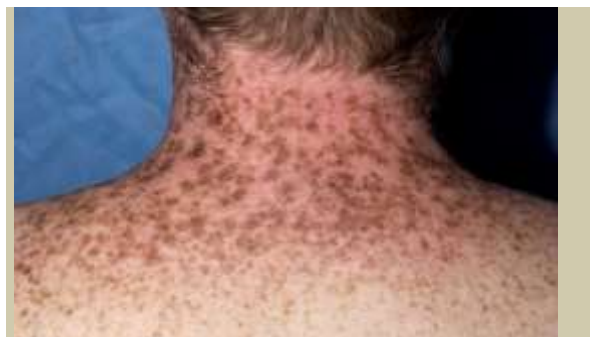86



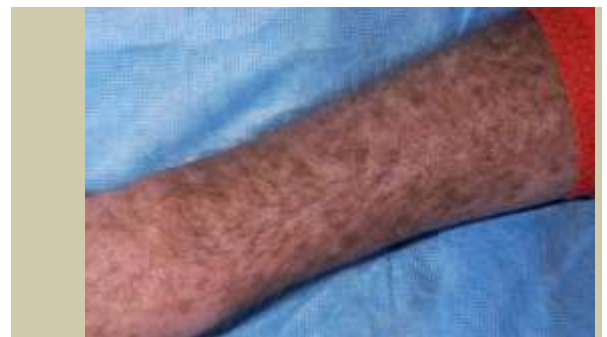87



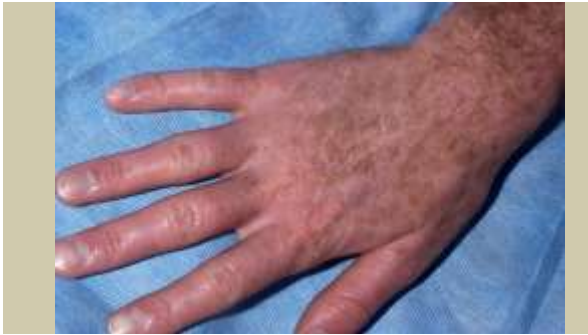88



89



90



91

Voriconazole phototoxicity/photoaging in an AA-male with coccidiomycosis

Ekaum DJ, Cowen EW. Arch Dermatol. 2012;148(6):565-6.

92

What is the true incidence of voriconazole-induced phototoxicity?

- Product labeling not generalizable to current Tx population
- Phototoxicity requires **both** drug and UV exposure
 - FDA trial data: critically ill inpts → limited outdoor exposure
 - NIH population: ambulatory outpt. population with chronic immunodeficiency (CGD, Job syndrome, cGVHD)
- The incidence of voriconazole-associated phototoxicity in the **ambulatory** (UV-exposed) population likely higher than described in product label

93

Voriconazole-associated phototoxicity/SCC

22 yo HIV+ pt. with Bowens disease (SCC *in situ*) on chronic voriconazole

94

9 yo with cGVHD with 2 SCC on chronic voriconazole

95

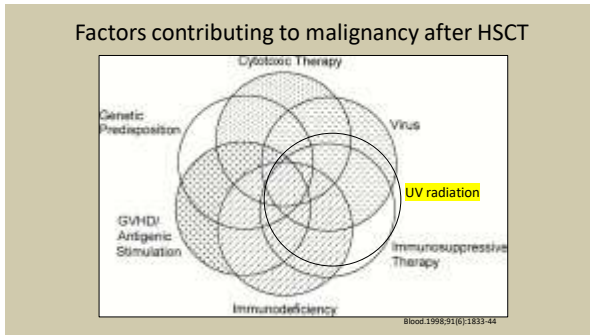
Voriconazole and SCC

- 51 SCC/8 immunocompromised pts with chronic voriconazole-associated phototoxicity (age 9-54 yrs)
- Duration of immunosuppression
 - Median 51 mos (range 13-122 mos)
- Duration of voriconazole Tx
 - Median 46.5 mos (range 13-60 mos)
- “High-risk” immunocompr. population
 - Correlation vs. causation

Metastatic SCC on chronic voriconazole

J Am Acad Dermatol 2010;62:31-7.

96



97

ORIGINAL CLINICAL STUDY | J Heart Lung Transplant.2019;28:1240-4.

Varicellazola exposure and geographic location are independent risk factors for squamous cell carcinoma of the skin among lung transplant recipients

Andrei Velicer, MD,* N. Hong Nguyen, MD,* Doreen R. Brown, MD,* Maria Crespo, MD,* Joseph P. Kozicki, MD,* Yoshitaka Toyoda, MD, PhD,* Christiana Sarmiento, MD,* Eric S. Koenig, MD,* Fernando P. Siqueira, MD,* and Timothy J. Clancy, MD*

From the Department of Medicine and *Oncological Surgery, University of Pittsburgh Medical Center, and the Department of Medicine, Pittsburgh VA Healthcare System, Pittsburgh, Pennsylvania.

- Retrospective case-control study (2003-08)
 - SCC 3.1% (17/543)
 - Median f/u: 36 mo; median time to SCC: 19.1 months
 - 94% sun exposed surfaces
- Multivariate analysis
 - Duration of voriconazole: HR 2.1 (p = 0.04)
 - High sun exposure residence: HR 3.8 (p = 0.0004)

98

Research | 2020;156(7):772-779.

Variconazole and the Risk of Keratinocyte Carcinomas Among Lung Transplant Recipients in the United States

Michael F. Chung, PhD, Andrew P. Hoff, PhD, Steven R. Brown, PhD, Eric S. Koenig, MD, PhD, Frederick J. Courtney, PhD, Joseph J. Finkelstein, MD, PhD, Joseph P. Kozicki, MD, PhD, Leonard P. Lerman, MD, PhD, Joseph S. Ross, MD, PhD, and Timothy J. Clancy, MD, MPH

9599 Non-Hispanic white patients (40% exposed to voriconazole); 1031 SCCs

Adjusted hazard ratio risk of SCC:

1-3 months:	1.09 (95% CI, 0.90-1.31)
4-7 months:	1.42 (95% CI, 1.16-1.73)
8-15 months:	2.04 (95% CI, 1.67-2.50)
>15 months:	3.05 (95% CI, 2.37-3.91)

30 day interval: SCC risk increased by 5% (AHR, 1.05; 95% CI, 1.04-1.06)

99

VFEND® IV, (voriconazole) for Injection

VFEND® Tablets (voriconazole)

VFEND® (voriconazole) for Oral Suspension

Dermatological Adverse Events:
Patients have rarely developed serious cutaneous reactions, such as Stevens-Johnson syndrome, during treatment with VFEND. If a patient develops an exfoliative cutaneous reaction, VFEND should be discontinued.

Phototoxicity:
In addition, VFEND has been associated with photosensitivity skin reactions. Patients should avoid excessive or prolonged exposure to direct sunlight during VFEND treatment. In patients with photosensitivity, skin reactions (erythema and sunburn) of the skin and medication have been reported during long-term therapy. If a patient develops a skin lesion consistent with squamous cell carcinoma or melanoma, VFEND should be discontinued.

100

- ### Take home points
- **HLRCC** → Aggressive renal cell cancer → surveillance
 - **GATA2 syndrome** → lymphedema, HPV, MDS/AML → HSCT
 - **HyperIgE syndromes** → eczema, abscesses
 - Job S → hyperextensibility, dysmorphism, fractures → Abx
 - DOCK8 → lymphoma, cutaneous viral infection → HSCT
 - **Voriconazole** → phototoxicity, SCC → D/C drug, surveillance

101

Contact information

- www.clinicaltrials.gov
- cowane@mail.nih.gov
- 301-827-2328

A cartoon showing a doctor in a white coat examining a patient. The doctor says, "There, yes, you should be a sign of cancer." The patient looks concerned.

102