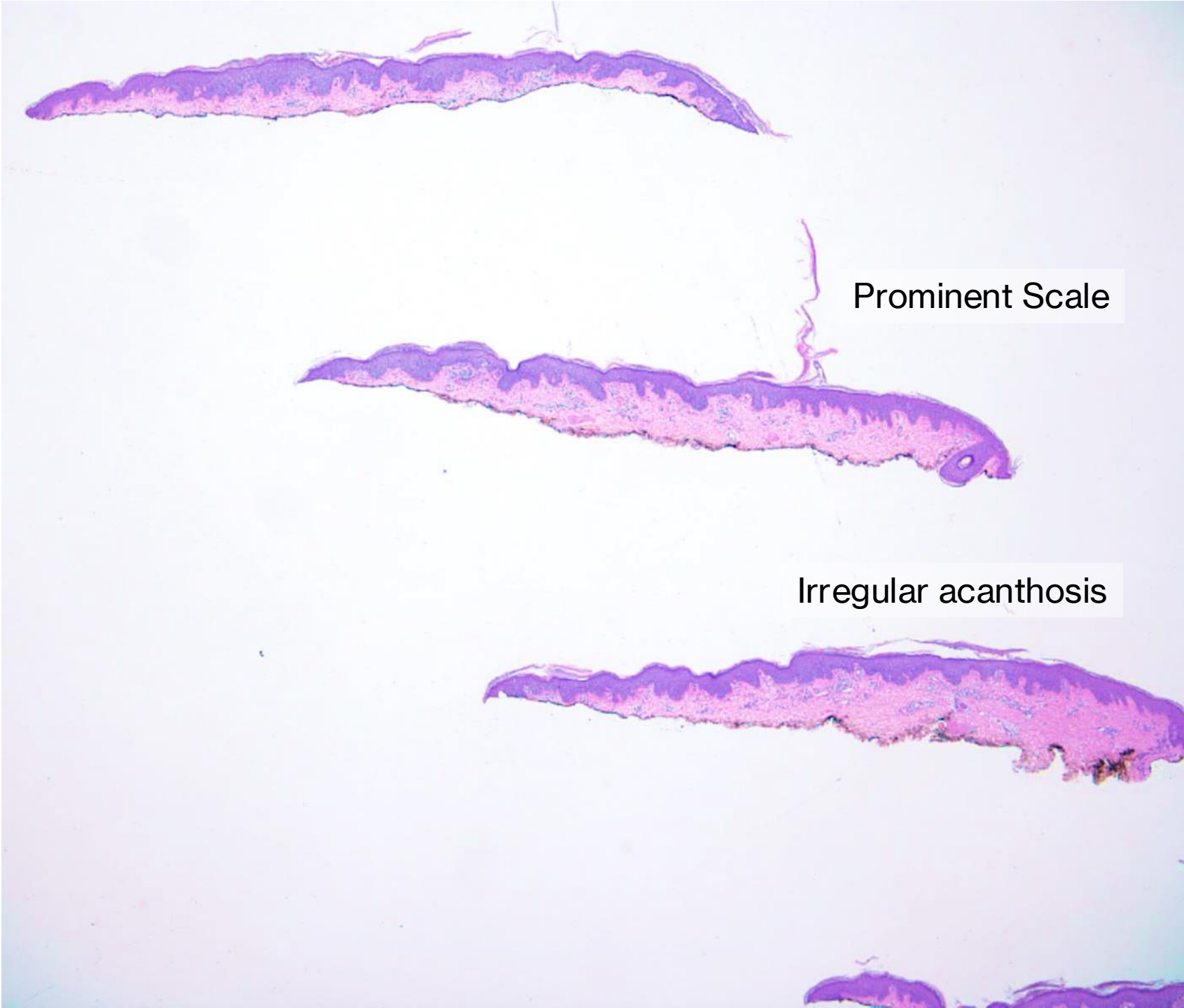


CASES OF PSORIASIFORM DERMATITIS

Soheil S. Dadras MD-PhD



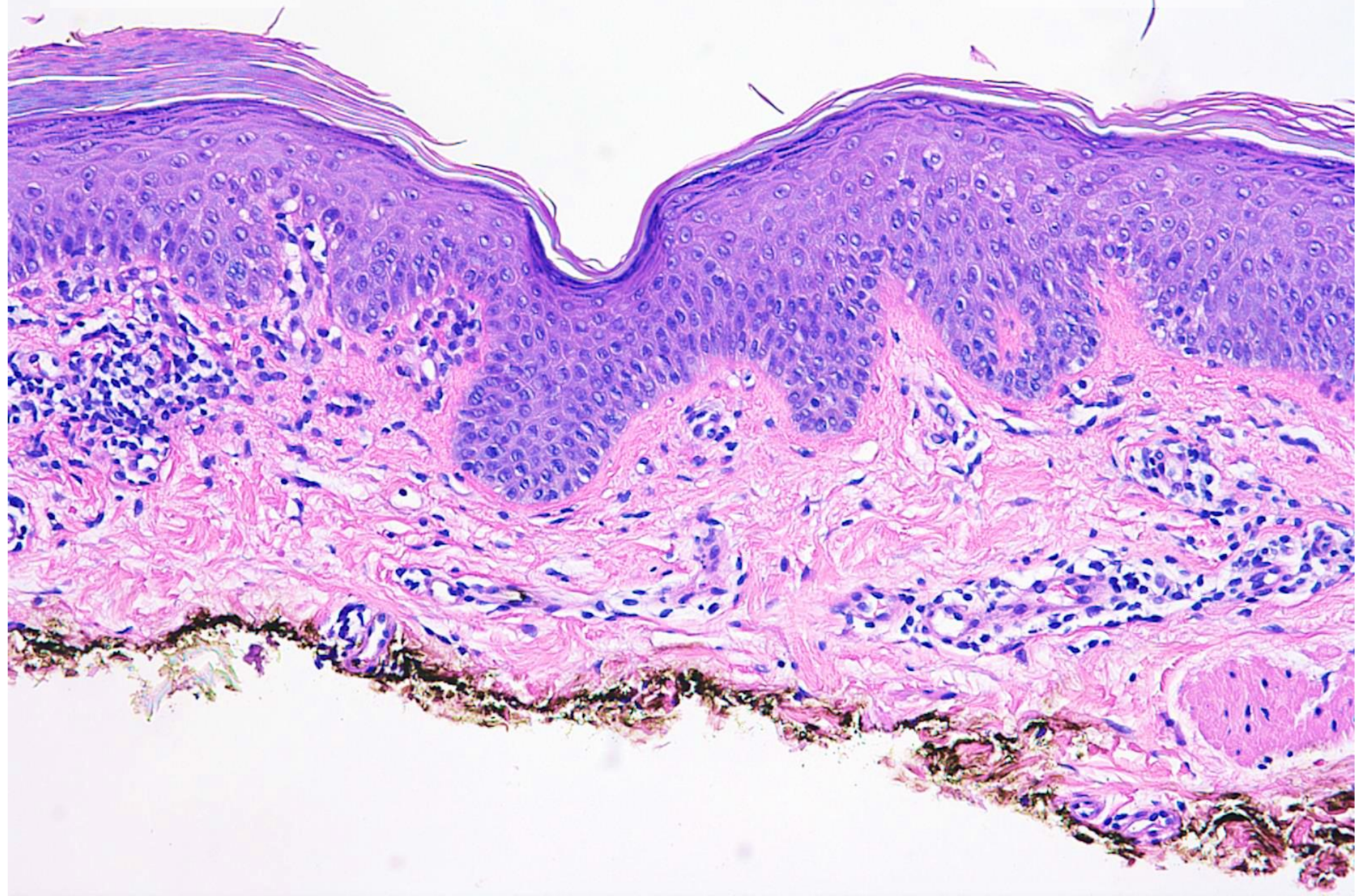


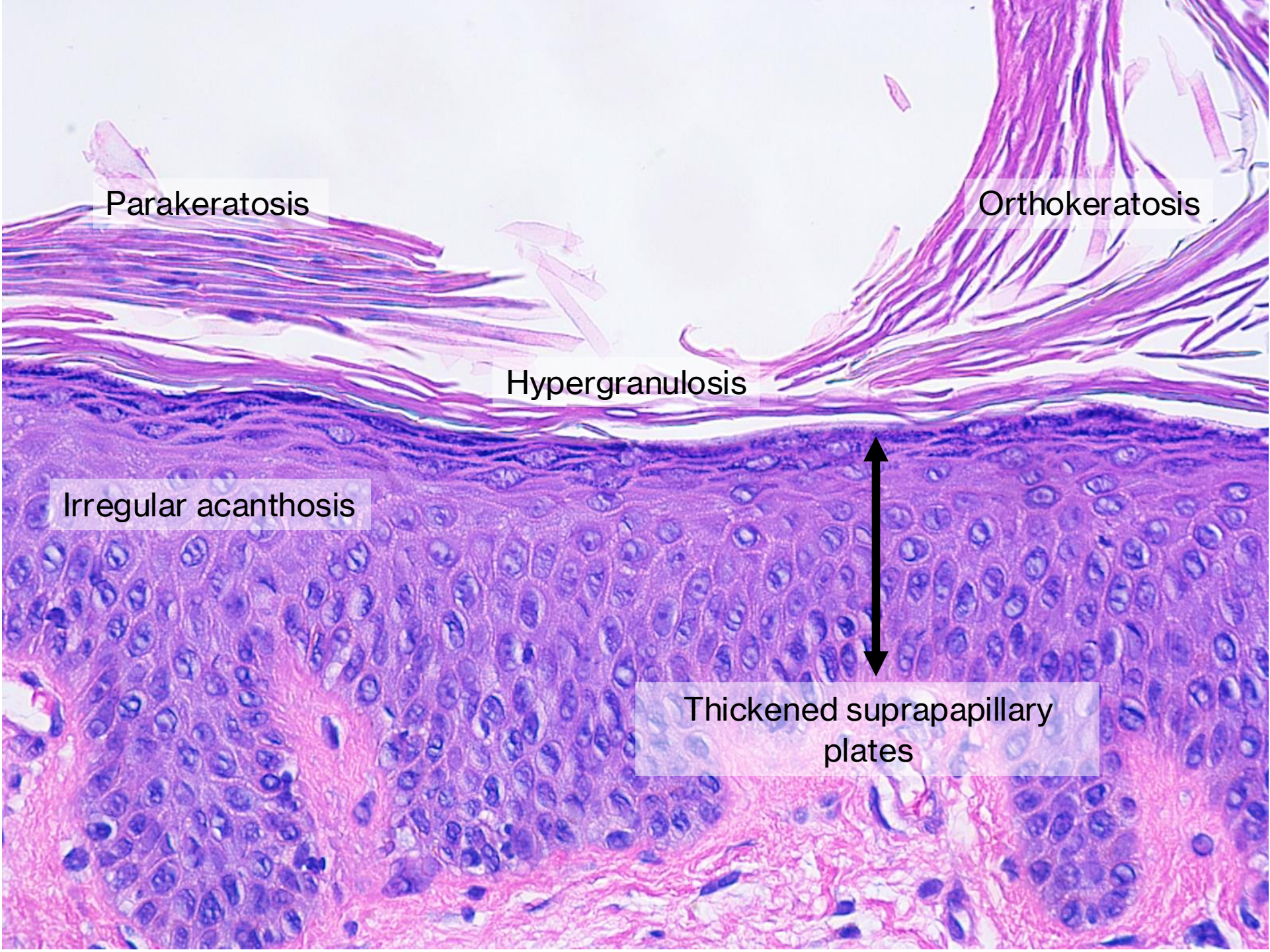
Prominent Scale

Irregular acanthosis

Parakeratosis

Orthokeratosis





Parakeratosis

Orthokeratosis

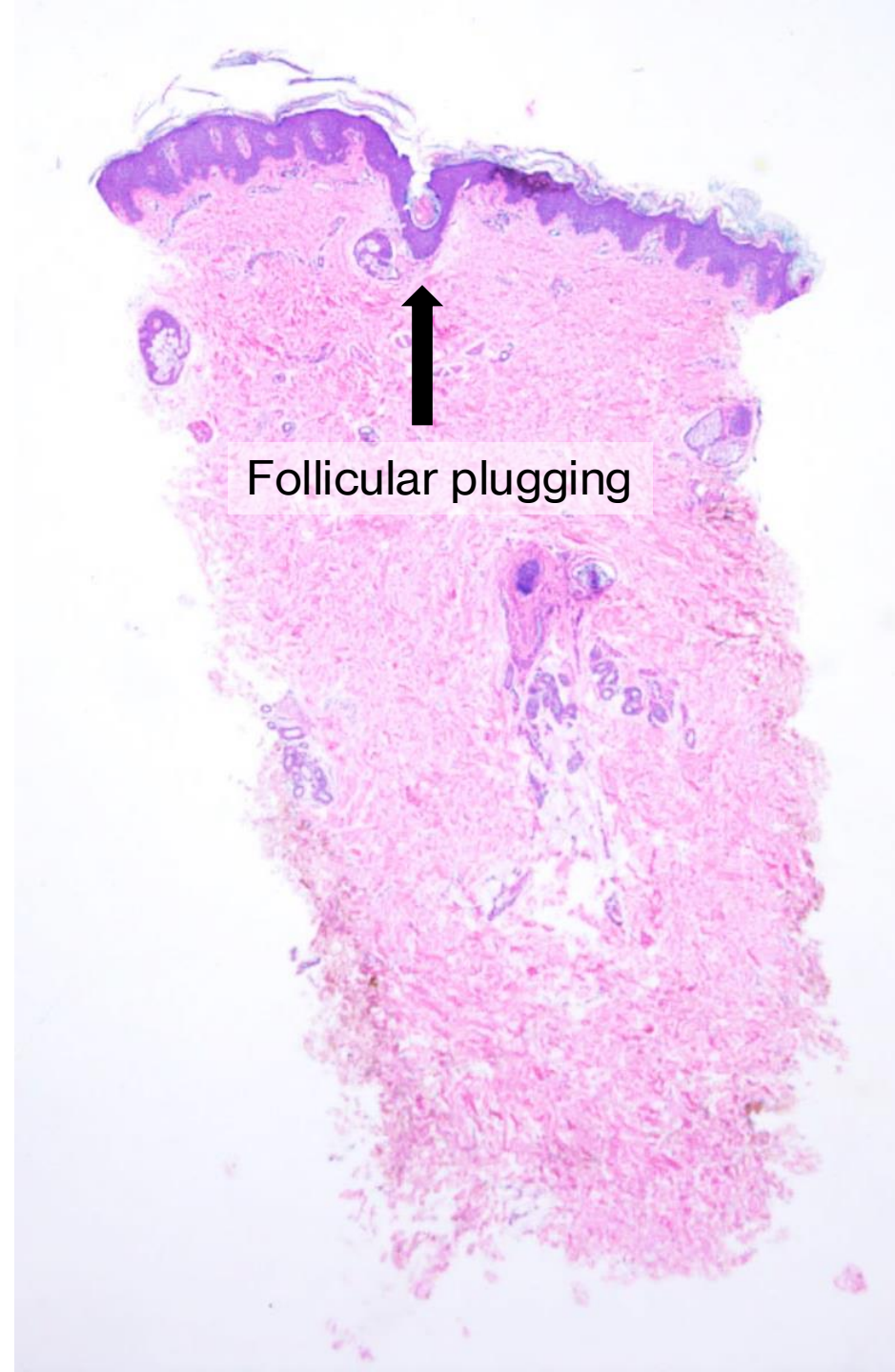
Hypergranulosis

Irregular acanthosis

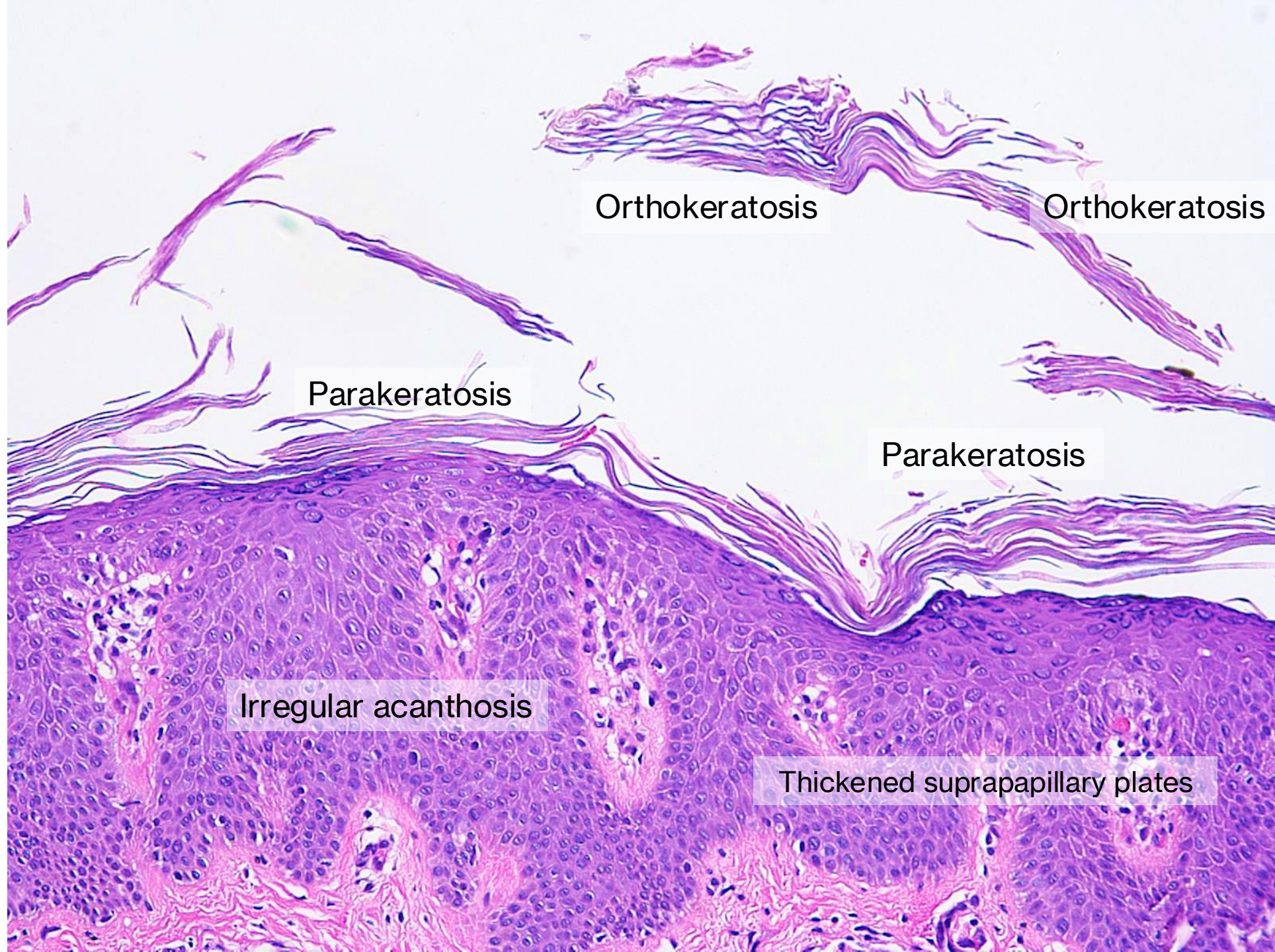
Thickened suprapapillary
plates

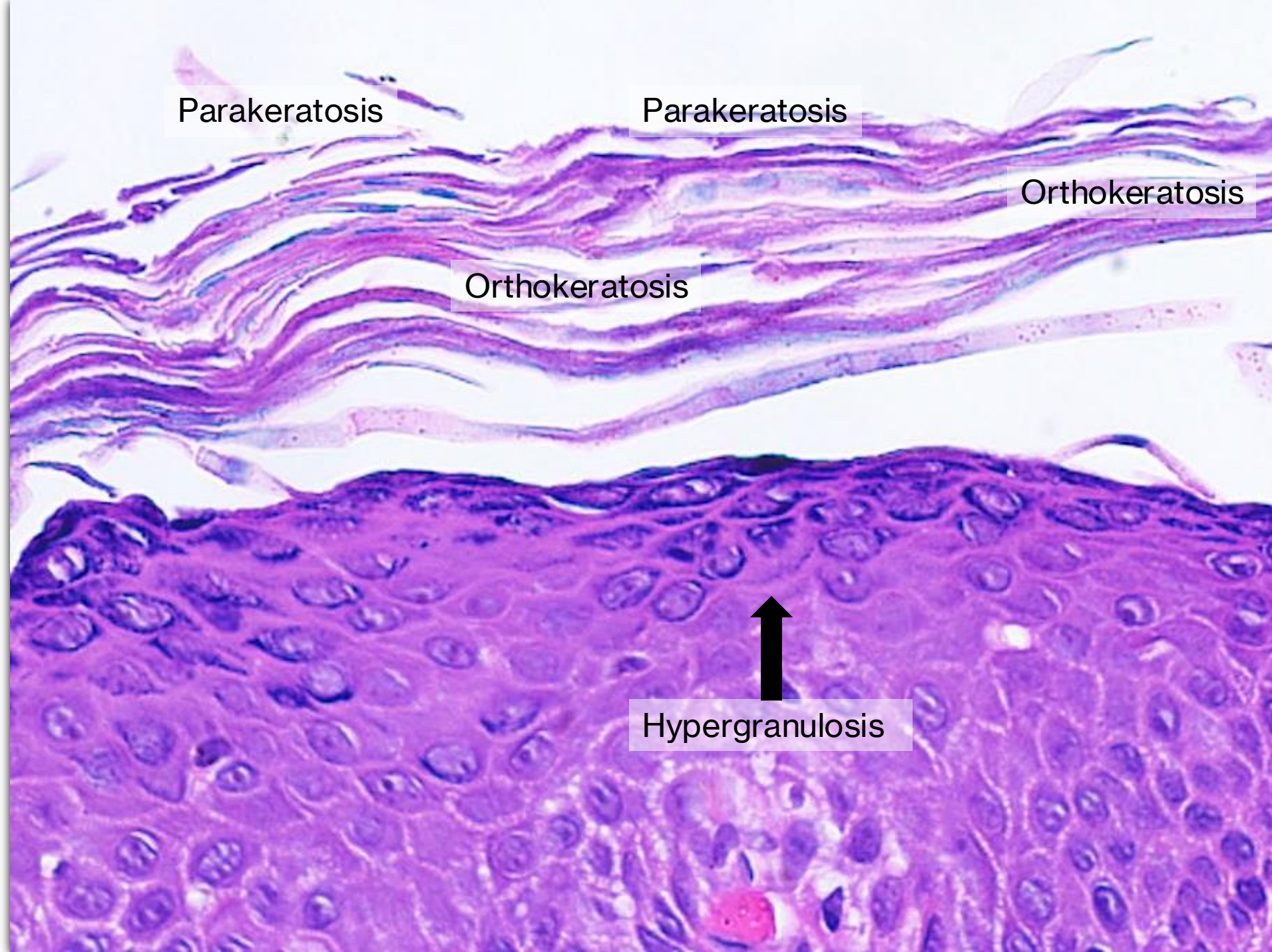
- **Clinical Information:** 49-year-old female, rule out partially treated psoriasis vs. PRP (23-16241).
- **DIAGNOSIS:**
Skin, Left Lower Back, Biopsy:
 - Pityriasis rubra pilaris.
- **Teaching Points:**
 - Look for alternation in orthokeratosis and parakeratosis; order PAS (rule out
- **Minimal Diagnostic Criteria:**
 - Vertical and horizontal foci of orthokeratosis alternate with parakeratosis
 - Parakeratotic mounds at follicular ostia (shoulder parakeratosis)
 - Follicular plugging
 - Rete ridges irregularly elongated and thickened
 - Thickened suprapapillary plates
 - Superficial perivascular lymphocytic information
- **Differential Diagnosis:**

 - Partially-treated psoriasis



Follicular plugging





- **Clinical Information:** 12-year-old male; L30.9; PSORIASIS VS PITYRIASIS ROSEA VS PITYRIASIS RUBRA PILARIS (22-16440).

- **DIAGNOSIS:**

Skin, Chest, Punch Biopsy:

- Psoriasiform epidermal hyperplasia with alternating ortho- and parakeratosis, and follicular plugging.
 - Comment: Overall, the histopathology is in keeping with early pityriasis rubra pilaris. The diagnostic features of psoriasis and pityriasis rosea are absent.

- **Teaching Points:**

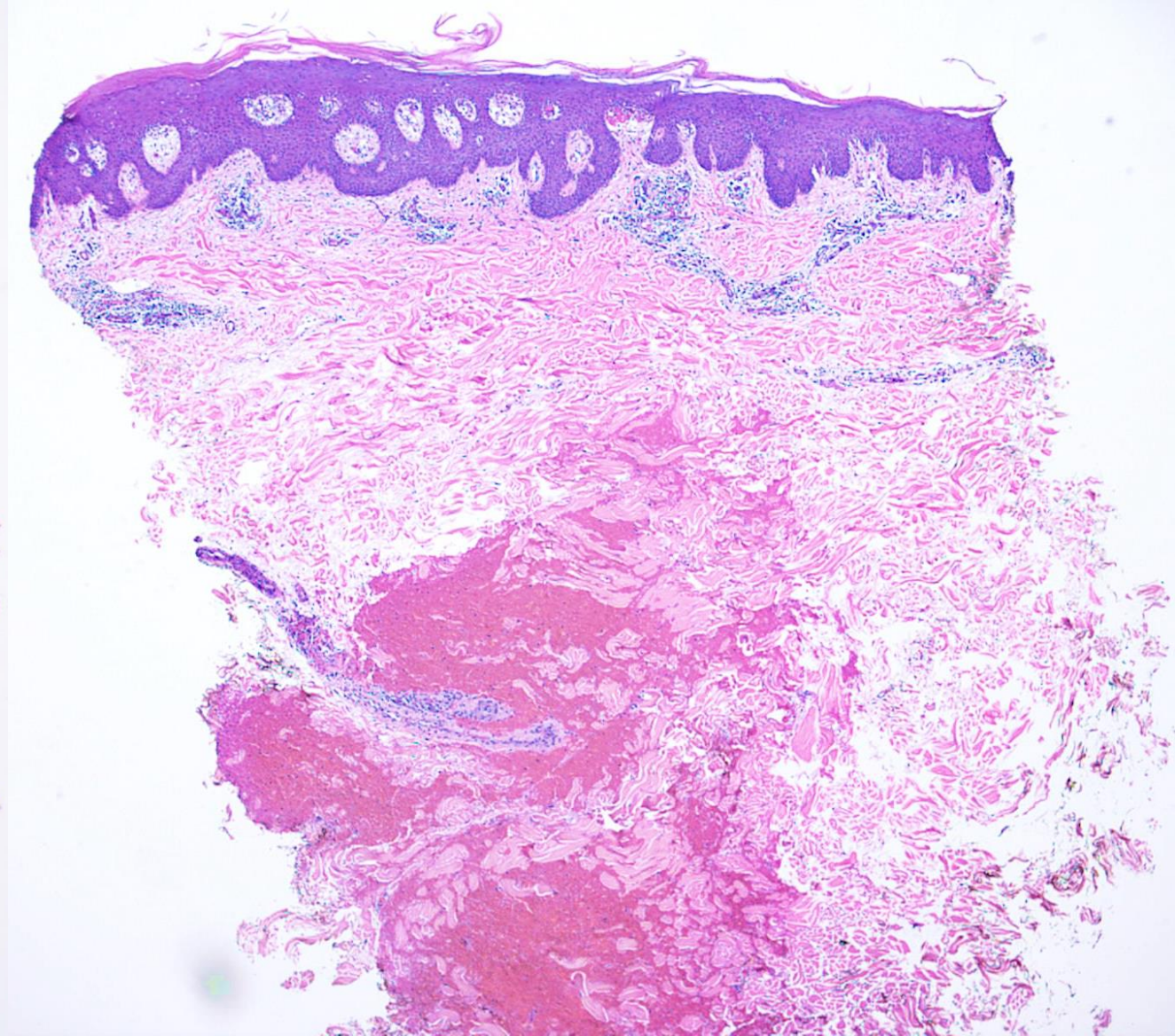
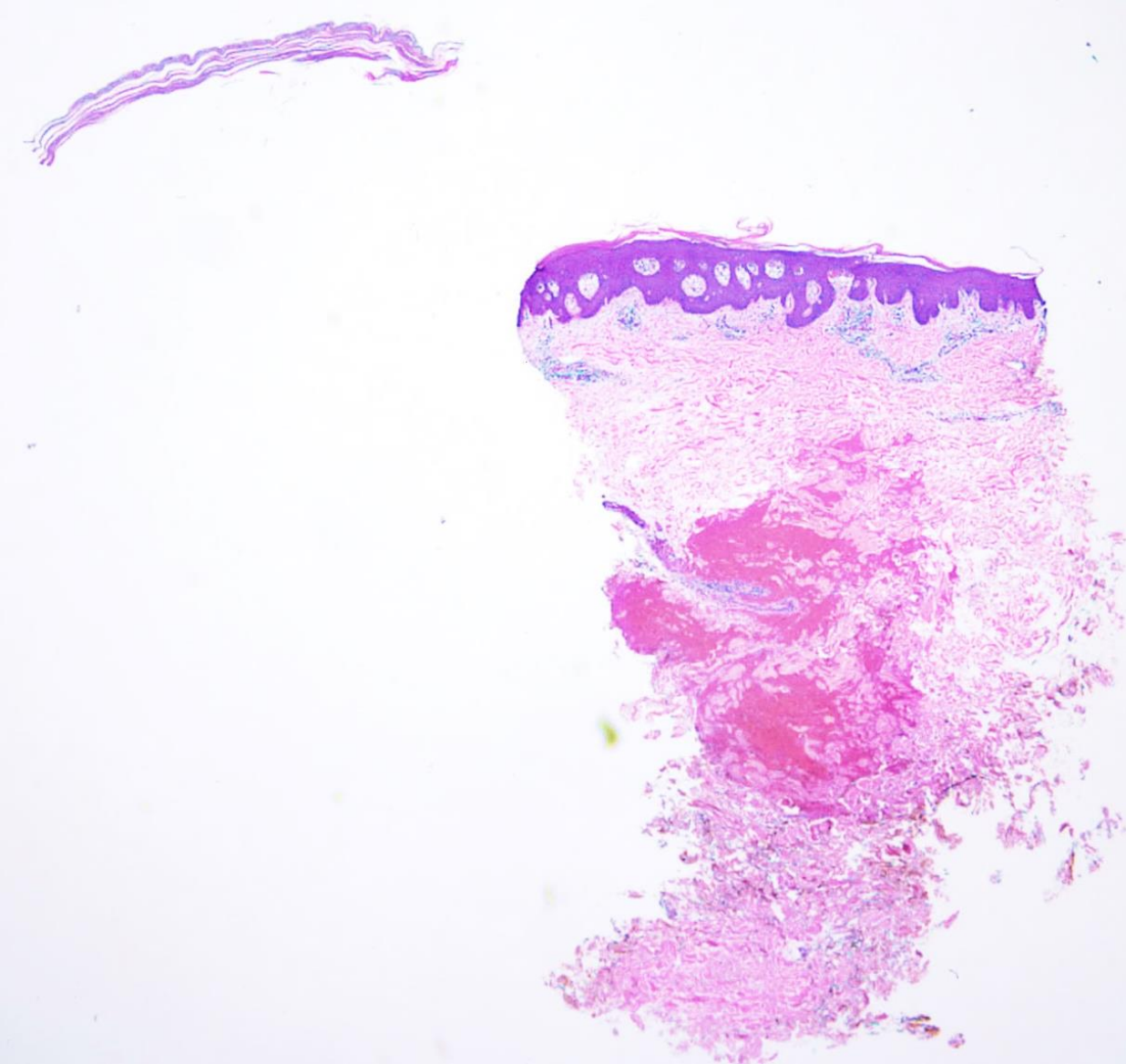
- PAS to exclude Pityriasis versicolor

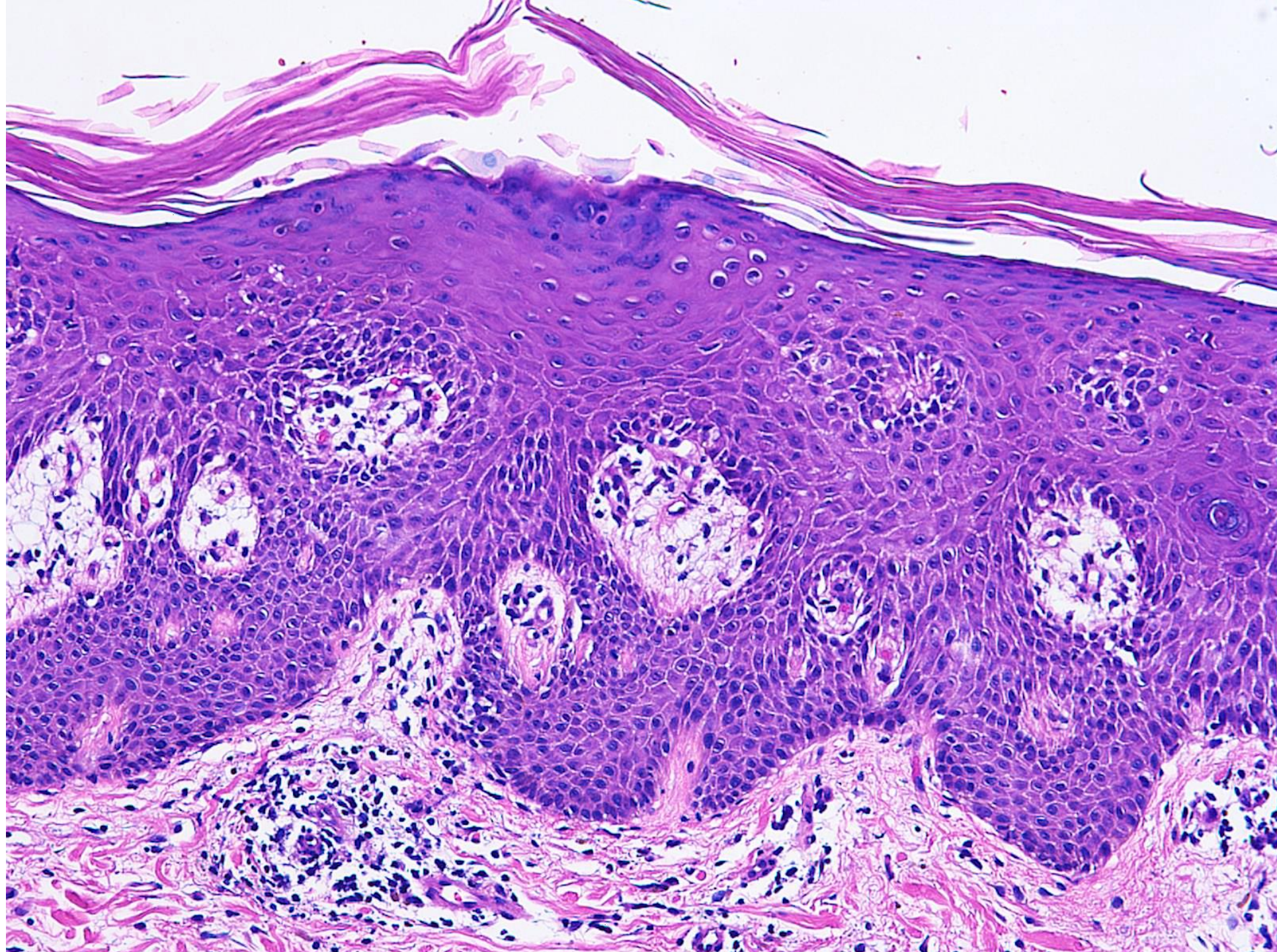
- **Minimal Diagnostic Criteria:**

- Vertical and horizontal foci of orthokeratosis alternate with parakeratosis
- Parakeratotic mounds at follicular ostia (shoulder parakeratosis)
- Follicular plugging
- Rete ridges irregularly elongated and thickened
- Thickened suprapapillary plates

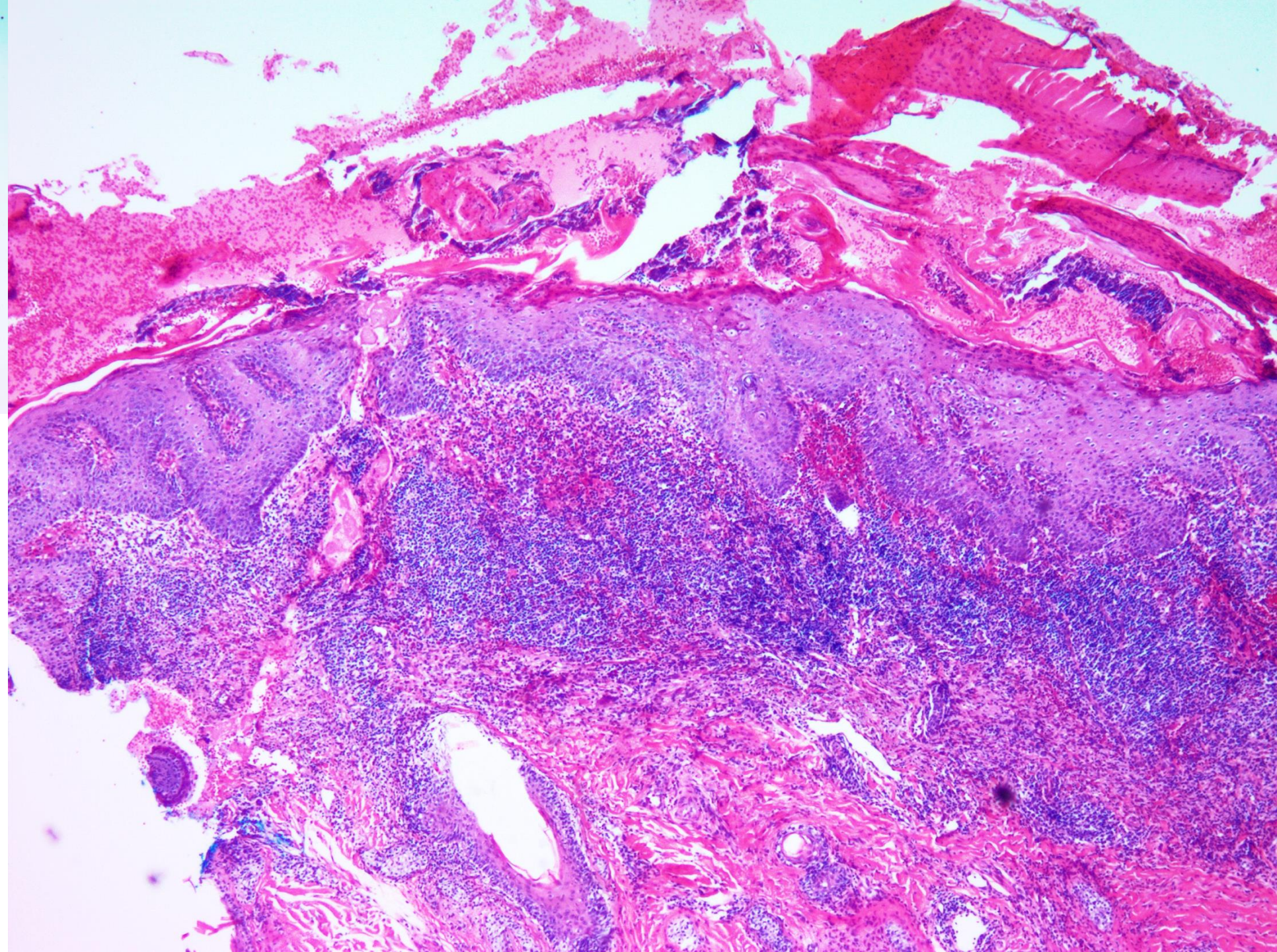
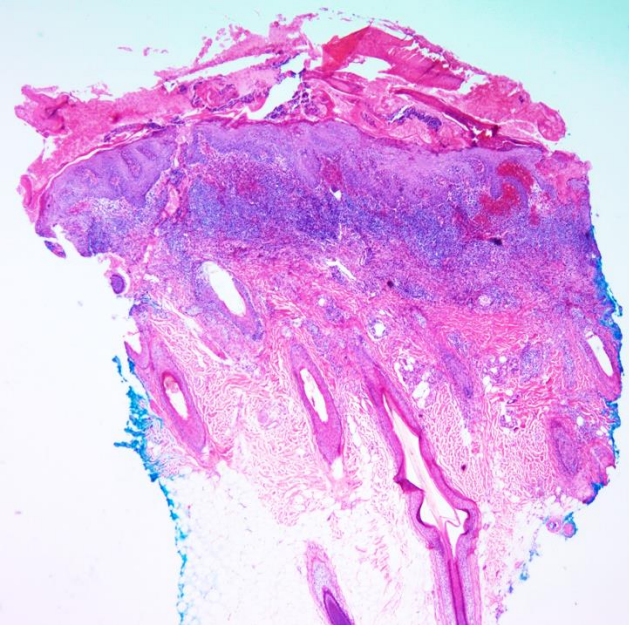
- **Differential Diagnosis:**

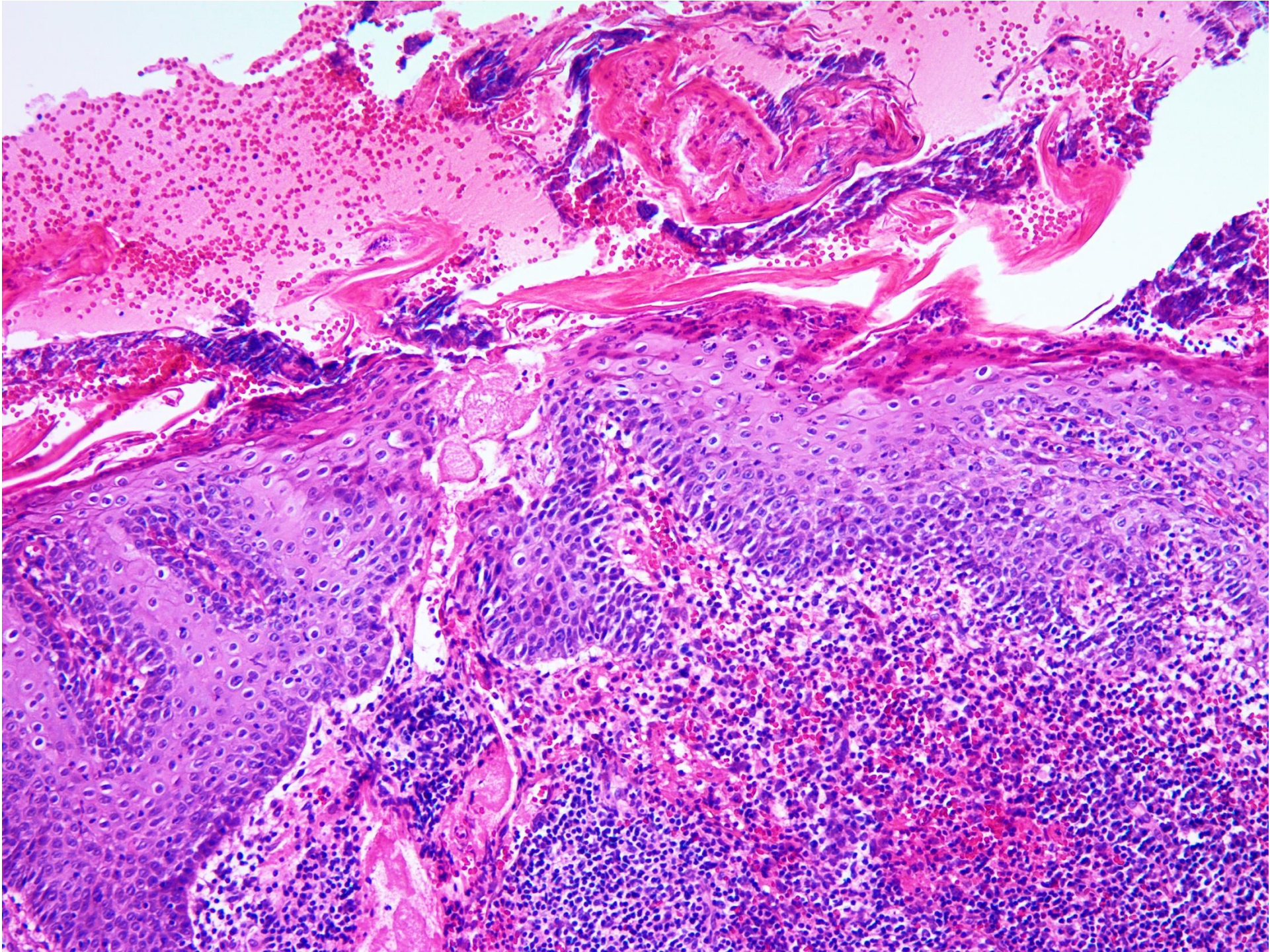
- Pityriasis versicolor
- Pityriasis rosea

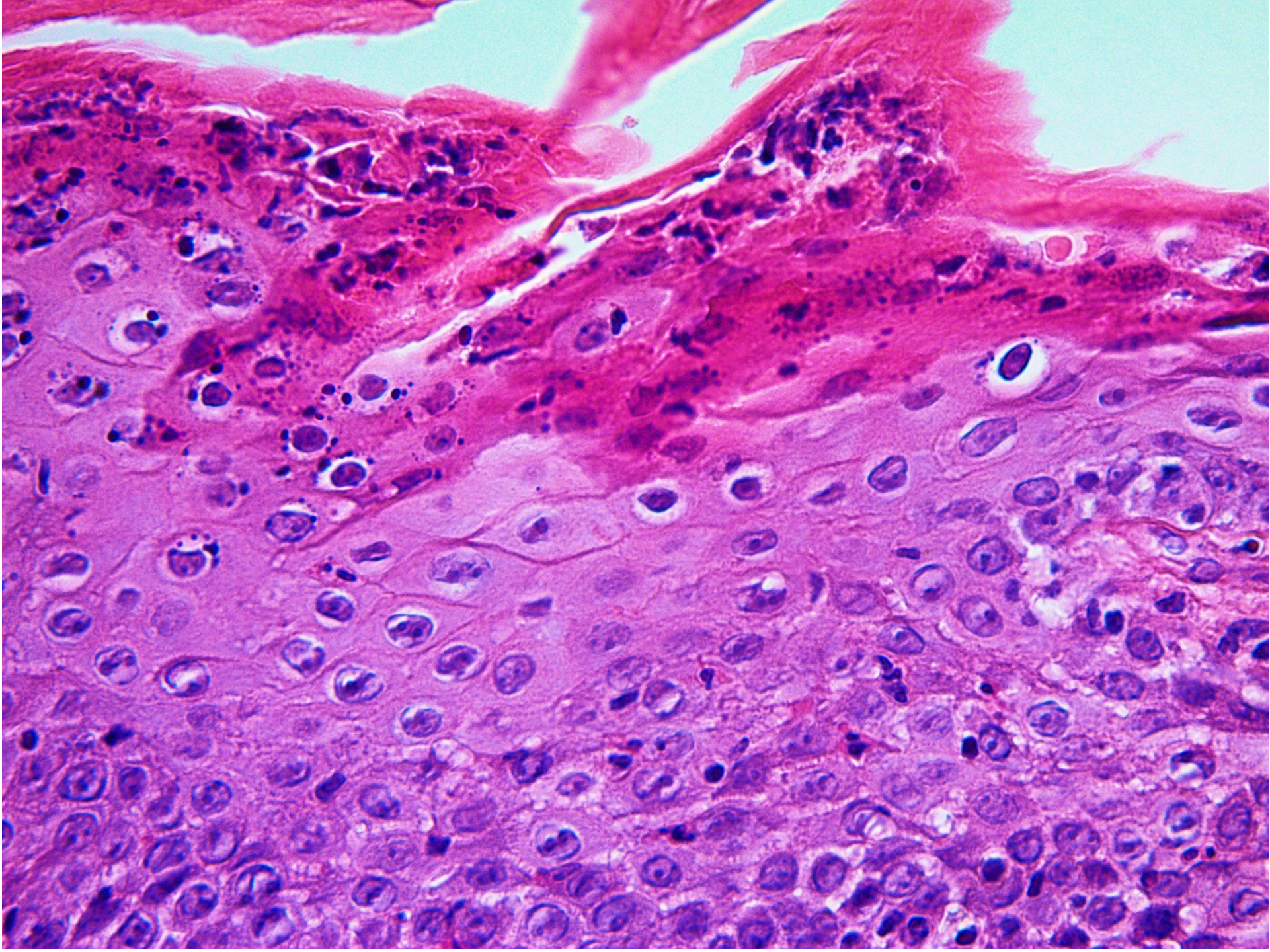




- **Clinical Information:** 47-year-old male; L30.9, R/O INVERSE PSORIASIS VS INTERTRIGO (22-28105).
- **DIAGNOSIS:**
Skin, Right Anterior Hip, Biopsy:
 - Psoriasis.
- **Teaching Points:**
 -
- **Minimal Diagnostic Criteria:**
 - Uniform elongation of rete ridges
 - Hyperkeratosis with confluent parakeratosis
 - Loss of granular cell layer
 - Papillary dermal edema with dilated tortuous capillaries
 - Thinned, suprapapillary plates
 - Neutrophils within the stratum corneum
 - Neutrophils within the spinous layer
 - Superficial perivascular lymphocytic infiltrate
- **Differential Diagnosis:**
 - Chronic spongiotic dermatitis, Superficial cutaneous fungal infections, Secondary syphilis, Reiter syndrome, and Lichen simplex chronicus

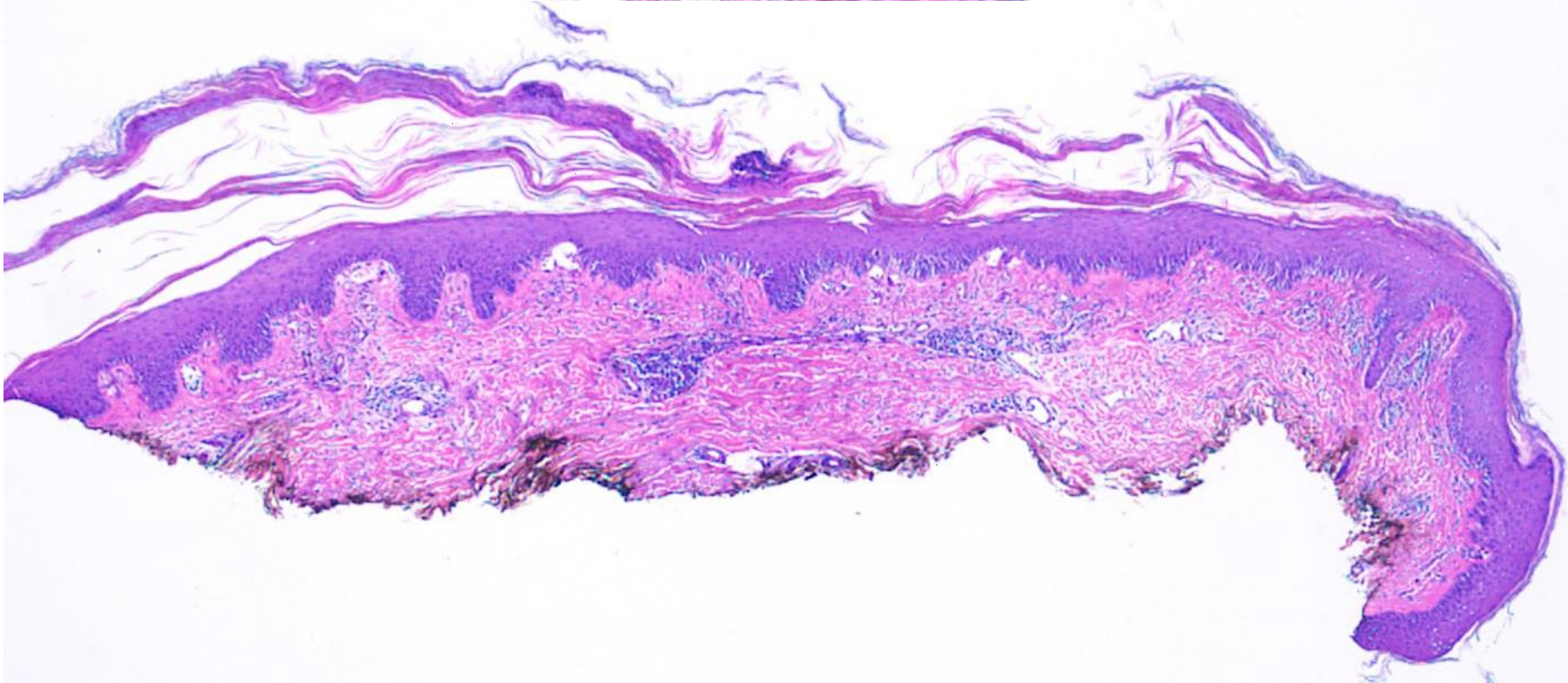
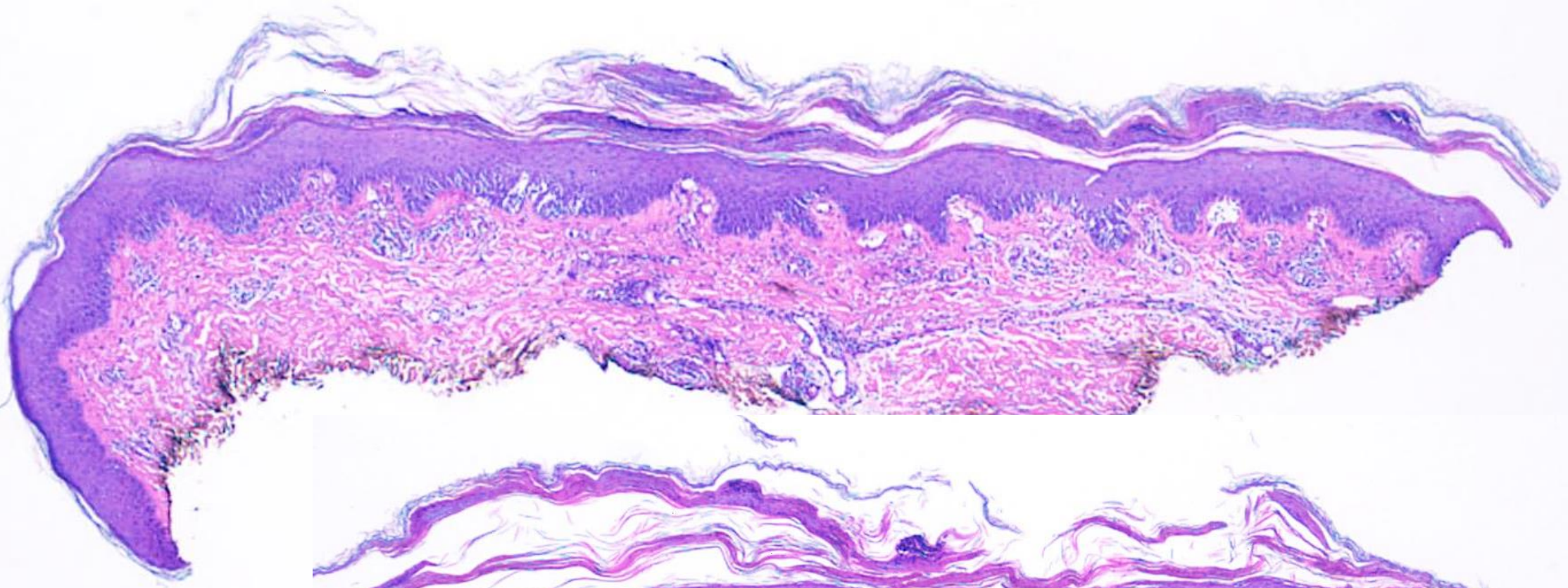


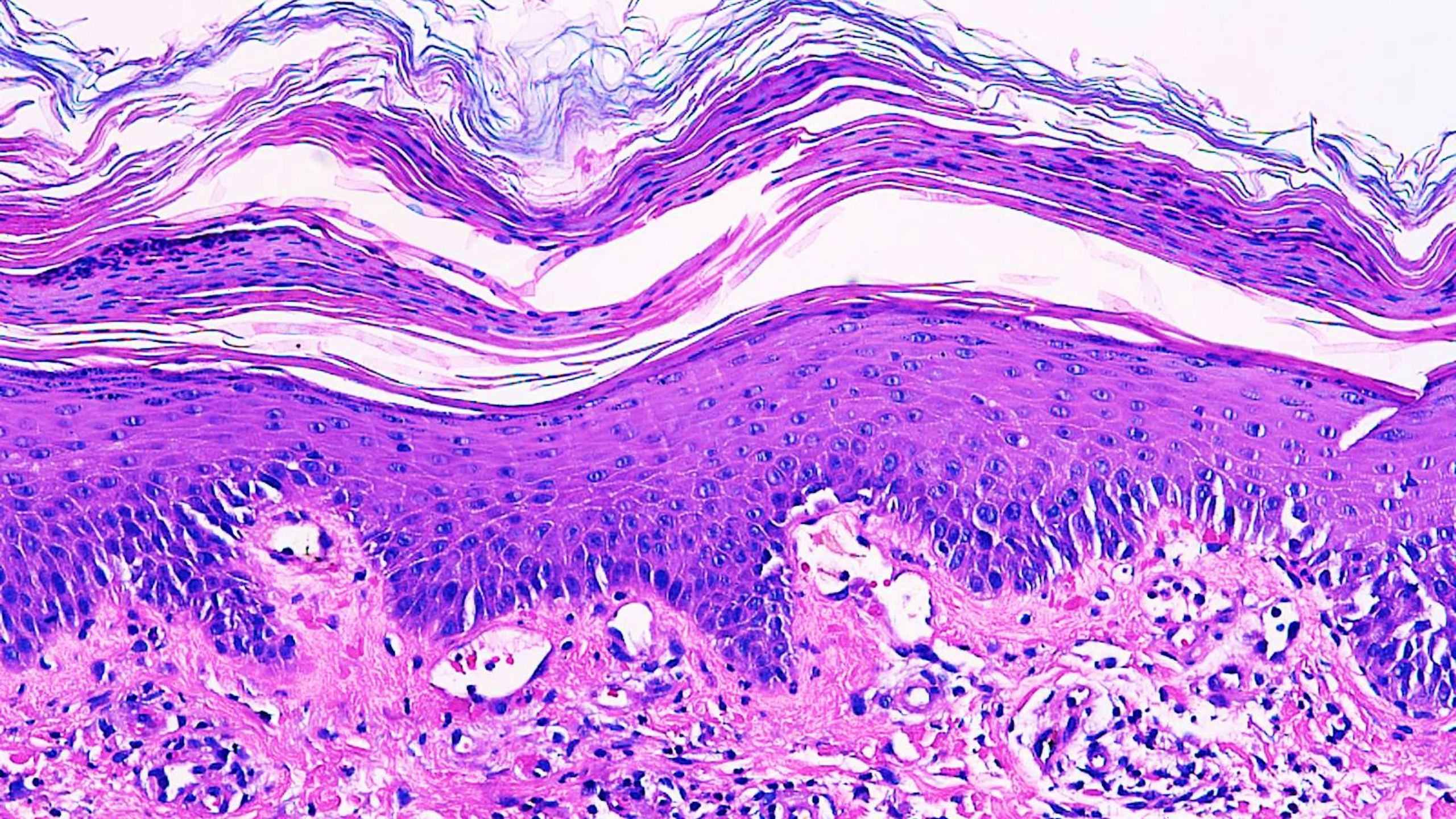


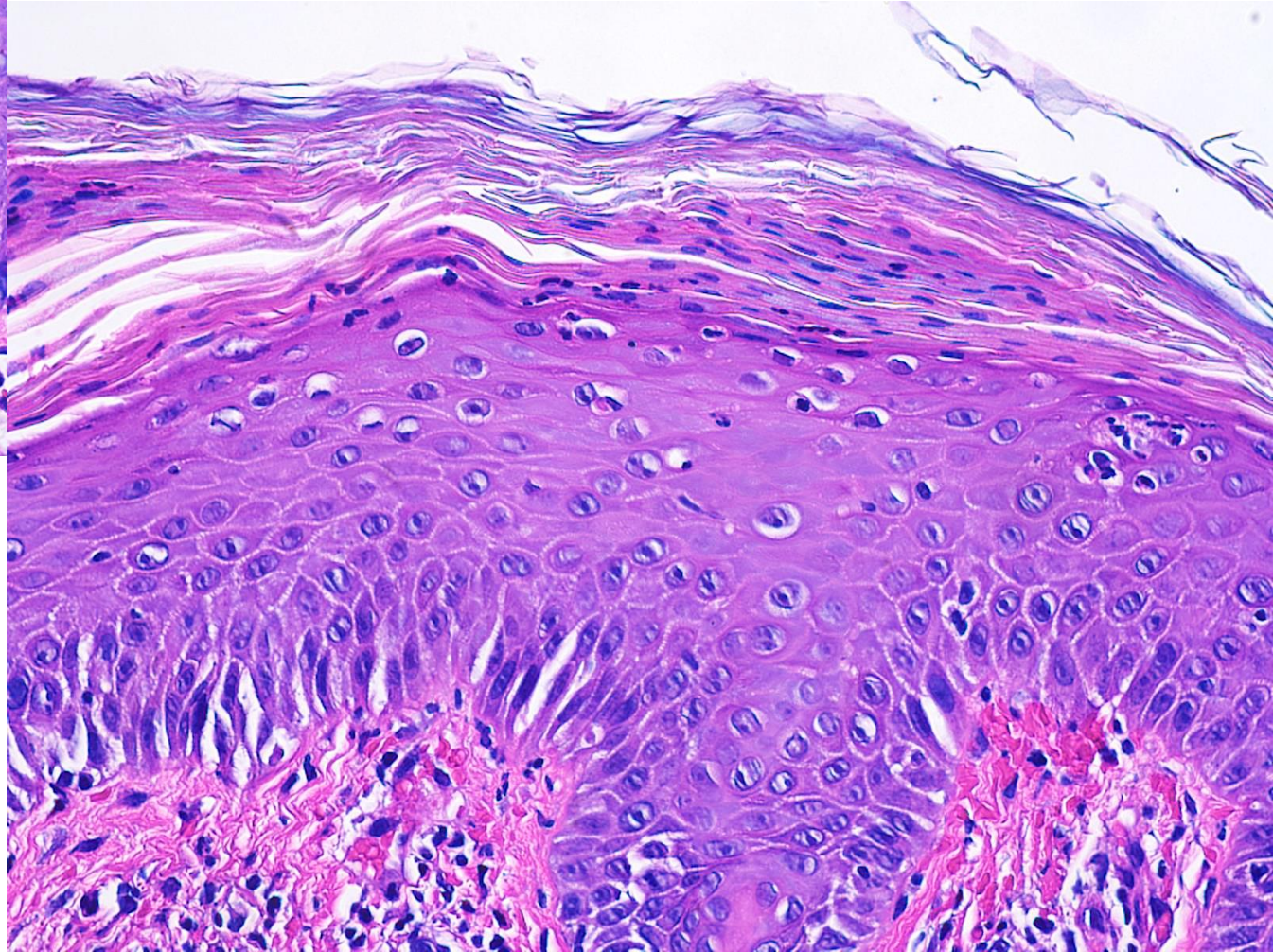
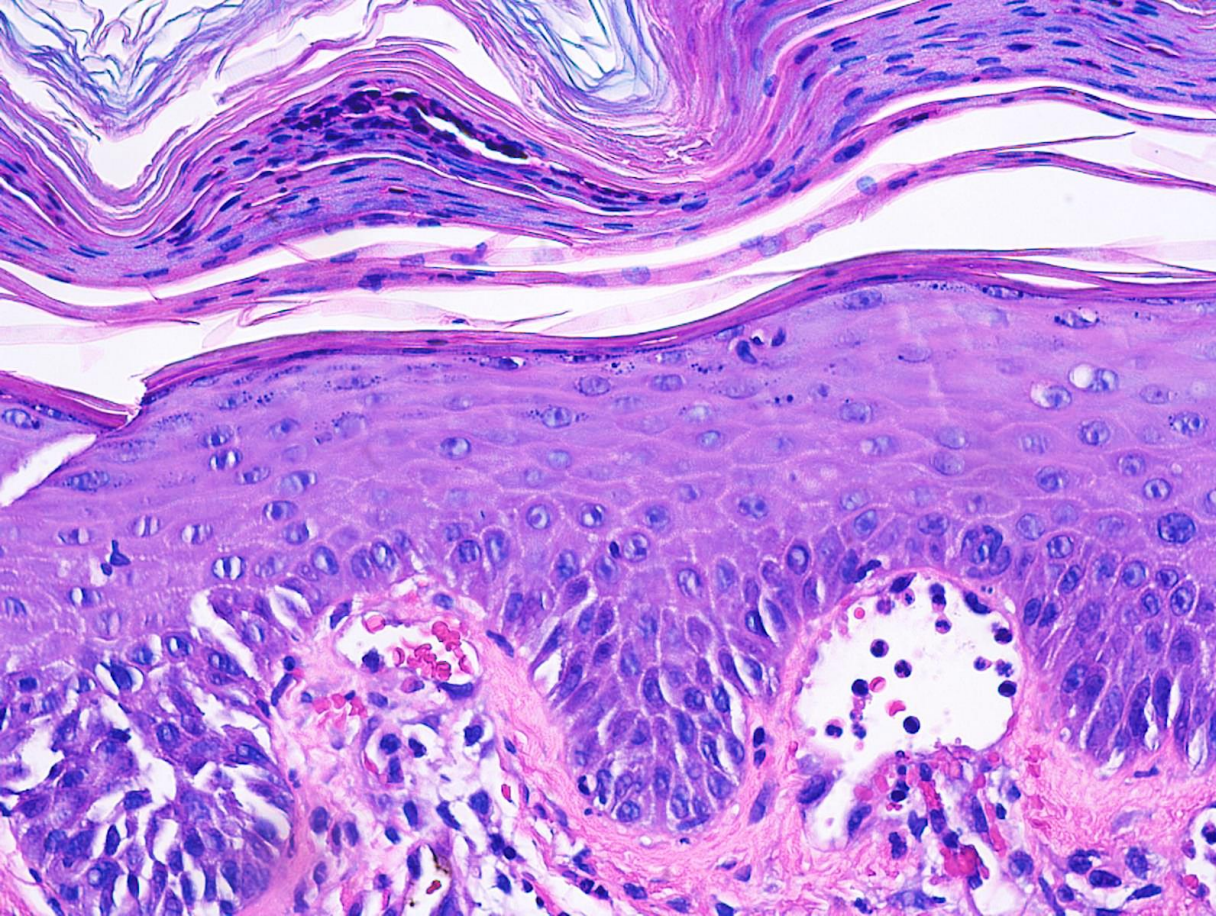


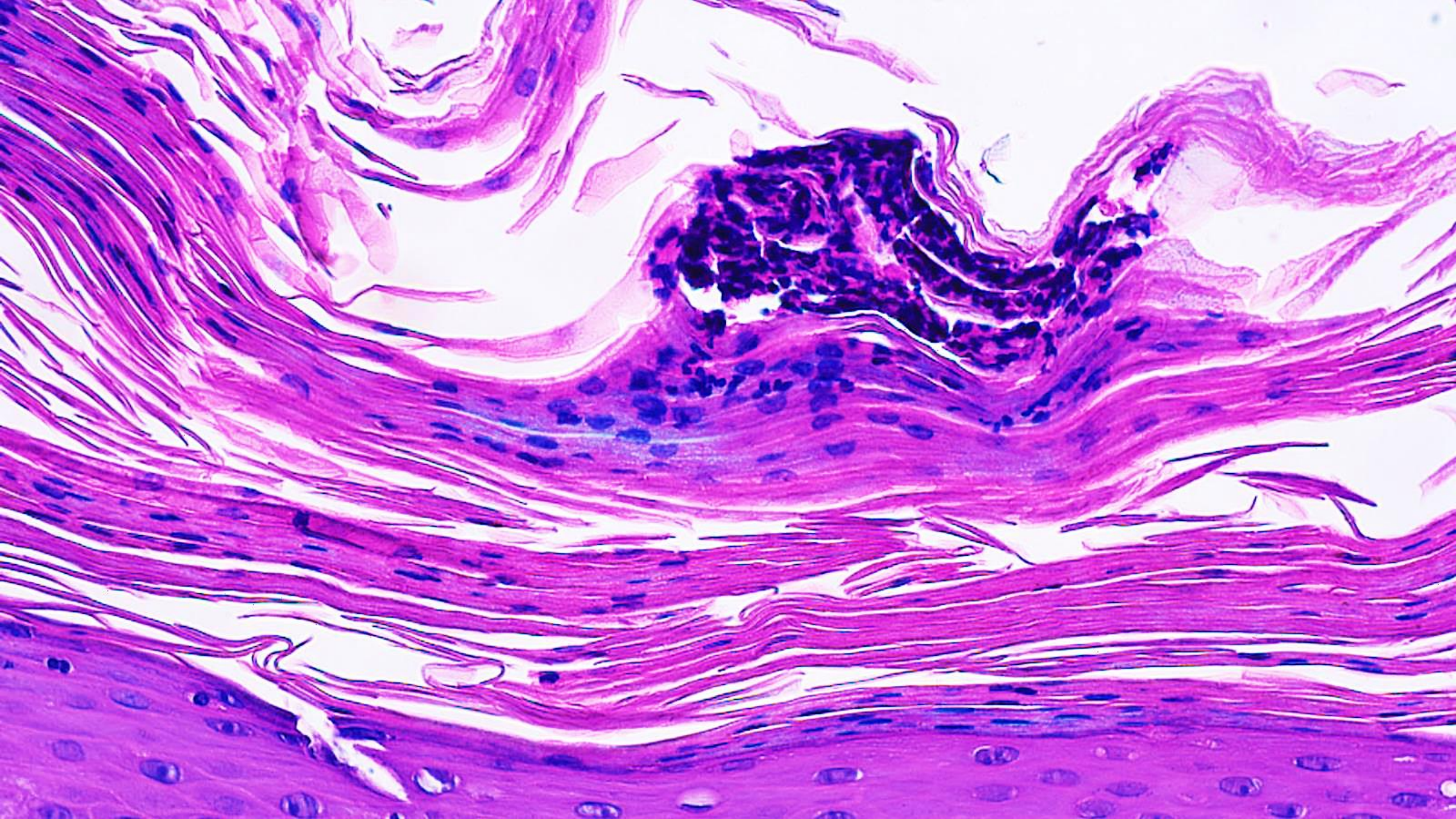
- **Clinical Information:** 43-year-old female; patient with psoriasis on TNF-alpha inhibitor (22-28589).
- **DIAGNOSIS:**
Skin, Scalp, Punch Biopsy:
 - Psoriasis, paradoxical.
- **Teaching Points:**
 - Treatment with TNF-alpha inhibitor may worsen preexisting psoriasis
- **Minimal Diagnostic Criteria:**
 - Loss of granular cell layer
 - Papillary dermal edema with dilated tortuous capillaries
 - Thinned, suprapapillary plates
 - Neutrophils within the stratum corneum
 - Neutrophils within the spinous layer
 - Superficial perivascular lymphocytic infiltrate
- **Differential Diagnosis:**

 - Chronic spongiotic dermatitis, Superficial cutaneous fungal infections









- **Clinical Information:** 76-year-old female; 9 MM PINK PAPULE R/O LICHEN PLANUS VS PSORIASIS (22-53030).

- **DIAGNOSIS:**

Skin, Right Medial Leg, Biopsy:

-Guttate psoriasis.

Comment: Overall, the findings of pityriasiform dermatitis with layered neutrophils above parakeratosis support the diagnosis and clinical impression of psoriasis. With appropriately staining control, PAS is negative for fungal hyphae.

- **Teaching Points:**

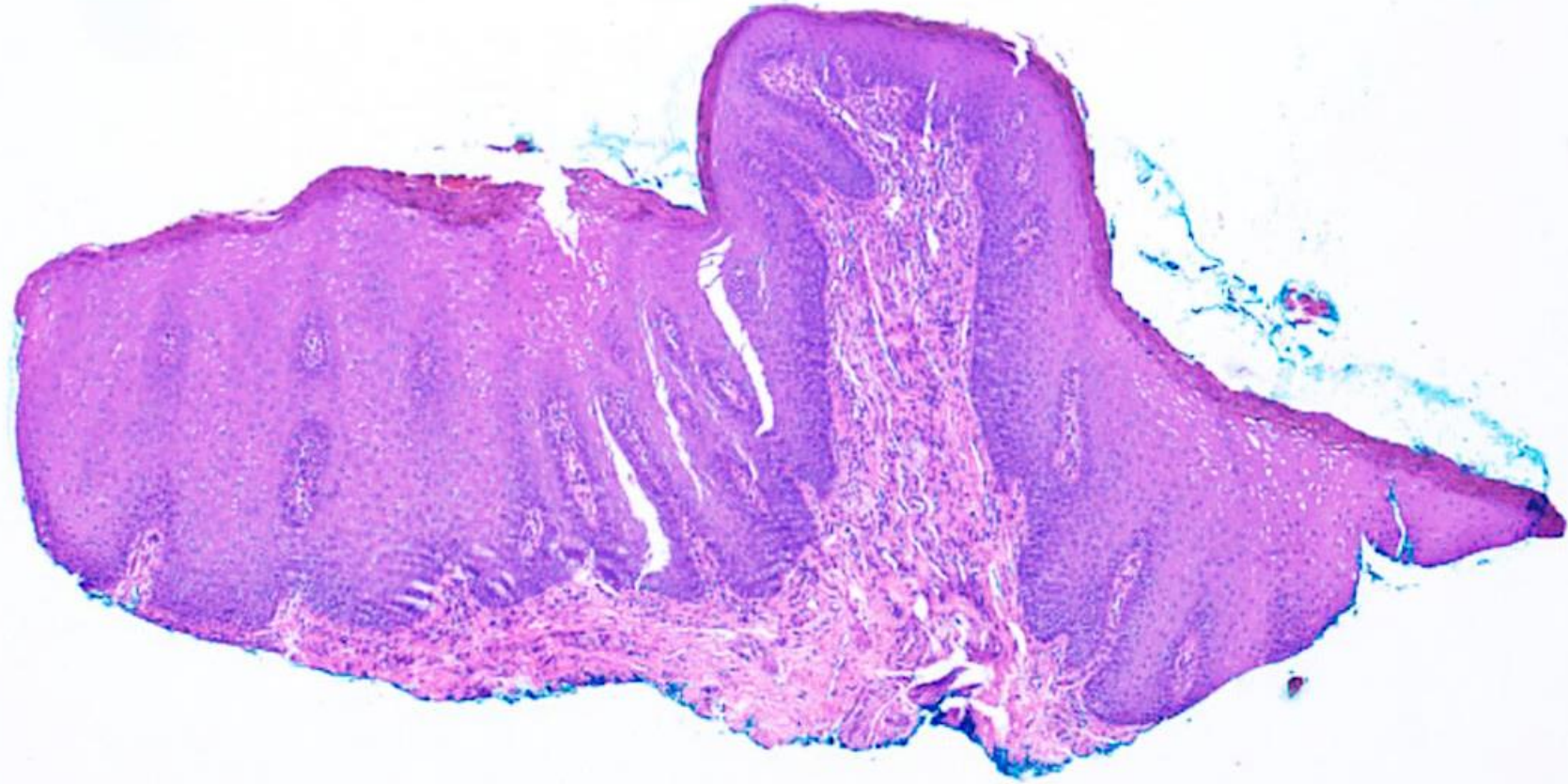
-

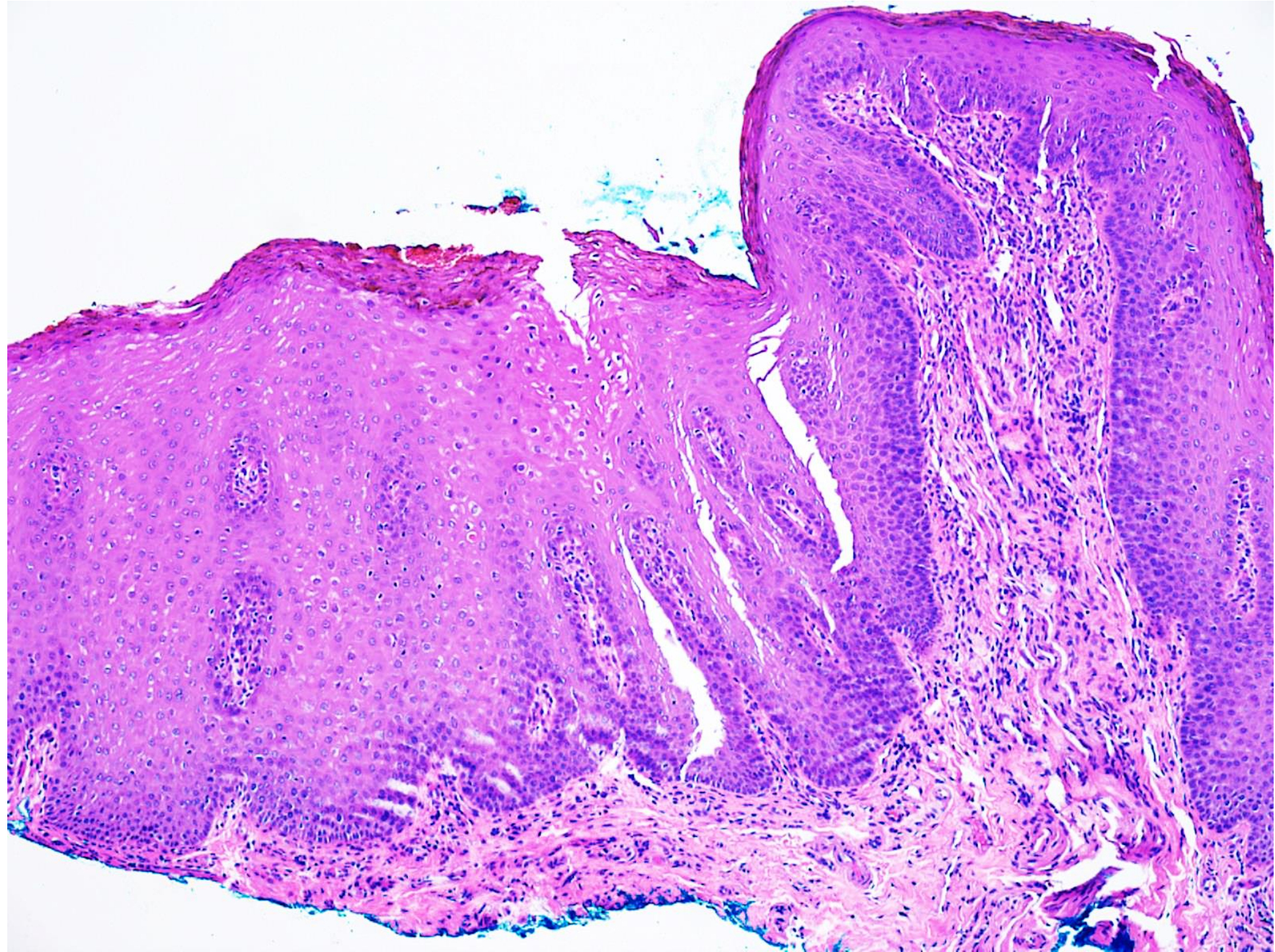
- **Minimal Diagnostic Criteria:**

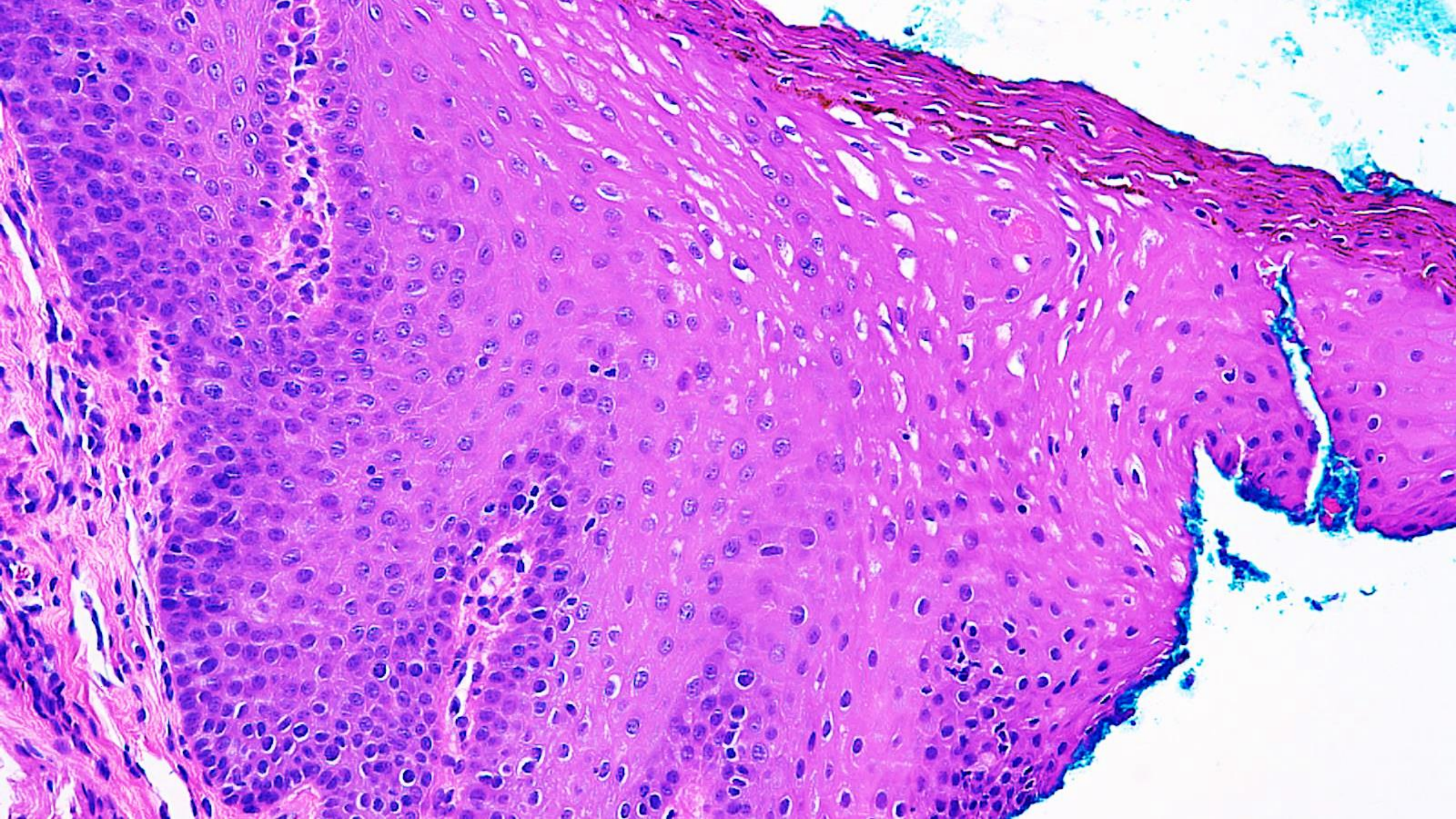
-

- **Differential Diagnosis:**

-







- **Clinical Information:** 58-year-old female; Per additional clinical history, the patient presents for tongue swelling and deep cracks and irritation (23-452).

- **DIAGNOSIS:**

Tongue, Left, Biopsy:

- Psoriasiform, spongietic glossitis.

Comment: The histologic differential diagnosis includes psoriasis, contact stomatitis, and lichenoid glossitis, which may be related to dental amalgam, medications, or foods or other ingestants. Additional levels are examined. PAS special stain is negative for fungal organisms. Negative results for direct immunofluorescence do not support an autoimmune bullous stomatitis or oral lichen planus.

- **Teaching Points:**

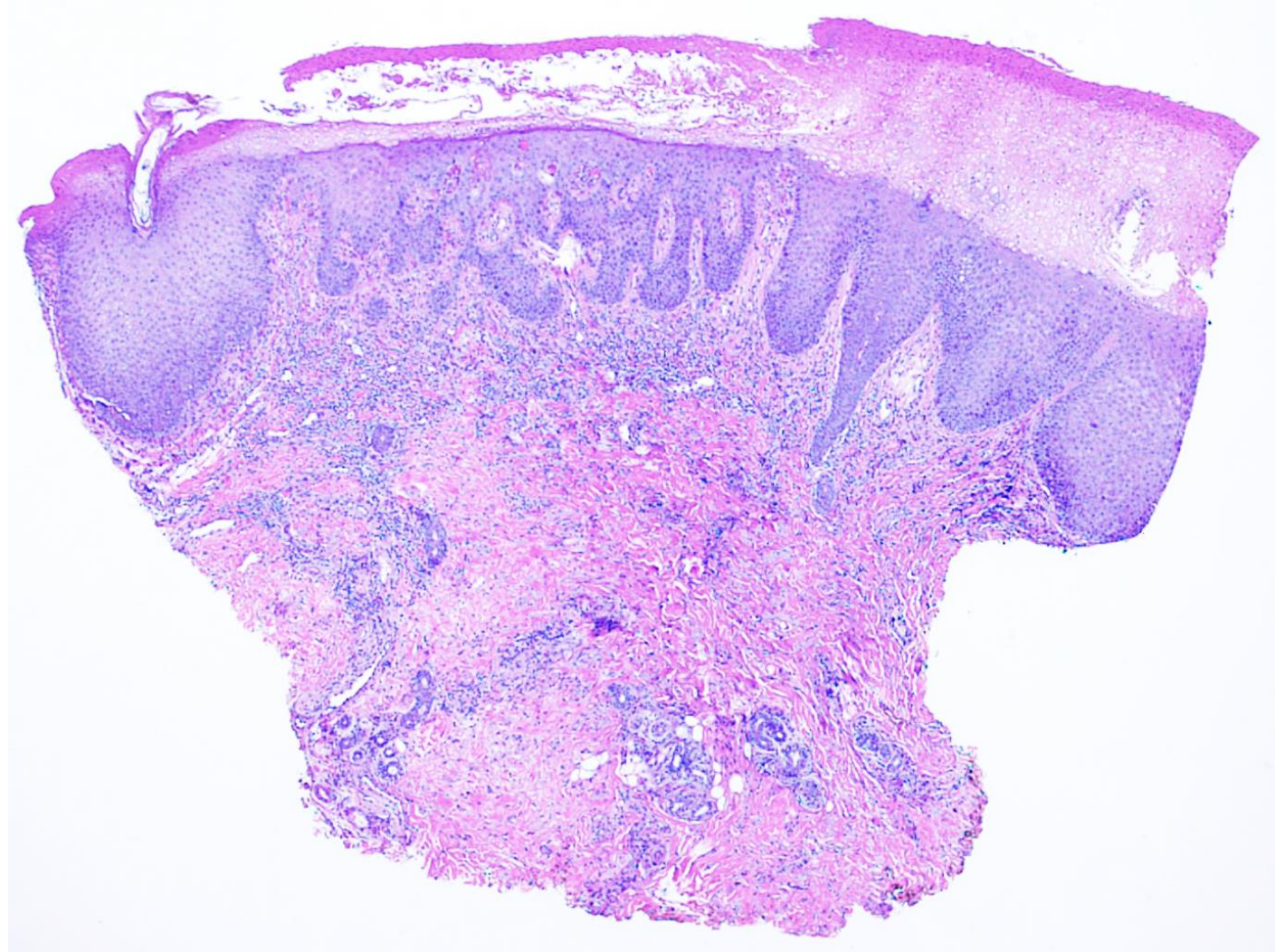
-

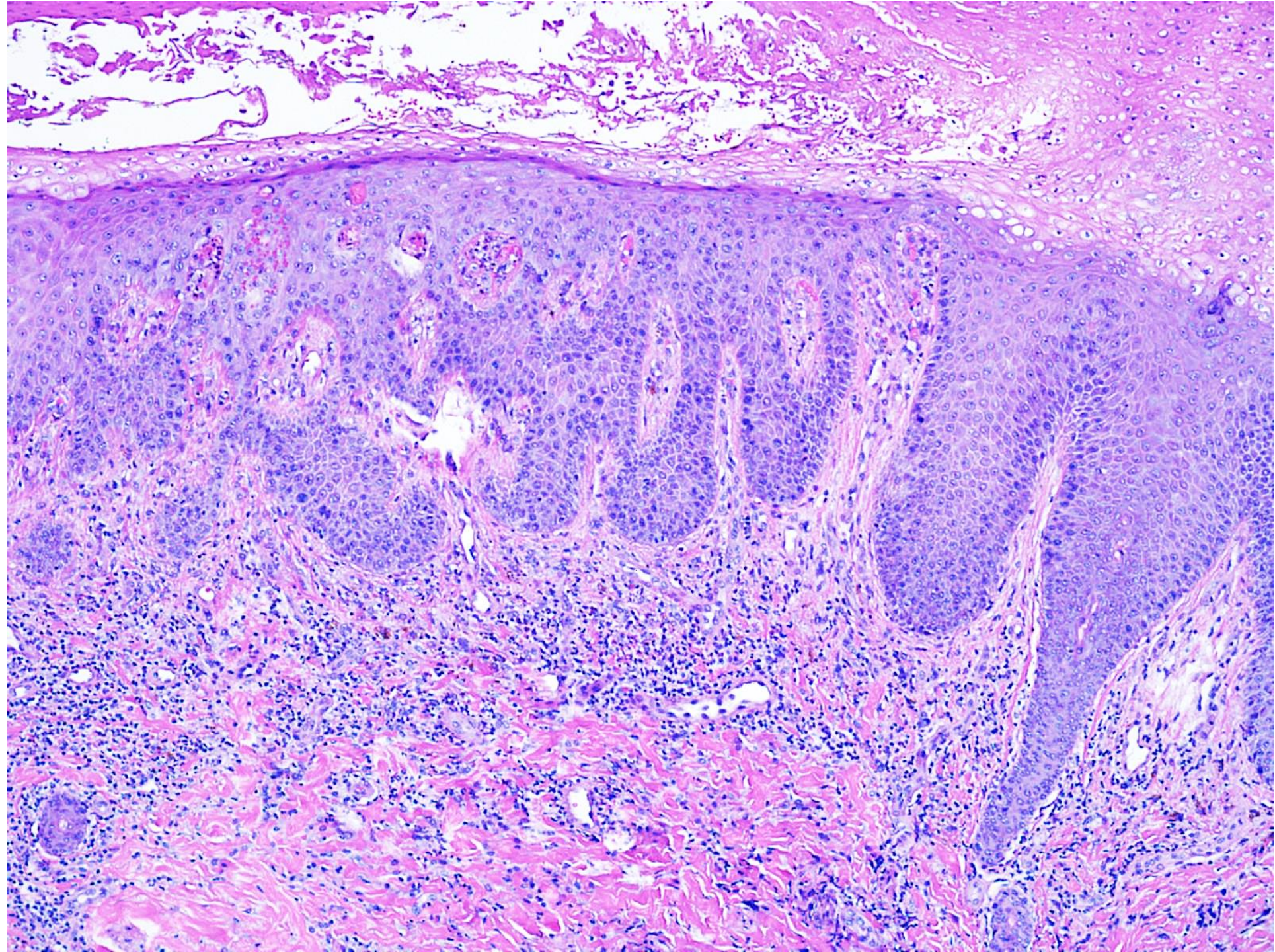
- **Minimal Diagnostic Criteria:**

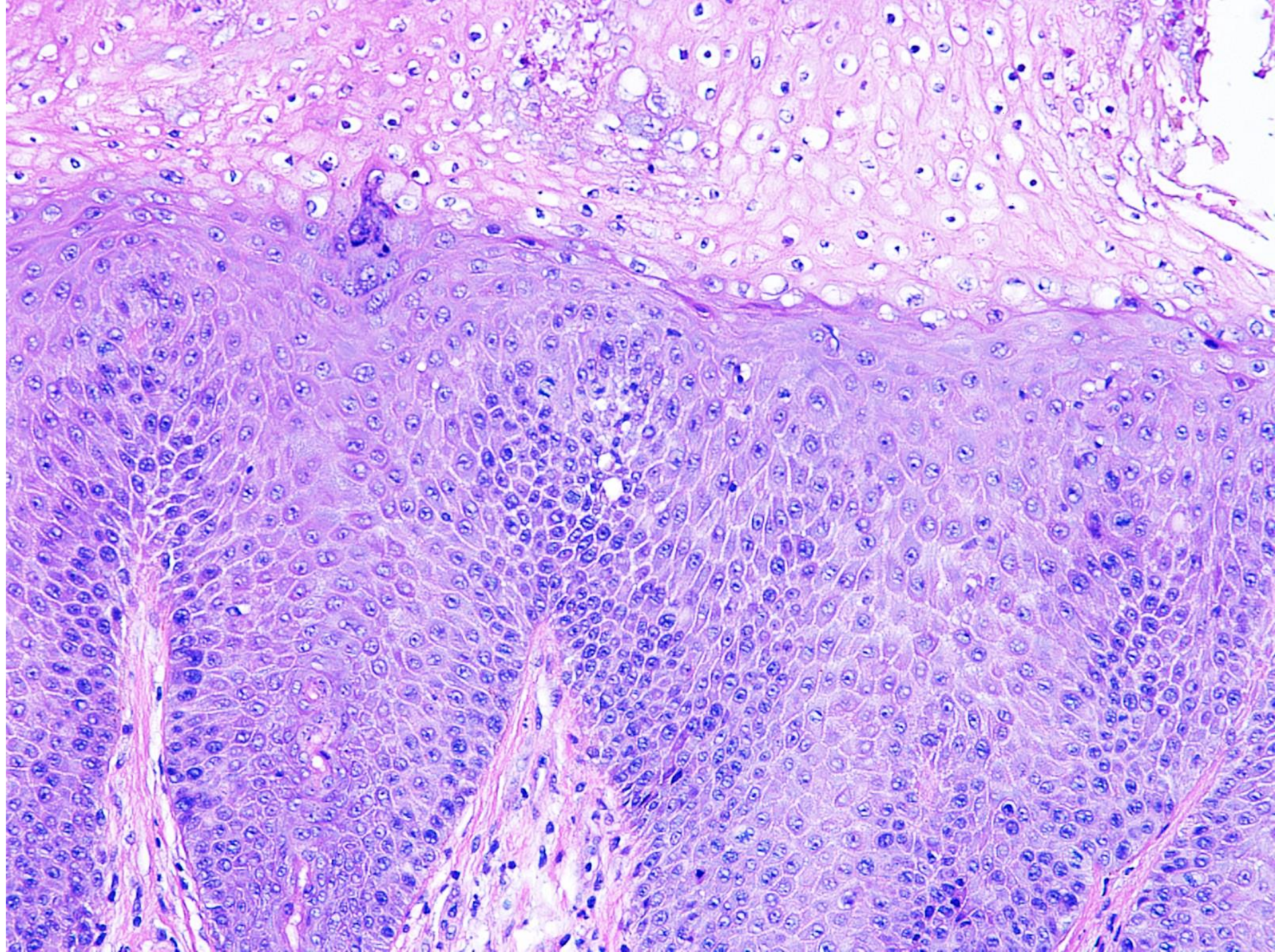
-

- **Differential Diagnosis:**

-

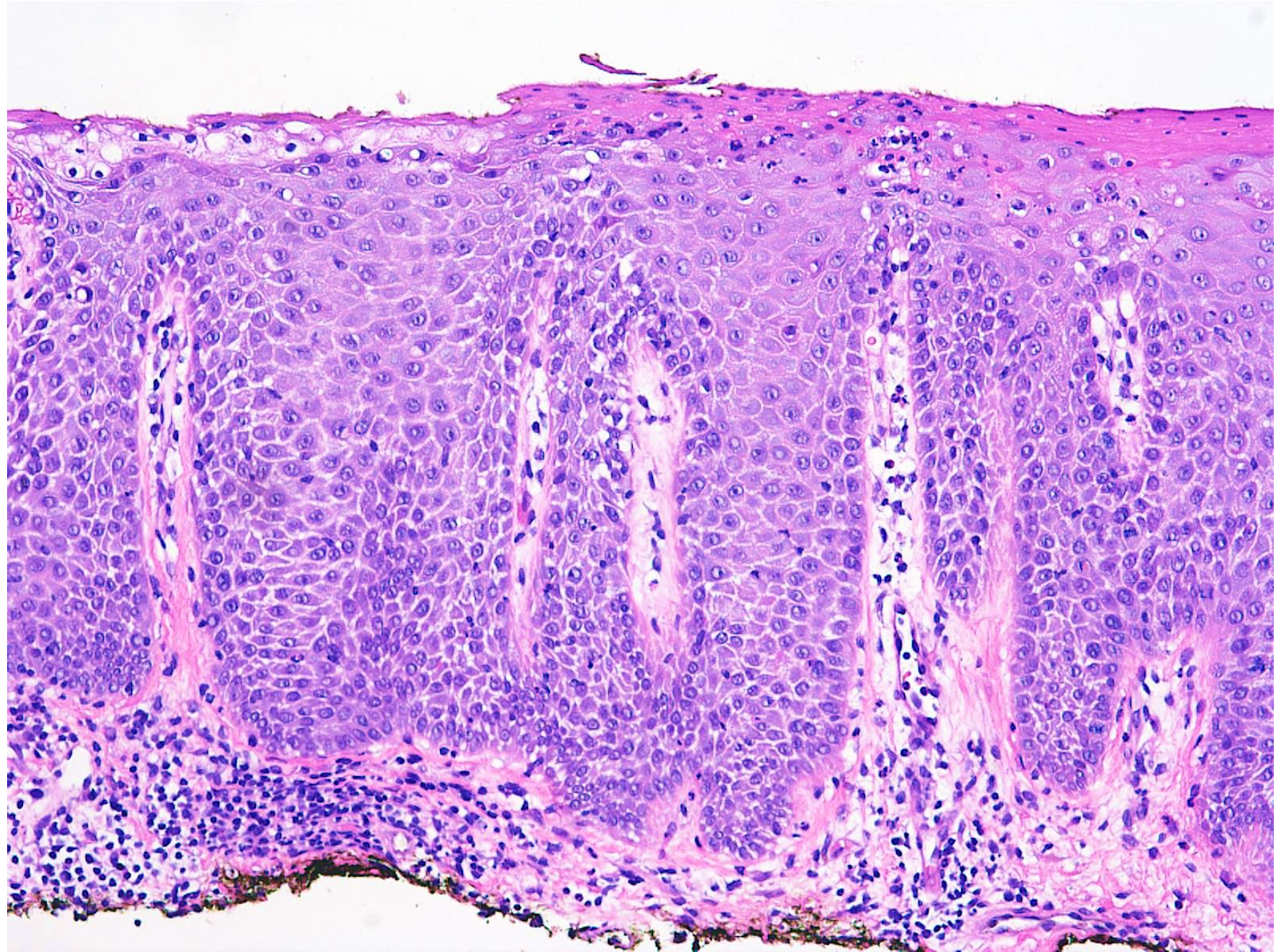






- **Clinical Information:** 80-year-old female; N90.89 (23-10413).
 - **DIAGNOSIS:**
 - Skin, Right Vulva, Biopsy:
 - Inverse psoriasis.
 - **Teaching Points:**
 -
 - **Minimal Diagnostic Criteria:**
 -
 - **Differential Diagnosis:**
 -
-





- **Clinical Information:** 32-year-old male; 9 YEAR HISTORY OF MACERATED PLAQUE GLUTEAL CREASE AND PERIANAL AREA, INTERTRIGO VS INVERSE PSORIASIS VS SEB DERM, R/O BACTERIAL/FUNGAL INFECTION, (22-06378).

- **DIAGNOSIS:**

Skin, Right Gluteal Crease, Biopsy:

- Inverse psoriasis.

- **Teaching Points:**

-

- **Minimal Diagnostic Criteria:**

-

- **Differential Diagnosis:**

-

