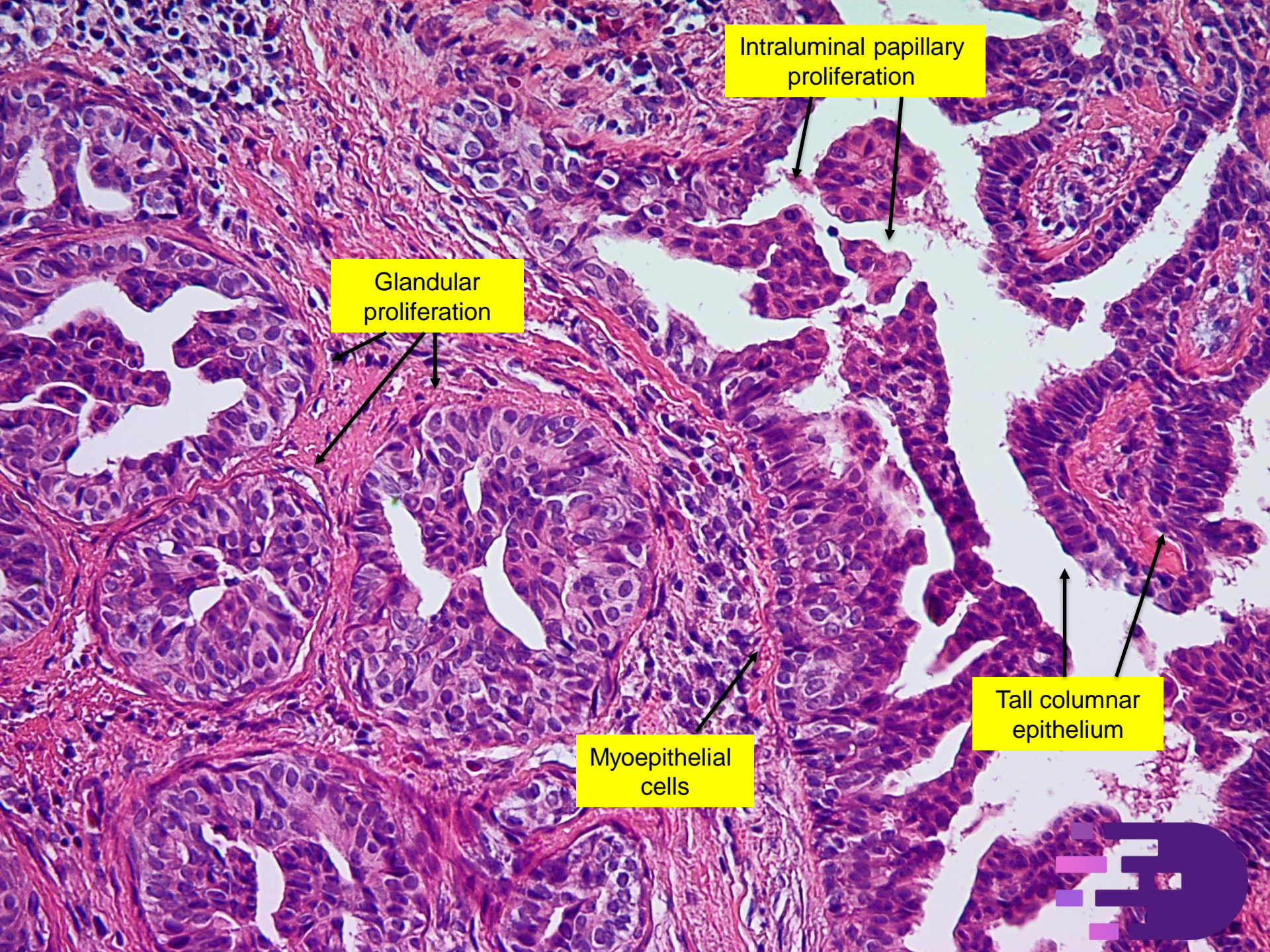

Intraluminal papillary proliferation


Glandular proliferation

Myoepithelial cells

Tall columnar epithelium







**DIGITAL SKIN PATHOLOGY (DiSK)**  
Learn Histologic Diagnosis Case-By-Case

- **Clinical Information:** 70/F R nipple, 9 mm ulcerated friable nonhealing papule on the right nipple, hx of breast cancer and radiation. BCC vs SCC vs other malignancy vs pyogenic granuloma.
- **DIAGNOSIS:**
  - SKIN, RIGHT NIPPLE, BIOPSY: NIPPLE ADENOMA, ERODED.
- **Teaching Points:**
  - Benign tumor of the nipple, middle-aged women
  - Scaly, erythematous, and eroded lesion
  - Mimics eczematous dermatitis of nipple  
Or Paget's disease
- **Minimal Diagnostic Criteria:**
  - Communicates with the surface
  - Usually eroded (aka erosive adenomatosis)
  - Adenomatous and papillary areas
  - Glands are lined by tall columnar cells
  - Myoepithelial cells
- **Differential Diagnosis:**
  - Syringomatous adenoma of the nipple
  - Ductal carcinoma in situ

