



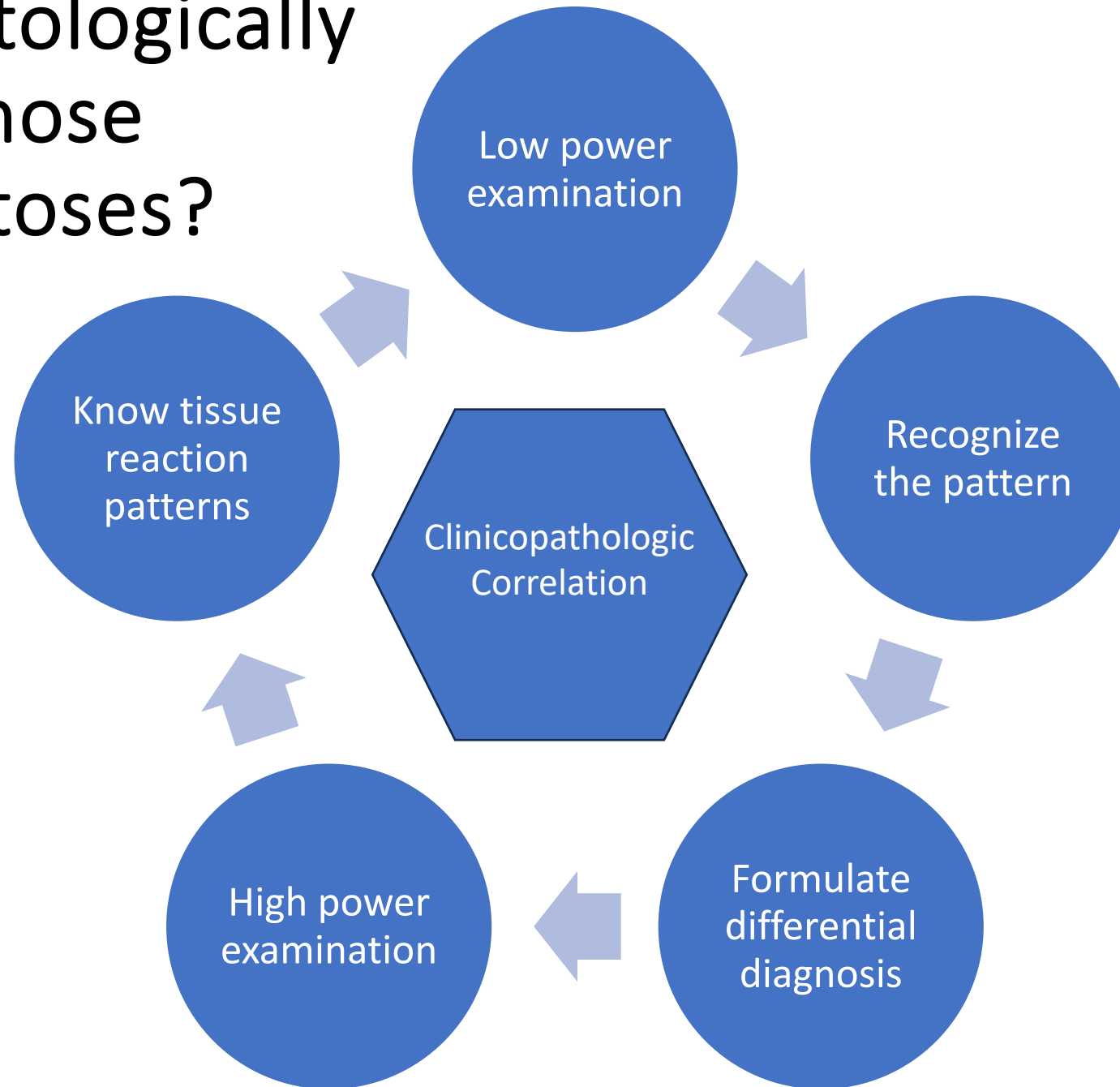
# The spongiotic reaction pattern

Sam Soheil Dadras MD-PhD

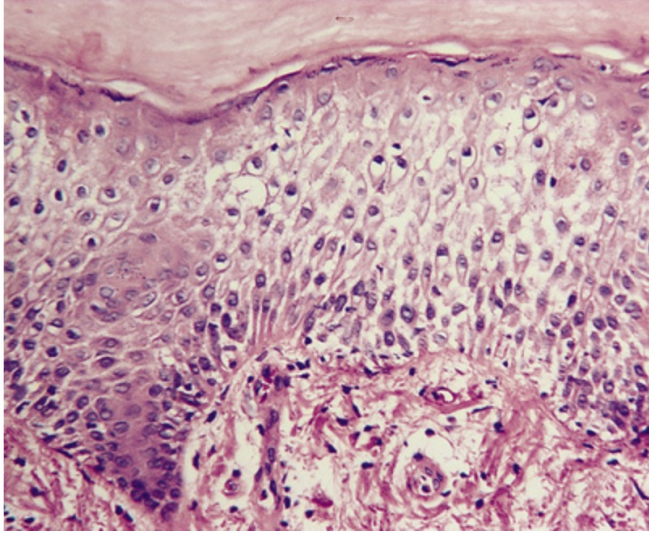
Director of Dermatopathology

UMass Department of Pathology

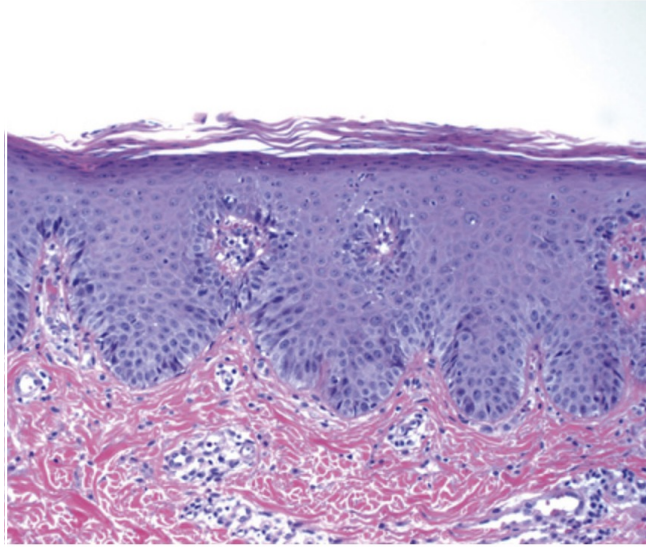
# How to histologically diagnose dermatoses?



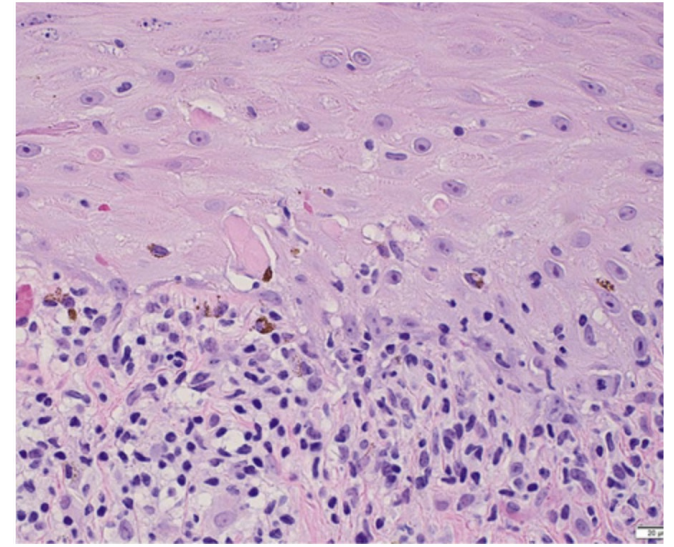
# Tissue reaction patterns



Spongiotic



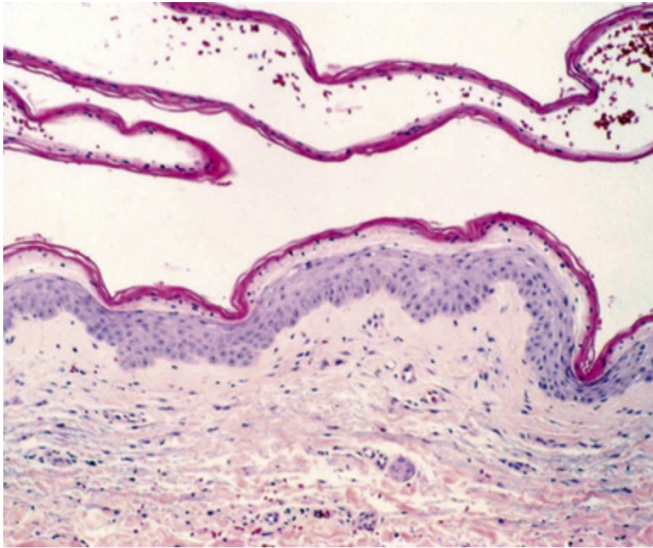
Psoriasiform



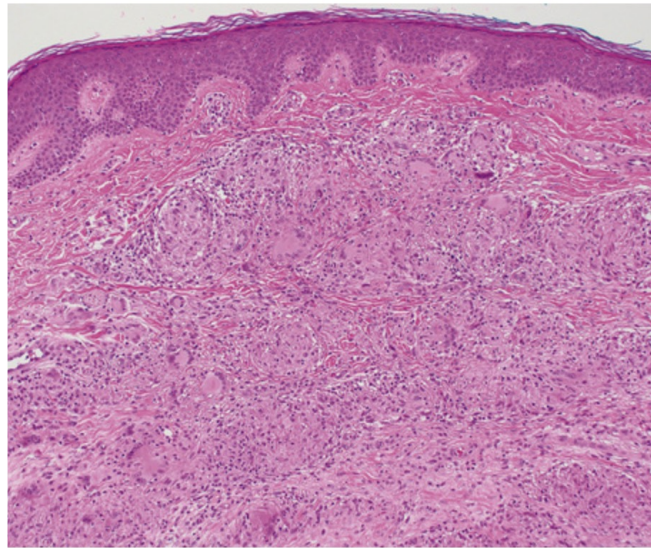
Lichenoid



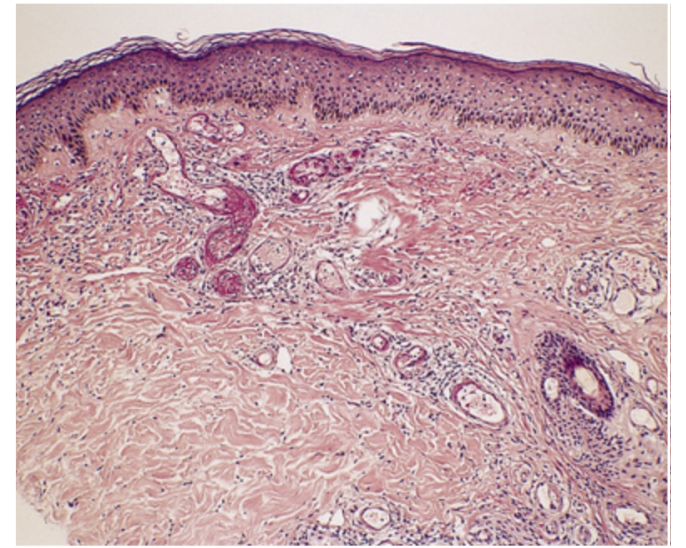
# Tissue reaction patterns



Vesiculobullous



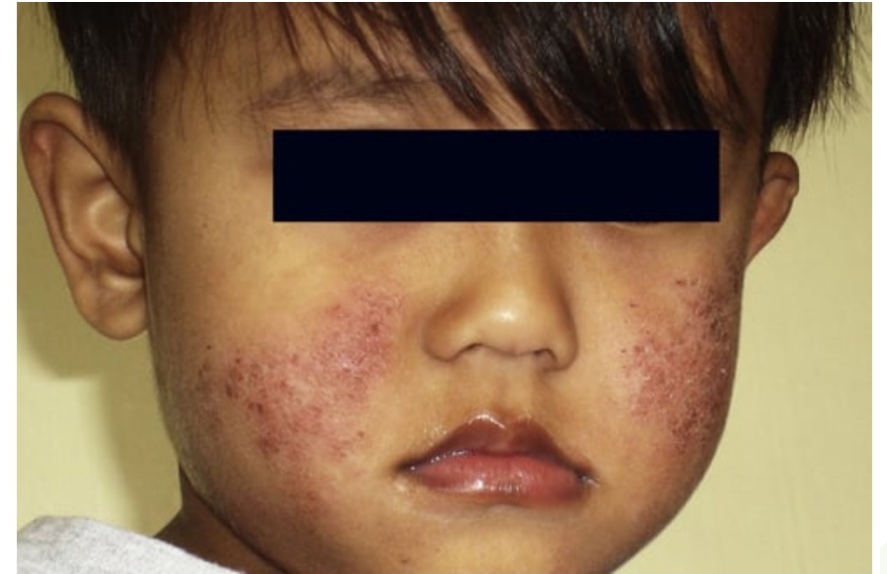Granulomatous



Vasculopathic

# Introduction: Spongiosis

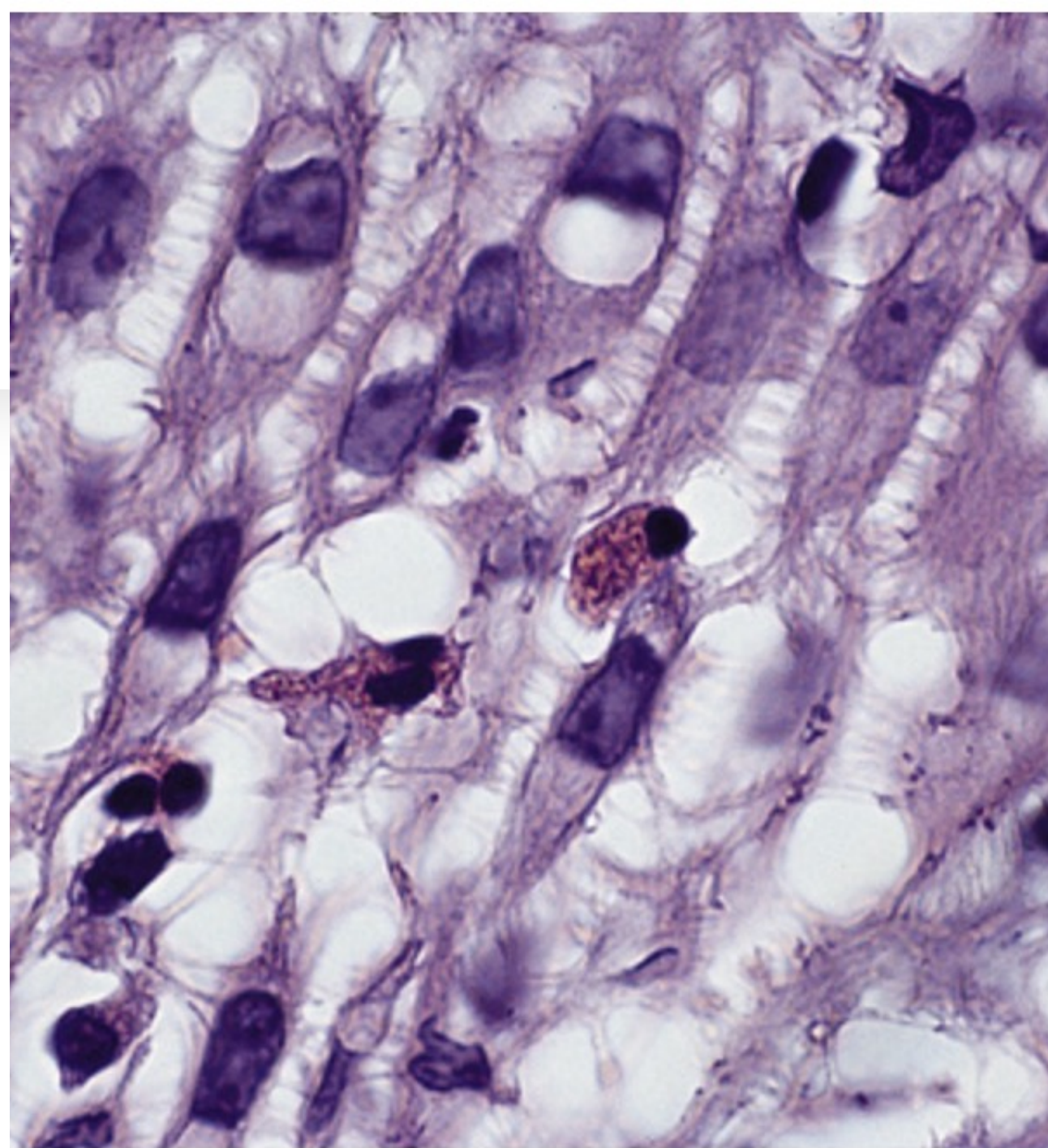
- Histopathologic concept, not clinical
- *Eczemas* “boiling over” – lacks precision
- Clinically, spongiotic disorders:
  - Weeping, crusted patches/plaques/papules/papulovesicles
  - As it resolves shows collarette of scale





# Histopathology

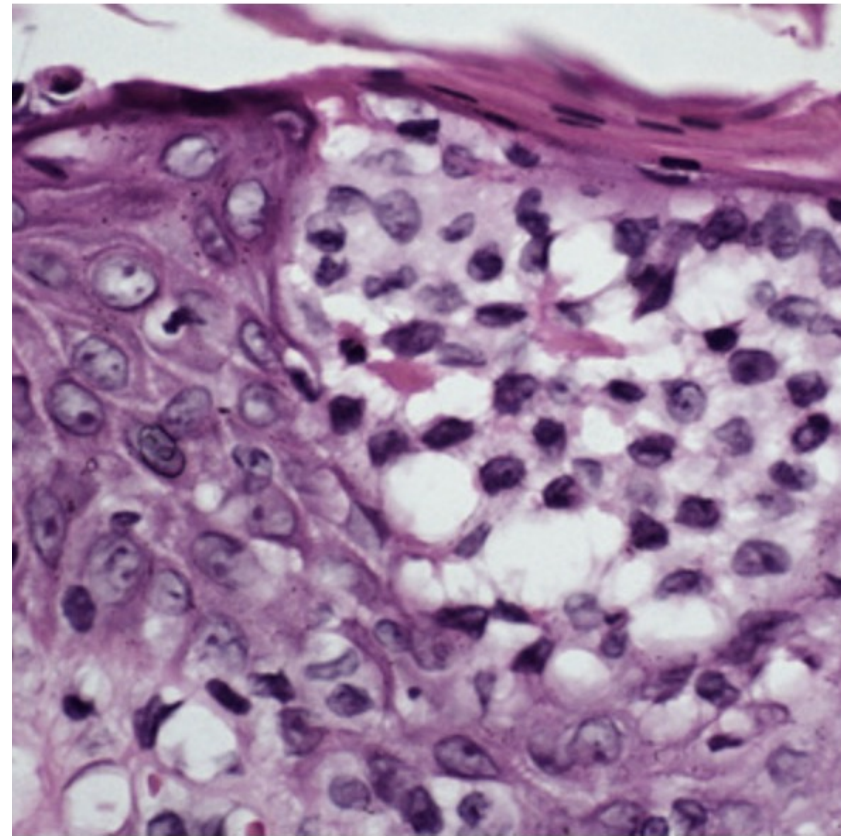
- Intraepidermal and intercellular edema (spongiosis)
- Widened intercellular spaces between keratinocytes
- Elongation of intercellular bridges
- Cellular components:
  - Lymphocytes (usually)
  - Neutrophils
  - Eosinophils



# Simulants of spongiosis

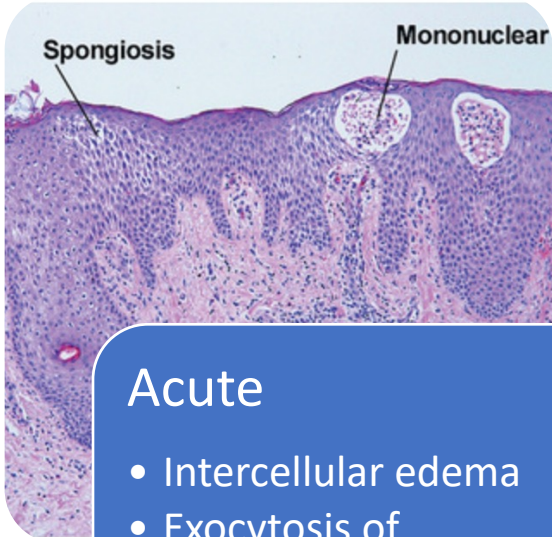
---

- Very common histopathologic pattern
- Secondary histologic finding, not the main disease category
  - Pityriasis lichenoides, erythema multiforme, and fixed drug eruption
  - Acantholytic dyskeratosis with spongiosis seen in Grover's disease
- Pautrier microabscess of mycosis fungoides mimics intraepidermal Langerhans cells
- Mucin in follicular infundibulum mimics spongiosis



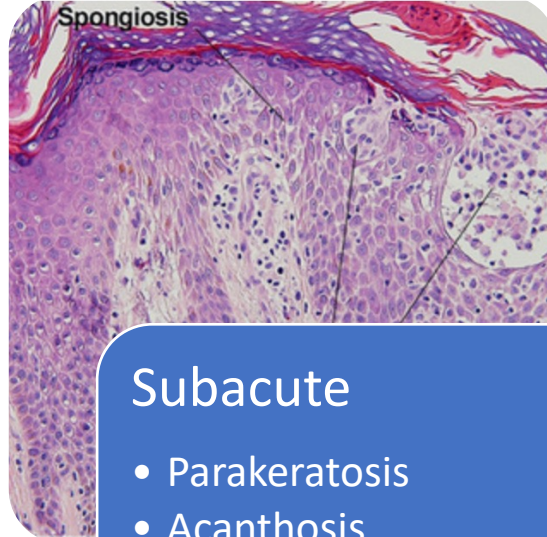

# Dynamic phases of spongiotic dermatitis



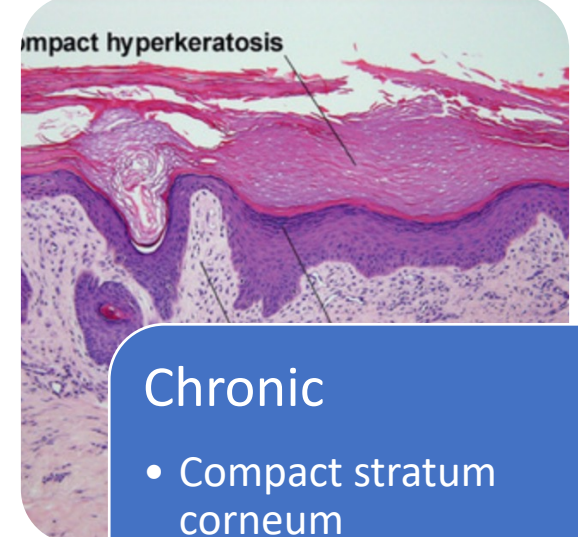
## Acute

- Intercellular edema
- Exocytosis of lymphocytes
- Intraepidermal microabscess



## Subacute

- Parakeratosis
- Acanthosis
- Intercellular edema
- Exocytosis of lymphocytes
- Intraepidermal microabscess



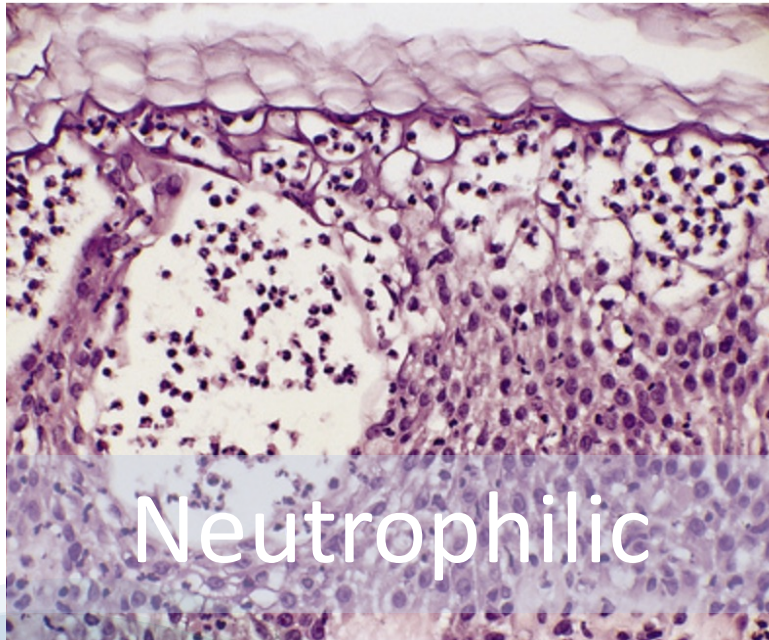
## Chronic

- Compact stratum corneum
- Irregular acanthosis
- Papillary dermal fibrosis
- "Hairy palm skin"



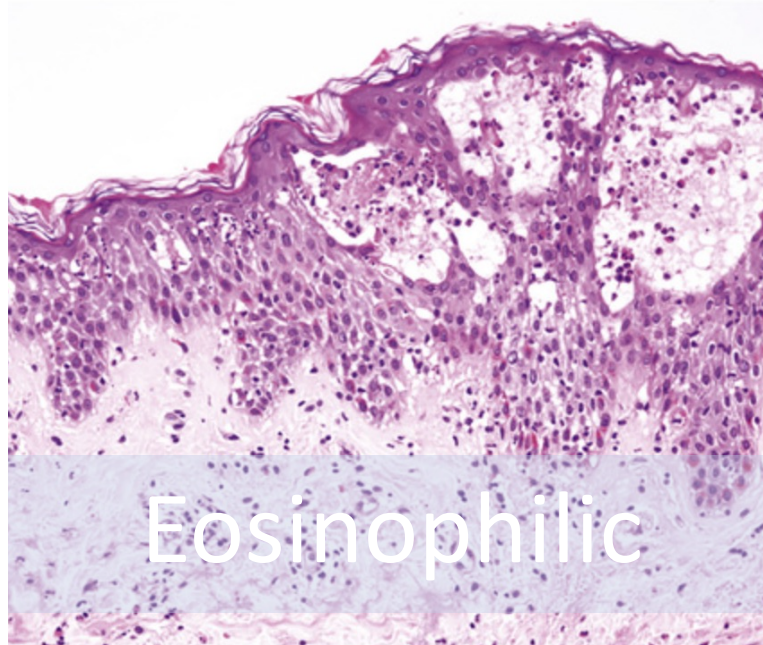# Five patterns of spongiosis

acrosyringium



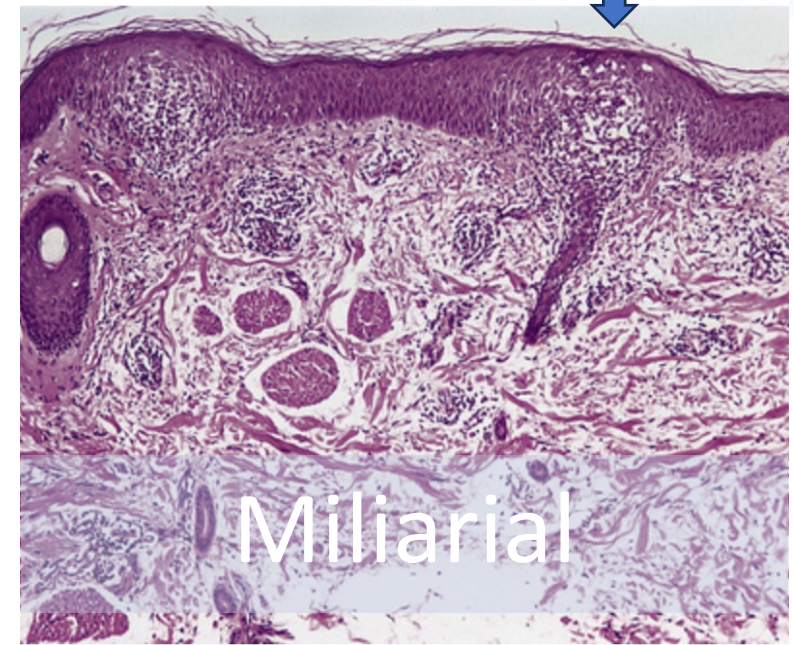
Neutrophilic

Dermatophytoses  
Acute generalized exanthematous  
pustulosis  
Pustular psoriasis



Eosinophilic

Allergic contact dermatitis  
Atopic dermatitis  
Arthropod assault  
Pemphigus and pemphigoid  
disease groups

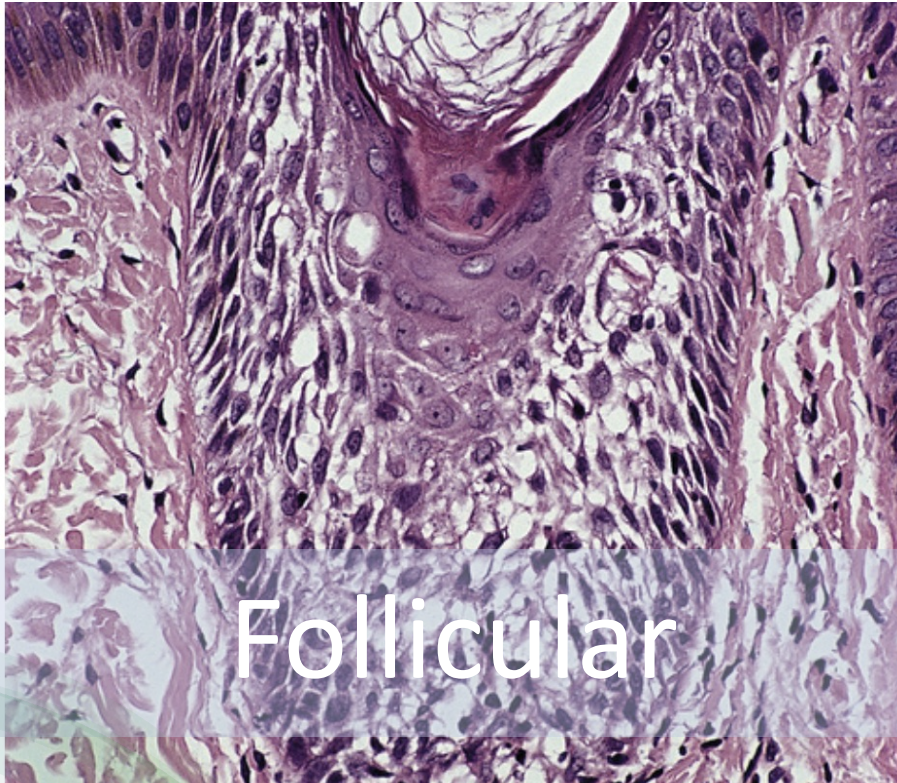

Miliarial

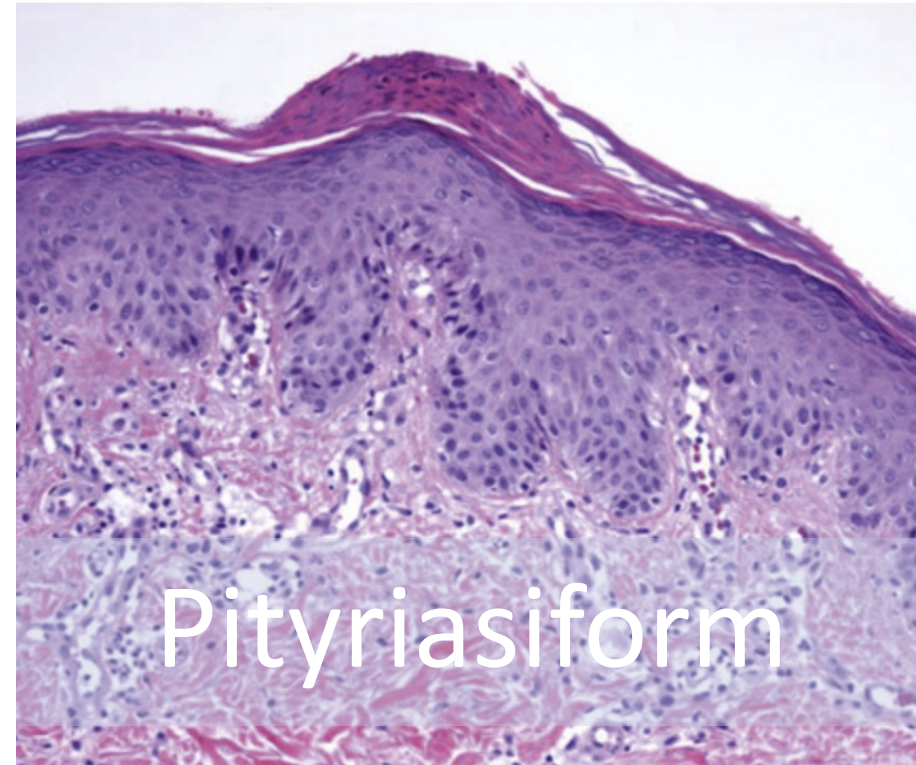Miliaria crystallina  
Miliaria rubra  
Miliaria profunda



# Five patterns of spongiosis



Infundibulofolliculitis  
Atopic dermatitis  
Eosinophilic folliculitis

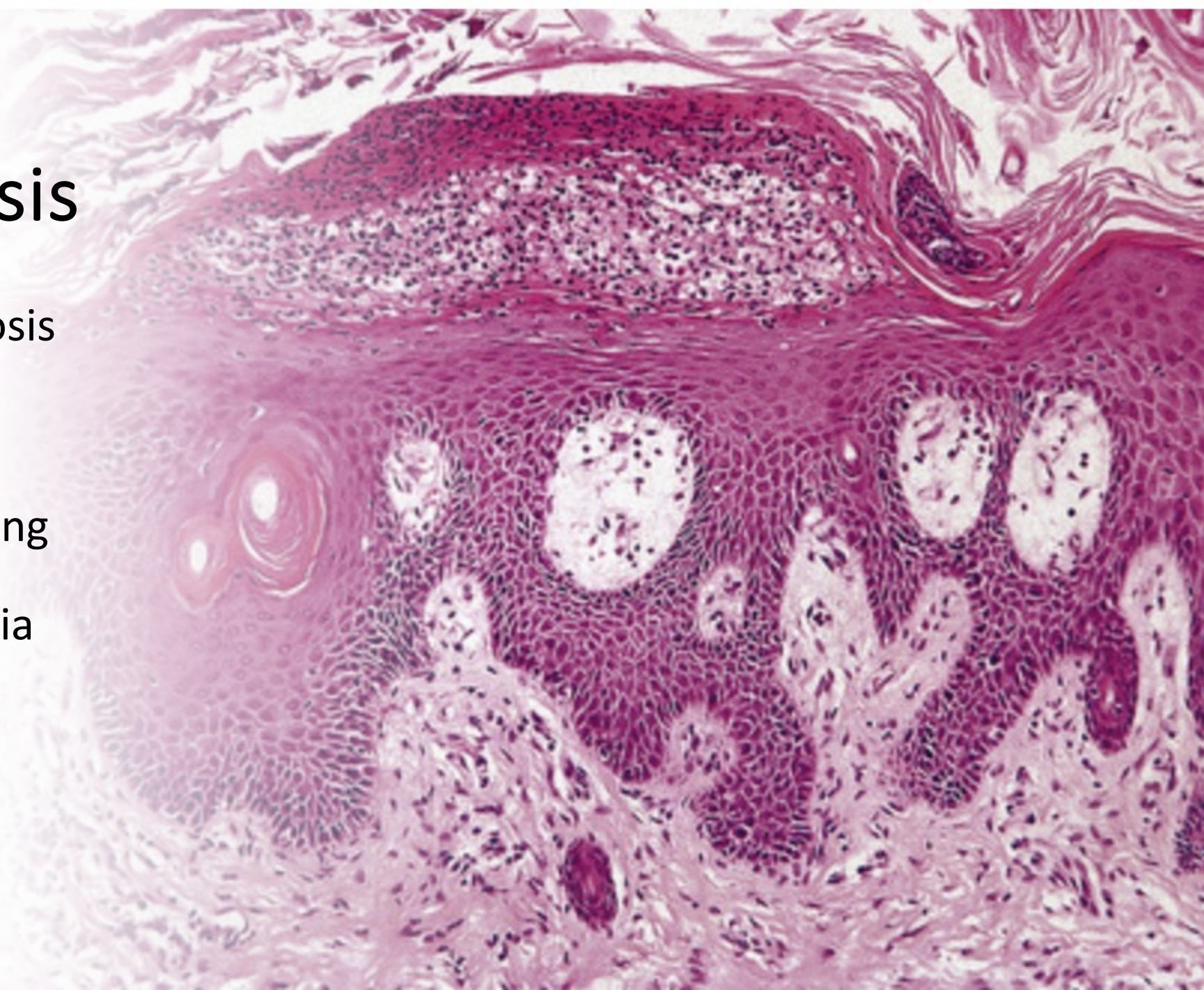


Pityriasis rosea  
Nummular dermatitis  
Erythema annulare centrifugum

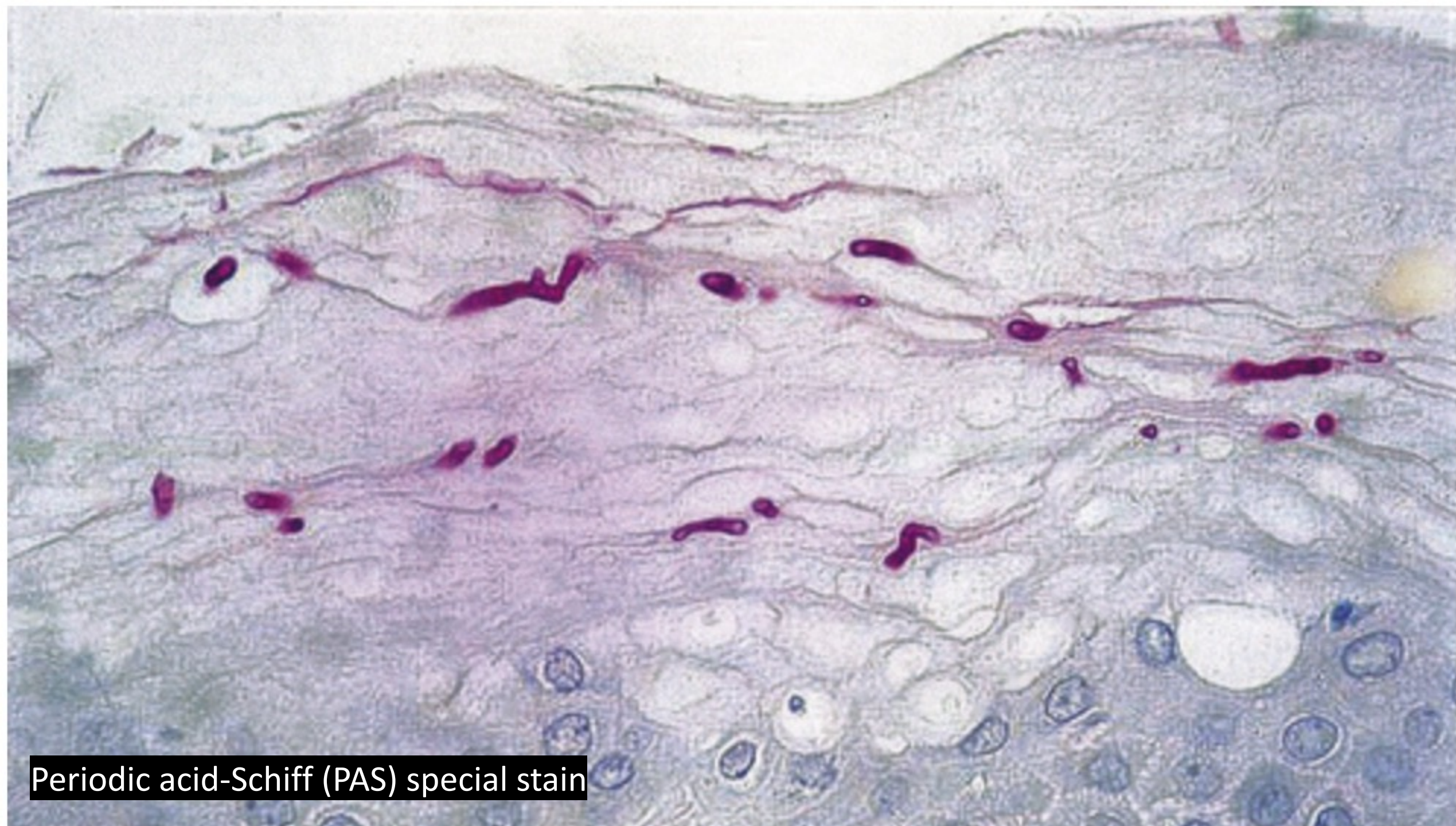


# Dermatophytosis

- Neutrophilic spongiosis
- Patch with central clearing and raised borders
- Parakeratosis overlying subcorneal pustule
- Epidermal hyperplasia with spongiosis
- Refractile elements vertical to epidermis







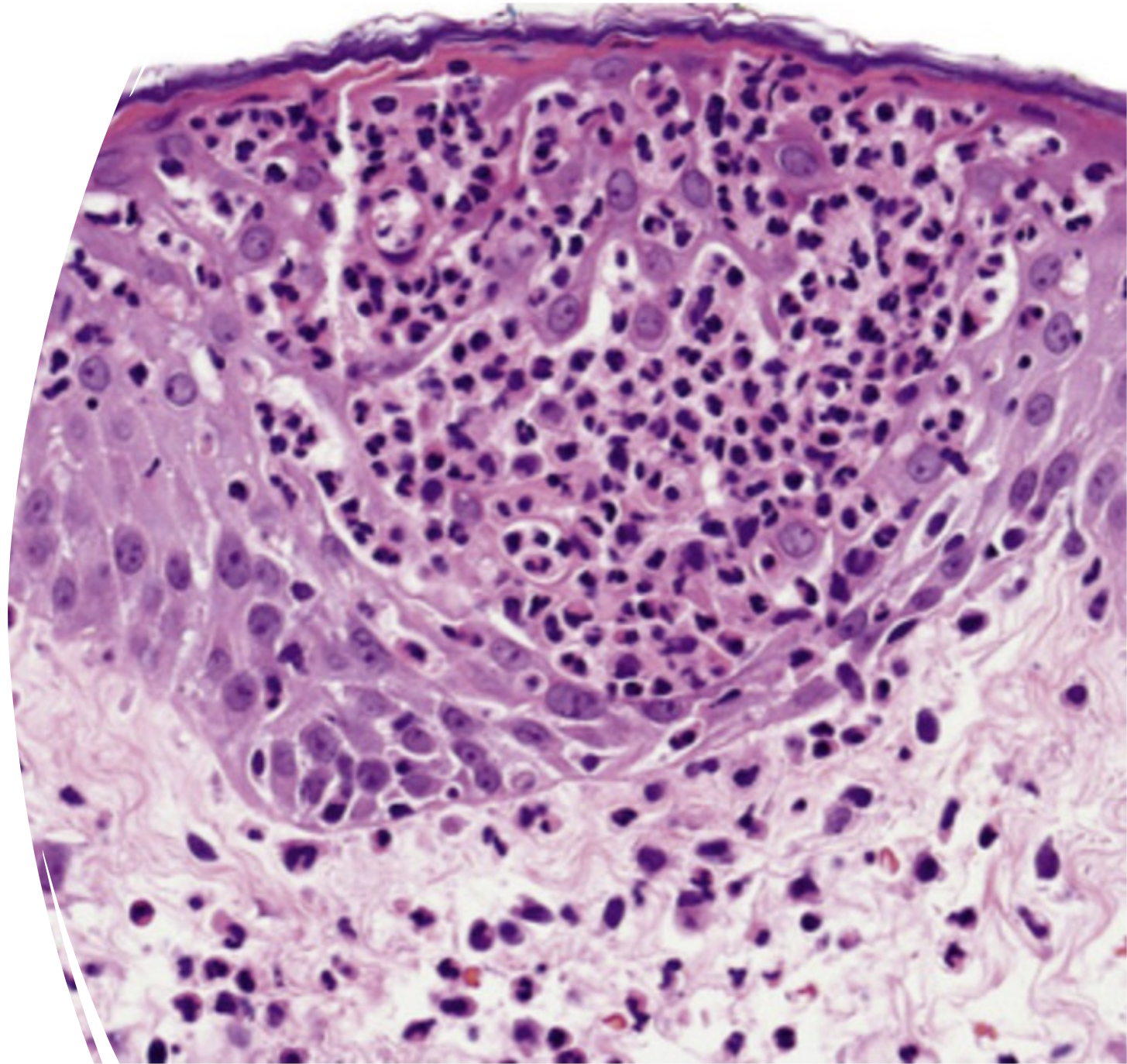
Periodic acid-Schiff (PAS) special stain



# Acute generalized exanthematous pustulosis

---

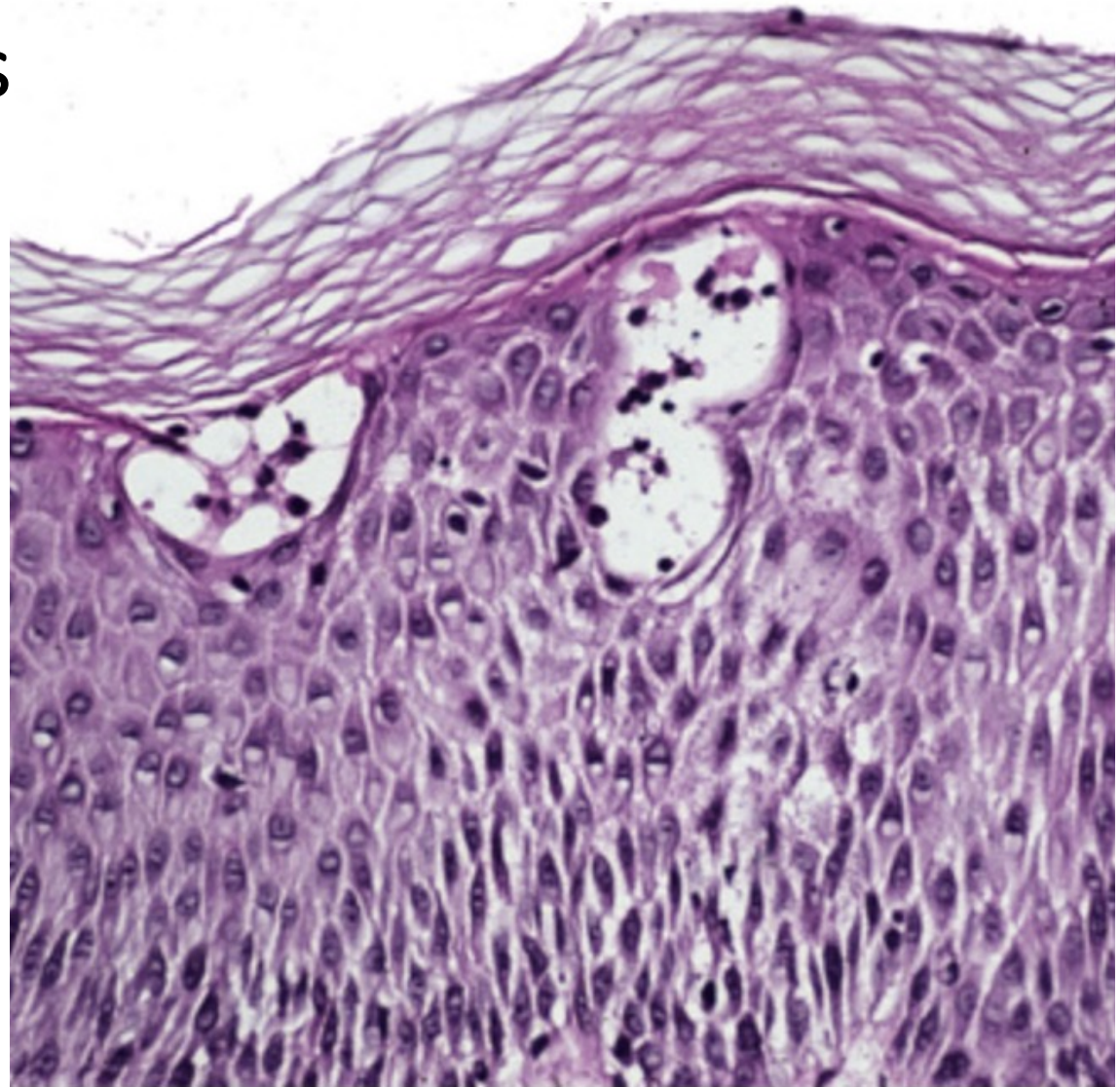
- Neutrophilic spongiosis
- Drug-induced pustules covering large area
- Subcorneal/intraepidermal neutrophilic pustules
- Background spongiosis
- Busy dermis: perivascular infiltrate of lymphocytes, histocytes or neutrophils
- $\pm$  Leukocytoclastic vasculitis





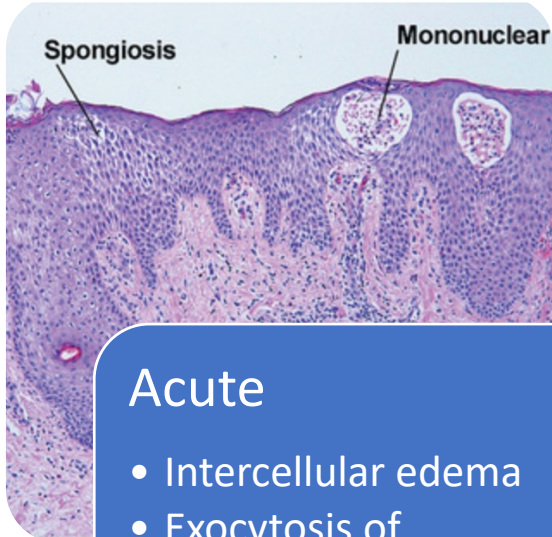
# Allergic contact dermatitis (eosinophilic spongiosis)

- Initiated by contact with an allergen to which the person has been sensitized
- Pruritic erythematous papules, vesicles or weeping plaques
- Intraepidermal vesicles
  - Langerhans cell microabscess
- Background spongiosis
- Exocytosis of lymphocytes and eosinophils



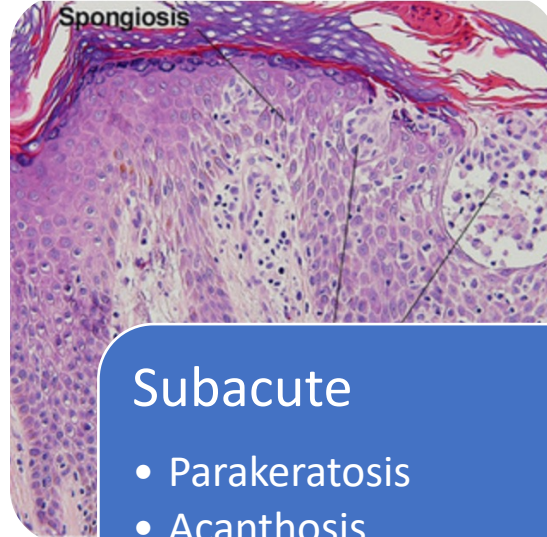

# Dynamic phases of spongiotic dermatitis: when and where to biopsy



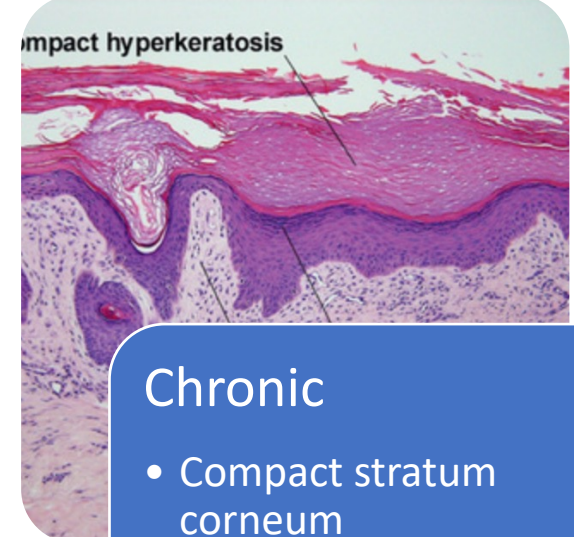
## Acute

- Intercellular edema
- Exocytosis of lymphocytes
- Intraepidermal microabscess



## Subacute

- Parakeratosis
- Acanthosis
- Intercellular edema
- Exocytosis of lymphocytes
- Intraepidermal microabscess



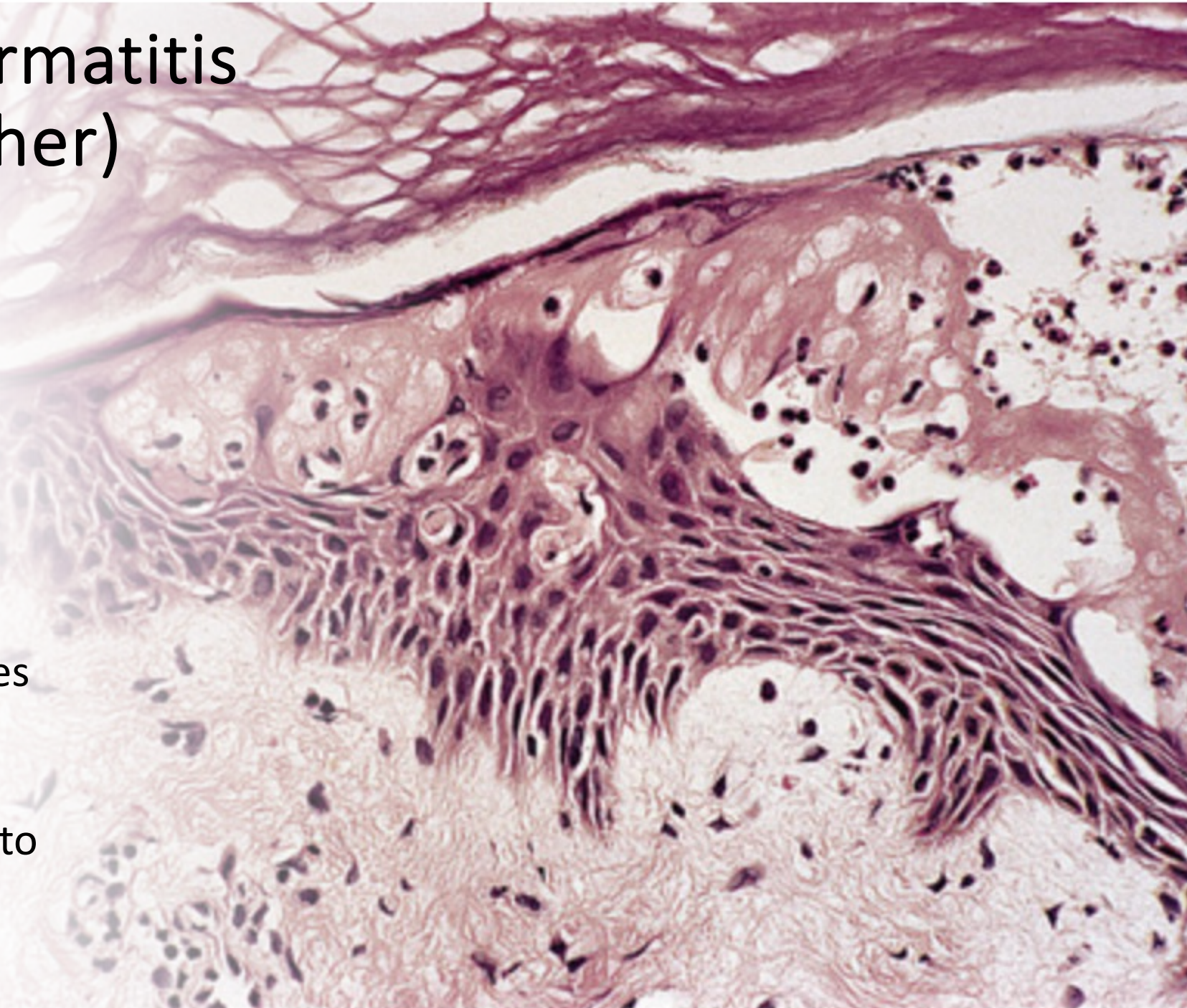
## Chronic

- Compact stratum corneum
- Irregular acanthosis
- Papillary dermal fibrosis
- "Hairy palm skin"



# Irritant contact dermatitis (spongiotic, other)

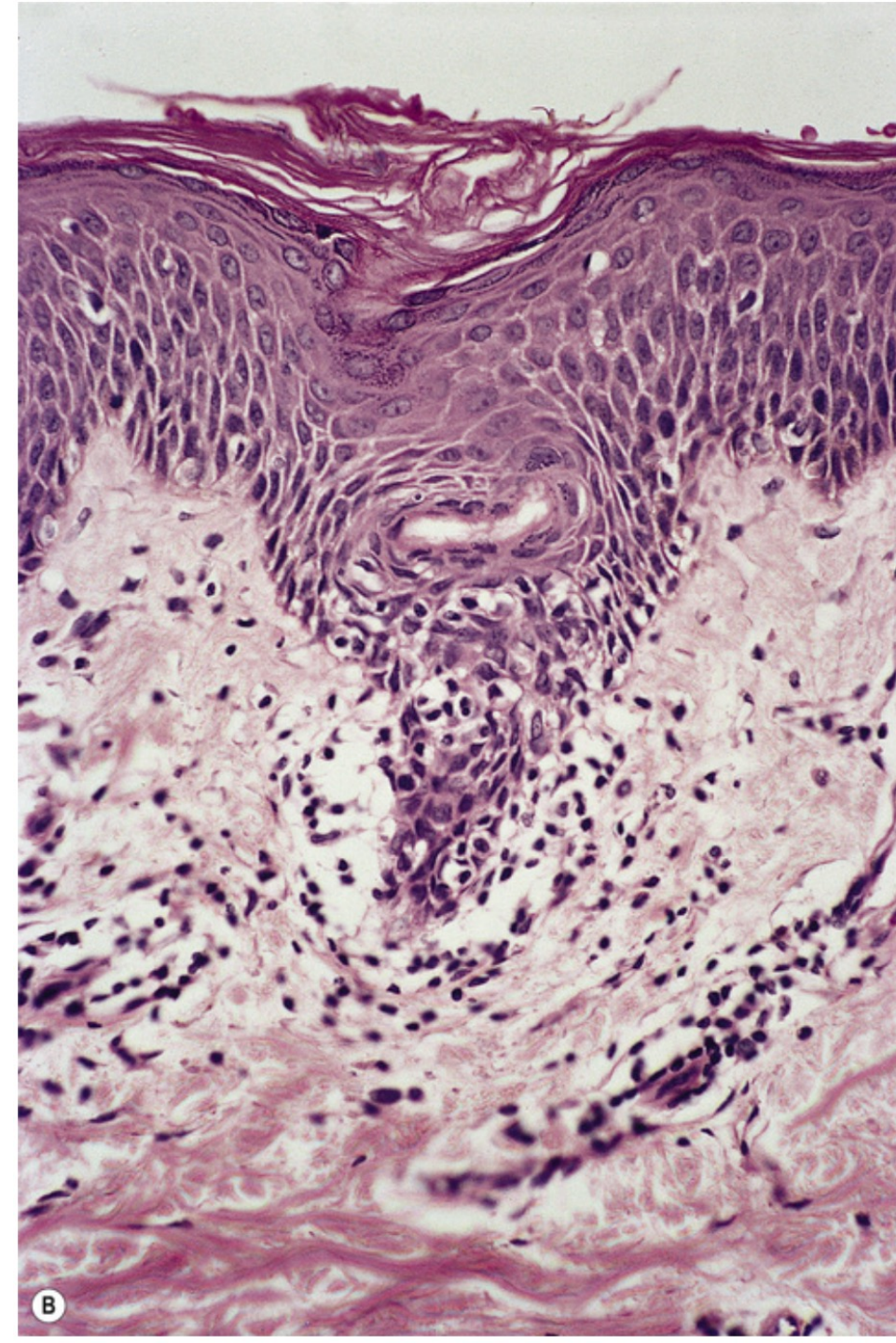
- In response to the direct toxic effect of an irritant substance
- Erythema to purpura, vesiculobullous lesions to epidermal necrosis
- Fissuring to cracking, e.g., hand eczema
- Ballooning of keratinocytes with neutrophils in the upper dermis  $\pm$  necrosis
- Epidermal necrosis: focal to confluent, may separate
- Spongiosis





# *Miliaria rubra* (miliarial spongiosis)

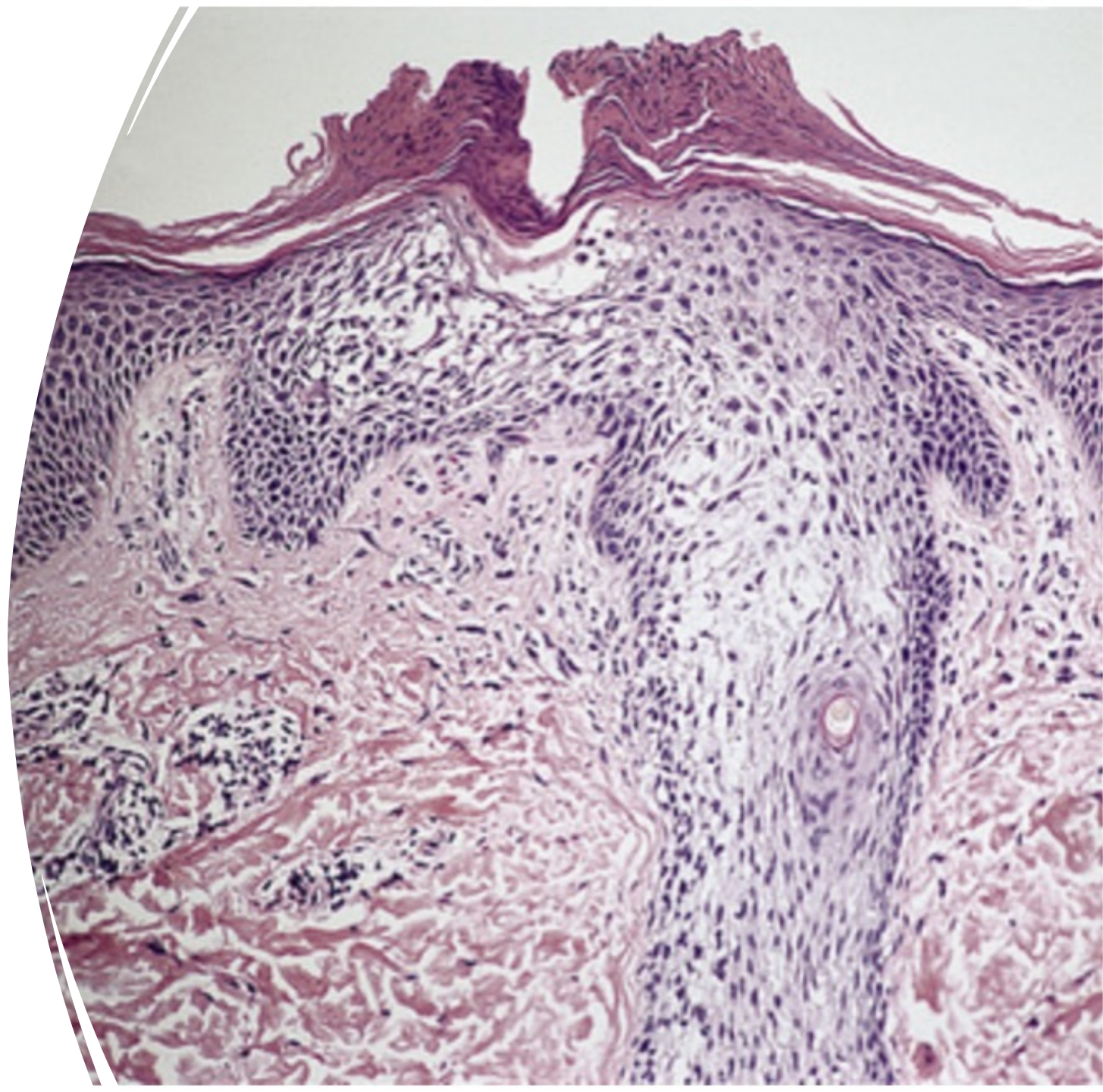
- Free flow of eccrine sweat to the skin surface is impeded
- (prickly heat) small, discrete erythematous papulovesicles
- Predilection for clothed body areas
- Intraepidermal edema centered on the acrosyringium
- Variable spongiosis and lymphocytic exocytosis
- Ortho or parakeratotic plug overlies spongiosis
- Papillary dermal edema





# Infundibulofolliculitis

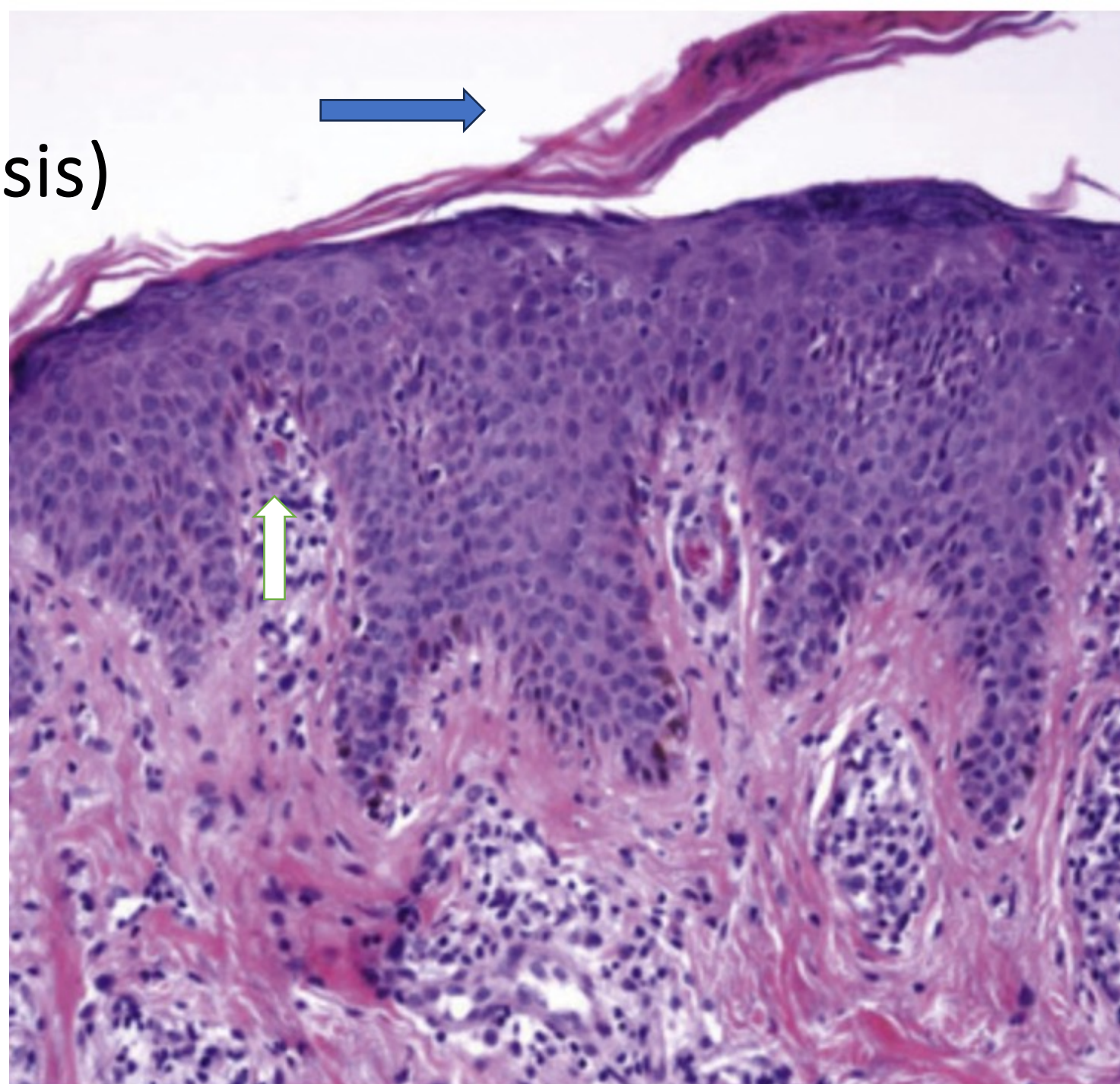
- Follicular, pruritic, popular eruption on the trunk and proximal extremities
- Young adult African-American men
- Resembles atopic dermatitis (on the trunk)
- Spongiosis of follicular infundibulum
- Exocytosis of lymphocytes
- Parakeratosis overlie follicular ostium
- Increased mast cells

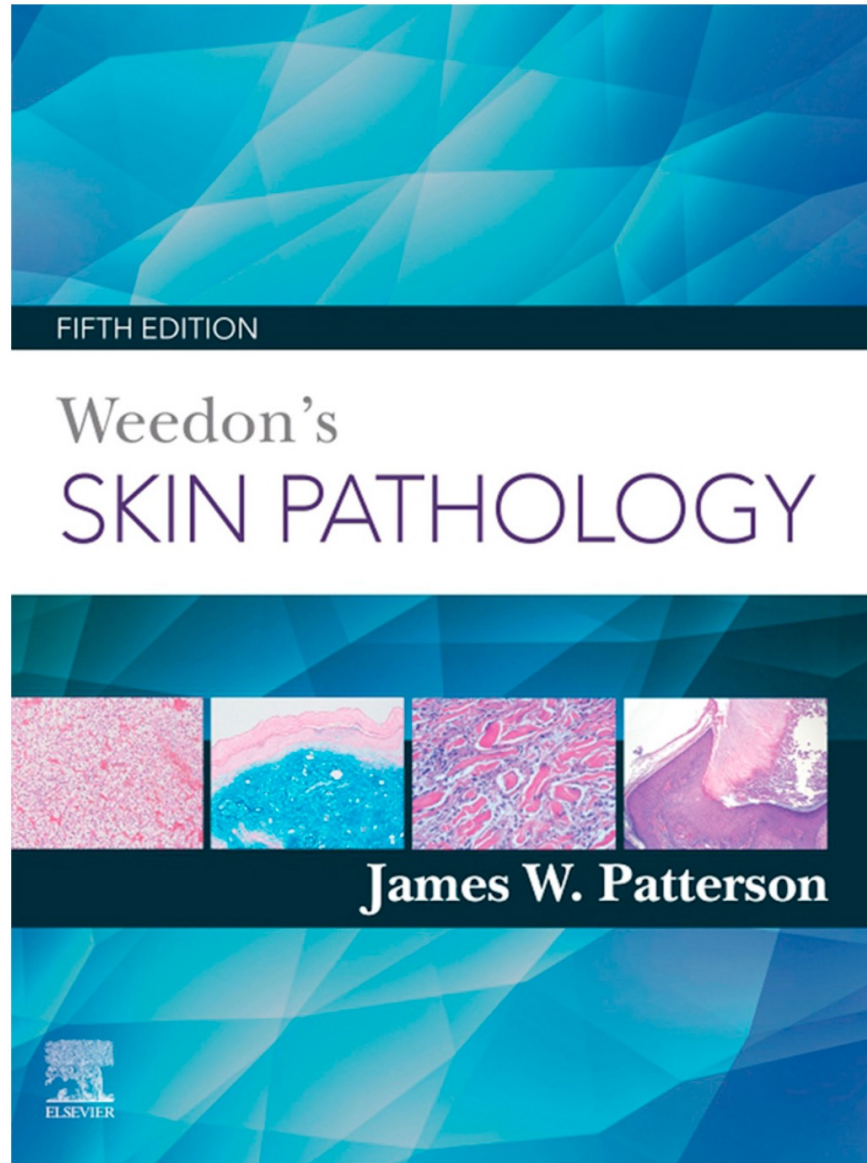




# Pityriasis rosea (Pityriasiform spongiosis)

- Acute, self-limiting dermatosis
- Discrete oval, salmon-pink papulosquamous lesions with collarette scaling
- Trunk, neck and extremities
- Non-specific undulating epidermis
- Tilted mounds of parakeratosis
- Red cells in papillary dermis





# References

---

- Weedon's skin pathology
- McKee's pathology of the skin
- Dermatopathology, Elston