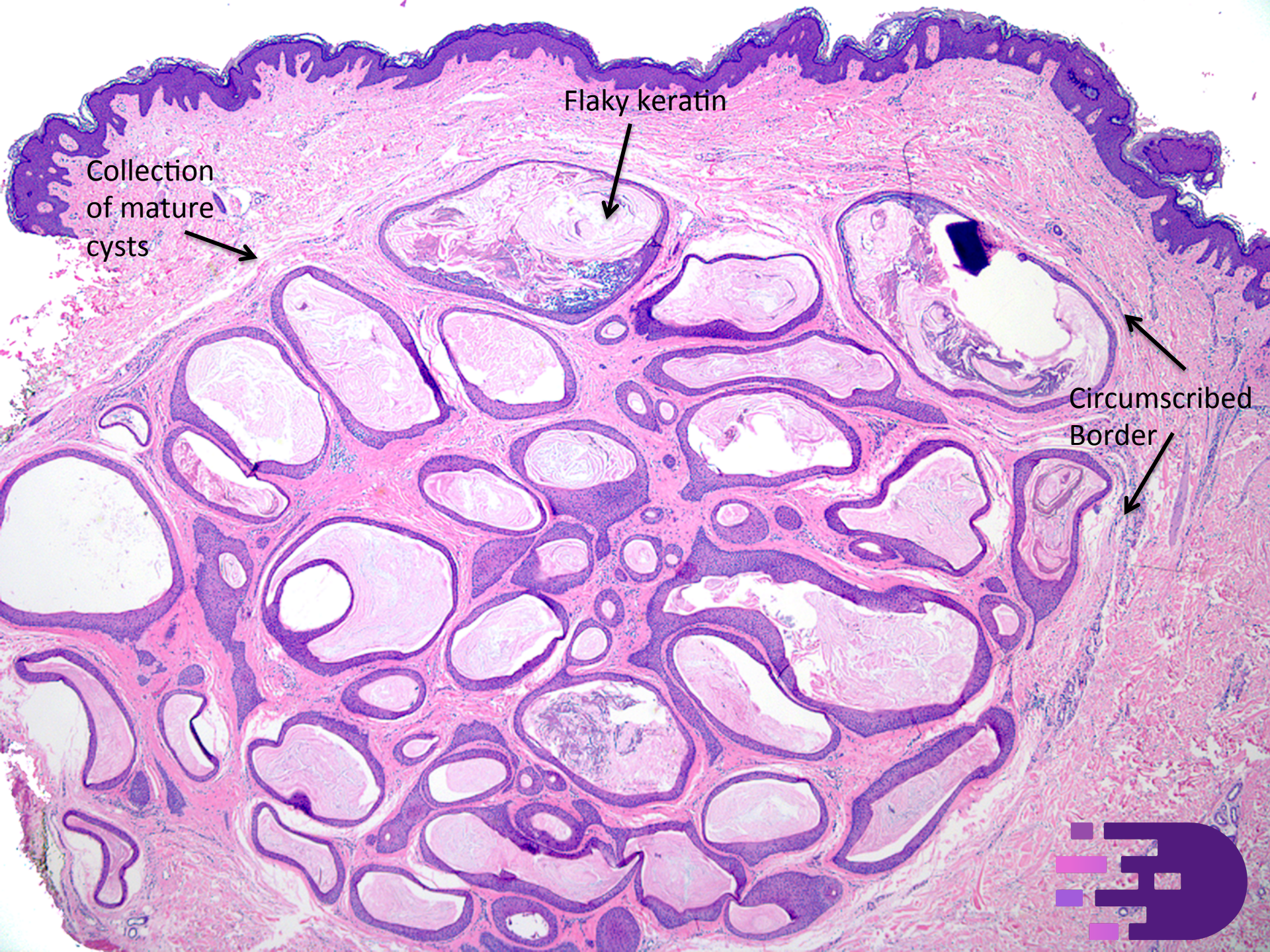
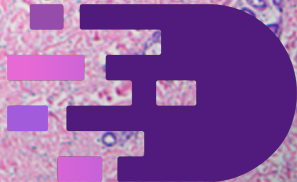
Flaky keratin

Collection
of mature
cysts

Circumscribed
Border



- **Clinical information:** Solitary nodule, 71/M left lower gluteus

- **DIAGNOSIS:**

- SKIN, LEFT LOWER GLUTEUS, EXCISION: TRICHOADENOMA

- **Teaching Points:**


- On face, sometimes buttocks
- Benign adnexal neoplasm
- Resembles infundibula of hair follicle
- No margin status or further therapy needed

- **Minimal Diagnostic Criteria:**

- Collection of well-circumscribed small cysts
- No infiltration of surrounding stroma
- Cyst lining resembles keratinization of epidermis
- Fibrotic stroma in between cysts

- **Differential Diagnosis:**

- Trichofolliculoma
- Nevus comedonicus
- Syringoma



DIGITAL SKIN PATHOLOGY (DiSK)
Learn Histologic Diagnosis Case-By-Case

