

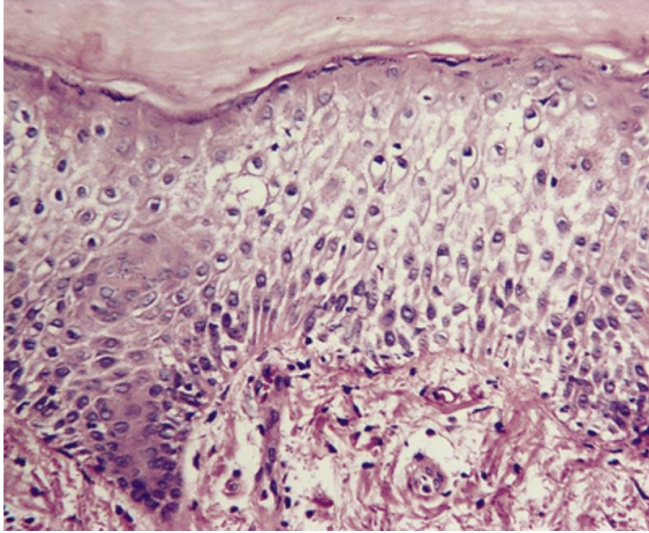
# Vasculitis and related disorders

Soheil S Dadras MD-PhD

October 16, 2023

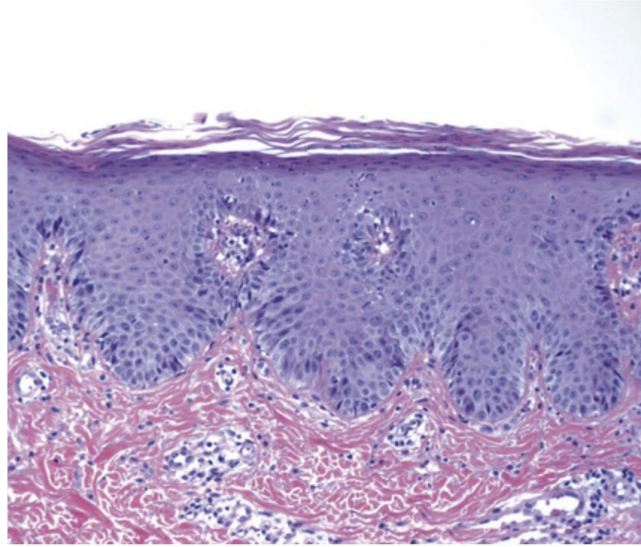


# Tissue reaction patterns



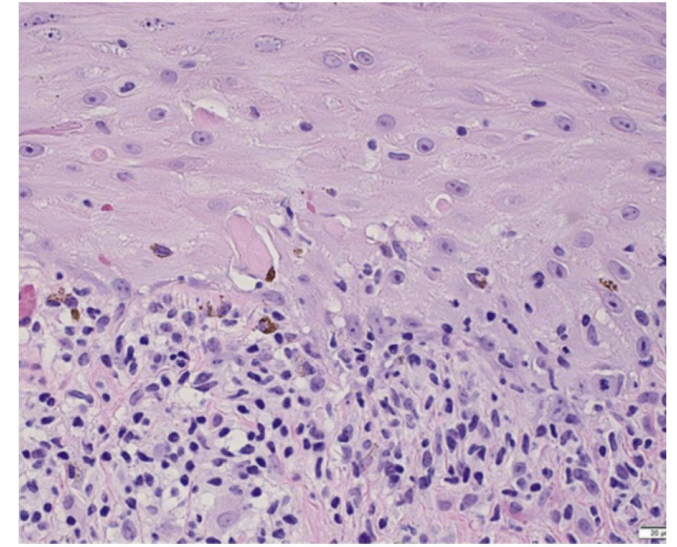
Atopic dermatitis

Spongiotic



Psoriasis

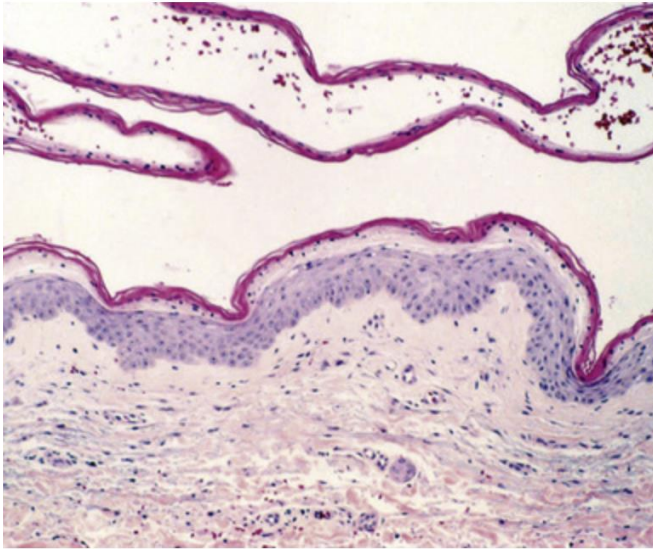
Psoriasiform



Lichen planus

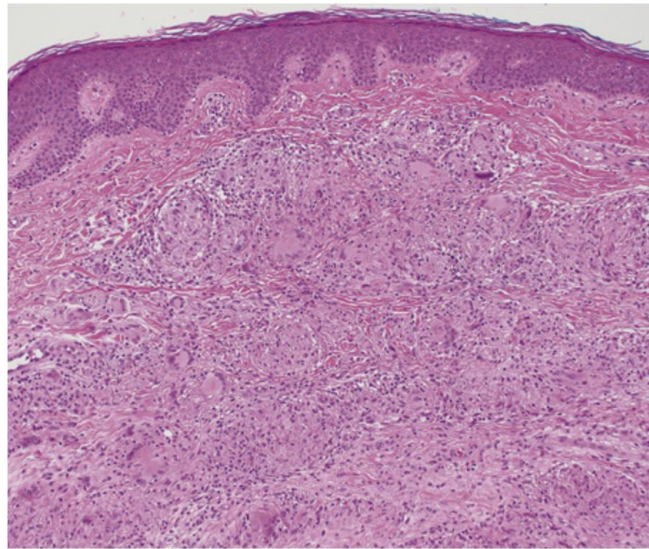
Lichenoid

# Tissue reaction patterns



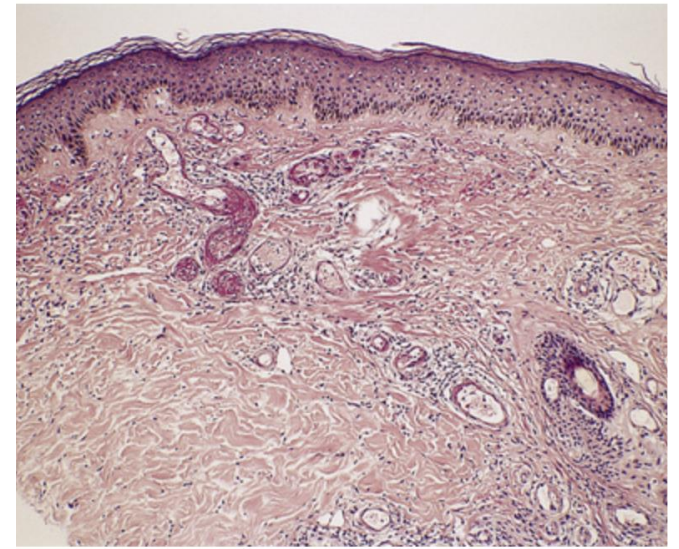
Bullous pemphigoid

Vesiculobullous



Granuloma annulare

Granulomatous

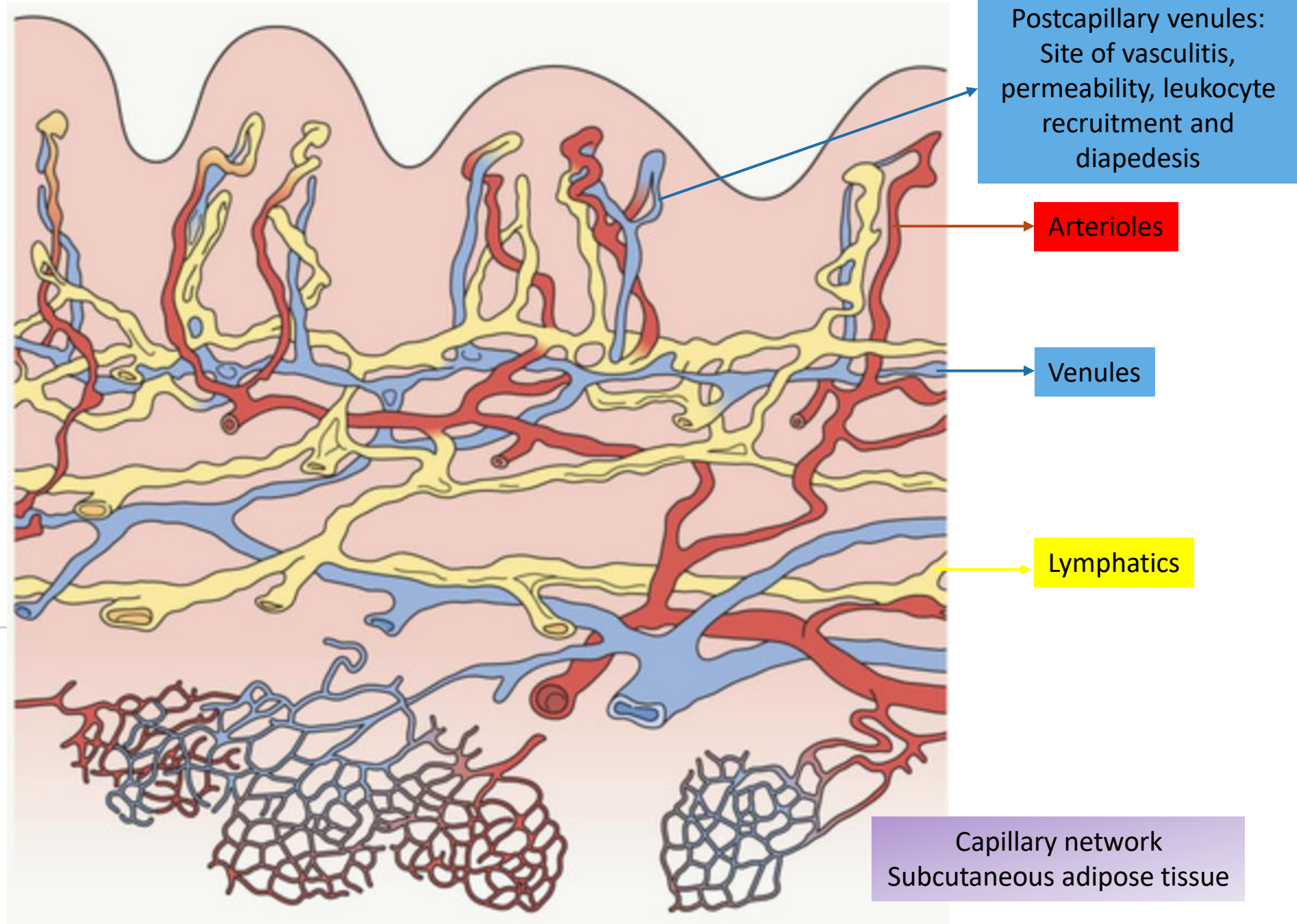


Atrophie blanche

Vasculopathic



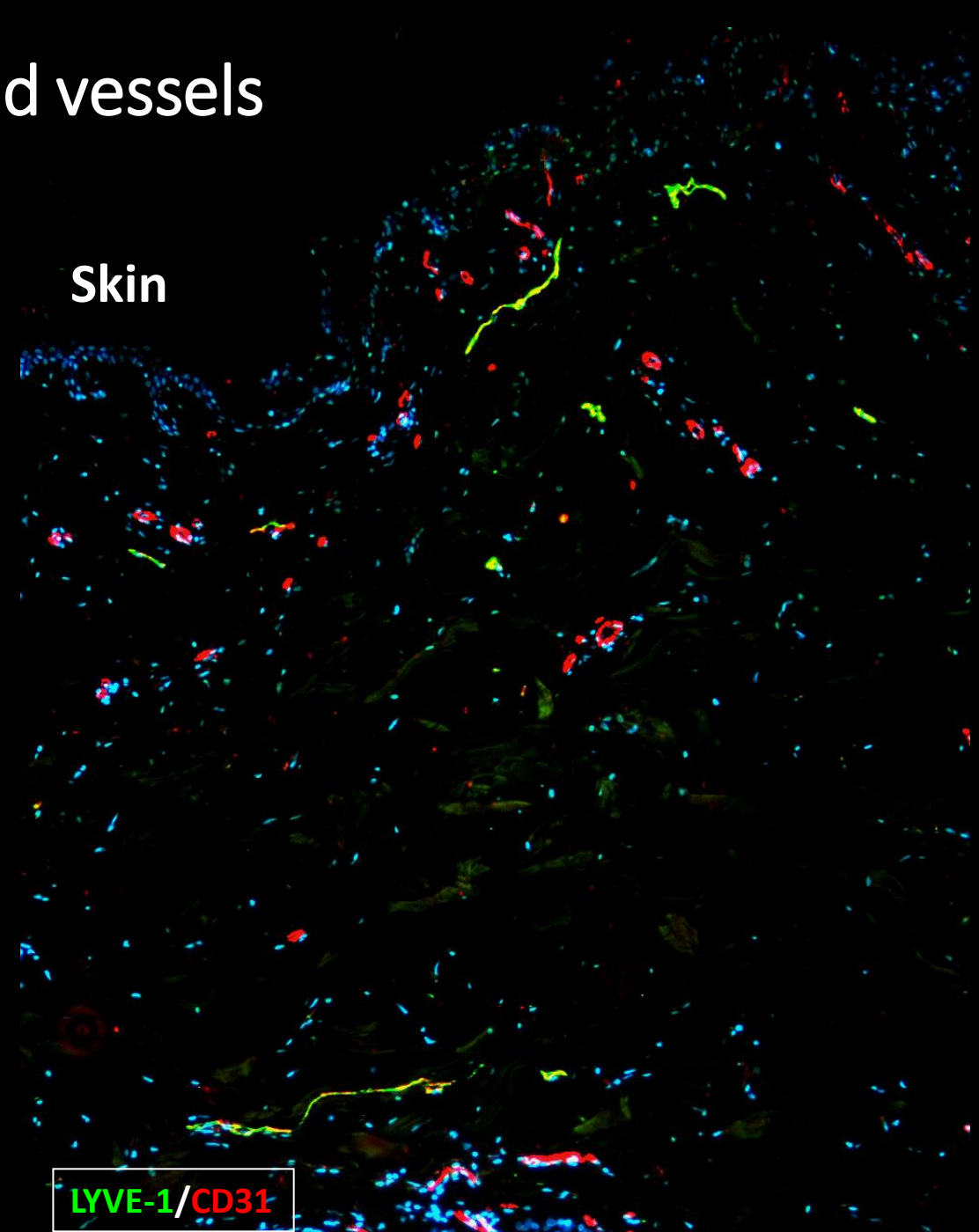
# Cutaneous vascular system



# Immunohistochemical markers for blood vessels and lymphatics

Marker	Lymphatic Vessels	Blood Vessels
<i>Blood Vascular Specific</i>		
CD34	-	+
CD44	-	+
PAL-E	-	+
Collagen type IV	-(+)	+
Collagen type XVIII	-(+)	+
Laminin	-(+)	++
Neuropilin-1	-	+
<i>Lymphatic Specific</i>		
VEGFR-3	+	-
Podoplanin	+	-
SLC/CCL21	+	-
LYVE-1	+	-
Prox1	+	-
<i>Panvascular</i>		
CD31 (PECAM-1)	+	++
VEGFR-2	+	+
Factor VIII-related antigen	+	++

Dadras and Detmar, *Hem. Onc. of North Ame.* 2004

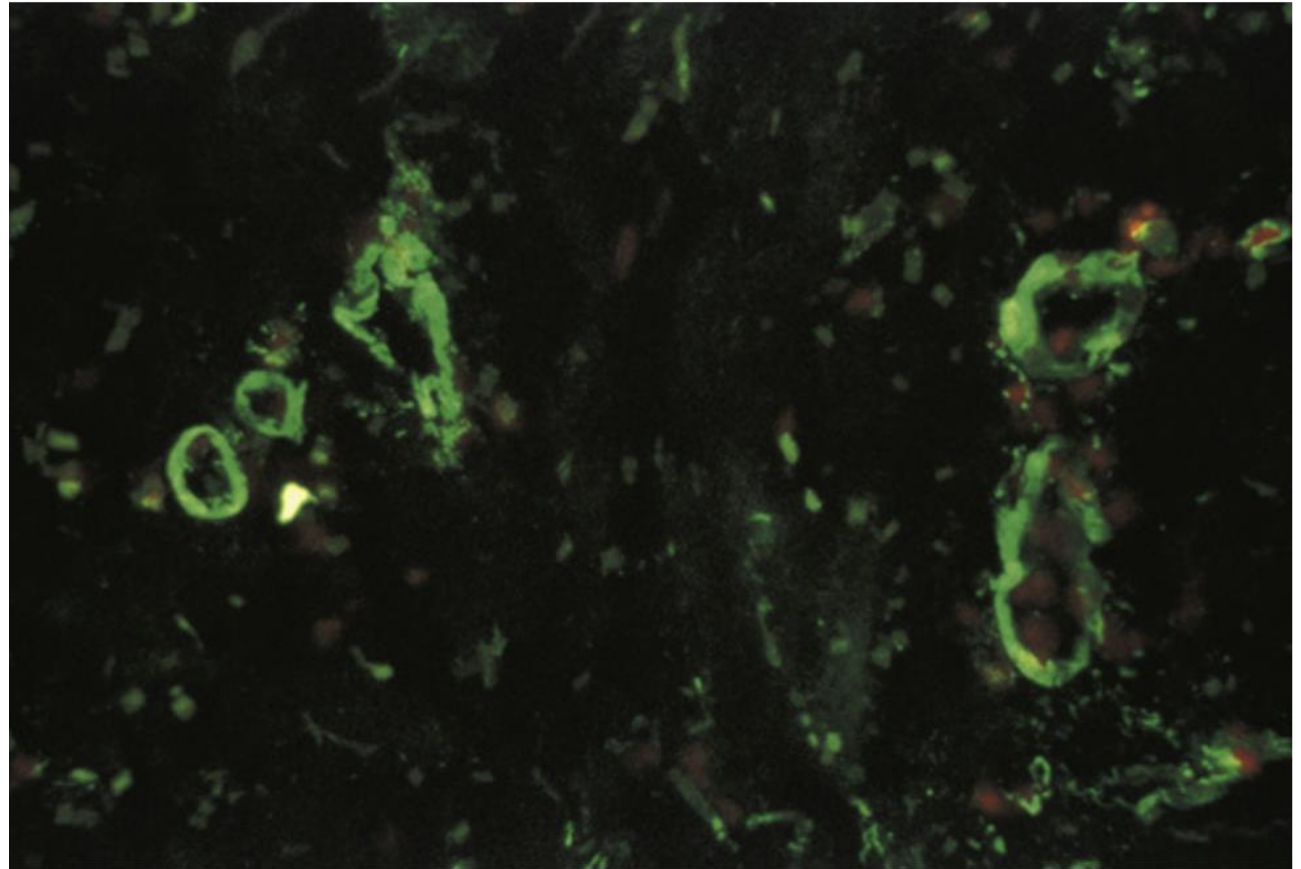


# Diagnostic approach to vasculitis

- Is there vasculitis or vasculopathy?
- Is the process cutaneous or systemic?
- Is the vascular injury primary or secondary?
- What is the size and the type of vessel involved?
  - Small, medium or large?
- What is the composition of the inflammatory infiltrate?
  - Neutrophilic, lymphocytic, eosinophilic, or granulomatous
- What are the associated findings?
  - Infection (special stains and microbial cultures)?
  - Plasma cells (spirochete)?
  - Viral infection (HSV vascular changes)?
  - Suggestion of connective tissue disease (interface dermatitis or dermal mucin)
  - Edema (urticarial reaction)
  - Serologic studies: ANA, ANCA, RF, cryoglobulins, DIF
  - Clinical context: demographics and presentation, other signs/symptoms

# Diagnostic approach to make/confirm vasculitis or vascular damage

- The damage could involve blood vessels in the deep dermis or subcutis
- Histologic evaluation: Perform punch (NOT shave) skin biopsy to include deep reticular dermis and subcutaneous tissue
- Direct immunofluorescence
  - Vascular pattern of immunoglobulins and complements (C3)
- PAS and elastic special stains
- IHC: smooth muscle actin



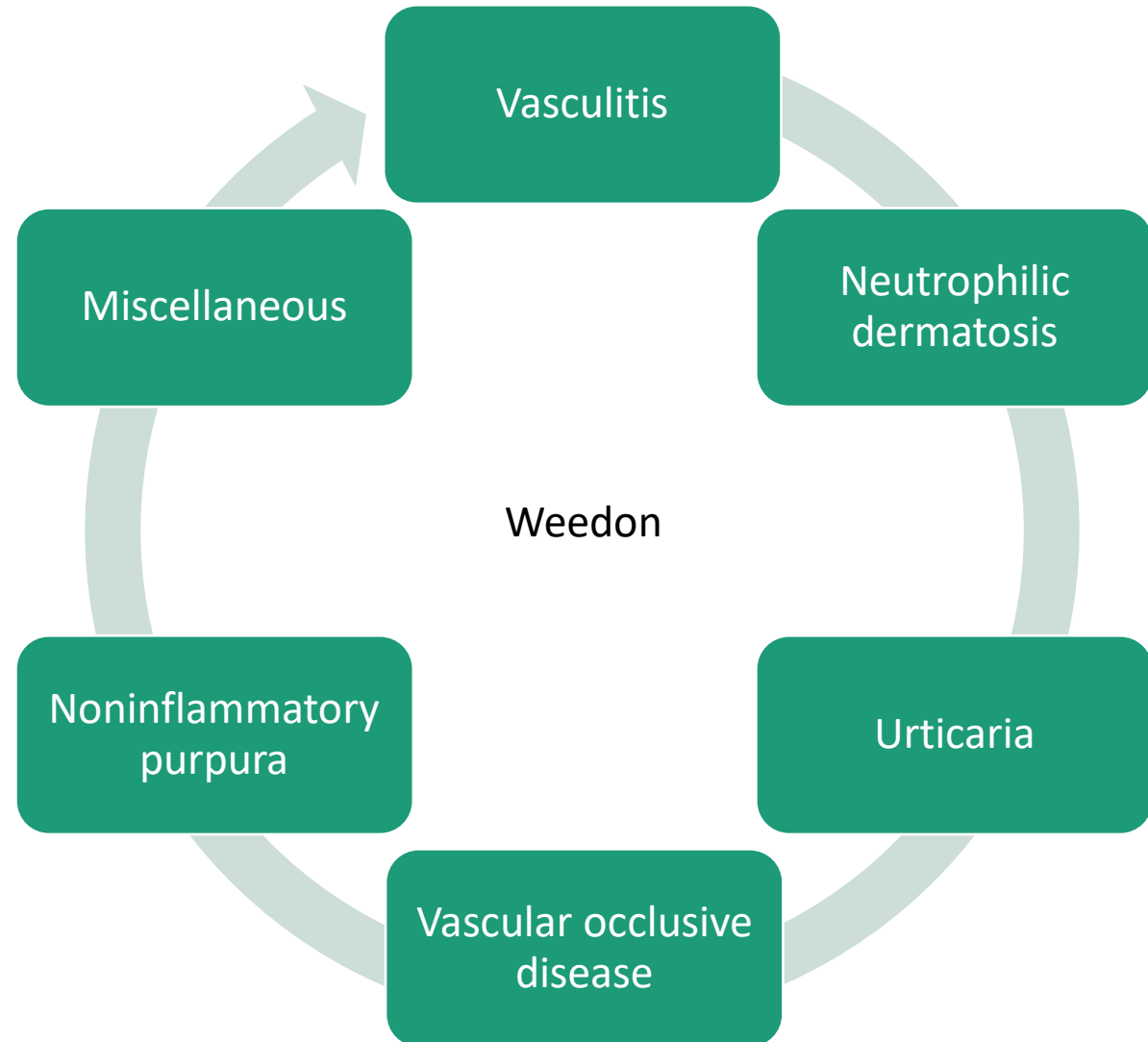
Leukocytoclastic vasculitis: IgM in the luminal surface of blood vessels



# Categorization of disease of blood vessels

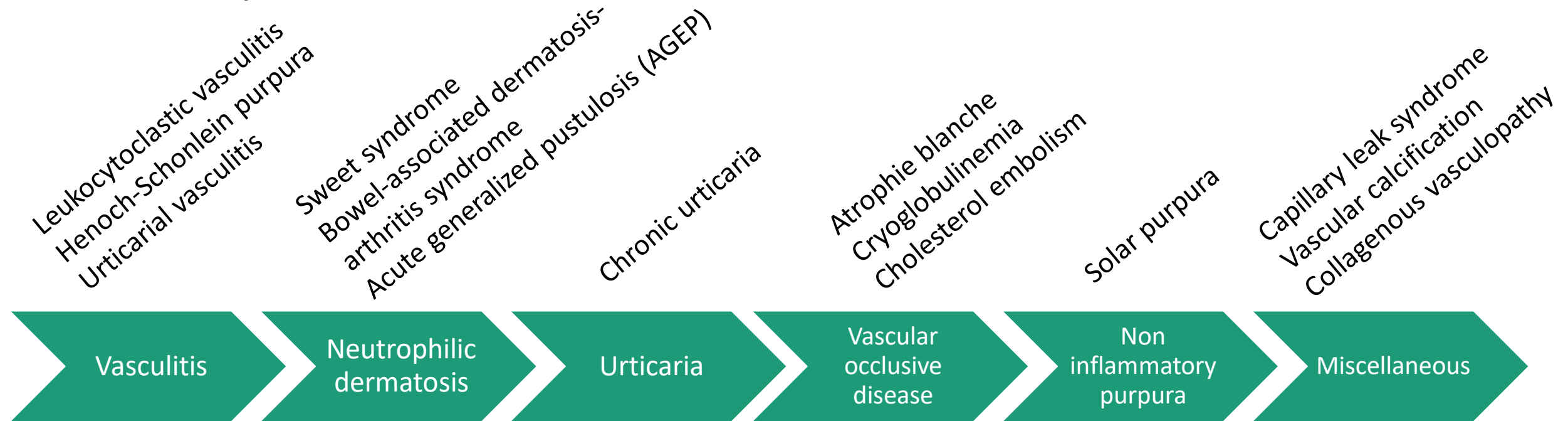
## Types and definitions of vasculitis

- Adopted by the 2012 Chapel Hill Consensus Conference
- List of clinical criteria and disease nomenclature
- Classified according to the type and size of the vessels
  - e.g., polyarteritis nodosa is under medium vessel vasculitis





# Conceptual overview: Vasculitis and related disorders



Fibrinoid necrosis and  
Inflammation

# Clinical and histologic definitions

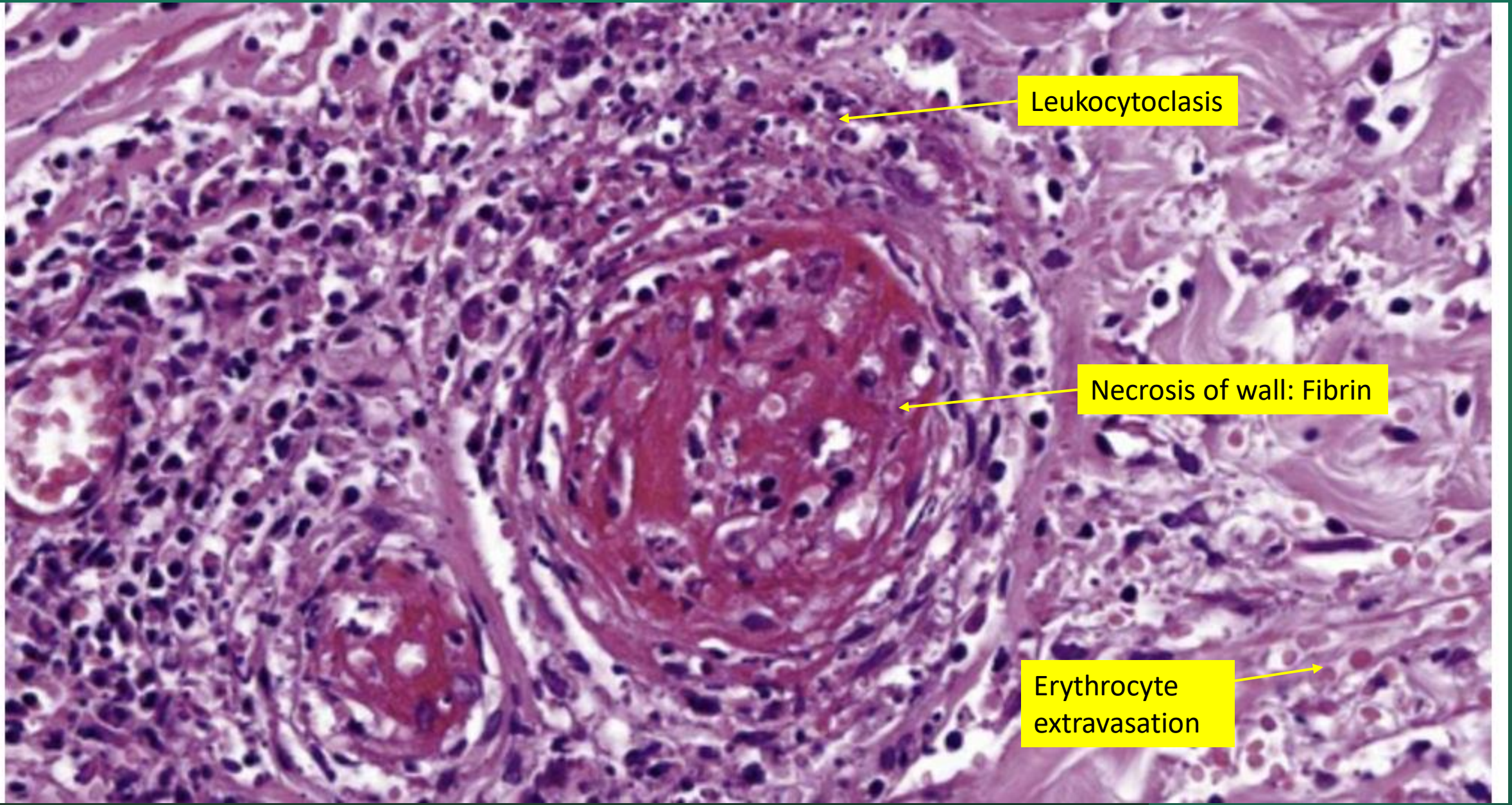
## Clinical

- Vascular damage:
  - Edema
  - Livedo reticularis (net-like pattern of red-blue skin discoloration)
  - Subcutaneous hemorrhage, or purpura
    - Petechiae, < 3-mm diameter
    - Ecchymoses, larger
    - Palpable purpura (raised, inflammatory infiltrate) [Punch Biopsy]
- Severe
  - Vascular occlusion --> ischemia --> necrosis --> gangrene --> ulceration

## Histologic

- Necrosis of vessel wall with deposition of fibrinogen material
- Leukocytoclasia (nuclear debris from infiltrating neutrophils)
- Karyorrhexis (nuclear dust)
- Extravasation of erythrocytes
- Endothelial cell swelling
- Luminal thrombosis
- Edema





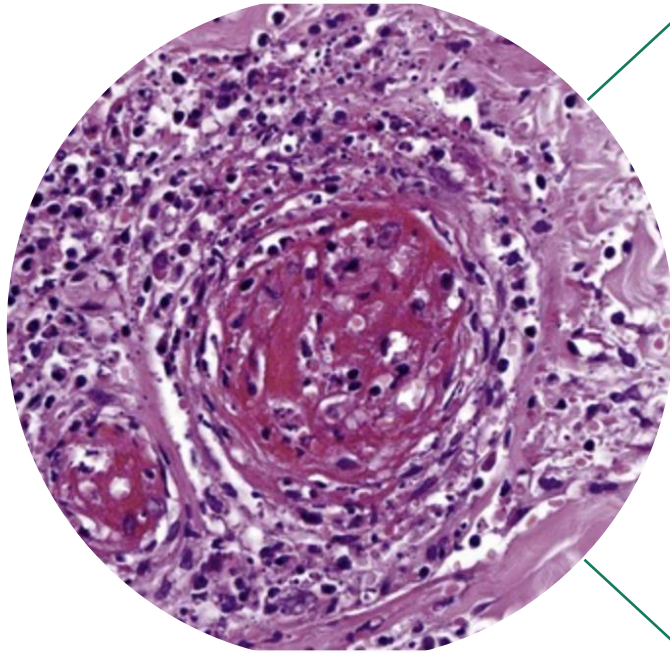
Leukocytoclasia

Necrosis of wall: Fibrin

Erythrocyte  
extravasation



# Small-vessel vasculitis



Leukocytoclastic vasculitis

- Bacterial/Rickettsial/fungal/viral
- Immune-complex
  - Henoch-Schoenlein purpura
  - Urticarial vasculitis
- Infection associated
- Drug induced
- Etc.

ANCA Associated vasculitis

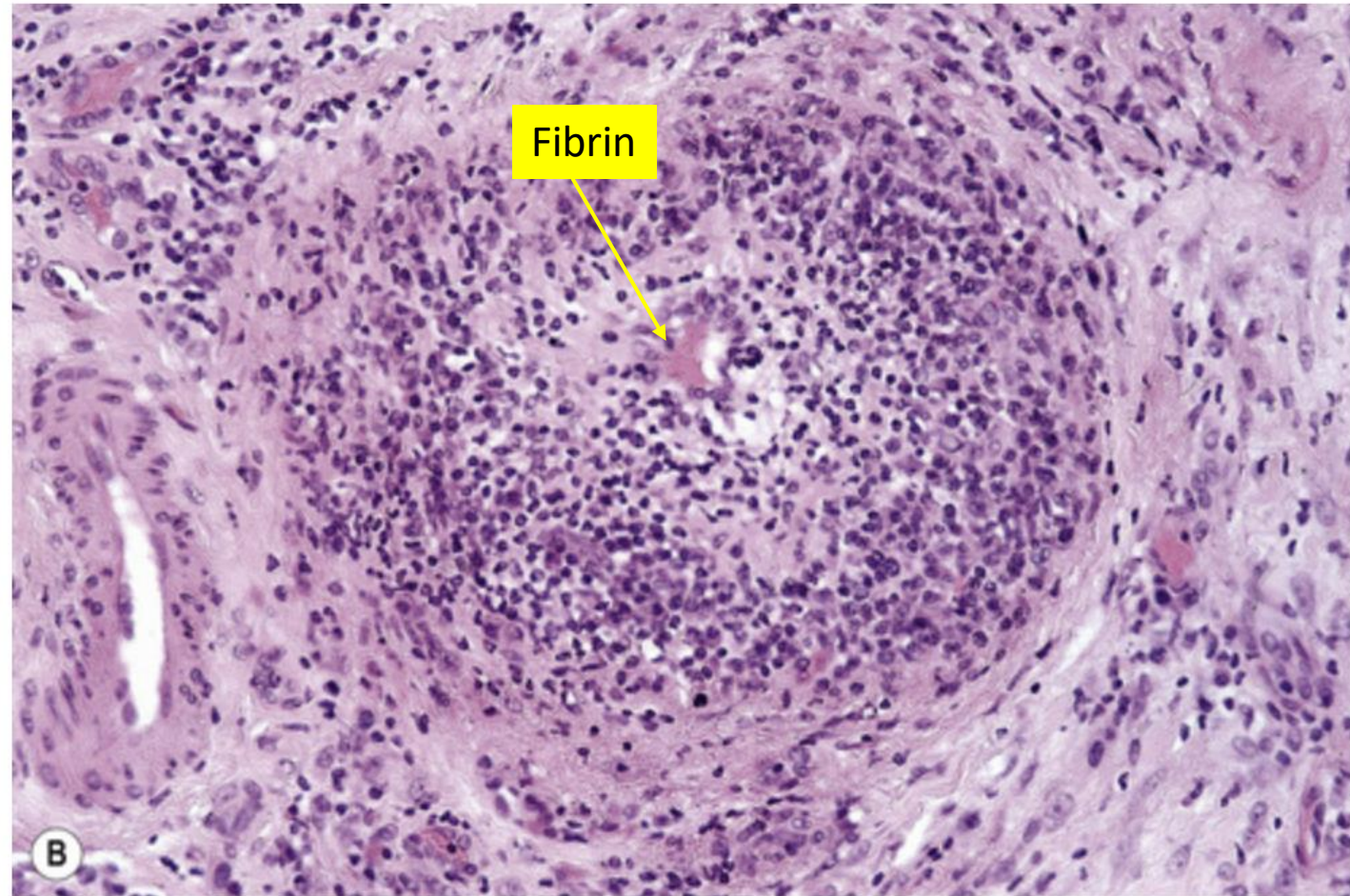
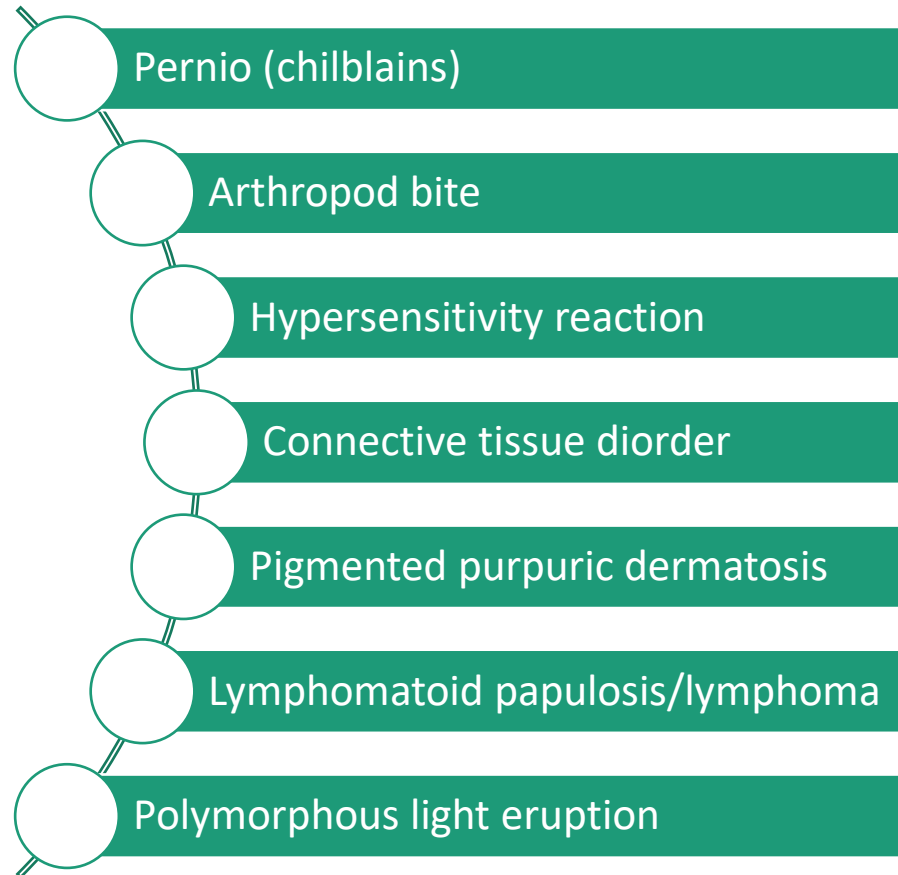
- Wegner granulomatosis
- Microscopic polyarteritis
- Churg-Strauss syndrome

Localized fibrosing vasculitis

- Erythema elevatum diutinum
- Granuloma faciale



# Lymphocytic vasculitis: vascular damage + lymphocytes $\pm$ minimal fibrin

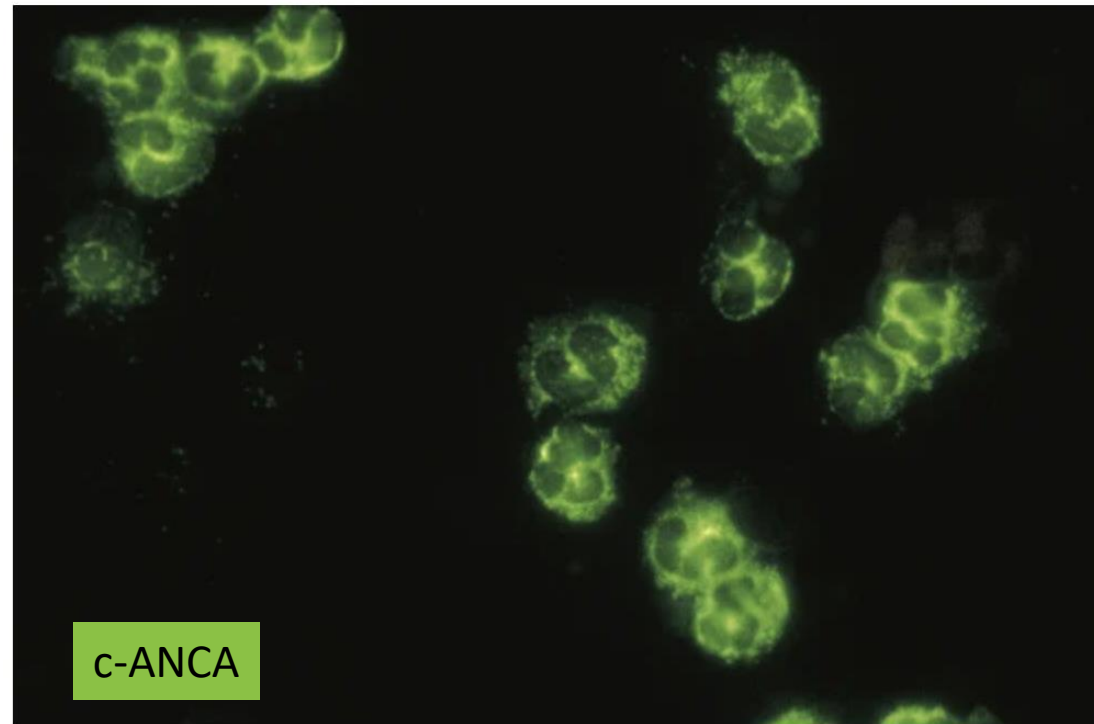
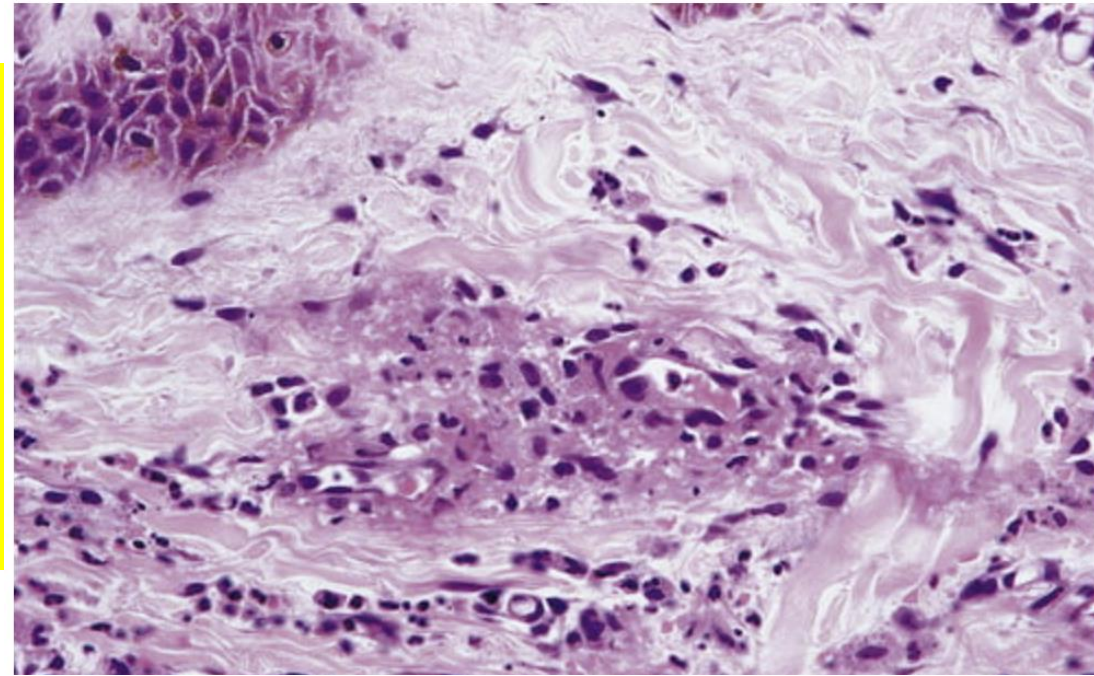


Numerous lymphocytes surround a blood vessel; no leukocytoclasia

# Antineutrophil cytoplasmic antibodies (ANCA)-associated systemic vasculitis

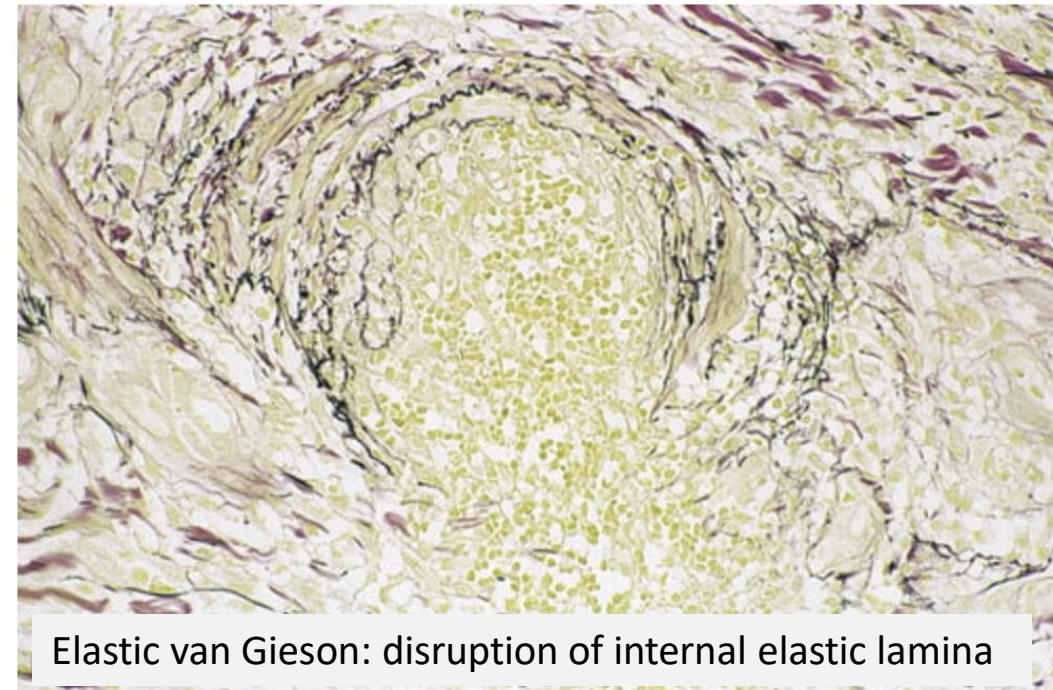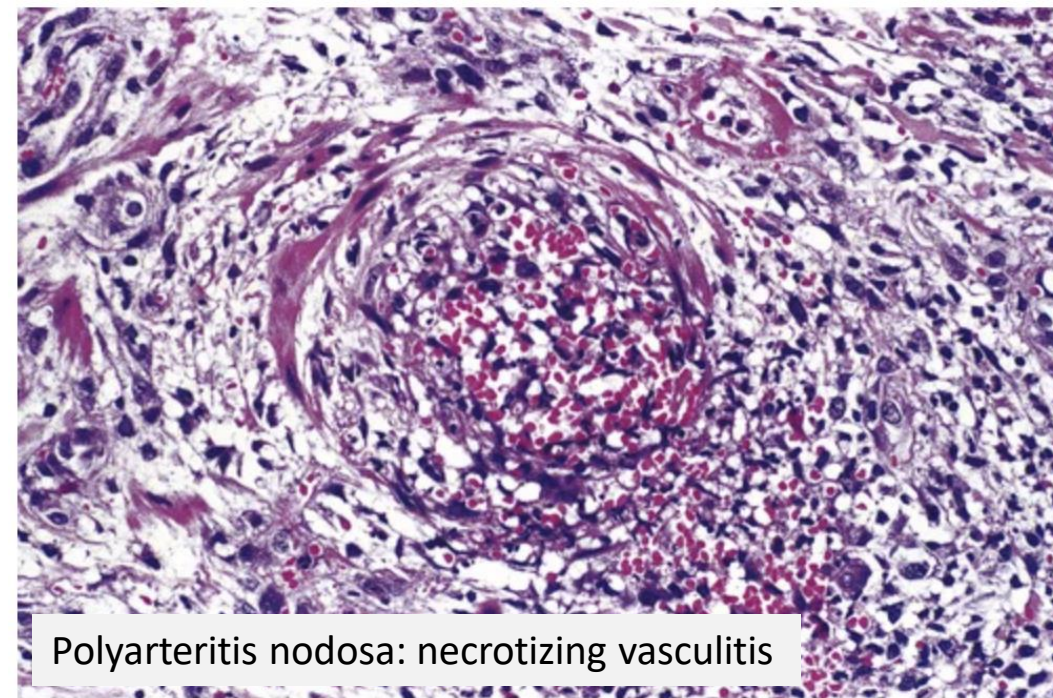
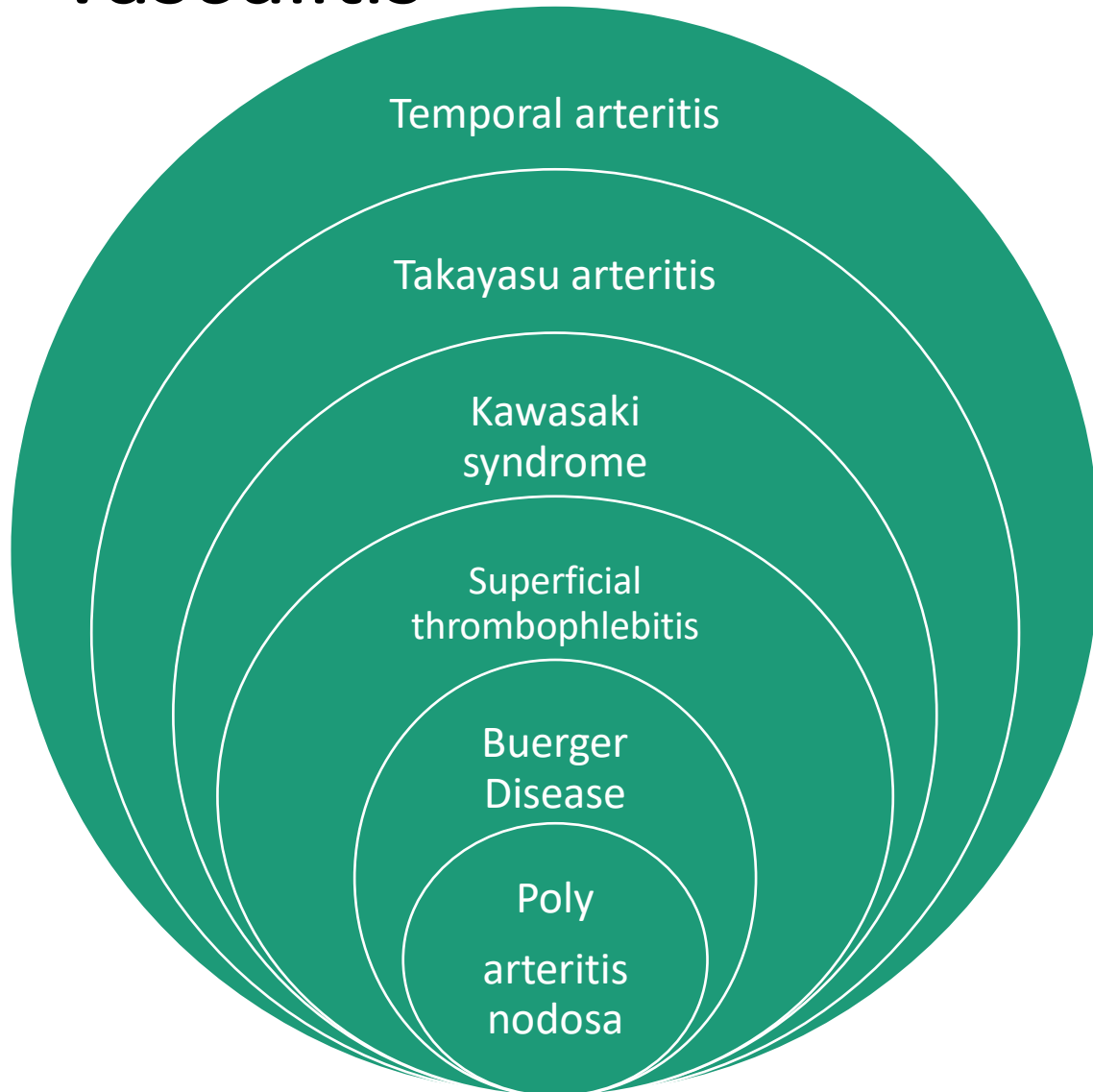
- Serologic marker to detect specific autoantibody
- Indirect immunofluorescence (IIF) of normal peripheral blood neutrophils
- Followed by enzyme-linked immunosorbent assay (ELISA)
- IIF two patterns:
  - Cytoplasmic (c-ANCA); proteinase 3
  - Perinuclear (p-ANCA); myeloperoxidase

Granulomatosis with polyangiitis (Wegener)



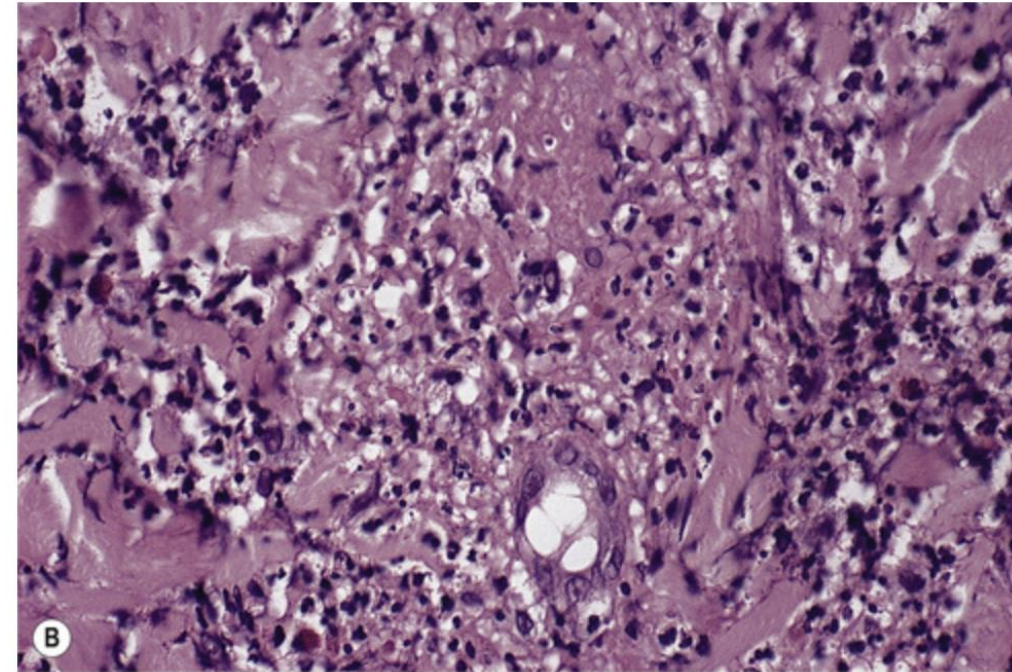
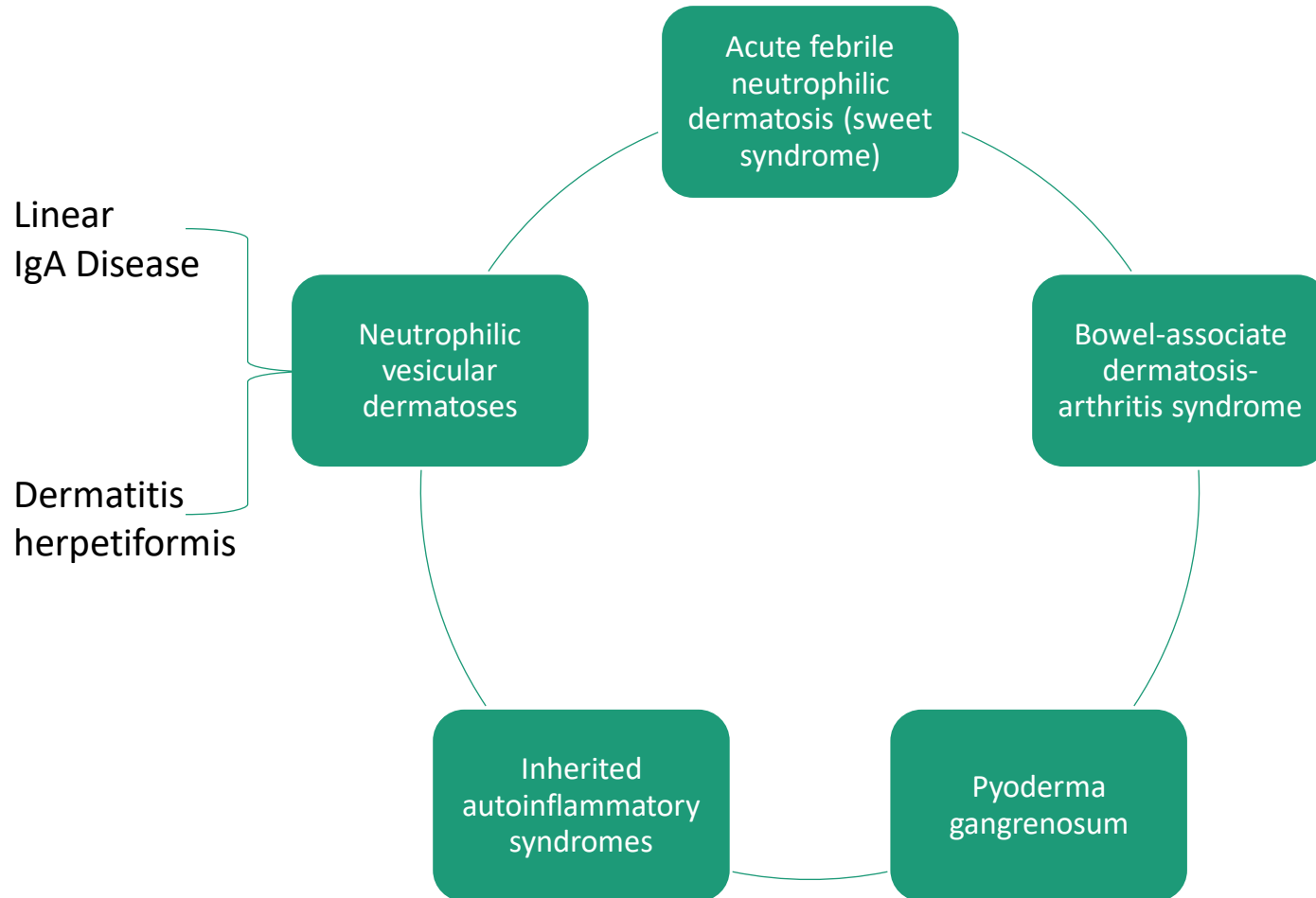


# Medium and large-sized vasculitis





# Neutrophilic dermatoses: Neutrophilic vascular reaction (not necrotizing vasculitis)



Sweet syndrome: numerous neutrophils surrounding blood vessel, no fibrinoid necrosis



Vascular occlusive disease:  
vasculopathic reaction and  
pseudovasculitis

Cryoglobulinemia

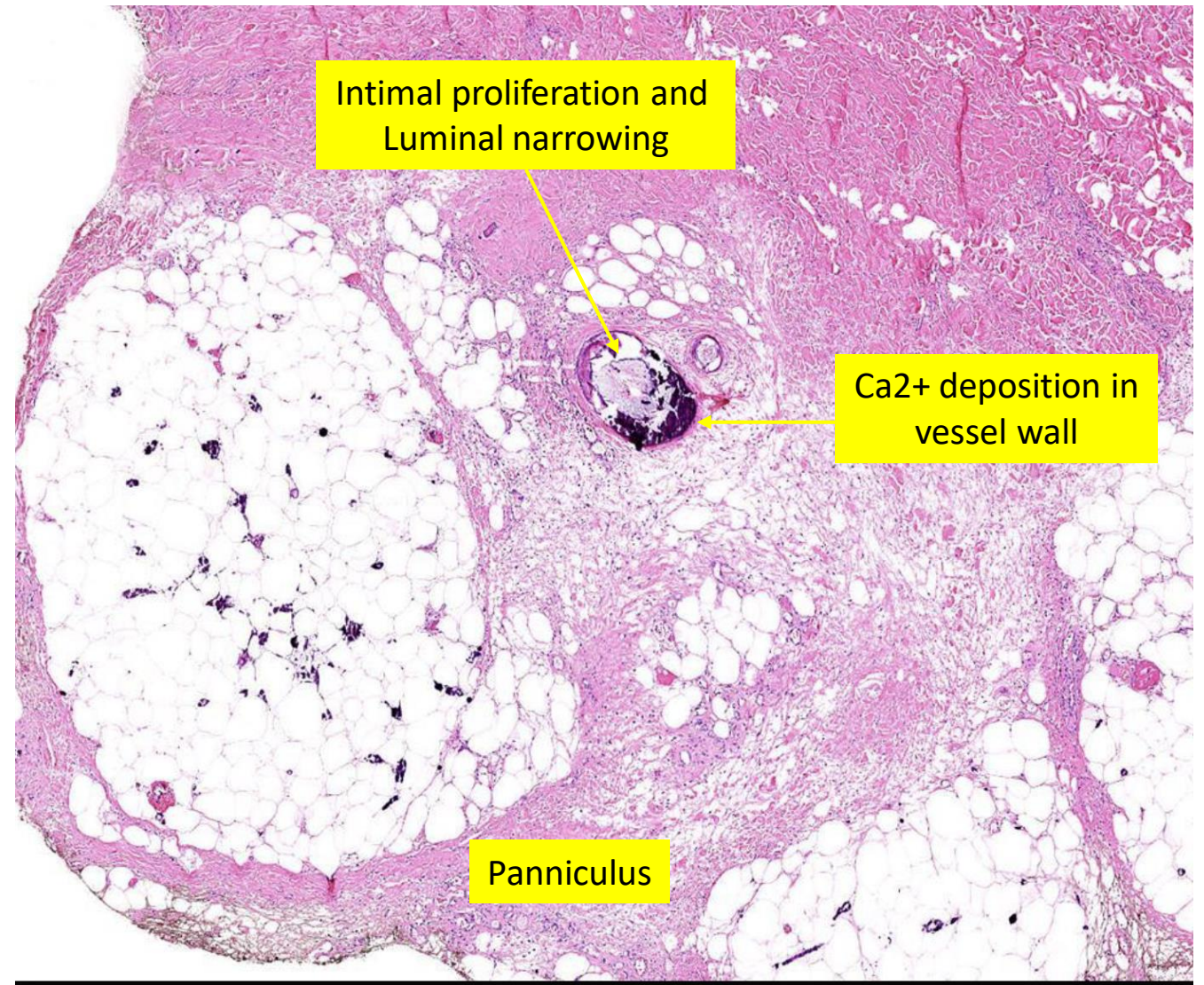
Cholesterol embolism

Livedo reticularis

Atrophie blanche

Degos syndrome

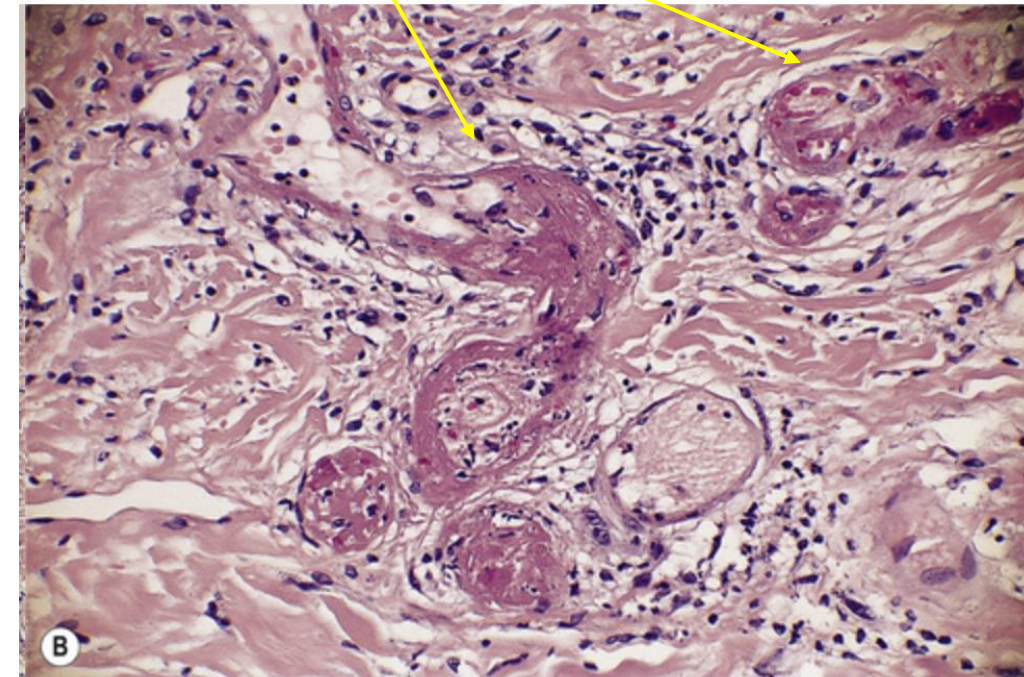
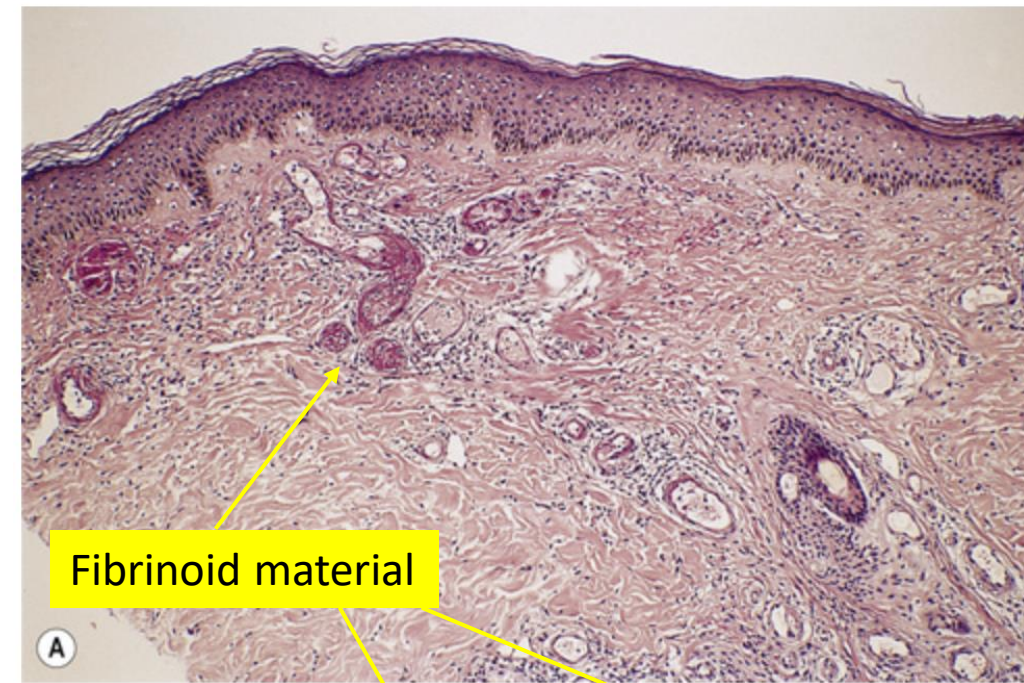
Calciophylaxis





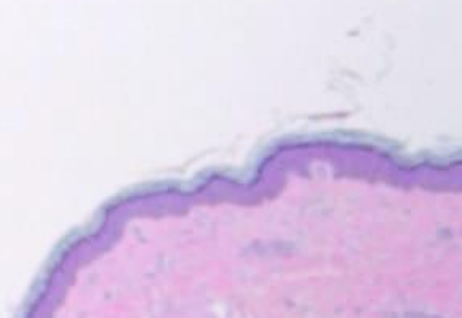
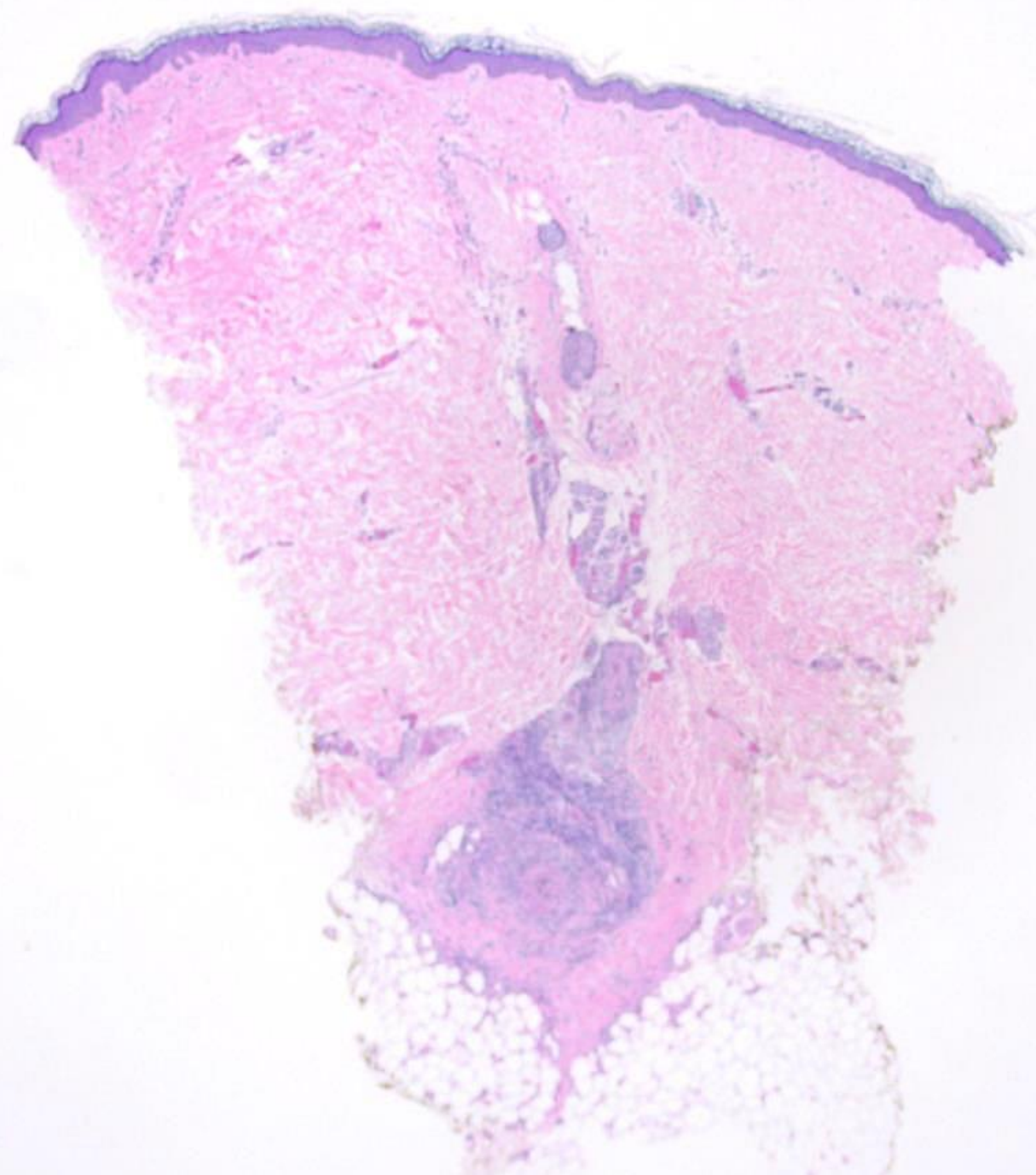
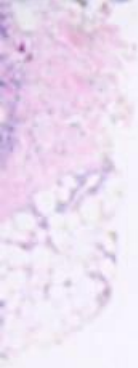# Atrophie blanche (livedoid vasculopathy) white atrophy

- Thrombogenic vasculopathy
- Decreased fibrinolytic activity (tissue plasminogen activator release defective)
- “Thrombogenic state” in several conditions
  - Lupus-type anticoagulant
  - Increased anticardiolipin antibody
- Painful, purpuric ulcers with reticular pattern on the lower extremities
- Histopathology:
  - Fibrinoid material
  - Minimal lymphocytic inflammation
  - Necrotic blood vessels
  - No Leukocytoclasia
  - Extravasation of erythrocytes
  - No edema

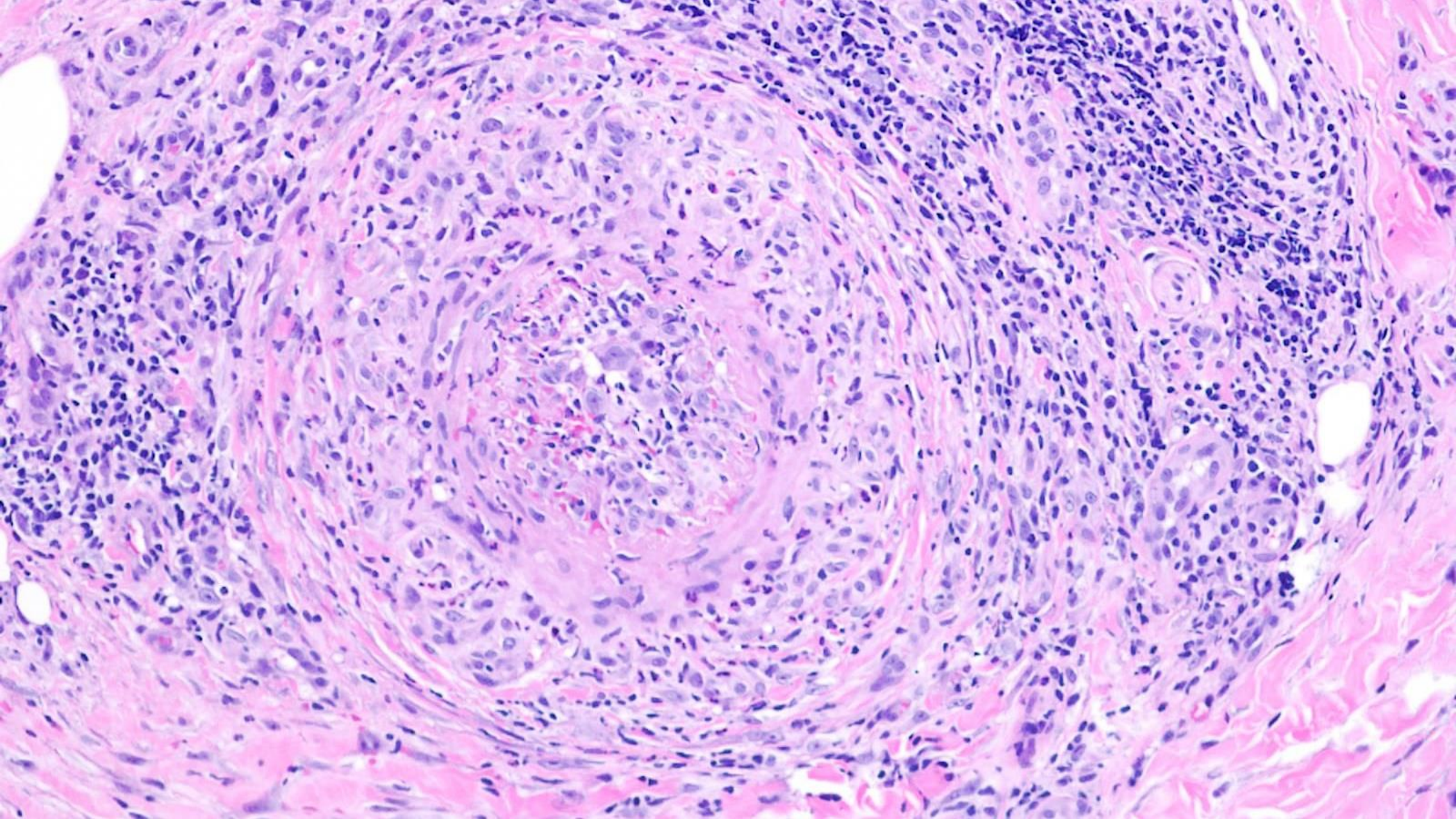


# Unknown cases

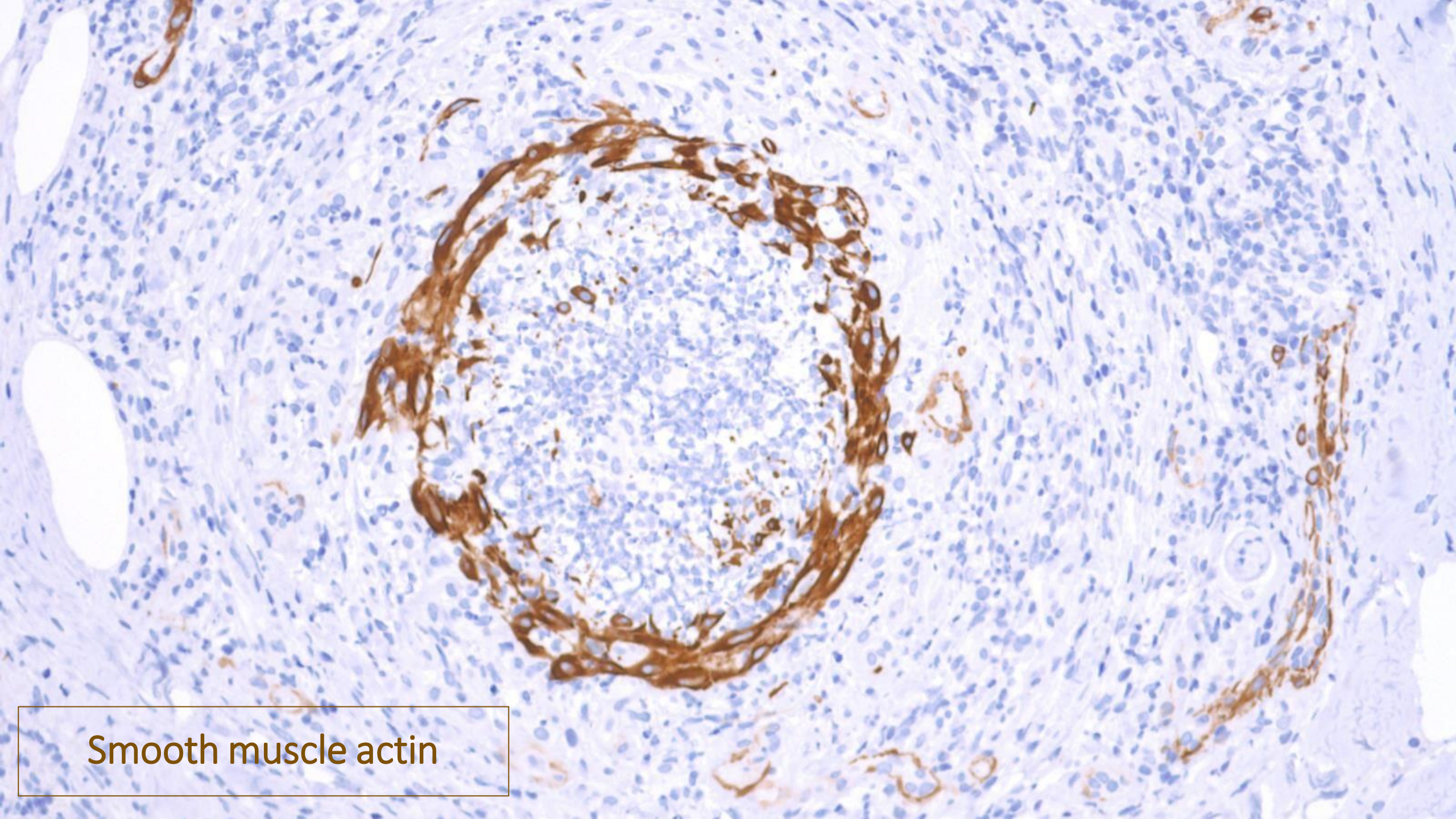
Will be available in full on <https://digitalskinpathology.com/>









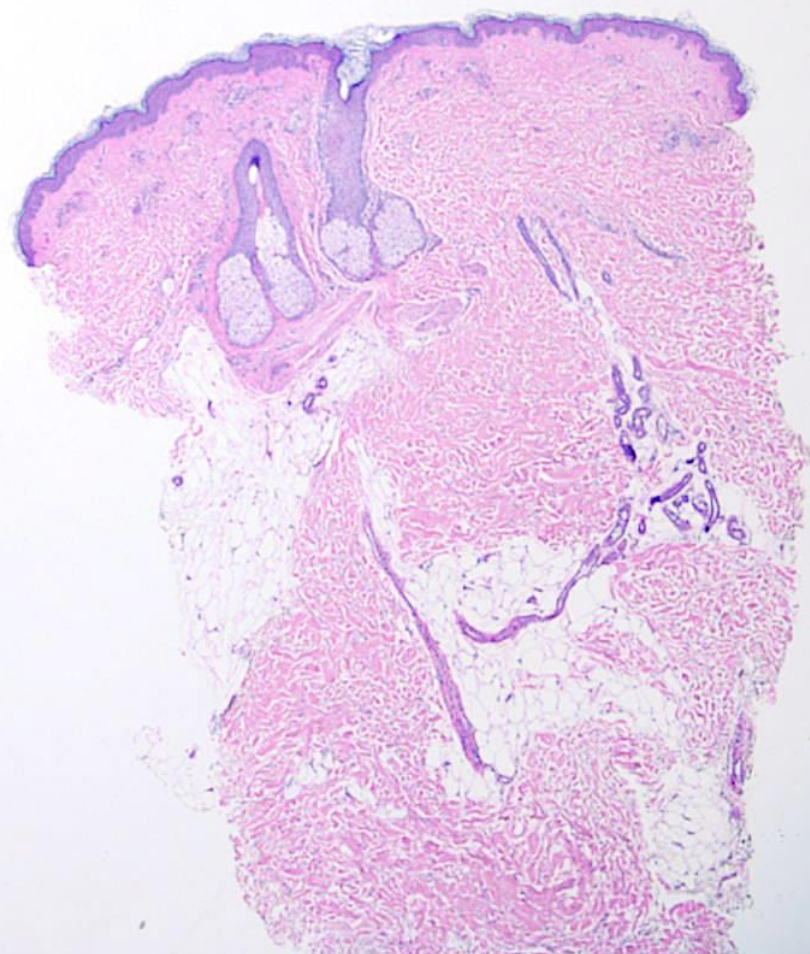
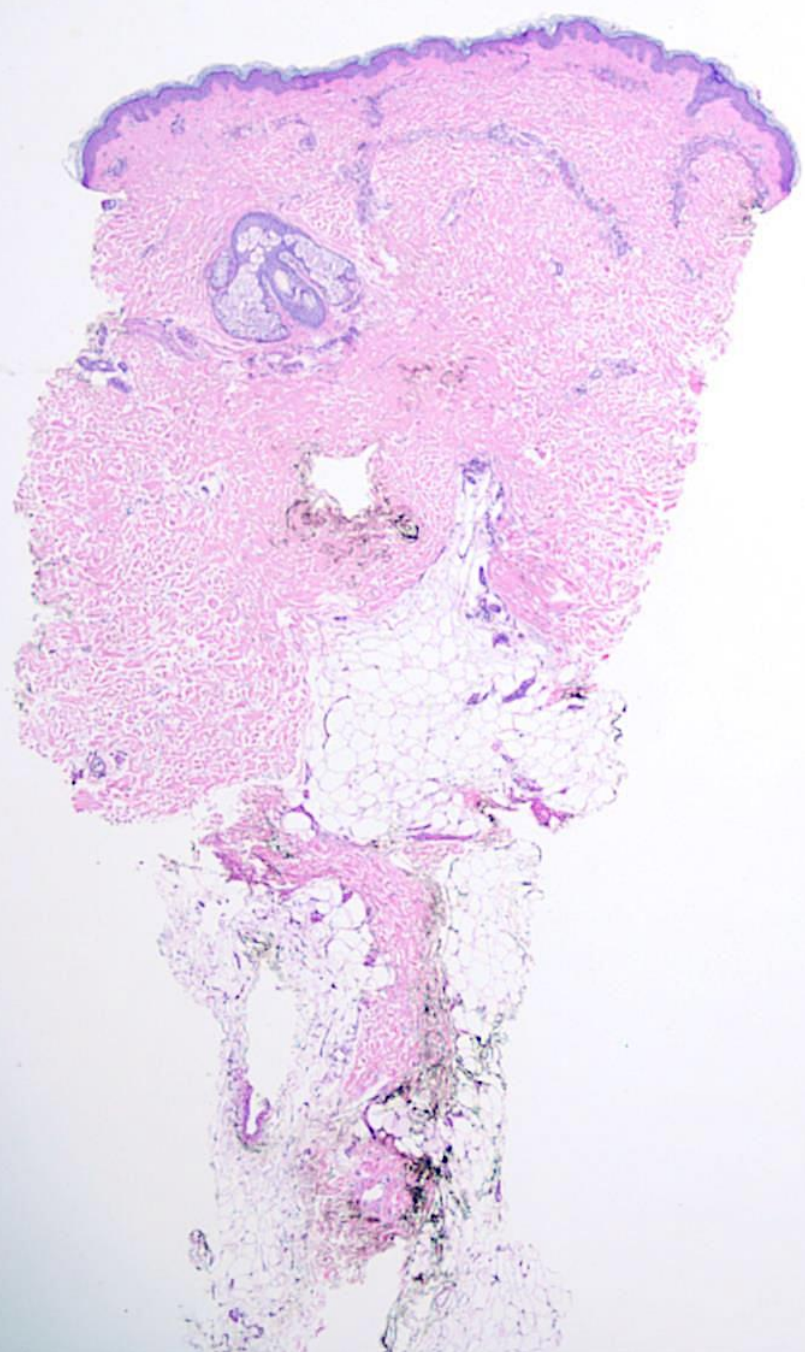


Smooth muscle actin

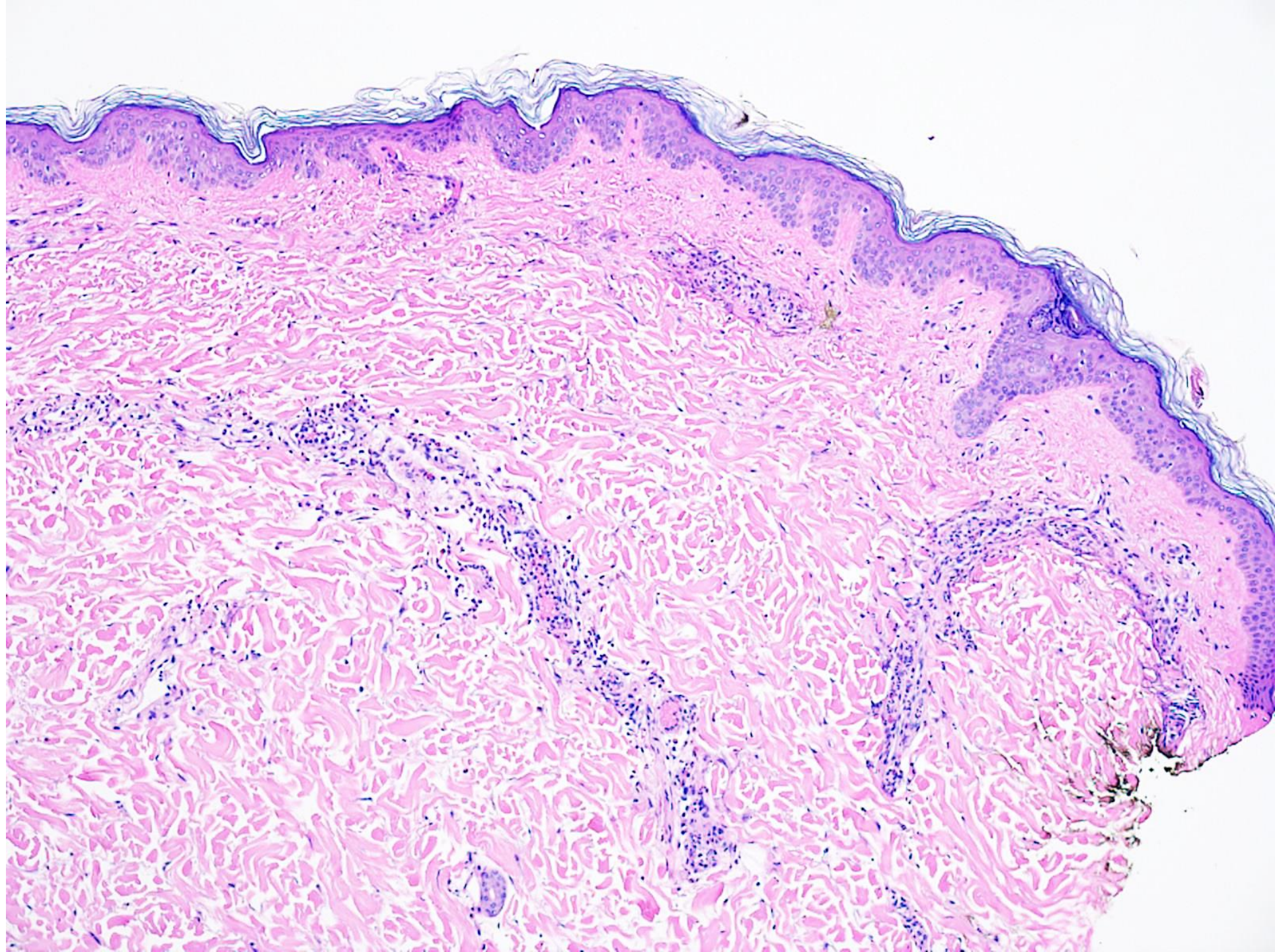


# Polyarteritis nodosa

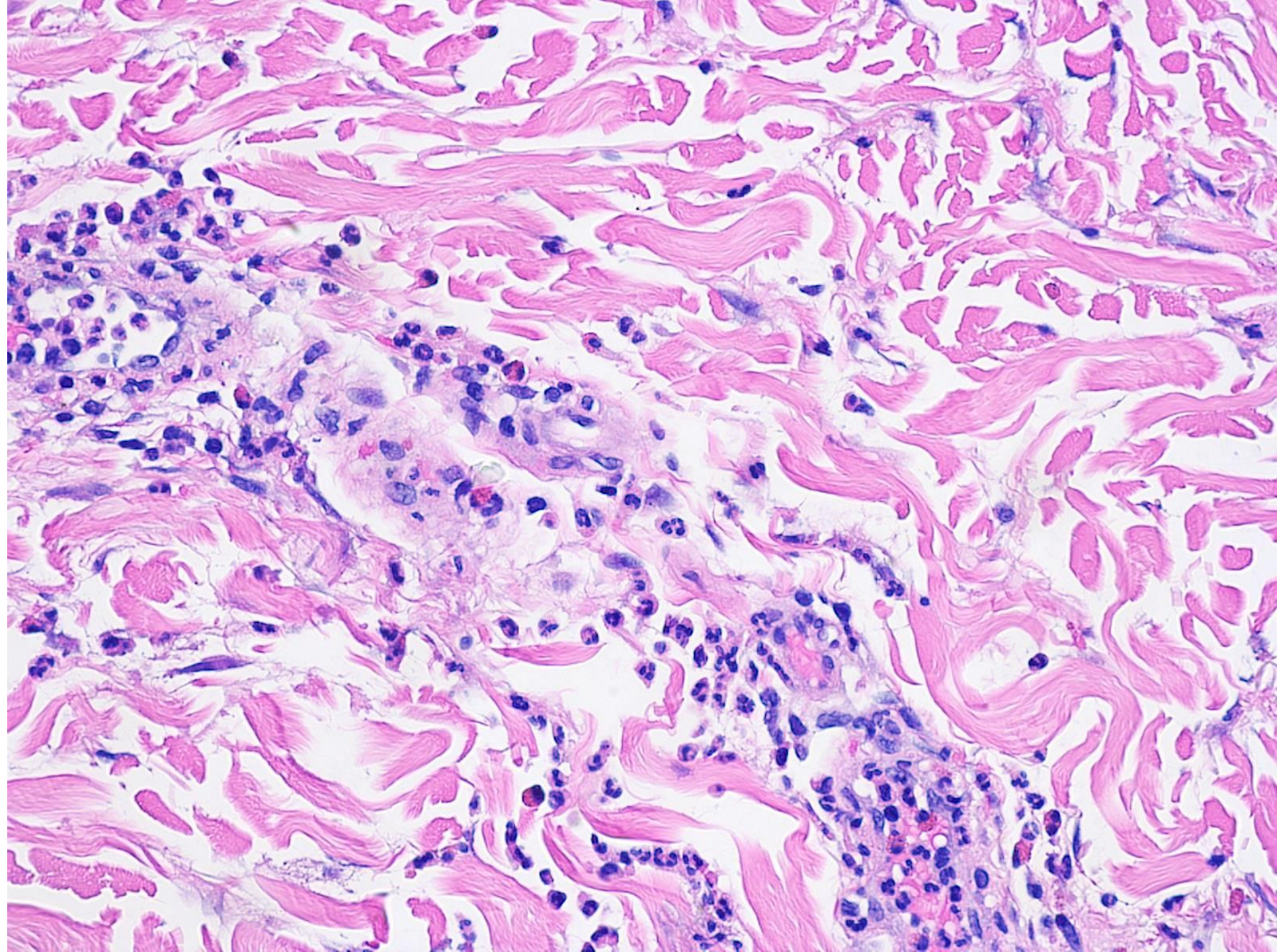
- 64/F LEFT ARM PUNCH with h/o NLD
- The pathology report pertaining to the prior biopsy from right leg/subcutaneous nodule is noted and reviewed (SGS-21-12351).
- The prior biopsy was sent to Dr. at UCSF Dermatopathology Laboratory for second opinion. His diagnosis was palisaded granulomatous dermatitis with focal vasculitis, probably necrobiosis lipoidica.
- LEUKOCYTOCLASTIC VASCULITIS INVOLVING MEDIUM-SIZED MUSCULAR ARTERY IN DEEP DERMIS.
- The current biopsy demonstrates a different histopathology than the prior in that there is no panniculitis. There is only pure leukocytoclastic vasculitis involving medium-sized artery, which can be seen in polyarteritis nodosa. Although necrobiosis lipoidica can demonstrate secondary lymphocytic vasculitis, the current findings are diagnostic for leukocytoclastic vasculitis and do not support necrobiosis lipoidica.







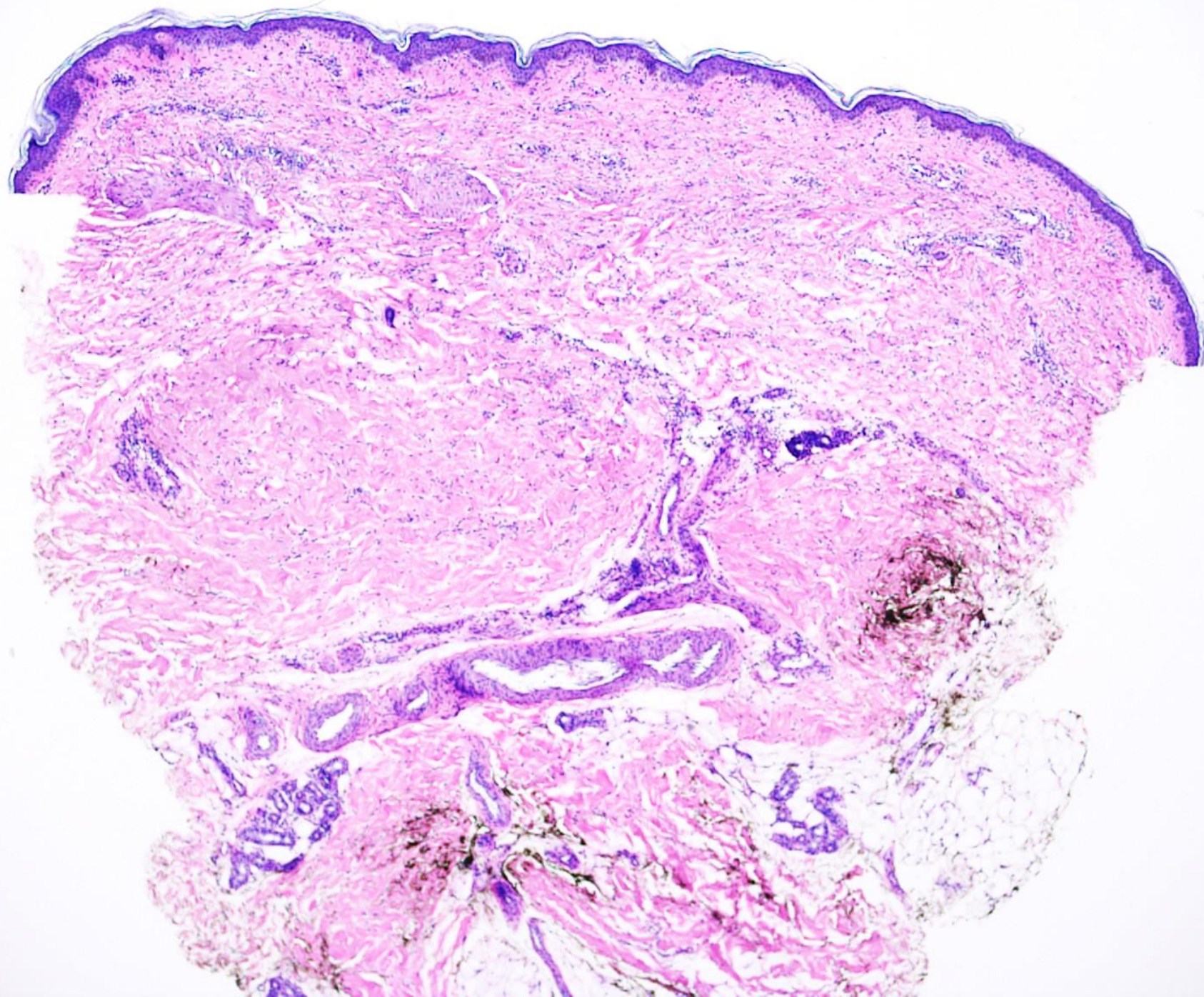




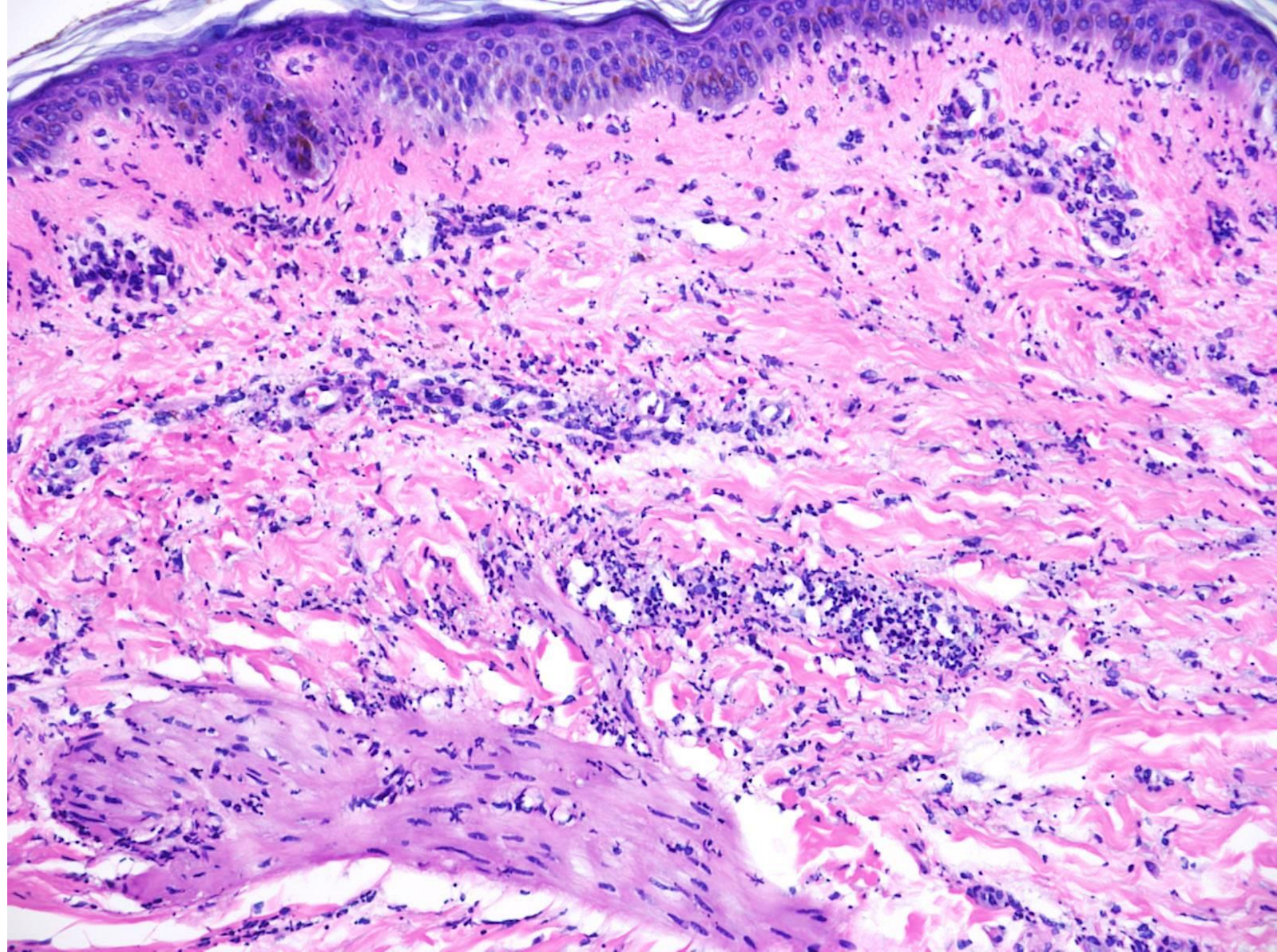


# Urticarial Vasculitis

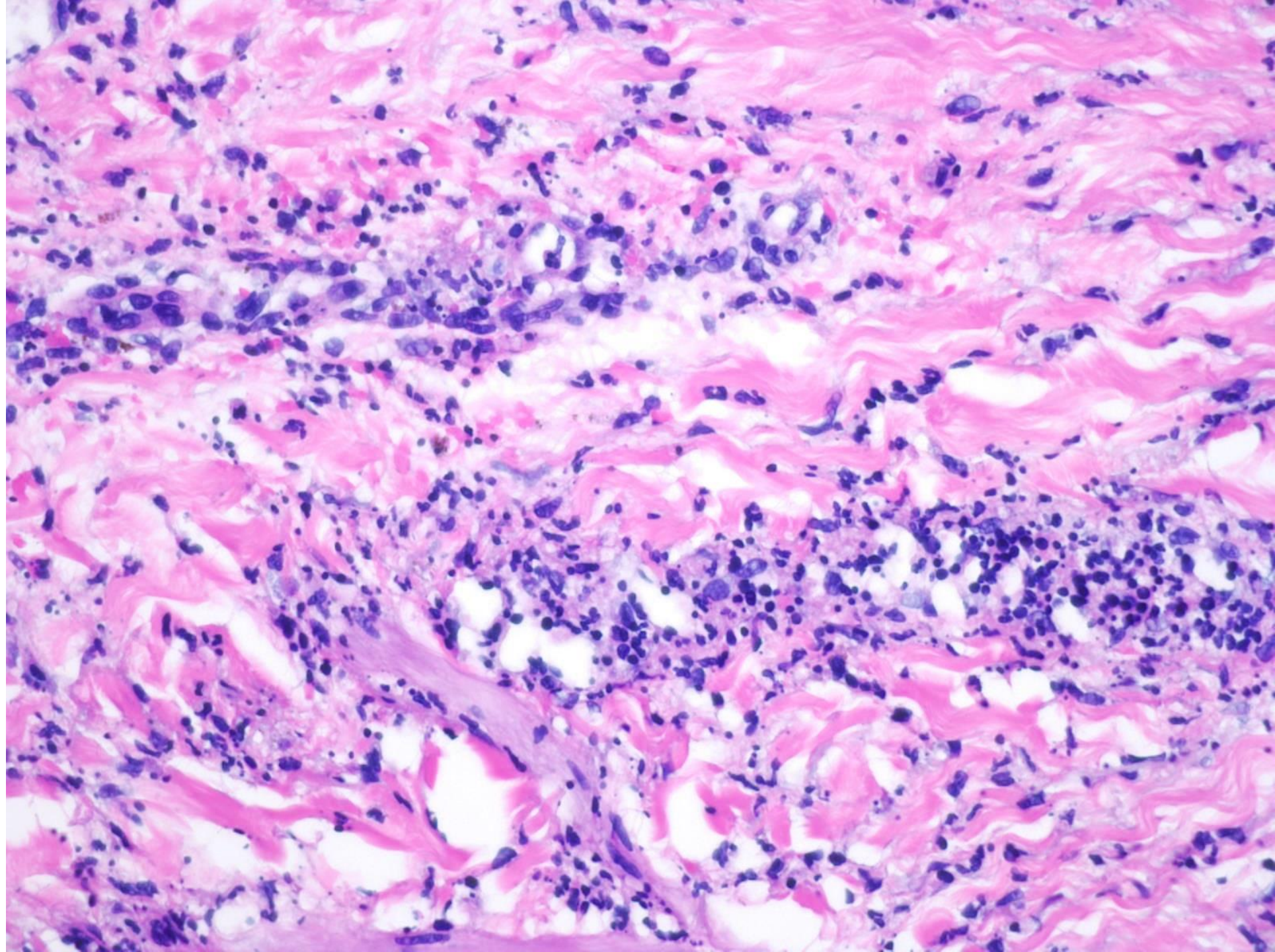
- 34/F RIGHT THIGH PUNCH BIOPSY
- L50.1; DIFFUSE URTICARIAL PAPULES, AREAS OF BRUISING, R/O URTICARIAL VASCULITIS
- COMPATIBLE WITH URTICARIAL VASCULITIS. Overall, the findings support the clinical impression of urticarial vasculitis, early phase. The differential diagnosis includes acute urticaria. Diagnostic features of established leukocytoclastic vasculitis are absent.



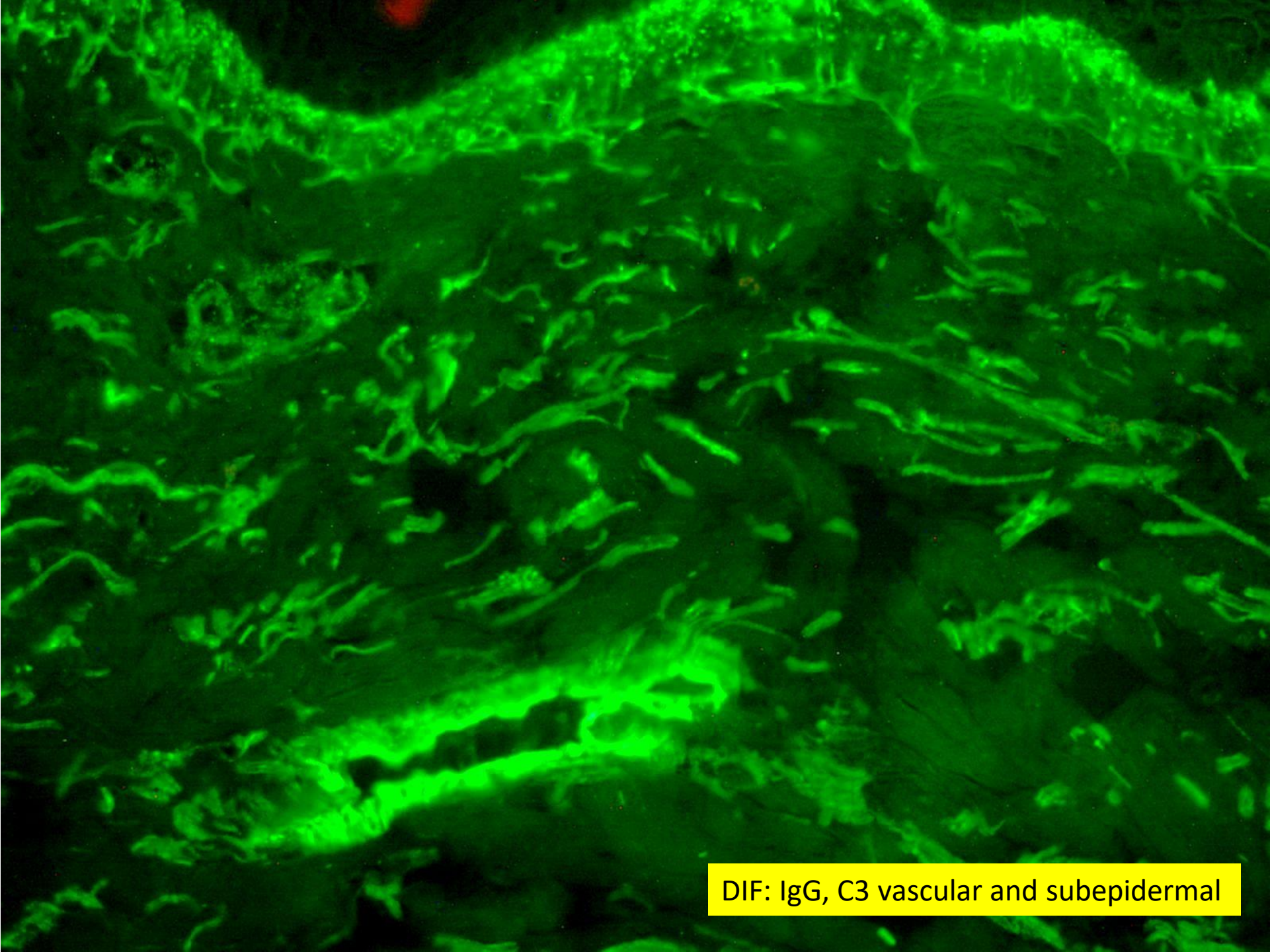












DIF: IgG, C3 vascular and subepidermal

# LCV in SLE: Lupus vasculitis


- L30.9; 41/F RIGHT THIGH H&E and DIF. PATIENT WITH A HISTORY OF SLE COMPLICATED BY NEPHROTIC SYNDROME AND RHEUMATOID ARTHRITIS WITH AN ACUTE ONSET RASH THAT INCLUDED ARCUATE PLAQUES, EDEMATOUS PAPULES AND PLAQUES ON THE CHEST AND BACK WITH NO MALAR RASH
- LEUKOCYTOCLASTIC VASCULITIS, INVOLVING SMALL-CALIBER BLOOD VESSELS IN SUPERFICIAL-MID DERMIS. The findings of leukocytoclastic vasculitis in this clinical context may represent vasculitis in systemic lupus erythematosus, which can be seen in roughly 11-30% of patients with systemic lupus erythematosus, supported by positive lupus band test and vascular reaction according to the results for DIF.



# Digital Skin Pathology

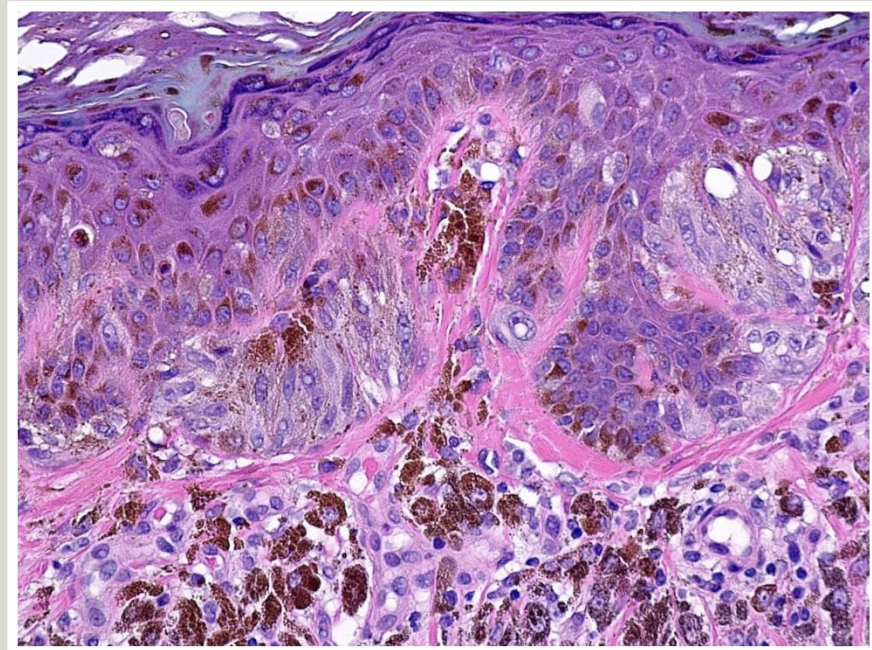
<https://digitalskinpathology.com/>

- Meet the challenges of the growing needs for dermatopathology knowledge
- Learn Dermatopathology based on actual real-life cases
- Dermatology PAs and NPs
- Primary MDs and general surgeons
- Residents of Dermatology and Pathology



**DIGITAL SKIN PATHOLOGY (DiSK)**  
Learn Histologic Diagnosis Case-By-Case

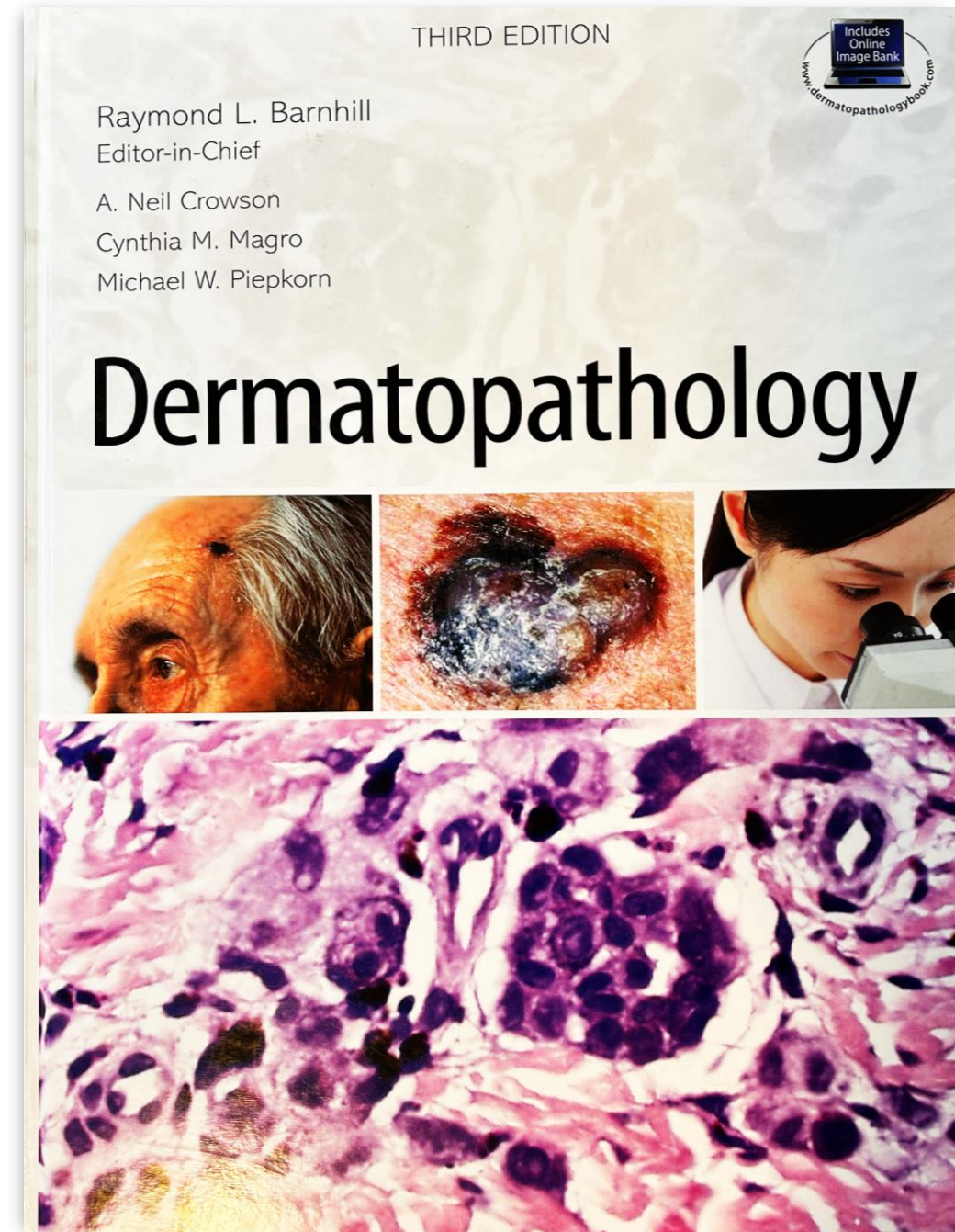
**DERMATOPATHOLOGY: LEARN HOW TO  
DIAGNOSE SKIN DISEASES DERM PATH  
DIAGNOSTICS**



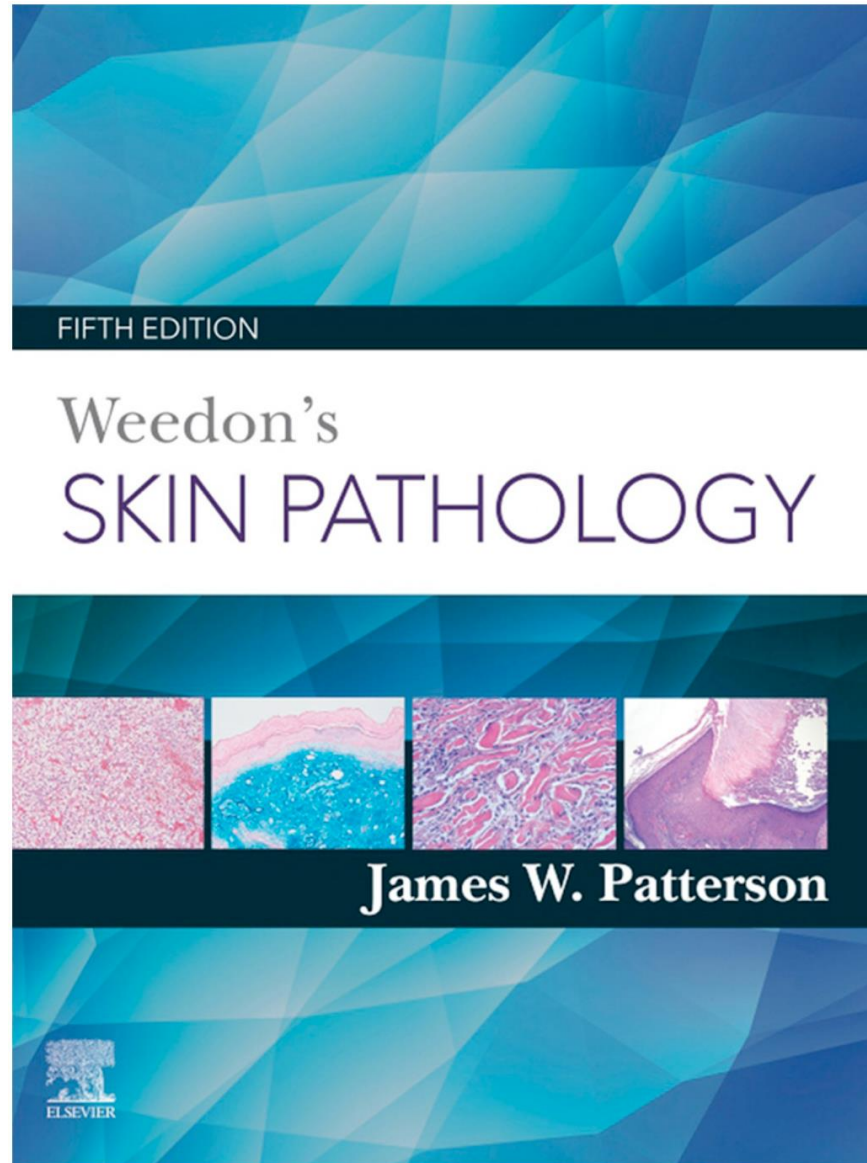
**Understand your patient's dermatopathology diagnostic report to  
provide better clinical care** (how to diagnose skin diseases). derm  
path diagnostics

# References

- Dermatopathology
  - Raymond L. Barnhill, editor-in-chief
  - A. Neil Crowson
  - Cynthia M Magro
  - Michael W Piepkorn







# References

- Weedon's skin pathology
- McKee's pathology of the skin