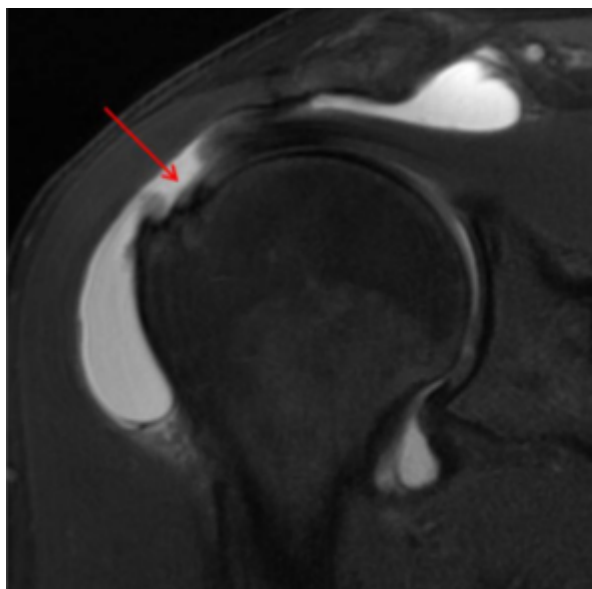
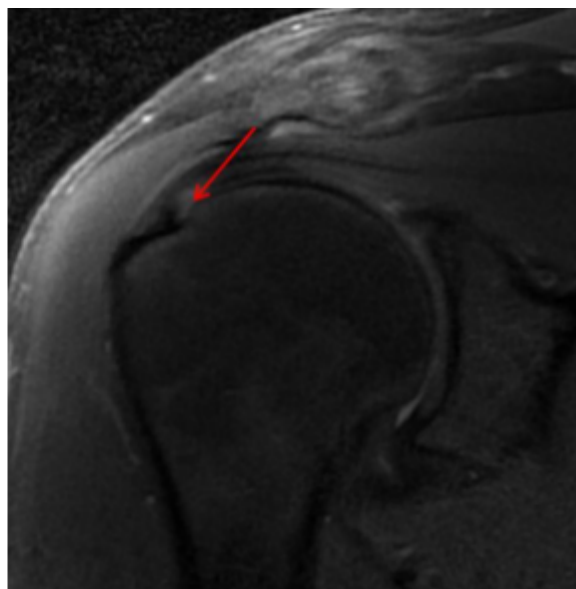


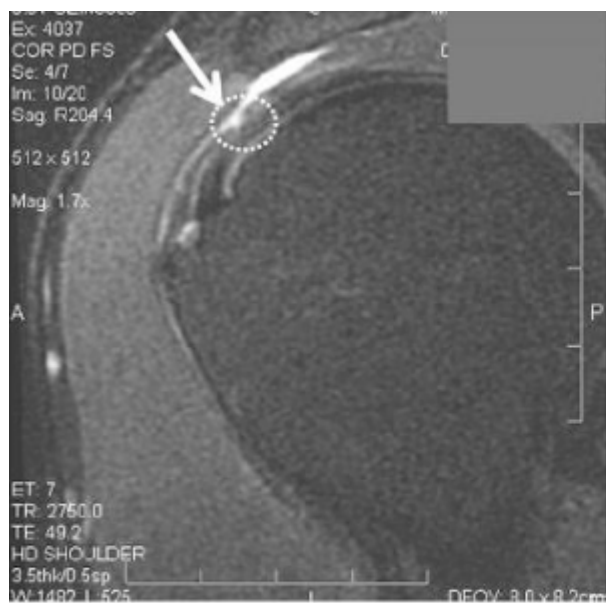
These patients had a tear in the supraspinatus tendon. The arrow is pointed at the tear which displays a gap where the tendon should be. You can view the MRI after image on the right to see the gap has gone away. These patients used their own bone marrow concentrate, which contained their stem cells, placed precisely into the tendon tear using ultrasound guidance.



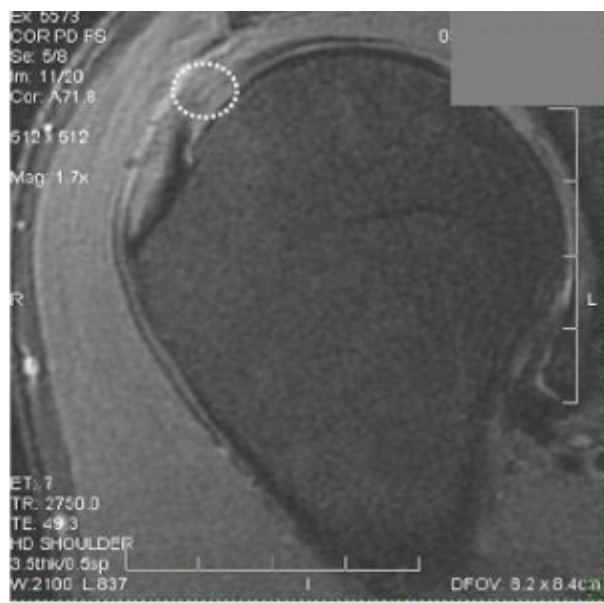BEFORE



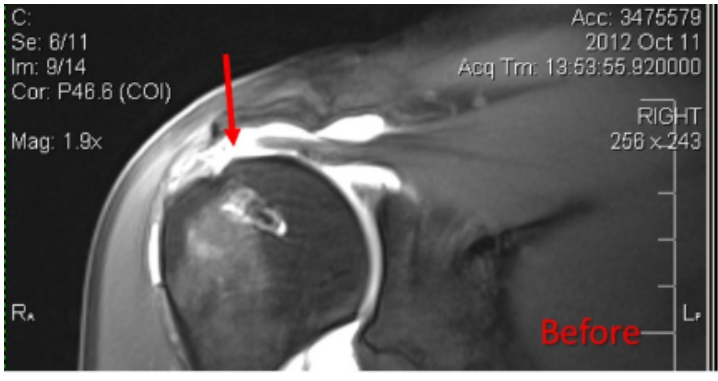
AFTER



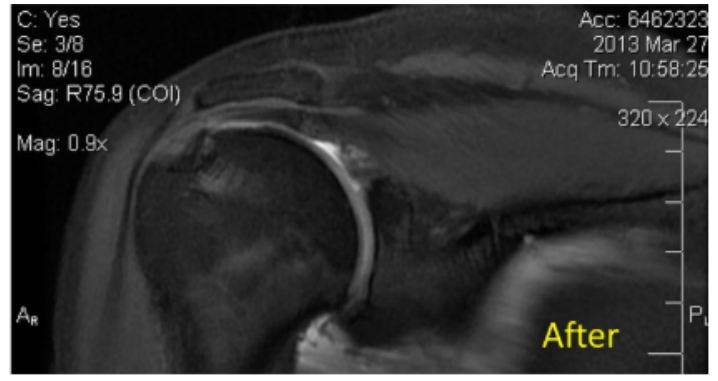
BEFORE



AFTER



BEFORE



AFTER