
Lower Arterial

Name: Sample, Patient A
Date of Birth: 11/24/1958

Age: 56

Patient ID: 123456
Gender: Female

Ref By: Smith, James MD
Examined By: Brown, Amy RVT, RDMS
Read By: Jones, William MD

Date: 06/16/2015 2:09 PM
Accession #: XO-A062220-03
Room: OP

History

Smoke: Never
Diabetic: Yes
Gangrene: None
Prev Angioplasty: No

Hypertension: Yes
Claudication: None
Vascular Ulcers: None
Prev Vasc Surg: No

Hyperlipidemia: Yes
Rest Pain: None
Skin Color Chg: None

Additional history notes or patient comments may be entered here. History questions as well as the answers are custom configured by the user.

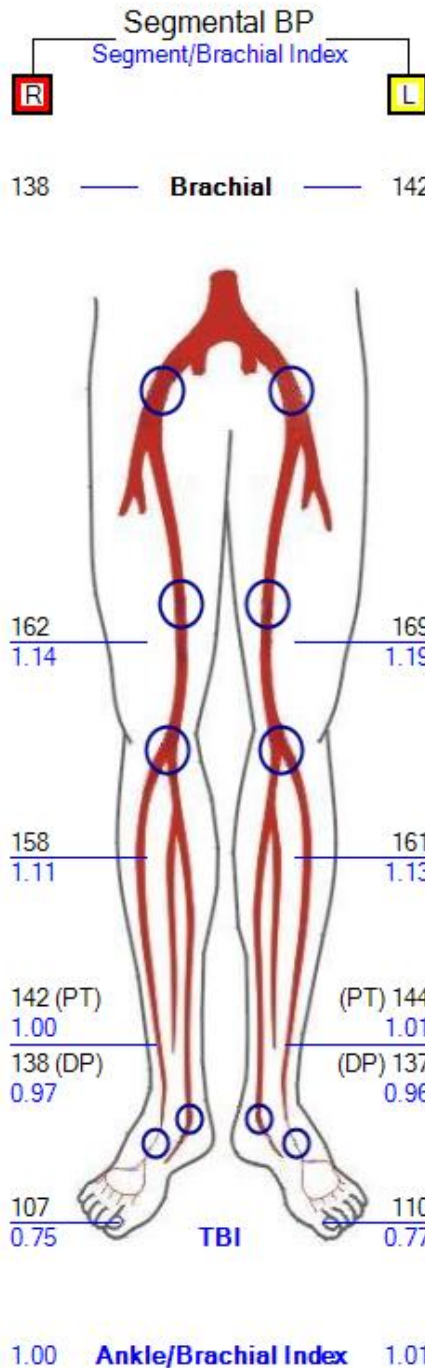
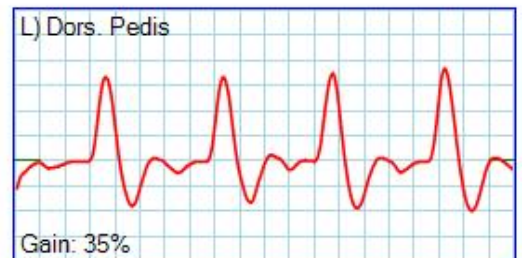
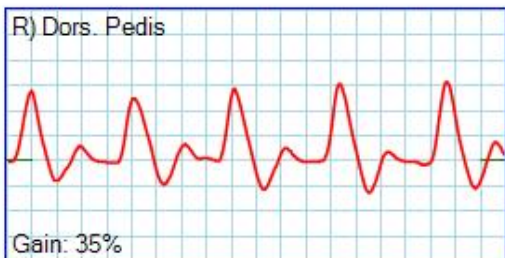
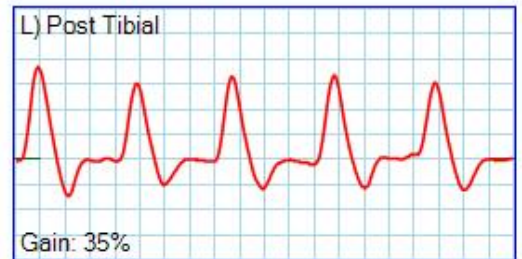
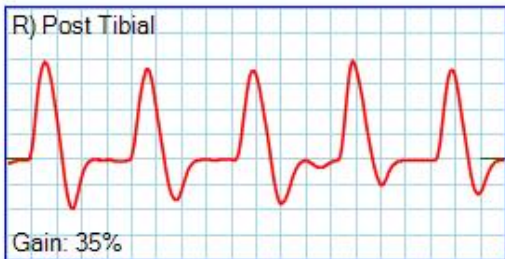
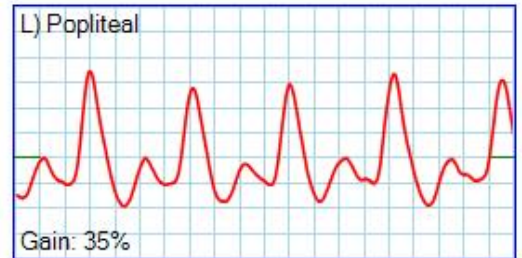
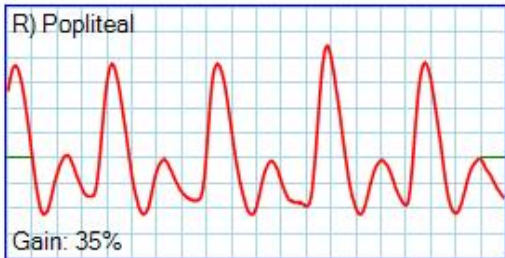
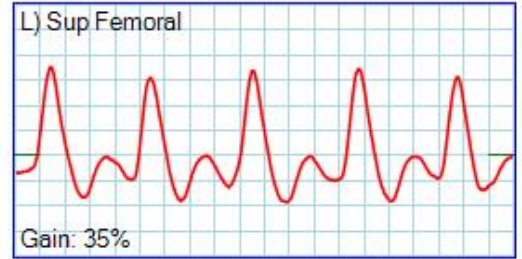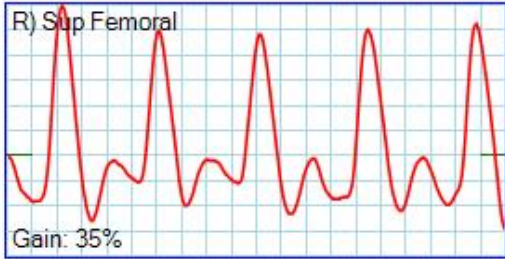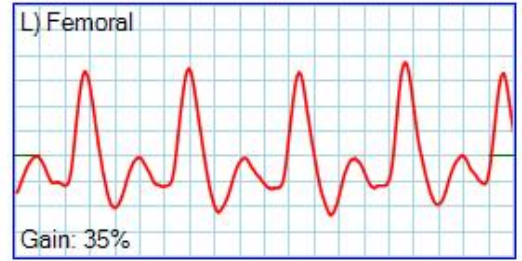
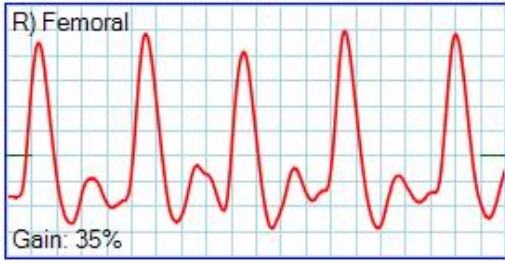
Segmental BP

| | Right | | | Left |
|--------------------|-------|-------|--|------|
| Brachial: | 138 | Index | | 142 |
| Thigh: | 162 | 1.14 | | 169 |
| Calf: | 158 | 1.11 | | 161 |
| Ankle (PT): | 142 | 1.00 | | 144 |
| Ankle (DP): | 138 | 0.97 | | 137 |
| Digit: | 107 | 0.75 | | 110 |

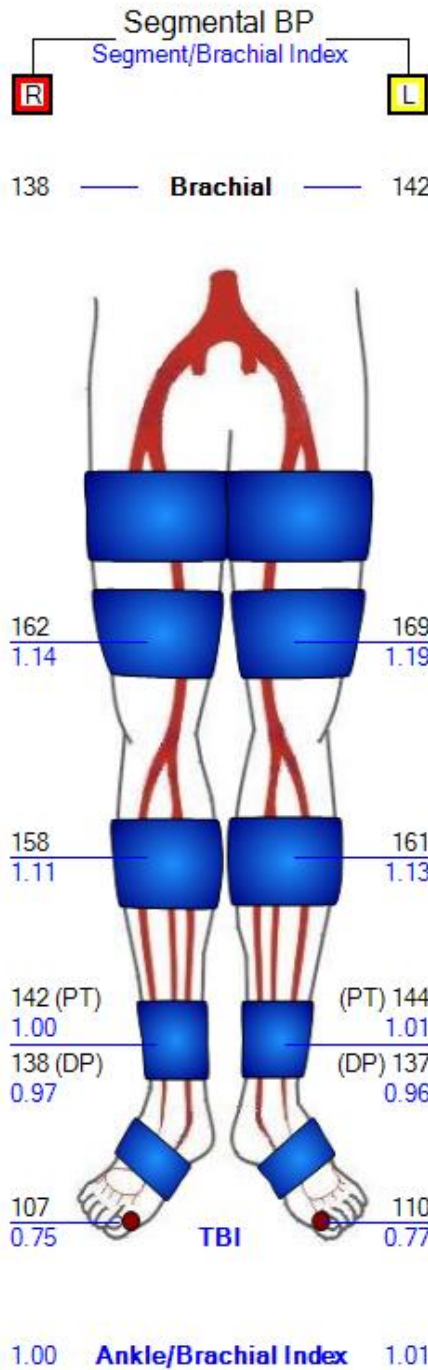
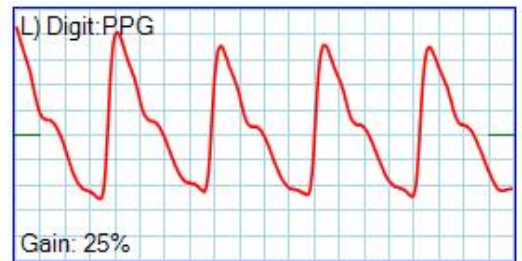
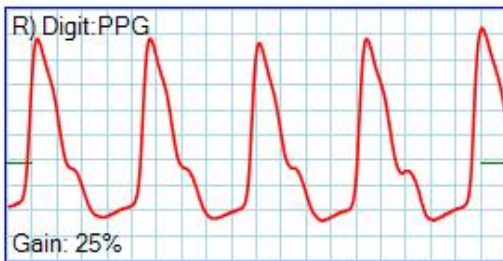
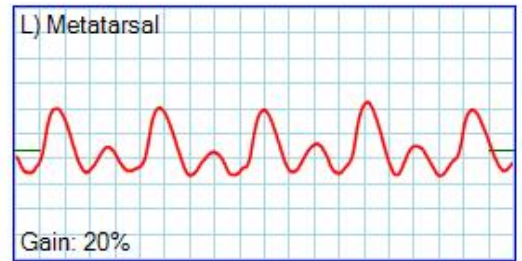
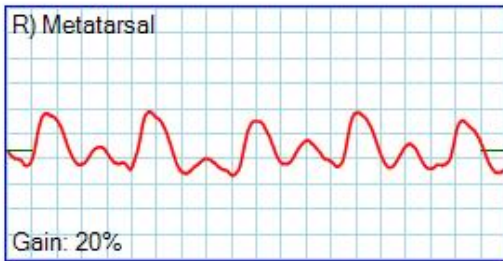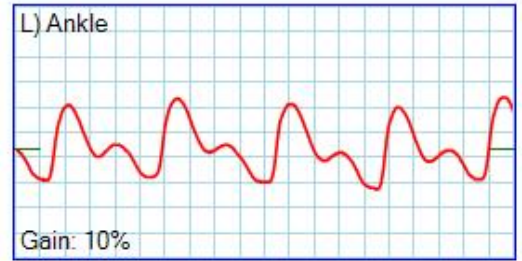
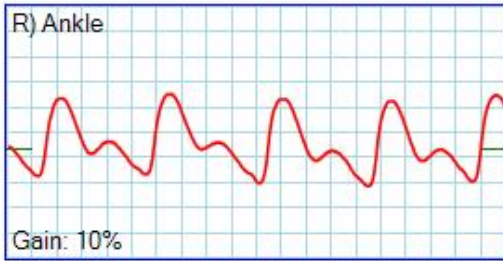
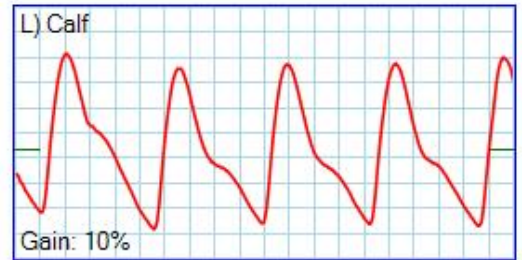
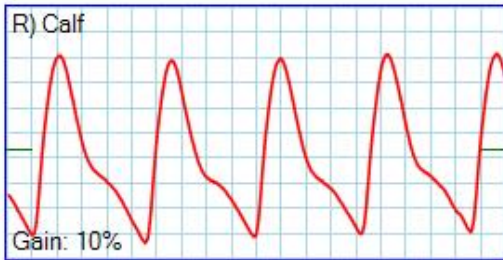
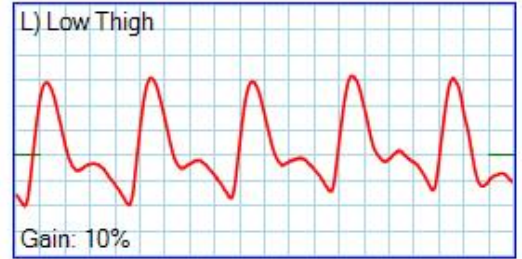
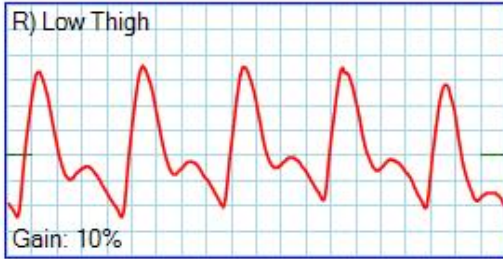
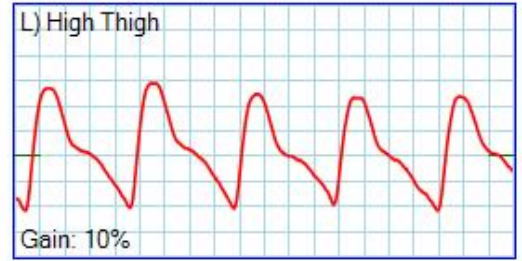
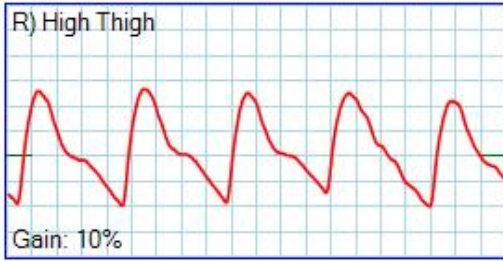
Pulses

| | Right | | | Left |
|----------------------|-------|--|--|------|
| Femoral: | 4+ | | | 4+ |
| Popliteal: | 4+ | | | 4+ |
| Dors. Pedis: | 3+ | | | 3+ |
| Post. Tibial: | 3+ | | | 3+ |

Doppler



Pulse Volume Recordings



Exercise Pressures

| | Rest | 1 | 2 | 3 | 4 | 5 | 6 |
|---------------|------|------|------|------|------|------|------|
| R Ankle (PT): | 142 | 95 | 105 | 115 | 121 | 130 | 142 |
| L Ankle (PT): | 144 | 145 | 145 | 143 | 144 | 144 | 144 |
| L Brachial: | 142 | 158 | 154 | 150 | 147 | 145 | 142 |
| R ABI: | 1.00 | 0.60 | 0.68 | 0.77 | 0.82 | 0.90 | 1.00 |
| L ABI: | 1.01 | 0.92 | 0.94 | 0.95 | 0.98 | 0.99 | 1.01 |

Exercise Pressures

