

Use of a 3-Dimensional Custom-Made Porous Titanium Prosthesis for Mandibular Body Reconstruction With Prosthetic Dental Rehabilitation and Lipofilling



Gaoussou Touré, MD, PhD, FEBOMFS,* and Emmanuel Gouet, DDS†

Reconstruction of mandibular substance loss by a free flap is a widely used technique. This technique suffers from several disadvantages, including the presence of a second intervention site and a substantial frequency of complications. We have undertaken a custom-made 3-dimensional reconstruction (using computer-aided design and manufacturing) with prosthetic dental rehabilitation and esthetic improvement by lipomodeling of the face. A 50-year-old woman presented with a massive recurrence of an ameloblastoma of the right hemimandible. A cervical approach was used to resect the mandible well away from the tumor site. In light of her refusal to undergo reconstruction by a fibula free flap, reconstruction was performed using a custom-made porous titanium device with dental prosthetic rehabilitation, followed by lipomodeling of the face. The reconstruction was achieved without the occurrence of any complications. The implant-supported prosthetic dental implantation and the lipofilling resulted in functionally and esthetically satisfactory outcomes. Three-dimensional mandibular reconstruction with a custom-made porous titanium device and lipofilling yielded satisfactory results. Fitting of the dental prosthesis was undertaken at an early stage as it did not require osseointegration, although there was a need to overcome difficulties linked with the seal and the stability of the dental prosthesis and titanium support. The duration of patient follow-up was 18 months.

© 2019 American Association of Oral and Maxillofacial Surgeons
J Oral Maxillofac Surg 77:1305-1313, 2019

Free flaps in mandibular reconstruction have been tried and tested, and they are considered the standard for mandibular reconstruction.^{1,2} However, in the case of contraindications or refusal by the patient, we believe that 3-dimensional (3D) reconstruction with custom-made porous titanium offers a suitable solution. It fits with the notion of therapeutic deflation, which favors implementation of an effective treatment with a minimum number of complications.

Mandibular reconstructions by osteo-musculocutaneous free flaps exhibit a substantial de-

gree of morbidity and necessitate creation of a second surgical site, and complications are not uncommon.^{1,3} It strikes us that seeking a functional and esthetic alternative is presently a high priority. We describe an example of reconstruction with a custom-made porous titanium plate, with dental rehabilitation using an implant-supported prosthesis and improvement of the esthetic appearance by lipofilling.

Report of Case

A 50-year-old female patient, who was employed by a banking agency and an avid runner, presented

Received from Service de Chirurgie Maxillo-Faciale, Intercity Hospital Center Villeneuve Saint Georges, Villeneuve-Saint-Georges, France.

*Professor and Department Head.

†Consultant.

Conflict of Interest Disclosures: None of the authors have any relevant financial relationship(s) with a commercial interest.

Address correspondence and reprint requests to Dr Toure: CHI Villeneuve Saint Georges, 40 Allée de la Source, Villeneuve-Saint-Georges 94195, France; e-mail: gaoussou.toure@chiv.fr

Received August 31 2018

Accepted December 21 2018

© 2019 American Association of Oral and Maxillofacial Surgeons

0278-2391/18/31396X

<https://doi.org/10.1016/j.joms.2018.12.026>

with a massive recurrence of an ameloblastoma at the level of the right-side angle of the mandible that extended to the ramus and the mandibular body on the same side. The patient was operated on twice, with an interval of 1 year, before it was decided to perform a mandibular resection. These 2 interventions consisted of curettage of the tumor cavity down to the presumably healthy bone tissue. The patient had insulin-dependent diabetes and mental depression. These pathologic conditions were medically well controlled. The patient refused to be treated by a fibula free flap. We therefore provided treatment by a mandibular resection in the healthy areas, followed by reconstruction using a custom-made 3D device made of porous titanium with dental prosthetic rehabilitation.

The treatment was provided in accordance with the ethical principles of our hospital and the World Medical Association Declaration of Helsinki. This case report was written according to the Surgical Case Report (SCARE) guidelines for surgical case reports.

A 3D reconstruction was made based on thin submillimeter tomodensitometric sections. The cutting guides and custom-made 3D entity were manufactured by Materialise (Leuven, Belgium) using Mimics medical software via computer-aided design and manufacturing (CAD-CAM) with sites intended for healing abutments, followed by the implant-supported prosthesis (Fig 1).

Exeresis of the tumor and fitting of the custom-made titanium plate to replace the resected mandibular segment were performed by a cervical approach. The cutting guides were attached based on the previously defined landmarks at the level of the right mandibular condyle and the symphyseal region. The mandibular resection was performed using a power tool. The predrilled holes were made at the same time with 1.5-mm-diameter drill bits. The plate was then held in place by 2-mm-diameter screws.

Two healing abutments were joined to the porous titanium prosthesis replacing the mandible. The implant-supported dental prostheses were manufactured and fitted to the porous titanium support 8 weeks after the surgical procedure.

The prosthetic fitting was carried out 1 month after the operation, after the soft tissues had healed. Thus, the implant-supported prosthesis rested on implants and fixtures inserted in the titanium epithesis. The implants were secured with screws torqued to 30 N-cm in the sites made for this purpose in the porous titanium, created during the digital planning. The implants were provided by the manufacturer of the plate (Materialise) to maximize the compatibility and the tightness of the seal.

The first prosthetic stage (Fig 2) consisted of a primary impression of the maxillary and mandibular arches. On the basis of the treated models, the prosthesis laboratory devised a customized impression tray for the pick-up impression, the purpose of which was to accurately record the position of the implants at the tooth-free site in relation to the teeth of the mandibular arch. The direct impression technique was used, by which the transfer of the impression for recording the position of the implant remains aligned with the impression tray on its removal. The pick-up-type transfers (captured and removed in the impression material) were screw retained on the implant. Their positioning was monitored radiologically. The material for the impression had excellent stability and detail reproduction properties (Impregum Super Quick Polyether Impression; 3M France, Cergy, France).

The plaster model derived from this impression reproduced the mucosal surfaces; the morphology of the teeth present; the hexagonal connection of the implants, as well as their relative positions; and the intra-implant screw axis. We also made a conventional alginate impression of the opposing arch, as well as recordings of the existing interdental spacing, using a maximal intercuspal bite registration.

Unfastening of the implants and fixtures took place at the same time as the healing abutments during this prosthetic phase. They were put back in and tightened to the torque level recommended by the manufacturer.

The prosthetic option that was retained consisted of 2 metallic crowns (Fig 3) joined directly by screw retention on the implants with parallel implant sites. Twelve months postoperatively, to improve the esthetic appearance, fat harvested from the internal side of the left thigh was injected to correct the depression of the right half of the face (Fig 3).

Results

The cervical surgical approach and the installation of the mandibular replacement prosthesis took place without any hurdles. The hospitalization lasted 3 days. No surgical complications were noted. The morphologic, esthetic, and functional outcomes were satisfactory 10 months postoperatively. The CAD-CAM process allowed us to fabricate a customized device. The patient was seen once a week in the first postoperative month and then twice a month over the next 2 months, followed by once a month. There was no periodontal treatment.

Unfastening of the healing abutments was followed by a transitory right perimandibular serous effusion that dissipated after they were tightly refastened. Although the esthetic appearance was adequate, after

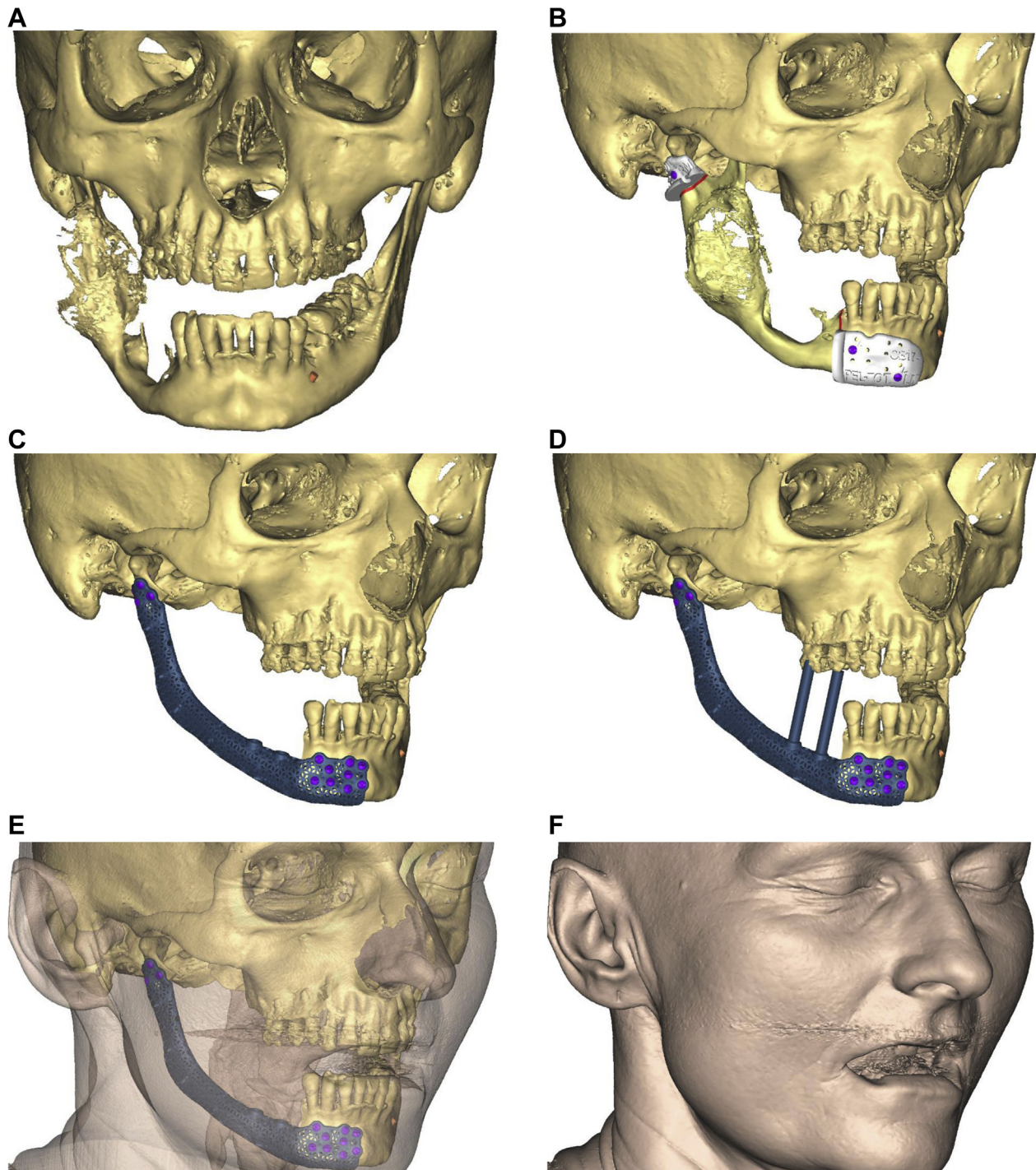


FIGURE 1. A-F, Mandibular tumor (ameloblastoma): 3-dimensional simulation, cutting guides, placement of titanium pins simulating positioning of healing abutments, and morphologic appearance at end of intervention.

Touré and Gouet. Titanium Mandibular Prosthesis. J Oral Maxillofac Surg 2019.

clinical evaluation, the right jugal depression was overcorrected by autologous fat, as the patient requested.

Discussion

There is precedent for replacement of the mandible by 3D reconstruction with titanium.⁴ Dental pros-

thetic rehabilitation and lipofilling allow functional and esthetic reconstruction.

Our clinical case illustrates the specific difficulties for oral implant-prosthetic rehabilitation on the episthesis.⁵⁻⁷ The main problem encountered was the unfastening of the implants and fixtures at the same time as the healing abutments during this prosthetic

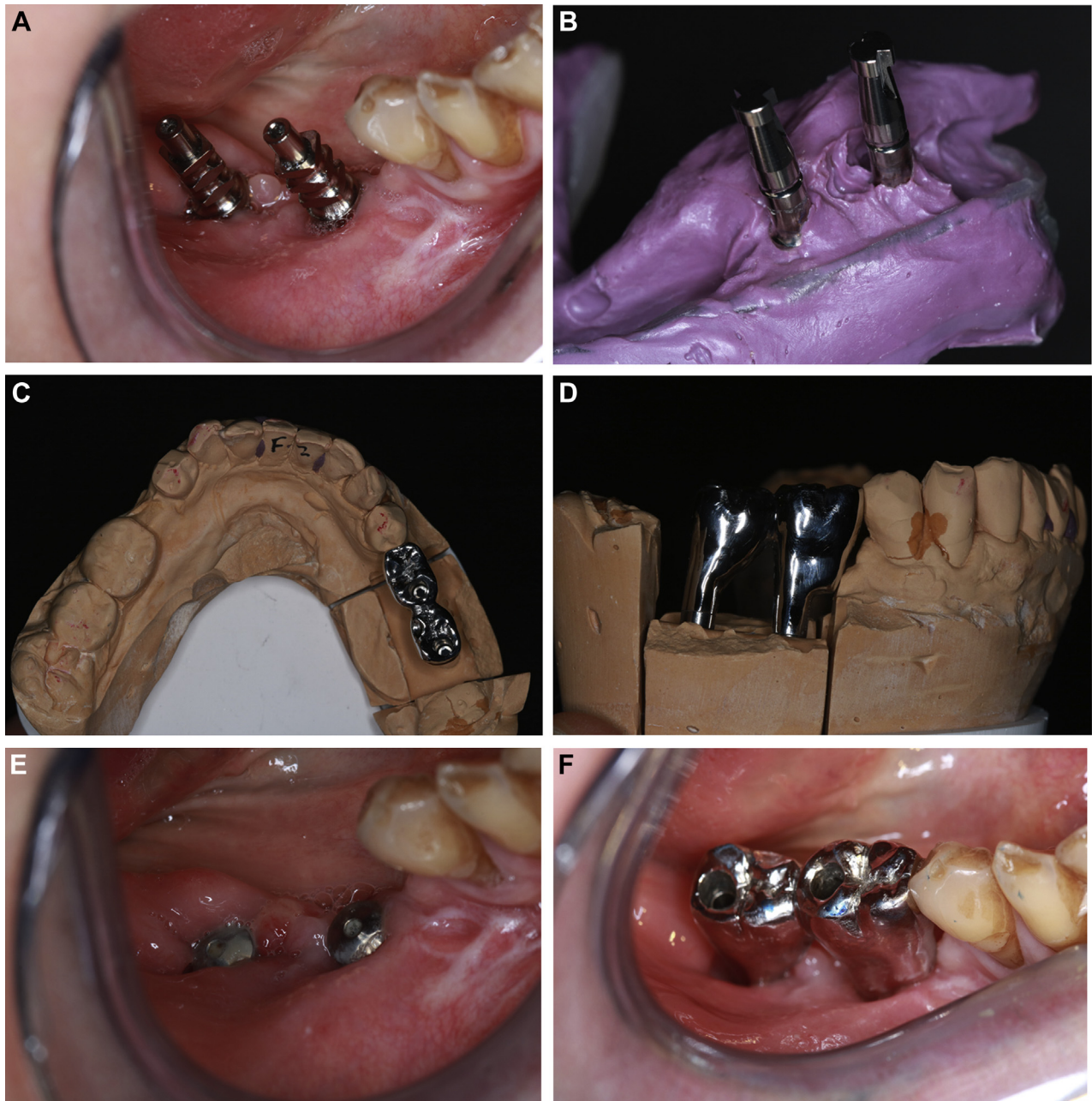


FIGURE 2. A-F, Prosthetic phase from taking of impression to appearance of dental prosthesis in mouth and in occlusion. F2, is a sign for the prosthesis laboratory to classify the manufactured elements.

Touré and Gouet. Titanium Mandibular Prosthesis. J Oral Maxillofac Surg 2019.

phase. The choice of dental prosthetic rehabilitation required emergence of the implants in the oral cavity, which is a particularly septic environment. Unlike devices that are entirely buried, this feature provides an entry route for possible secondary contamination of the epithesis.

The positioning of the implant sites within the epithesis was decided during the digital planning process. The available prosthetic space was increased after the operation with 2 key consequences. The prosthesis occupied a substantial portion of the space provided

by the loss of substance consequent to the hemimandibulectomy, and this was not entirely compensated for by the epithesis. This unusual increase in the height of the crowns exposed the implant-prosthetic rehabilitation to mechanical risk as a result of occlusal functional forces exerted on a crown-implant complex for which the ratio of the heights is increased. The biomechanical behavior of this type of device is still unknown.⁵⁻⁷

The absence of a combined vestibule at the height of the crowns makes access difficult for instruments for

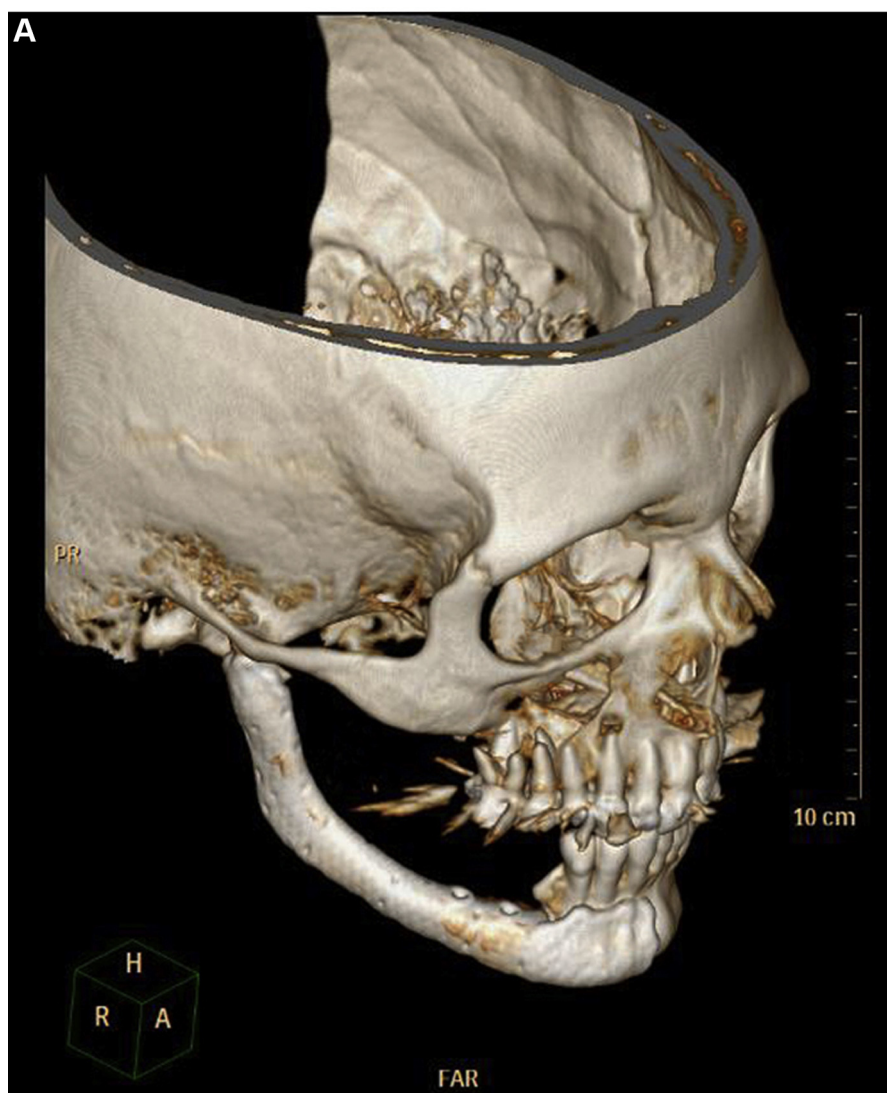


FIGURE 3. Postoperative images. A, Replacement device made of 3-dimensional porous titanium. A, anterior; FAR, forward anterior right; H, high; R, Right (side). (Fig 3 continued on next page.)

Touré and Gouet. Titanium Mandibular Prosthesis. J Oral Maxillofac Surg 2019.

hygienic purposes. The hexagonal external implant connection is characterized by its lack of a seal, weakness of mechanical retention, and difficulty with estimating adequate adjustment of the transfers or of the prosthetic items during their insertion.

The neck of the implant emerged under the mucosal layers, which made handling of the prosthetic fitting difficult and increased the risk of contamination or a lesion of the mucosal mounting, which led to a transient submandibular effusion in our patient. The protocol for screw restraint of the implant via an implant holder required numerous items, which constituted a degree of surgical discomfort.

The manufacturer (Materialise) provided the fixtures but none of the items earmarked for the impression and for the prosthetic work. A recourse to compatible implant systems does not guarantee a

suitable assembly on the fixtures (eg, the length of the screws constituted an obstacle for fully fastening on the crowns). Our analysis of the difficulties encountered and exposed in the literature, referring to studies conducted on osseointegrated implants,⁵⁻⁷ leads to the suggestion of changes in the conception of the fixture that ought to offer better anchorage at its site with a more retentive screw thread, a fixture with a more substantial diameter, a transmucosal implant neck to avoid possible bacterial contamination during unfastening and refastening of submucosal prosthetic parts,⁷ and an oversized external hexagonal connection relative to conventional standards with a better resistance to lateral forces on implant-prosthetic rehabilitations of such height.

In terms of function, the patient was able to open her mouth quite well, which allowed for proper

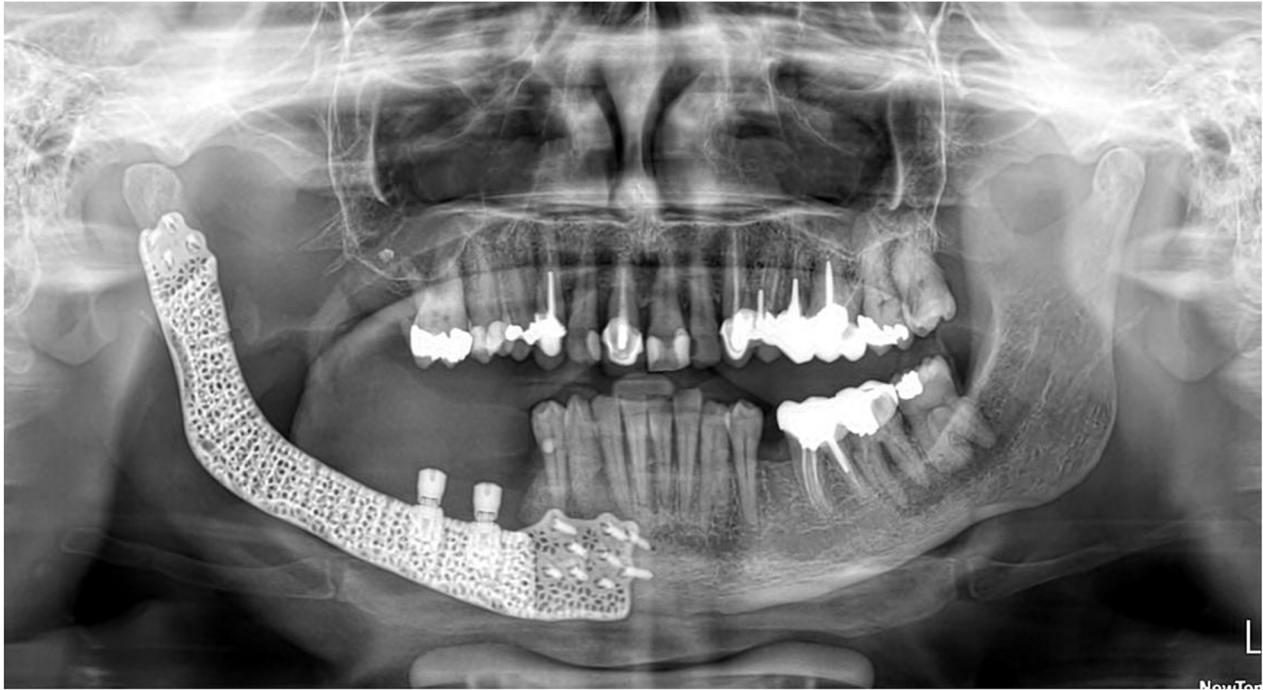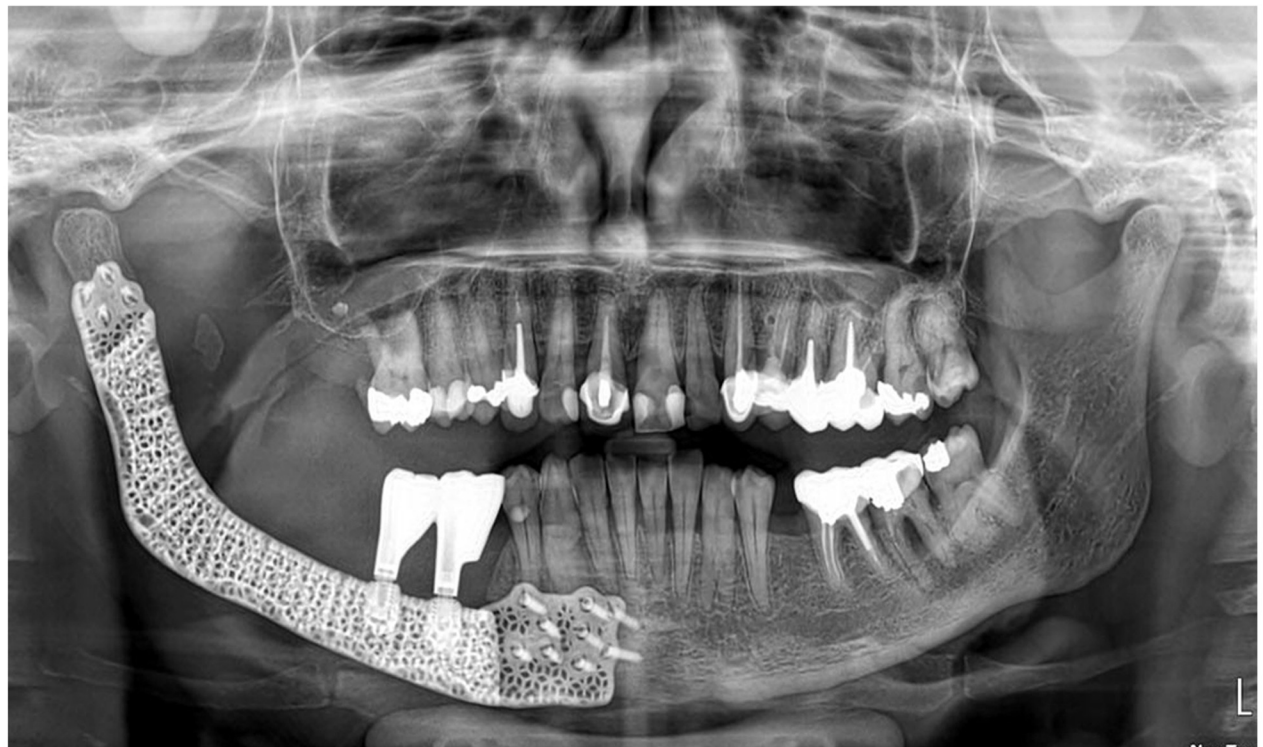B**C**

FIGURE 3 (cont'd). B, Installation of healing abutments. C, Dental prostheses in place on porous titanium. L, left (side). **(Fig 3 continued on next page.)**

Touré and Gouet. Titanium Mandibular Prosthesis. J Oral Maxillofac Surg 2019.

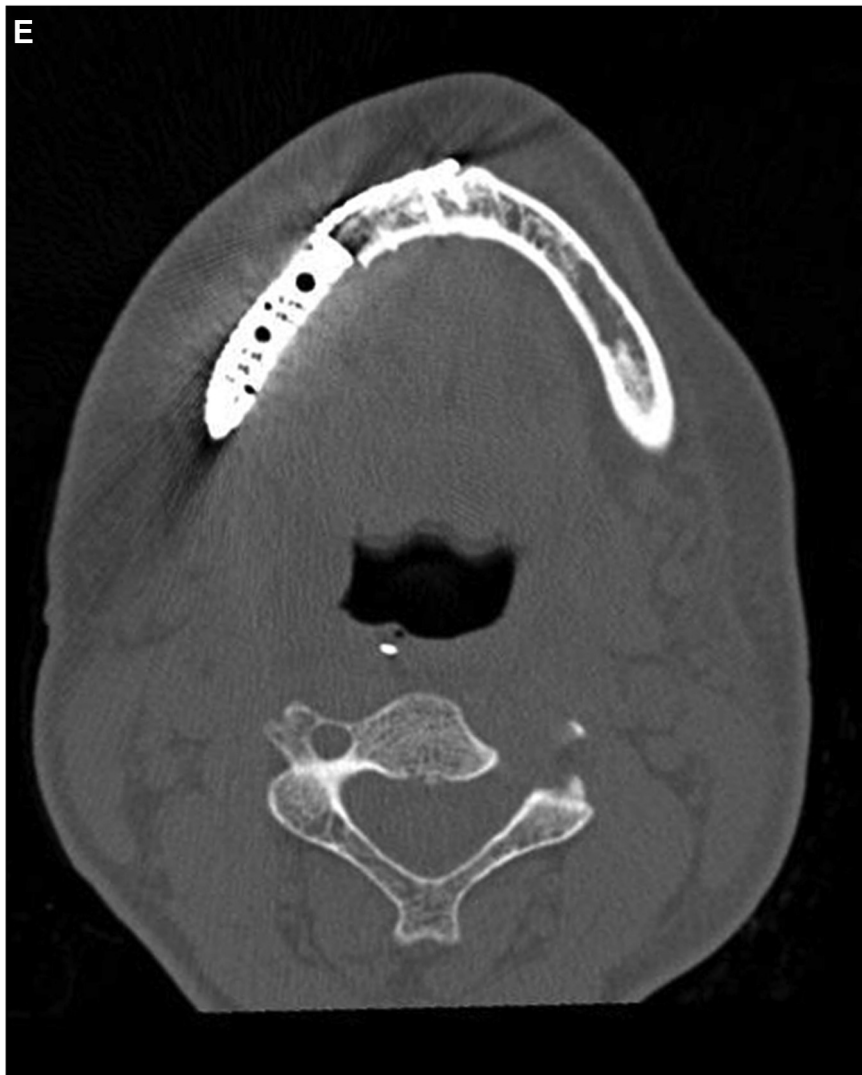

FIGURE 3 (cont'd). D, Overcorrection by lipfilling. (Fig 3 continued on next page.)

Touré and Gouet. Titanium Mandibular Prosthesis. J Oral Maxillofac Surg 2019.

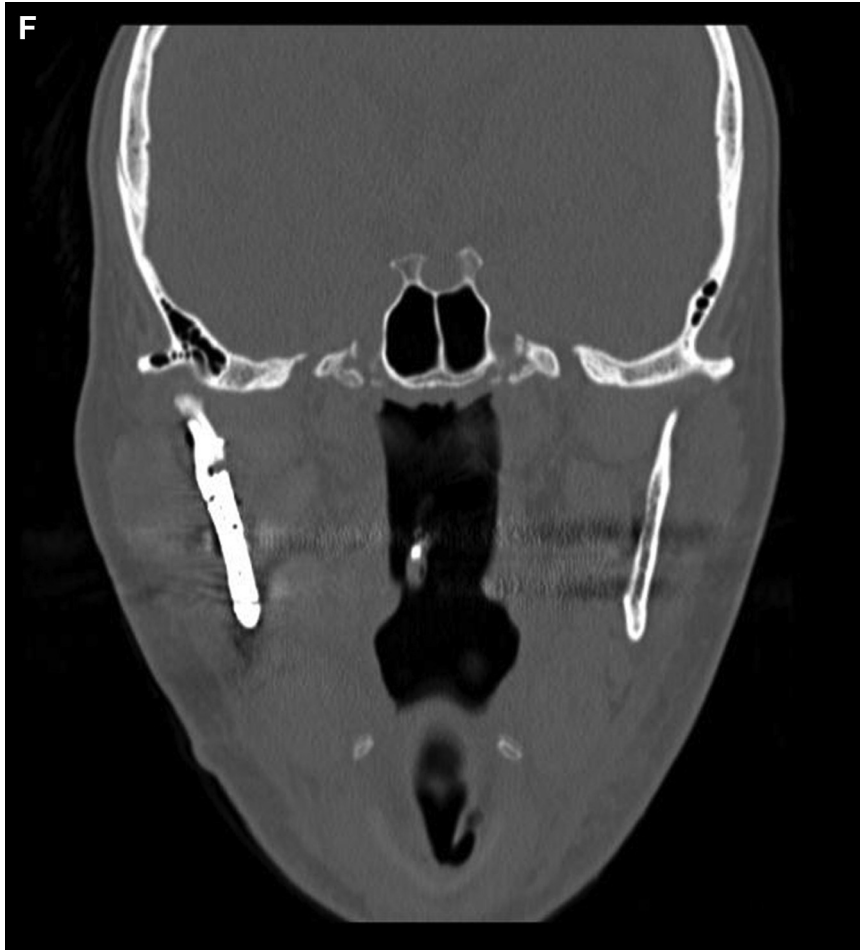

FIGURE 3 (cont'd). E, F, Filling around porous titanium.

Touré and Gouet. Titanium Mandibular Prosthesis. J Oral Maxillofac Surg 2019.

nutrition and adequate oral hygiene. Chewing soft foods was easy and painless. The patient had resumed her job without her physical appearance affecting contact with clients.

The soft tissues surrounding a dental implant constitute a superficial barrier that protects the underlying tissues, ensuring durability of the treatment. A healthy and stable mucosa surrounding the implant is indispensable for success and durability of the osseointegration of the implant and depends on healing and maintenance of the peripheral soft tissues.⁸⁻¹⁰

The clinical model we have presented is characterized by the absence of osseointegration because the bone is replaced by titanium. For the mucosa surrounding the implant to be effective as an antibacterial barrier, preservation of the quality and stability of this biological junction appears to be indispensable. This requirement is ensured by applying oral hygiene measures and rigorous, regular, extended monitoring, as well as by reducing the risk of bacterial infiltration linked with the device.

Nonetheless, aside from the technical difficulties, the multidisciplinary treatment of the patient by a surgical and then prosthetic process planned upstream of the hemimandibulectomy ensured a functional prosthetic rehabilitation. This promoted the psychological approach, and cooperation by the patient was enhanced. A rigorous oral-dental follow-up appears indispensable for longevity of these devices and allows for re-evaluation of the altered state of chewing.

CAD-CAM and 3D printing are increasingly part of the therapeutic arsenal in maxillofacial surgery. This type of reconstruction is straightforward, fast, and reliable. Dental prosthetic rehabilitation is possible and can take place at an early stage as it does not require an osseointegration phase.

References

1. Markiewicz MR, Bell RB, Bui TG, et al: Survival of microvascular free flaps in mandibular reconstruction: A systematic review and meta-analysis. *Microsurgery* 35:576, 2015

2. Shnayder Y, Lin D, Desai SC, et al: Reconstruction of the lateral mandibular defect: A review and treatment algorithm. *JAMA Facial Plast Surg* 17:367, 2015
3. McMahon J, Handley TPB, Bobinskas A, et al: Postoperative complications after head and neck operations that require free tissue transfer—Prevalent, morbid, and costly. *Br J Oral Maxillofac Surg* 55:789, 2017
4. Qassemyar Q, Assouly N, Temam S, Kolb F: Use of a three-dimensional custom-made porous titanium prosthesis for mandibular body reconstruction. *Int J Oral Maxillofac Surg* 46: 1248, 2017
5. Gehrke SA: Importance of crown height ratios in dental implants on the fracture strength of different connection designs: An in vitro study. *Clin Implant Dent Relat Res* 17: 790, 2015
6. Gil FJ, Herrero-Climent M, Lázaro P, Rios JV: Implant-abutment connections: Influence of the design on the microgap and their fatigue and fracture behavior of dental implants. *J Mater Sci Mater Med* 25:1825, 2014
7. Jaworski ME, Melo ACM, Picheth CMT, Sartori IA: Analysis of the bacterial seal at the implant-abutment interface in external-hexagon and Morse taper-connection implants: An in vitro study using a new methodology. *Int J Oral Maxillofac Implants* 27: 1091, 2012
8. Chai WL, Brook IM, Emanuelsson L, et al: Ultrastructural analysis of implant-soft tissue interface on a three-dimensional tissue-engineered oral mucosal model. *J Biomed Mater Res* 100: 269, 2012
9. Geurs NC, Vassilopoulos PJ, Reddy MS: Soft tissue considerations in implant site development. Review. *Oral Maxillofac Surg Clin North Am* 22:387, 2010
10. Ivanovski S, Lee R: Comparison of peri-implant and periodontal marginal soft tissues in health and disease. *Periodontol* 2000 76: 116, 2018