




Available online at
ScienceDirect
www.sciencedirect.com

Elsevier Masson France
EM|consulte
www.em-consulte.com/en



Case Report

Vascularization of the maxilla by a branch of the submandibular artery

G. Touré^{a,b,*}, A. Moreau^a, M. Ndiaye^{a,d}, A. Ory^{a,c}

^a Centre hospitalier intercommunal, chirurgie maxillo-faciale, Villeneuve Saint Georges 94195, France

^b URDIA Université Paris Descartes, 45, rue des Saints Pères, Anatomie, Paris 75006, France

^c CHU Bouaké, Bouaké, Cote d'Ivoire

^d Service de chirurgie maxillofaciale, Hôpital Le Dantec, Dakar, Senegal

ARTICLE INFO

Historique de l'article :

Received 6 January 2019

Accepted 31 January 2019

Available online 11 February 2019

Keywords:

External carotid artery

Maxilla

Facial artery

Ascending palatine artery, submandibular gland

ABSTRACT

Vascular variations are common. A cervicofacial anatomical dissection carried out at the anatomy laboratory allowed us to document a rare vascular variation. The facial artery did not give rise to branches that led to the submandibular gland; an artery arising directly from the external carotid artery vascularized the submandibular gland and gave rise to the ascending palatine artery that led to the maxilla. We did not find cases in the literature where an artery emanated directly from the external carotid artery to vascularize the submandibular gland and that gave rise to an ascending palatine artery leading to the maxilla. Knowledge of the variations of the arterial vascularisation of the submandibular gland is important for submandibulectomies and transfers of the gland.

© 2019 Elsevier Masson SAS. All rights reserved.

1. Introduction

Variations of the external carotid artery are common [1–9]. It has a variable number of branches. Among its branches, the facial artery has a major role in blood supply to the face. Indeed, it ensures blood supply to the maxilla by means of the ascending palatine artery, although it is also responsible for blood supply to the submandibular gland, by providing branches to this gland, currently referred to as "submandibular arteries" [2].

Knowledge of the vascularization of the submandibular gland is of clear and major interest for submandibulectomies and transfers of the submandibular gland. Transfers of the submandibular gland are becoming increasingly common to prevent xerostomia after radiotherapy and to treat severely dry eyes. This is why knowledge of the variations of the arterial vascularization is of interest [8,9].

Our work documented an anatomical variation.

2. Case report

Upon dissection at the anatomy laboratory of the cervical region of an anatomical specimen from a 78-year-old female, several anatomical variations were noted.

The right external carotid artery gave rise to a facial artery devoid of branches leading to the submandibular gland and lacking the ascending submandibular artery (Figs. 1 and 2). The branches leading to the submandibular gland were, in fact, represented by a single large artery, the "submandibular" artery, for which the origin was directly at the level of the external carotid artery, above the facial artery. In regard to the ascending palatine artery, its origin was this "submandibular artery". Moreover, the lingual artery formed a common trunk with the facial artery.

The facial artery was present, although its origin was at the level of the carotid bifurcation. It passed in front of the masseter muscle, skirting the lower edge of the mandibular body (Fig. 3).

The other branches of the facial artery were located. The venous route did not have any unusual features. No anatomical variation was noted for the left side.

* Corresponding author at: Centre hospitalier intercommunal, chirurgie maxillo-faciale, Villeneuve Saint Georges, 40, allée de la source, 94195 France.

E-mail address: gaoussou.toure@chiv.fr (G. Touré).

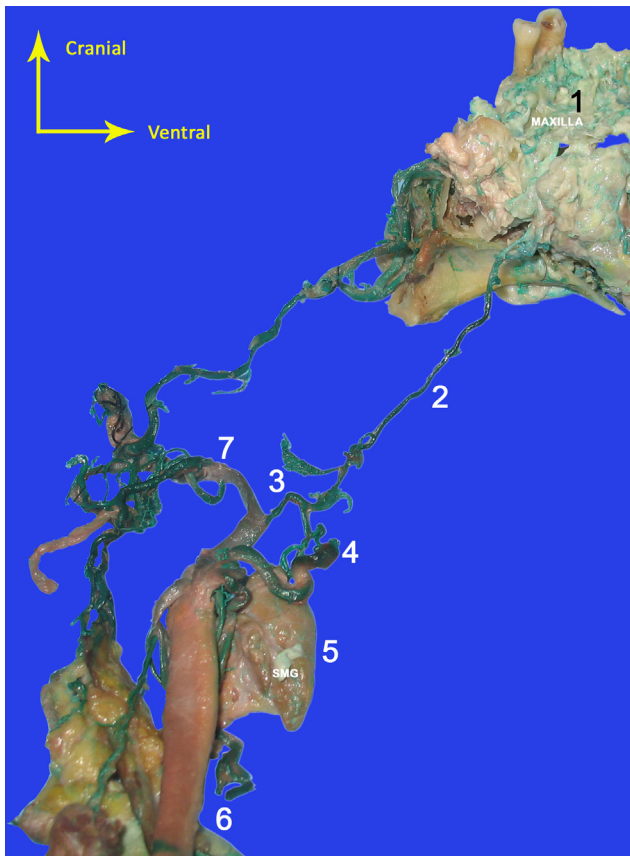

Fig. 1. Ventral view of the maxilla. 1: Right-hand side of the maxilla, as seen from below. 2: Ascending palatine artery. 3: Submandibular artery. 4: Facial artery. 5: Submandibular gland. 6: Common carotid artery. 7: External carotid artery.

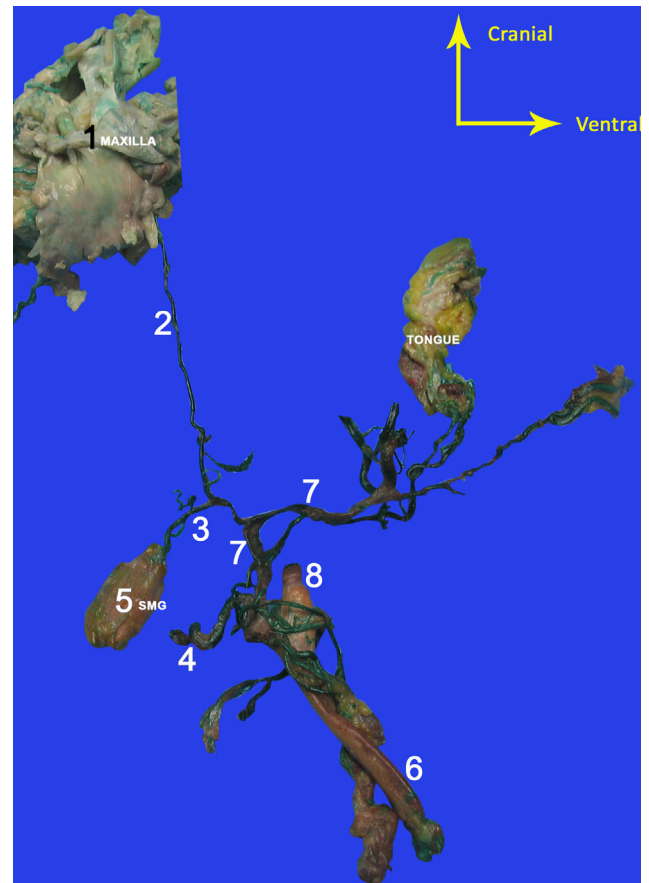


Fig. 2. Dorsal view of the maxilla. 1: Soft palate. 2: Ascending palatine artery. 3: Submandibular artery. 4: Facial artery. 5: Submandibular gland (SMG). 6: Common carotid artery. 7: External carotid artery. 8: Internal carotid artery.

3. Discussion

We have documented a rare case of vascularization of the maxilla by collateral branches of the “submandibular artery” arising directly from the external carotid artery.

A number of variations have already been described in the literature. Mamatha et al., Mohandas et al., and Li et al. have reported similar cases of vascularization of the submandibular gland by a branch arising directly from the external carotid artery [3–5]. Other vessels can also give rise to vascularization of the submandibular gland. Eid et al. have described a submandibular gland vascularized by a branch arising from the lingual artery, in the absence of a facial artery [6].

Marx et al. have described variations of the facial artery. They reported a bilateral anomaly, with an abnormal trajectory of this

artery on the right-hand side, without a loop around the submandibular gland, and the absence of the inferior labial artery on the left side [7].

The ascending palatine artery is usually the first collateral of the facial artery. Its purpose is vascularization of the pharynx, the amygdala, the styloglossus muscle, and the soft palate [8]. According to the work by Bergman, the origin of the ascending palatine artery is at the level of the facial artery in 70% of cases, the external carotid artery in 20% of cases, the ascending pharyngeal artery in 8% of cases, the lingual artery in 1% of cases, and the occipital artery in a further 1% of cases [9]. However, to our knowledge, no description of the ascending palatine artery as a branch of the artery which supplies the submandibular gland has been made. Knowledge regarding the arterial variations of the submandibular gland is important for transfers of the gland and for submandibulectomies.

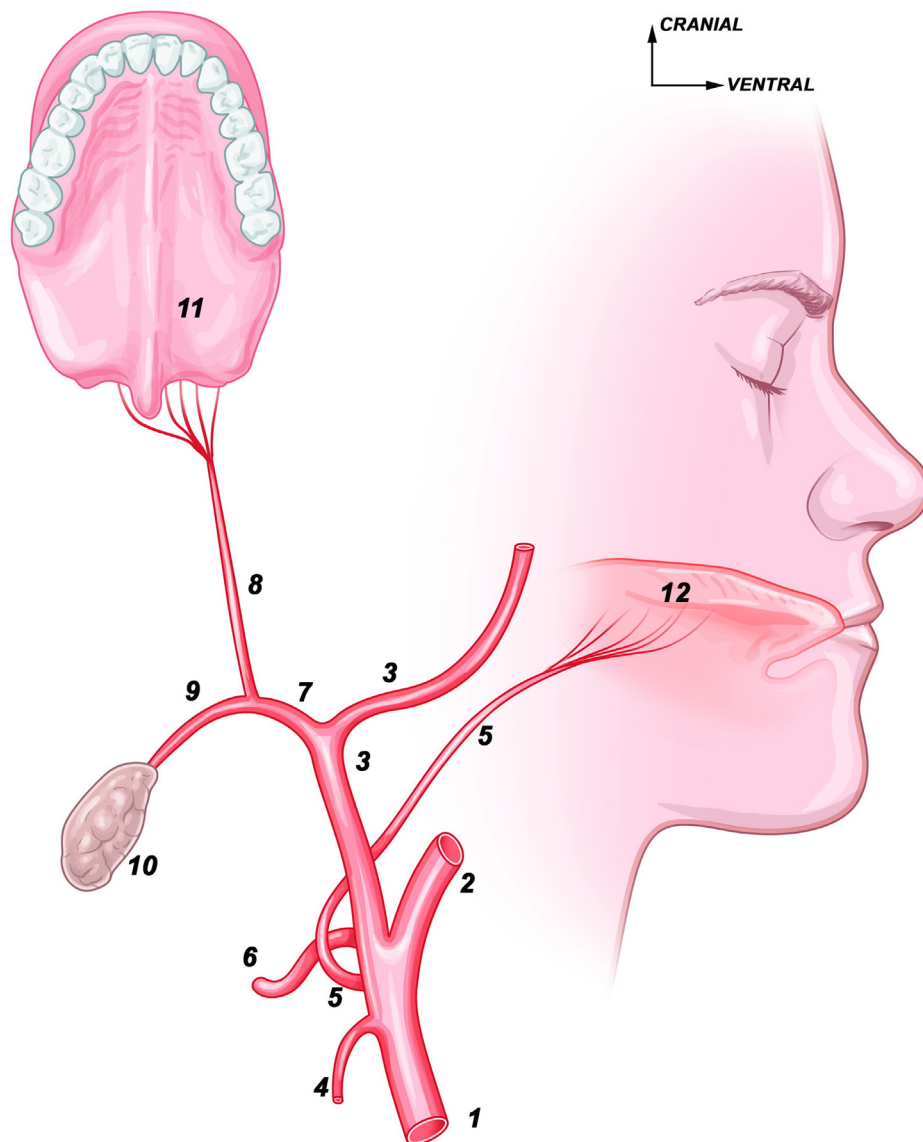


Fig. 3. Diagram of the vascularization of the maxilla and of the submandibular gland by a common arterial trunk. 1: Common carotid artery. 2: Internal carotid artery. 3: External carotid artery. 4: Superior thyroid artery. 5: Lingual artery. 6: Facial artery. 7: Common trunk of the ascending palatine artery (8) and the artery to the submandibular gland (9). 10: Submandibular gland. 11: Maxilla. 12: Tongue.

4. Conclusion

There are numerous publications regarding variations of the external carotid artery and its branches. However, there does not appear to be a description in the literature of the ascending palatine artery arising from the "submandibular artery", itself derived directly from the external carotid artery.

Knowledge of the anatomical variations that can occur, even when they are rare, is a prerequisite for surgery and radiology.

Ethics statement/confirmation of patient permission

Not required.

Funding

This research did not receive any specific grant from funding agencies in the public, commercial, or not-for-profit sectors.

Disclosure of interest

The authors declare that they have no competing interest.

References

- [1] Zümre O, Salbacak A, Çiçekcibaşı AE, Tuncer I, Seker M. Investigation of the bifurcation level of the common carotid artery and variations of the branches of the external carotid artery in human fetuses. *Ann Anat* 2005;187:361–9.
- [2] Touré G, Méningaud JP. Anatomical study of the vascular territories of the maxilla: role of the facial artery in allotransplantation. *J Plast Reconstr Aesthet Surg* 2015;68:213–8.
- [3] TM, Rai R, Prabhu LV, Hadimani GA, PJJ, MDP. Anomalous branching pattern of the external carotid artery: a case report. *Rom J Morphol Embryol* 2010;51:593–595.
- [4] Mohandras R, Rodrigues V, Shajan K, Krishnasamy N, Radhakrishnan AM. Unilateral high origin of facial artery associated with a variant origin of the glandular branch to the submandibular gland. *Int J Anat Var* 2009;2:136–7.
- [5] Li L, Gao XL, Song YZ, Xu H, Yu GY, Zhu ZH, et al. Anatomy of arteries and veins of submandibular glands. *Chin Med J* 2007;120:1179–82.
- [6] Eid N, Ito Y, Otsuki Y. Anomalous branching pattern of external carotid artery: clinical relevance to cervicofacial surgery. *Clin Anat* 2011;24:953–5.
- [7] Marx C, Kumar P, Reddy S, Vollala VR. Bilateral variation of facial artery: a case report. *Rom J Morphol Embryol* 2008;49:399–401.
- [8] Marzouki HZ, Elkhalidy Y, Jha N, Scrimger R, Debenham BJ, Harris JR, et al. Modification of the submandibular gland transfer procedure. *Laryngoscope* 2016;126:2492–6.
- [9] Su JZ, Cai ZG, Yu GY. Microvascular autologous submandibular gland transplantation in severe cases of keratoconjunctivitis sicca. *Maxillofac Plast Reconstr Surg* 2015;37:5.