

A JOURNEY WITH PARASITES

LIVING WITH HAEMONCHUS CONTORTUS {BARBERPOLE} BY DEB APTHORP

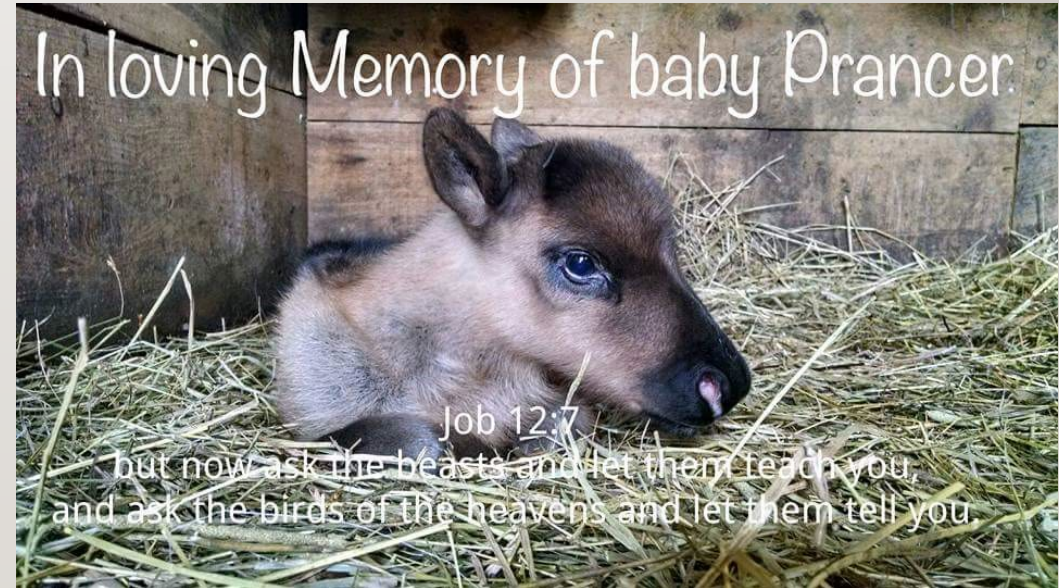

DISCLAIMER

- The content, opinions, and views expressed belong solely to Deb Apthorp, this is intended as a informational approach to a personal journey with my reindeer. I am not affiliated in any way with any of the products included, I am not a veterinarian. This information is NOT intended to replace proper professional veterinary care.

HOW IT BEGAN

- This was the beginning, the real-world slap in the face as to my ignorance with parasites, the lesson learned from a life lost, a journey to absorb as much information as possible to prevent history from repeating itself. This is dedicated to baby Prancer April 20, 2015 – August 24, 2015



WHAT ARE HAEMONCHUS CONTORTUS TREATMENTS

- Defined in the Veterinary parasitology reference manual (fifth edition used) H. Contortus is commonly called barberpole or wire worm. It is a (trichostrongyloidea) it can cause acute anemia, bottle jaw, chronic weight loss in adults and death. It is diagnosed by fecal floatation, we use a McMaster's which gives specific egg counts. In animals who die as a result, upon necropsy adults will be found in the abomasum.
- Drugs used can develop drug resistance
- Treatments commonly used include;
- Albendazole 10mg/kg PO,
- Doramectin 0.2mg/kg IM or SQ,
- Eprinomectin 0.5mg/kg pour on,
- Ivermectin 0.2mg/kg SQ,
- Fenbendazole 5mg/kg PO,
- Levamisole 5-8mg/kg PO cattle dose,
- Morantel tartrate 9.7mg/kg PO
- Moxidectin 0.5mg/kg pour on
- Tetramisole 15mg/kg PO (for sheep do not exceed total 600mg dosage)
- I.) Foreyt William J, *Veterinary Parasitology reference manual 5th edition* (Blackwell Publishing, 2001), 80.
- **Definitions PO stands for by mouth or per orally, IM stands for Intramuscular, SQ or SC stands for Subcutaneous, and pour on stands for pour over the skin without any invasive technique**

COMMON NAMES
AND OTHERS
NOT LISTED -
*AGAIN PLEASE
CONSULT YOUR
VETERINARIAN FOR
USAGE BASED
UPON TESTING
RESULTS AND LEGAL
OR OFF LABEL
USAGES*

- Albendazole (Valbazen)
- Doramectin (Dectomax)
- Eprinomectin (Eprinex Pour On)
- Ivermectin (Ivermec)
- Fenbendazole (Safeguard, Panacur)
- Levamisole (LeviMed Prohibit)
- Morantel tartrate (Mor-Max, Rumatel 88 Strongid C2X, DuMOR goat pellet)
- Moxidectin (Cydectin Quest, Quest Plus)
- Oxibendazole (Anthelcide EQ Synanthic oral suspension 22.5%)
- Pyrantel Pamoate (Pyrantel paste)

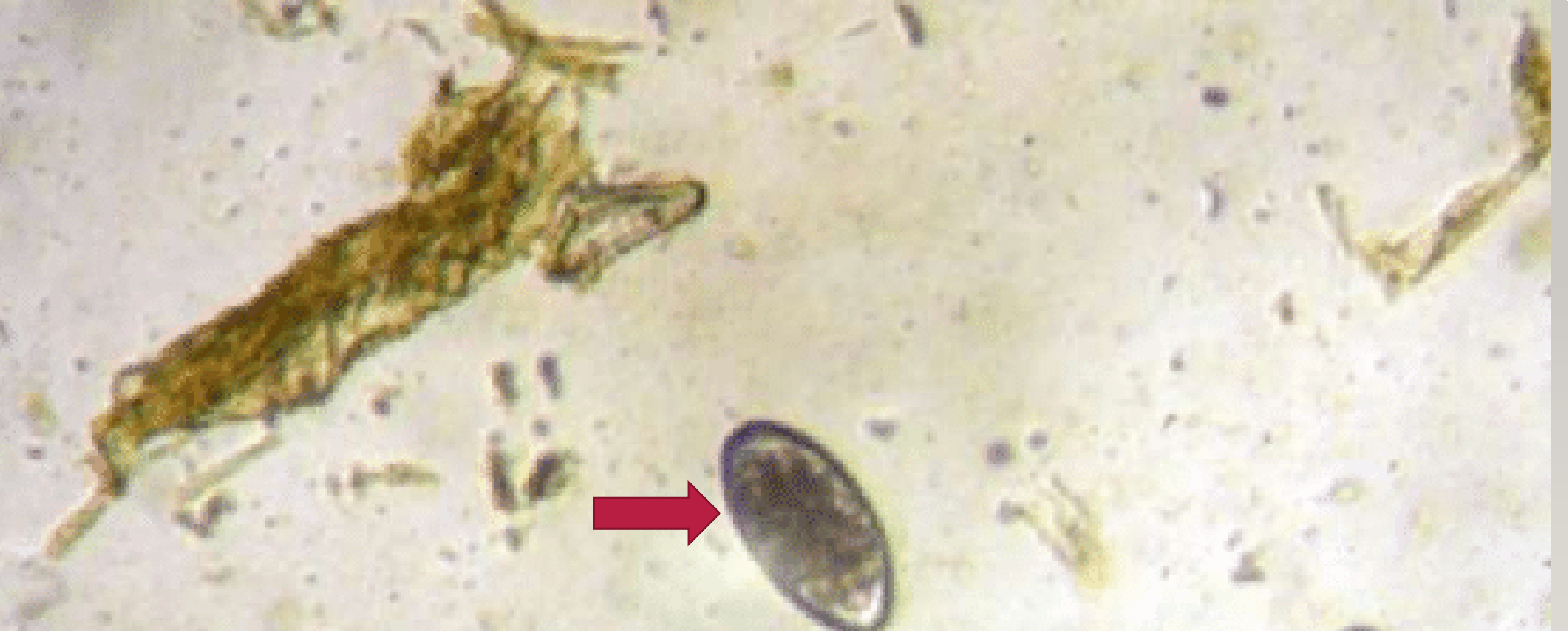NECROPSY RESULTS

- Upon results from VADDS case # 15-29808 9/14/15 it was determined that our 4month old baby reindeer Prancer had died as a result of : *Abomasum: Diffuse chronic moderate mucosal hemorrhage with intraluminal myriad Haemonchus contortus. Mandibular and orbital soft tissues ha moderate edema (bottle jaw seen the pervious day as well as a hepatic abscess.*
- So what did all this mean to a new owner whom had never death with parasites this severe in 2 years, it meant we had affected animals (3 adults) all anemic HCT counts at that time presented at between 11 -28 whereas normal ranges in reindeer fall between 40-45 +/- 5 egg counts were as high as 9700.
- Haemonchus can multiply rapidly with adult females laying as many as 10,000 eggs daily the L3 for of hatching larvae is the infectious form whereas the L4 for attaches and sucks blood in the abomasum resulting in low weights, anemia, poor breeding and death.
- 2.) Ohio State University Veterinary Medical Center, 2015, Necropsy, ID number 000756495
- 3.) AHW, 2015, Idexx laboratory requisition fecal egg count ID:27836 & ID 31021
- 4.) https://en.m.Wikipedia.org/wiki/haemonchus_contortus



WHAT DID WE DO

- Now began a long evolving journey of trials and treatments, constant lab monitoring. It began with a base line HCT test and fecal which we did weekly for 1 month, as we saw increases in HCT and PCV counts we moved to by weekly than monthly and finally arrived at McMasters fecal checks every 6 weeks, Currently 5 years out we have a good protocol and testing can be stretched to 12+ weeks but fecals remain a constant in our care plan. I do not read my own, they are verified by an independent lab, Should we ever choose do learn and preform more testing at our farm, any suspect results should be verified by an independent lab. These parasites are not one to take lightly
- HCT stands for hematocrit a measure of percentage volume of red blood cells
- PVC stands for packed cell volume which is the measurement of proportion of blood that is made up of cells
- Red blood cells are important in carrying oxygen to all body tissues thus keeping muscles and organs alive



WHAT DOES A POSITIVE FECAL LOOK LIKE FOR STRONGYLS

OUR CURRENT REGIMENT

- Fecal every 3 months or sooner if needed
- Separate testing per animal No group samples collected
- Treat only affected (positive) reindeer with moxidectin (quest) paste per body weight
- Daily Strongid C2X pellets given at current weight 1 time daily
- Regular observation of mucus membranes utilizing the FAMACHA scale
- Yearly CBC testing



FAMACHA SCALE

GOAT SCALE

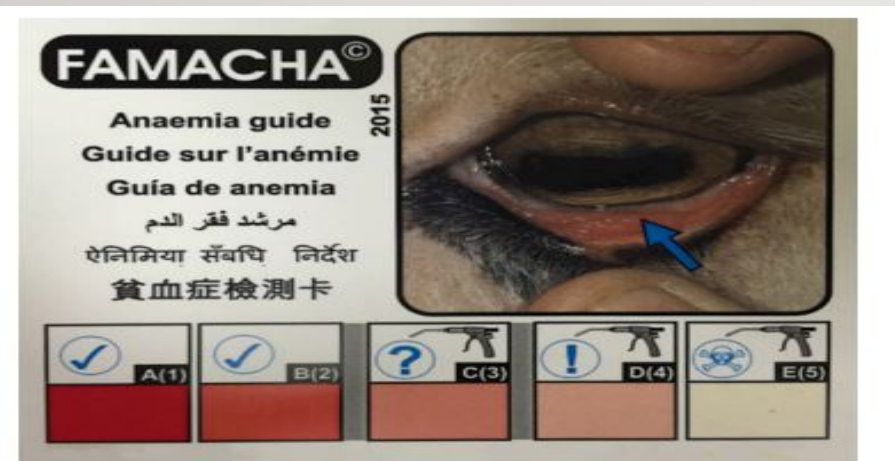
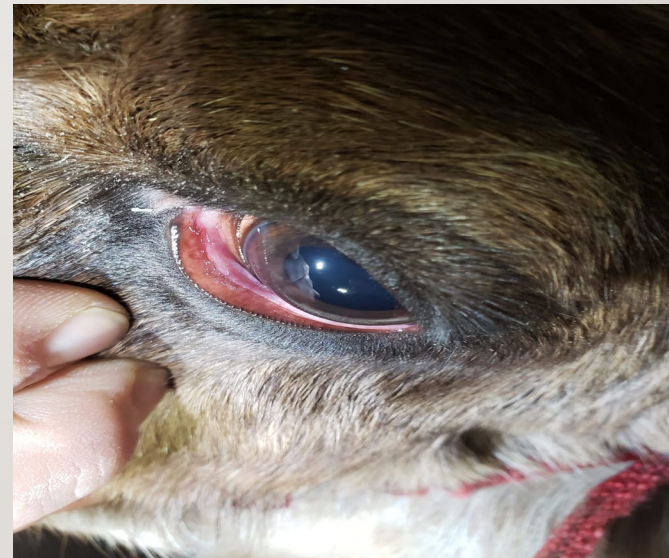
Figure 2. Photo of FAMACHA® scoring chart. Colors are likely not accurate in this publication. Cards are provided to individuals that complete an accredited training workshop. Online training can be found at: <http://web.uri.edu/sheepgoat/famacha/>

ACTUAL PICTURE OF REINDEER AVA



BARBERVAX VACCINE MAYBE ONE DAY...


- When we had lost the battle with haemonchus contortus with our then 4-year-old Donner, and he remained heavily burdened and not responding to moxidectin, and Strongid C2X. I turned to Kyle Wilson, who had led us to the initial treatments, he had come across more hopes in a vaccine developed in Scotland by Moredun Laboratories. The vaccine was being utilized in Australia (who's sheep population have as many problems as we do in the US) with a killed vaccine labeled Barbervax. After months of applying for an import permit to the United States and several emails, calls, and paperwork with Dr. David Smith, the USDA permit was denied for the biological product to be sent to my veterinarians. Donner died that following April due to strictures from the worm scarring his abomasum as well as bleeding ulcers which led to a rupture causing diffuse septic peritonitis. Donner was euthanized while undergoing emergency exploratory surgery due to the findings. My final hopes are to still import or work with the USDA to derive our own vaccine as Dr. David Smith has graciously shared with me the process in our quest to get Donner meds that never came to fruition and study the effects on reindeer.
- 5.) Ohio State University Veterinary Medical Center, 2017, Necropsy, ID# 000760393

UPON
FURTHER
RESEARCH IT
APPEARS WE
ARE CLOSER
TO
BABERVAX
VACCINE IN
THE UNITED
STATES

- This is a really good blog from Cornell University, it covers a broad range of topics pertaining to control of parasites including Haemonchus Contortus
- https://cpb-us-e1.wpmucdn.com/blogs.cornell.edu/dist/e/7832/files/2017/11/New_Worm_Control_Strategies-pt3-resized-sulvvd.pdf

BIOWORM & LIVAMOL WITH BIOWORM

- This product is available within the United States, it is a pasture management tool it appears to not be intended to replace regular monitoring or anthelmintics (wormers). Bioworm is a supplement derived from the *Duddingtonia Flagrans* fungus. After eating absorbing and passing the supplement, the animal eliminates the product in feces. By forming a fungal web Bioworm captures, paralyzes, and consumes the parasites larvae. Effectively breaking the worm cycle. Check out more at Premier I
- www.premierlsupplies.com



THANK YOU

If you need help or have questions with any of this information email me at reindeer@apthorpfarms.com or paramedicdeb4506@gmail.com

