

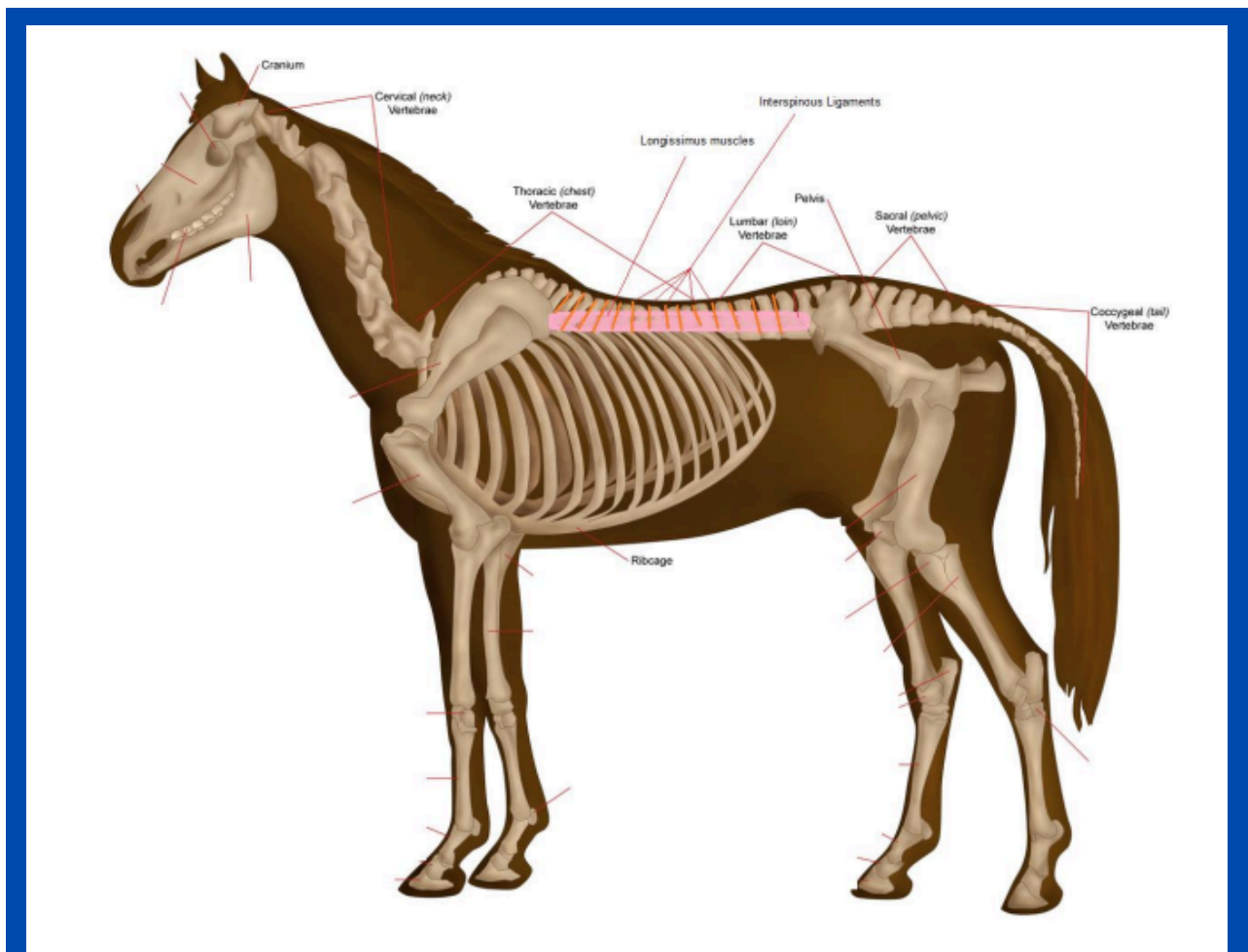


A PAIN IN THE BACK

Dr. Chris Bell BSc, DVM, MVetSc, DACVS

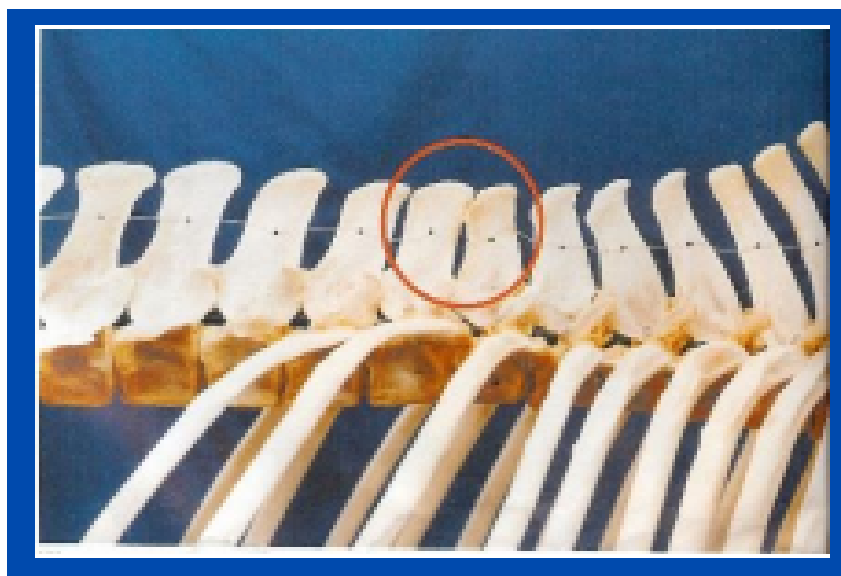
When we think of the many unsoundness issues that we encounter in horses, the back is not often thought of as a primary area of potential pain. Although true that back pain can be a secondary issue to other lameness problem, primary back pain does occur and can be difficult to determine in some cases.

The horse's back consists of many muscle groups and vertebrae that make up the composition of the core of the horse. There are 7 cervical, 18 thoracic and 5-6 lumbar vertebrae that make up the core bony column of the neck and back. From those bones and surrounding them insert and originate many muscle groups with the longissimus and epaxial muscle groups running alongside the spine that make up the strength and flexibility of the back. Many ligamentous structures also course the length of the spine and provide further structure and support to the back (Fig. 1). An extensive anatomic, conformational and physiologic discussion could be had on simply the structure and function of these individual muscles and ligaments but for sake of brevity that will be for another article.



Since the back's function is intimately intertwined with the function performed by the rest of the body, it is no surprise that horse's will get sore backed from many causes. The most common reason for a sore back is compensatory muscle strain resulting from, most typically, hind limb lameness. Hock and stifle pain, either unilateral (one sided) or bilateral (both sides), results from the differential transfer of limb forces into the lumbar region of the back. As the horse unevenly loads the hind limb to relieve pain, particularly at the hock joint, the lumbar muscles undergo increased uneven loading and tension. This results in lumbar and sacral back pain. In the case of stifle associated back pain, the location of the compensatory pain tends to be located at the sacral and croup region but lumbar pain can be quite common as well. From an examination point of view, this lumbar and sacral pain can be palpated with hand pressure through the lumbar musculature and the point of maximal intensity for the pain can be found. As mentioned, this lumbar and sacral pain may be secondary to orthopaedic pain in the hind limbs and when this type of back pain is found, a thorough examination of the hind limbs is recommended. In practice, the most common cause for lumbar pain is osteoarthritis of the hocks – lower hock joint arthritis. As it is a compensatory pain in the lumbar muscles, blocking of the hock may eliminate the hock joint pain, but the back main persists. However, with the hock joint pain appropriately treated, the back pain will generally subside as well.

The sources of primary back pain are less common but no less detrimental to the horse's overall soundness and in many cases can be very limiting to athletic performance if allowed to become chronic in nature. The most common type of primary back pain is called impingement of the dorsal spinous processes or 'kissing spines'. This is a condition where the long bony spines or processes, that protrude upward from the top of the thoracic (mainly) and lumbar vertebrae, begin to rub together (Fig 2). The result is significant pain and inflammation of the bones, ligaments and muscles and a horse that is described as 'cold backed'.

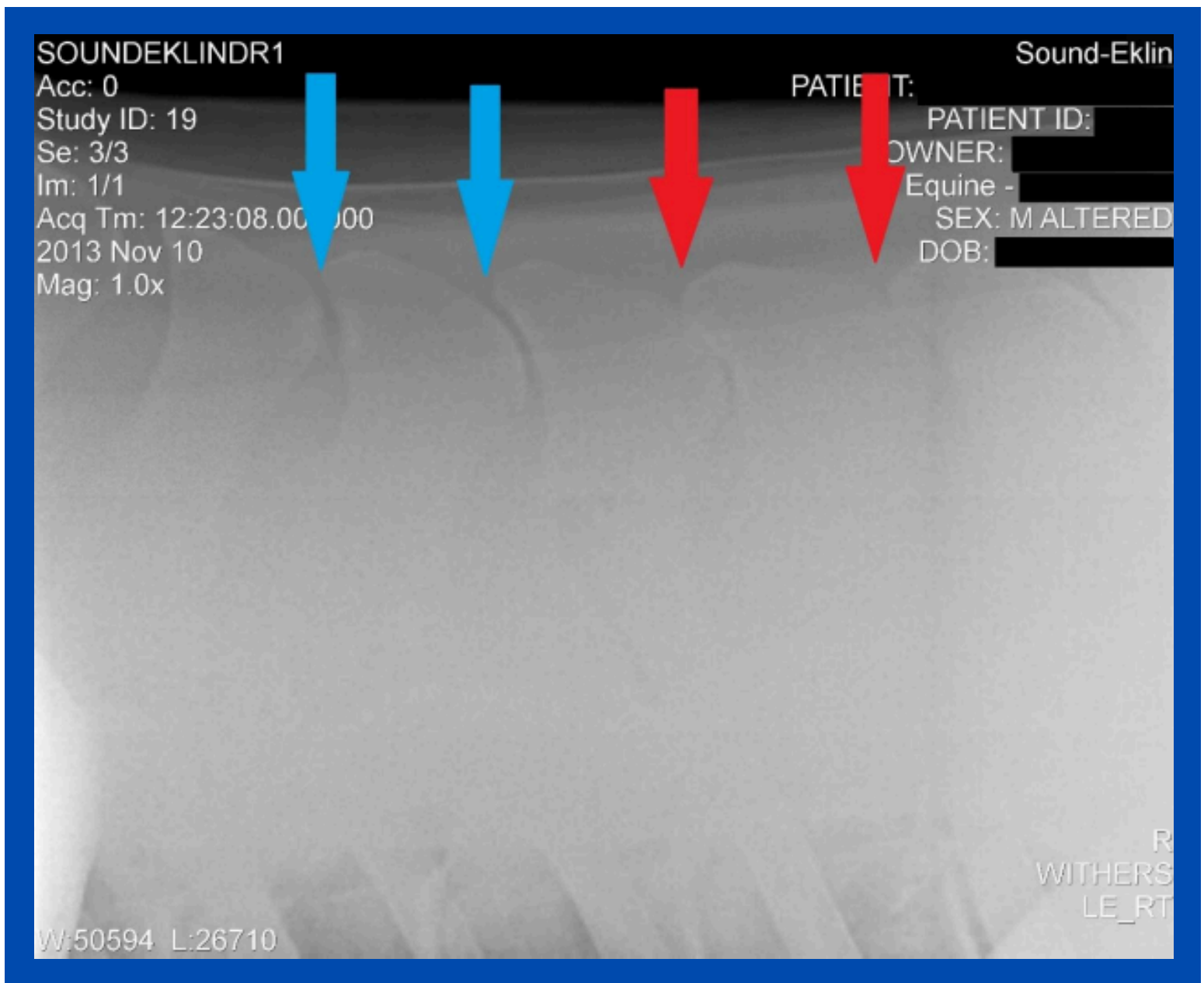


Saddle fit problems are the rote thinking for the cause of many back sore horses. Unfortunately, the saddle fit is often secondary to the primary back problem and plenty of money can be spent on saddles and fitting before coming to the realization of the primary issue. Saddle fit may indeed play an important role in gaining soundness of back in some of these horse but ruling out primary back pain should come prior to changing saddles.



A PAIN IN THE BACK

The diagnosis of kissing spines is performed by your veterinarian. A multi-facet diagnosis requires specific palpation of the dorsal spinous processes and determination of point pain over each process. This is followed by xrays of the processes and identification of overriding processes (Fig 3. Red Arrows) and/or sclerosis (hardening; denser white color on the xray – Fig 3. Blue Arrows) of the processes where they have been touching each other and causing bone on bone irritation. With the diagnosis confirmed, treatment options available include physiotherapy in combination with anti-inflammatories and muscle relaxants for the back as the primary technique. The physiotherapy should consist of back strengthening and rounding exercises to improve a more convex back position and thus separating the processes from interference with each other. This can be achieved with a pessa or surcingle and tie down to work the horse into a rounded position and increase longissimus muscle strength which in turn will pull the processes apart and prevent rubbing of the bone on bone. Working the horse up hills can also help to round the back. The work will usually need to begin without rider as the processes are prone to deeper interference with rider. Usually the first 4-6 weeks are without weight. The physiotherapy is the cornerstone of all the different management options to be discussed.





A PAIN IN THE BACK

In horses that are refractory to physiotherapy and medication alone, the next option is injection of the interspinous ligament and surrounding back musculature with corticosteroids. This has the effect of dramatically decreasing inflammation and allowing relaxation of the interspinous ligament. The interspinous ligament runs between each process, connecting one process to the next in a train like fashion. The trouble with this condition tends to occur as these ligaments become more chronically irritated and the ligaments begin to contract or shorten. The effect of this is the pulling together of the dorsal spinous processes and resultant interference between them. With steroid injection, physiotherapy will be continued and improving results should be seen within 3-4 weeks.

Horses refractory to steroid injection or those with overriding spinous processes on xray are candidates for surgical relief of the interspinous ligaments. There have been many different surgical treatments attempted for relieving impingement of the processes over the past many years. The more modern approach involves severing the interspinous ligament between the affected processes. This relieves the tension of the contracted ligament and allows the processes to go back to a more normal anatomical position – not in contact with each other. Recently, a veterinary paper was published on the outcomes of this procedure in a variety of sport horses and showed very good results and good prognosis with this approach. The procedure is called an interspinous ligament desmotomy (ISDL). This is the procedure used in my practice for surgical management of these horses. It is performed with the horse standing under heavy sedation and thus the anesthesia risks are significantly reduced. It has proven beneficial in several horses and looks to be a viable treatment for horses that cannot be treated by conservative means.

It would be remiss to not cover the benefits that can be provided from alternative medicine modalities. Whether the horse is being managed via a conservative approach or post-operatively, alternative medicine techniques and therapies can be beneficial. Shockwave therapy is used often for back pain as it provides rapid but temporary relief via a number of therapeutic mechanisms and can allow for a more thorough and complete rehabilitation program. The shockwaves improve blood flow to the back and relieve nerve/sensory pain in the muscles while allowing for relaxation of chronically inflamed backs. It is ineffective or only temporary in relief if not combined with an understanding of the primary cause and thus the specific goals of the rehabilitation program prescribed. Acupuncture is another beneficial modality that can provide for relaxation of the muscles in the back and allow for a better rehabilitation. The results of an acupuncture treatment may be temporary but when used in combination with the prescribed program, again, the results can be very rewarding. Chiropractic and massage therapy can play a role in some programs depending on the application of the therapy and the providers understanding of the goals that are hoped to be attained in combination with the prescribed rehabilitation program. A good working relationship with between the veterinary professional and the alternative therapy provider is key as some techniques used by the therapy providers may be detrimental to healing.

The other main source of back pain in the horse relates to the sacroiliac region or SI joints and this will be covered in a future article as the topic is large and deserves its own dedicated review. In brief, sacroiliac pain results from inflammation at the intersection of the sacrum to the ilium (a part of the pelvis) as the vertebral column runs through the pelvis. At this intersection are two ‘joints’ – one of each side of the sacrum connecting to the ilial wings. Inflammation of these joints results in significant pain and can produce a moderate to severe lameness in the hind legs.



A PAIN IN THE BACK

Sacroiliac pain, also known as SI pain, is a mixed type of back pain with some primary source pain combined with secondary issues resulting from hind limb dysfunction and lameness. It is treatable but can be frustrating to diagnose, treat and rehabilitate depending the chronicity and severity of the condition.

There are several other more minor primary back pain condition and of course neurological conditions that will not be covered and reinforces the importance of a thorough veterinary exam when dealing with a potential back issue. Many types of back pain are treatable and can allow your horse to get back to a athletic, pain-free level of performance, whatever that may be, provided the condition can be identified and time taken to rebuild a strong back.



If you have any questions please reach out to our office @ **1-204-864-2888**.
Or you can email at : **office@elderequineclinic.com**