



# NAVICULAR DISEASE

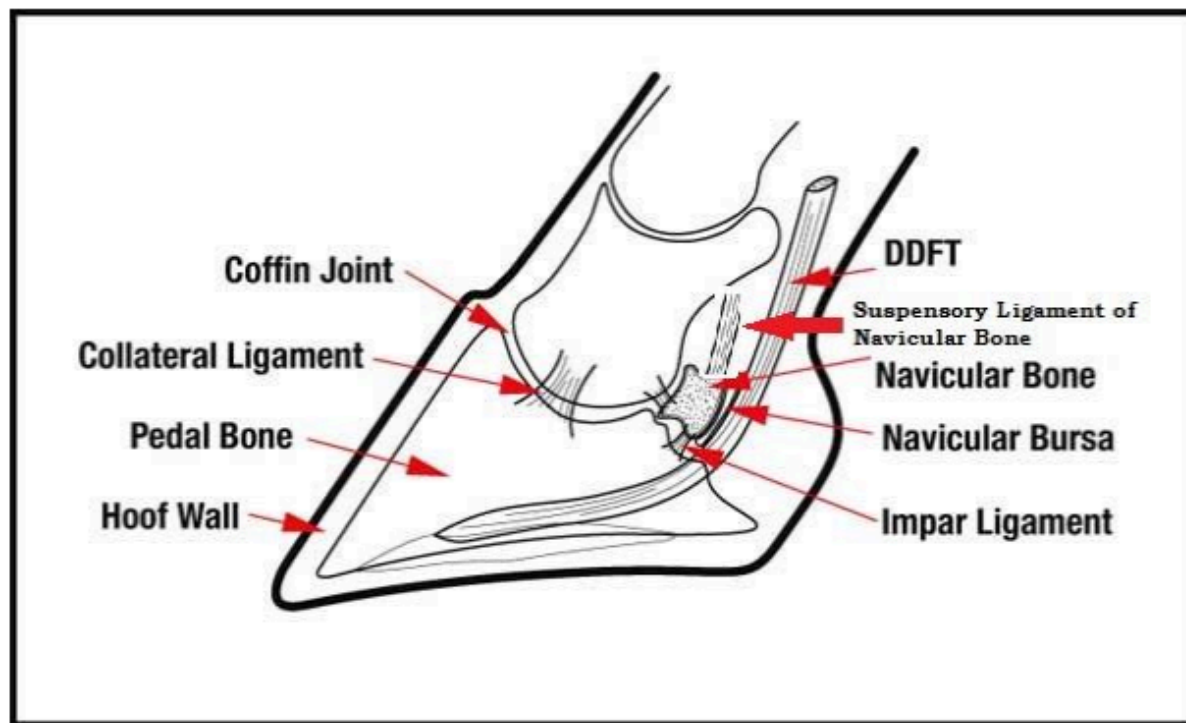
## DEALING WITH NAVICULAR DISEASE

Dr. Chris Bell BSc, DVM, MVetSc, DACVS

Navicular disease is a degenerative condition of the navicular bone and soft tissues in the back of the foot. Over the years there have been many names given to the condition including navicular syndrome, podotrochitis, caudal heel pain or foot pain. The current accepted vernacular for the condition is caudal heel pain. Although a diagnosis of 'navicular disease' can be devastating to hear, there are options to treat your horse and in many cases, with some work, these horses can return to athletic work.

When we talk about navicular disease, we are dealing with a large number of structures that are located in the back of the foot (Fig 1). It is not as simple as saying the navicular bone is damaged or inflamed. The navicular bone is an anatomical fulcrum – it functions to provide a smooth pivot point from the deep digital flexor tendon (DDFT) to travel over the back of the foot and insert onto the bottom of the coffin bone (P3 bone). The DDFT is very tight and puts pressure against the navicular bone as it courses over the back of the foot. If the heels are low and/or the toes are long, then the force exerted by the DDFT against the navicular bone increases. This is a simplified ideal of the situation but helps to illustrate the function and possibility for dysfunction of the navicular bone.

Figure 1



(Courtesy University of Missouri and modified by Dr. Chris Bell)



# DEALING WITH NAVICULAR DISEASE

When conformational unsoundness, farriery, genetics and injury collide, we have the making for inflammation and degeneration of the navicular bone and all the associated soft tissues. In most cases of navicular disease, a soft tissue injury is first thought to occur. This may be from an overextension or a medial/lateral imbalance, twisting or torqueing of the foot. The research to date has not advanced enough to determine exactly how the disease begins, but a soft tissue injury in the back of the foot is thought to occur before the changes to the bone that we see on the xrays begin to appear.

## DIAGNOSING NAVICULAR DISEASE

The diagnosis for navicular disease consists of several important procedures. First, a thorough history should be taken and then the horse will be palpated over all the limbs and back. A hoof tester exam is performed. This is where the vet will pinch on the bottom of the foot with a set of instruments called hoof testers. Horses with navicular pain or caudal heel pain will often flinch when the testers are applied over the frog and sometimes the heels. The horse will be evaluated at a trot in a straight line and both circles on a lunge line. If a forelimb lameness is identified, then the process of nerve blocking would begin. With lameness, the goal of the veterinarian is to isolate lameness to a specific area of the limb. This is done by selectively anesthetizing or 'blocking' the nerves in the leg beginning with the lowest approachable nerves and working up the leg segmentally. With caudal heel pain, the first nerve block performed (palmar digital nerve in the front legs) will usually drastically improve the degree of lameness. Many horses will then switch to a lameness in the opposite limb. Unfortunately, navicular disease is often present in both front feet. There are specialized pressure tests and partial nerve blocks that may be performed to help determine the exact location of a lameness (such as a specific collateral ligament injury) but those are often skipped as they require a revisit of the patient at a later date and did not often add to the diagnosis and treatment plan. Once the limb has been 'blocked to the foot', then the diagnosis moves to imaging of the foot beginning with xrays

## X-RAYS AND MRI'S

The more common soft tissue injuries seen on MRI are DDFT tears, impar ligament strains and tears, suspensory ligament of the navicular bone strains and tears and collateral ligament of the coffin joint and navicular bone strains and tears. There are other structures which can be damaged as well but those are the main ones we see on MRI. When there is injury and early degeneration of these soft tissue structures, the blood flow to the foot increases. Increases in blood flow in response to inflammation results in dilation of the blood vessels. As these dilated vessels push against the base of the navicular bone, the bone begins to resorb in response and we get the pathognomonic 'lollipop' lesions seen on xrays at the base of the navicular bone (Fig 2). These are the most common finding on xrays in horses with navicular disease. This also results in inflammation of the navicular bone itself and we see this on MRI. In some horses, there is injury to suspensory ligament of the navicular bone. In response to this strain or tear of the ligament the body attempts to stabilize the injured area, the body does this by mineralizing the ligament to help prevent further movement of the injured ligament. These are seen on xrays as 'spurs on the wings of the navicular bone' (Fig 3). Occasionally, there will be avulsion fractures of the impar ligament at the base of the navicular bone as well but these are generally only seen on MRI. The other main findings that might be seen on xrays are arthritis of the coffin joint, irregular or scalloped margins of the navicular bone.



# DEALING WITH NAVICULAR DISEASE

Sclerosis (hardening) of the navicular bone and loss of the cortex on the flexor surface of the navicular bone. Xrays are limited to problems with the bone. In order to diagnose soft tissue injuries, MRI or ultrasound must be employed. Ultrasound of the foot is possible but is not very sensitive for picking up small tears and limited in the scope of the area that can be examined through the bottom of the foot. MRI is the gold standard for evaluating the foot for injury. MRI can look both the soft tissues and bone in the foot and most foot MRI exams will give us a look from the bottom of the hoof wall up to the level of the top of the long pastern bone. Common diagnosis made by MRI are DDFT longitudinal tears, impar ligament tears, collateral ligament tears, navicular bursitis etc. – things that cannot be seen on xrays. An MRI can be very important in providing more advanced treatment options for horses with caudal heel pain.

## TREATMENT OPTIONS

When treating a horse with caudal heel pain, the simplest change to make is shoeing/farrier work. The goal of the farrier is to decrease the tension on the deep digital flexor tendon (DDFT) during movement and decrease the pressure over the navicular bone where the disease exists. Many horses that are diagnosed with caudal heel pain can be improved by shortening or squaring the toe. The goal behind this is to create an early point of breakover in the stride. By creating an early breakover point, this decreases the tension on the DDFT. Another technique used, in combination with creating an early breakover, is to elevate the heel with a wedge (either a pad or wedged shoe) or by working to establish more heel wall. By lifting the heel, this decreases the tension along the DDFT over the navicular bone. There are a myriad of shoes designed to specifically treat caudal heel pain and a whole article could be dedicated to shoeing recommendations. The current starting point recommendations in my practice are to shoe the horse in a wide webbed, full fitting, flat shoe with a rolled toe and early breakover and extend the heel by ¼ inch. As your farrier work is very important in treating these horse, ensure your veterinarian and farrier work together to find the best options for your horse.

The next avenue to explore when treating these horses is anti-inflammatories. Since caudal heel pain results from inflammation/injury of the structures in the back of the foot, we can modify the degree of discomfort with medications. The standard anti-inflammatory offered is phenylbutazone (Bute). Bute is an excellent anti-inflammatory for musculoskeletal pain and works well in mild to moderately affected caudal heel pain horses. There are some side-effects to chronic Bute use including gastric ulcers. Not every horse will develop gastric ulcers, but with that concern, there are some alternative options on the market. Firocoxib (Equioxx/Previcox) is an anti-inflammatory that has been gaining popularity as it has a more specific enzyme activity and is thought to decrease the side effects of Bute while providing similar anti-inflammatory/pain suppression qualities. Other anti-inflammatories used are banamine (flunixin meglumine), anafen (ketoprofen), metacam (meloxicam) and others. The typical first line treatment for horses diagnosed with caudal heel pain is therapeutic shoeing and anti-inflammatories.

When the first line treatments fail, the next step your veterinarian will often suggest is to administer anti-inflammatories directly into the joints/bursa affected – the coffin joint and navicular bursa. These are called joint injections or intra-articular injections. The goal is to squelch the inflammation in the foot and provide a better degree of soundness for a period of time.



# DEALING WITH NAVICULAR DISEASE

The anti-inflammatories used are often corticosteroids such as methylprednisolone (Depo-Medrol or similar) or triamcinolone (Vetalog, Kenalog or similar). Other steroids also can be used. These are powerful anti-inflammatories that block the inflammation production in the region they are injected. The choice of navicular bursa versus coffin joint injection may be guided by veterinarian's preference, clinical signs (coffin joint effusion) or based on a specific diagnosis (MRI, contrast CT, or ultrasound based). With joint injections, the joint or bursa is sterilely prepared and the injection performed in a sterile manner. There is a small risk of joint infection and many veterinarians will include a small amount of antibiotic with the injection. The steroids generally take about 10-14 days to produce noticeable improvement and you can generally expect between 3-12 months of soundness depending on the severity of the disease. An important caveat to navicular bursa injections is that the xrays should be closely evaluated to ensure that a flexor cortex lesion is not seen as research indicates that those horses will not respond to injections and should be retired rather than continued in athletic work.

There are numerous other medical treatments out there for caudal heel pain. Some of the more common treatments are hyaluronic acid (HA, Acid etc.), Tildren (Tiluronic acid) and shockwave therapy. Hyaluronic acid is a joint medication that is injected into the joint or given intravenously to help decrease inflammation of the synovial lining of the joint as well as provide some support to the joint fluid. It can be combined with steroids in the joint/bursa injection or can be used alone in the joint or administered intravenously. Tildren is a human osteoporosis medication that gained popularity about 3- 5 years ago for use in horses with suspected navicular bone resorption lesions as a result of inflammation. The medication works to suppress bone loss and thought to decrease inflammation as a result. It is administered either IV or by regional perfusion into the foot. Tildren can be effective if used in very specific situations but can be very expensive and ineffective if not appropriately used. Shockwave therapy aims to provide pain relief and increase healing of tendon and ligament injuries. It is applied directly over the heels and coffin joint as necessary and repeated at 2-3 week intervals for 3-6 treatments.

More recently, regenerative medicine or biologics have begun to be used in horses with various caudal heel injuries and inflammatory conditions. These include stem cell therapy, platelet rich plasma therapy and interleukin-1 receptor antagonist protein (IRAP) treatments. Most of these therapies remain unproven in the treatment of caudal heel pain but can be used successfully in specific cases to target treatment of specific lesions or conditions. In my practice, we have had success with the use of biologics when combined with rehabilitation programs and targeted treatments.

## **SURGICAL TREATMENTS**

There are some surgical options for horses with caudal heel pain. The main surgical option discussed is a neurectomy. This is a procedure where the nerves supplying the back of the foot are severed and sensation removed. This will generally produce soundness in the foot, however, there are some drawbacks which make this option a salvage procedure that should be reserved for when medical management fails. The main drawbacks are the horse could sustain injury or infection in the foot and not alert you to the problem until it's too late, rupture of the DDFT, neuroma (painful post-operative complication) and nerve regrowth – usually over 3-5 years



# DEALING WITH NAVICULAR DISEASE

Once nerve regrowth occurs, second neurectomy becomes very difficult or not possible. This option can provide pain relief but generally only for a 3-5 year period of time. Horses can perform athletically, however, careful monitoring is required and can be discussed with the surgeon. Recent MRI research has also given some more definitive timelines for the length of time soundness can be expected following neurectomy and this can be discussed with your surgeon as well.

There have been some recent advancements in the surgical management of particular lesions in caudal heel pain. Surgical debridement of DDFT adhesion between the navicular bone and the DDFT within the navicular bursa has shown some promise as well as transection/cutting of particular ligaments of the navicular bone may be an option for some horses. An MRI or contrast CT diagnosis is often needed for these cases.

## CONCLUSIONS

By whatever name it is known, caudal heel pain or navicular disease is a chronic condition of the foot that results in pain and performance limiting lameness in the horse. Most commonly affect the forelimbs only and can appear to be a 'shoulder' lameness. Accurate diagnosis is very important and consists of a thorough exam with appropriate imaging (xrays to begin with). The treatment options are good and can produce a sound, athletically useable horses for many years to come following an initial diagnosis in most cases. If all options fail, surgical removal of sensation to the feet can allow for a 3-5 year period of pain free life to allow for retirement or modified athletic work. Research on the causes and treatments for this condition is constantly evolving and there is hope for even better outcomes in the coming years.



If you have any questions please reach out to our office @ **1-204-864-2888**.  
Or you can email at : **[office@elderequineclinic.com](mailto:office@elderequineclinic.com)**