

Change in Lower Eyelid Contour Following Ectropion Repair With Lateral Tarsal Strip

William Young, B.S., Stacy M. Scofield-Kaplan, M.D., R. Evan Levy, M.D., Zachary Keenum, M.D.,
and Ronald Mancini, M.D., F.A.C.S.

Department of Ophthalmology, UT Southwestern Medical Center, Dallas, Texas, U.S.A.

Purpose: To evaluate the change in lateral canthal angle (LCA), inferior ocular surface exposed (IOSE), lower eyelid curvature, and margin-to-reflex distance 2 in those undergoing lower eyelid ectropion repair using a lateral tarsal strip technique.

Methods: This is an Institutional Review Board-approved retrospective analysis of patients undergoing lower eyelid ectropion repair. This study included all patients from 2012 to 2018 operated on by a single surgeon at the University of Texas Southwestern Medical Center. For each patient, LCA, IOSE, and eyelid curvature were measured on preoperative and postoperative photographs using NIH Image J photographic analysis. These measurements were compared using paired 1-tail *t*-tests for LCA and IOSE and paired 2-tail *t*-tests for eyelid curvature. This study was Health Insurance Portability and Accountability Act-compliant with protection of individually identifiable information.

Results: Fifty-one patients with lower eyelid ectropion underwent lower eyelid ectropion repair using a lateral tarsal strip technique. Forty-three of the patients underwent a bilateral lower eyelid ectropion repair. There was no statistically significant difference in the LCA. There was a reduction in IOSE among both cohorts. The fourth degree polynomial trendlines generated to assess eyelid curvature demonstrated statistical significance, suggesting a flattening of eyelid curvature. margin-to-reflex distance 2 also had a statistically significant decrease postoperatively.

Conclusions: Lower eyelid ectropion repair using a lateral tarsal strip approach causes a reduction in IOSE, a more gradual lower eyelid curvature, and a decrease in margin-to-reflex distance 2 without causing a statistically significant change in LCA.

(*Ophthalmic Plast Reconstr Surg* 2020;36:557–561)

Age-related changes in the lateral canthal angle have been well documented in the pathogenesis of the aging face.¹ Lower eyelid ectropion repair using a lateral tarsal strip technique provides restoration of lower eyelid tone and position, which improves the lower eyelid function and recreates a youthful appearance. Prior studies measuring eyelid curvature have mainly focused on the upper eyelid position in the setting of thyroid eye disease or blepharoptosis.^{2–7} Lower eyelid curvature

has been reported following the surgical correction of thyroid eye disease.^{5,7} The authors evaluated the relationship between lower eyelid curvature, lateral canthal angle (LCA), and inferior ocular surface exposed (IOSE) both before and after lower eyelid ectropion repair using digital photographic analysis.

METHODS

This study was approved by the University of Texas Southwestern Institutional Review Board. The authors retrospectively reviewed the medical records of consecutive patients who underwent lower eyelid ectropion repair by a single oculoplastic surgeon (R.M.) from 2012 to 2018. The lower eyelid ectropion repair was performed as follows. A lateral canthotomy and inferior cantholysis was created and a lateral tarsal strip was fashioned by denuding the eyelid margin epithelium and recessing the anterior lamella. A 5-0 double-armed prolene suture was then passed in a horizontal mattress fashion through the created tarsal strip. This suture was then passed intraorbitally incorporating a purchase of periosteum at the arcus marginalis with the needle exiting the orbit 2 mm superior to the medial canthus. The second arm of the suture was passed through the same tissues in a slightly different pathway to create the horizontal mattress suture. The lateral canthus was closed with interrupted 6-0 fast absorbing gut suture.

This study only included patients with involutional lower eyelid ectropion; those with cicatricial or mechanical ectropion were excluded. Patients were excluded if they did not have preoperative and a postoperative follow-up photograph at least 60 days from the time of surgery, if the patient had a negative orbital rim vector, if the patient had prior surgery that affected the lower eyelid or lateral canthal angle position, or if the patient had concurrent lower eyelid surgery such as lower blepharoplasty. Preoperative and postoperative patient photographs were analyzed using Image J software (obtained from the NIH website). Each photograph was initially standardized to size by an accepted corneal diameter of 11.64 mm for female patients and 11.77 mm for male patients by drawing a line representing the corneal diameter and then setting this dimension as the accepted corneal diameter mentioned above.⁸ Using this calibration, the LCA, IOSE, and eyelid curvature were measured. The LCA was defined as the angle formed by a line drawn between the medial and lateral canthi and a line drawn from the lateral canthus to a point on the lower eyelid margin. The point on the lower eyelid margin was standardized as the intersection of a vertical line drawn from the lateral limbus (Fig. 1A). The superior half of the LCA was not measured to avoid confounding upper eyelid pathologies or prior operations. For the same reason, IOSE was measured as an enclosed area bounded by a line drawn following the margin of the lower eyelid and connecting the inferior punctum to the lateral canthus (Fig. 1B). Eyelid curvature was determined by plotting points along the lower eyelid margin at 15° intervals from the lateral canthus to the inferior punctum (Fig. 2).^{2,5–7} Then, a fourth degree polynomial trendline, following the general structure of $y = ax^4 + bx^3 + cx^2 + dx + e$, was generated for each individual case, where y represents the vertical position of the curve for any horizontal x coordinate.⁶ The polynomial coefficients a , b , c , d , and e are numbers that help to determine the curvature of the trendline. The coefficient values for

Accepted for publication February 8, 2020.

The authors have no financial or conflicts of interest to disclose.

Presented at the Fall ASOPRS Meeting 2019, Poster.

Address correspondence and reprint requests to Ronald Mancini, M.D., F.A.C.S., Department of Ophthalmology, University of Texas Southwestern Medical Center, 5323 Harry Hines Blvd., Dallas, TX 75390-9057. E-mail: Ronald.Mancini@utsouthwestern.edu

DOI: 10.1097/IOP.0000000000001634

each of these individual trendlines were then averaged, creating an average preoperative and postoperative polynomial equation for right and left eyes. Each of the coefficients in the polynomial trendline were evaluated with a paired 2-tail *t*-test to evaluate for a change in eyelid curvature. As the absolute value of the coefficient increases, its impact on the curvature increases. Additionally, if the absolute value of the coefficient decreases, the overall curvature of the trendline becomes flatter. The origin of the plane used to plot the scatter points and generate the trendlines correlates to the center of the pupil. Therefore, the *y*-intercept, coefficient *e*, is equivalent to the MRD-2. Paired 1-tail *t*-tests were used to compare the LCA and IOSE, while paired 2-tail *t*-tests were used to compare mean eyelid curvature coefficients and MRD-2. A *p* value of less than 0.05 was considered statistically significant. This study was Health Insurance Portability and Accountability Act-compliant with protection

of individually identifiable information and adhered to the tenets of the Declaration of Helsinki as amended in 2013. Patient consent was obtained for use of identifiable clinical photographs.

RESULTS

Fifty-one patients were identified who underwent lower eyelid ectropion repair—33 females and 18 males with an average age of 73.4 ± 7.6 years. Of these 51 patients, 43 underwent bilateral lower eyelid ectropion repair. On average, the postoperative follow-up photography was 267 days, with a range of 61 days to 5 years.

There was no statistically significant change in the LCA when comparing preoperative and postoperative measurements in both right and left eyes (Table 1, Fig. 3). While there was a decrease in the IOSE postoperatively in both right and left eyes, the change was only statistically significant in the left eye cohort (Table 1, Fig. 4).

Eyelid curvature was evaluated by the aforementioned polynomial equations as shown in Table 2. There was a statistically significant decrease in the absolute value of coefficient *b* in right eyes as shown in Table 2 and Figure 5. In both right and left eyes, there was a statistically significant decrease in the absolute value of coefficients *d* and *e*/MRD-2 postoperatively (Table 2, Figs. 5 and 6). These aforementioned changes can also be visualized by the net trendlines generated in Figures 5 and 6. There was also a decrease in coefficients *a* and *c*, but this was not a statistically significant change. These coefficients in the polynomial function are surrogates for the degree of eyelid curvature and their absolute value decrease indicates flattening and softening of eyelid curvature.

DISCUSSION

The evaluation of eyelid curvature in the literature has mainly focused on upper eyelid position in thyroid eye disease and blepharoptosis or the lower eyelid curvature following surgical correction of thyroid eye disease.²⁻⁷ In the evaluation of patients undergoing lower eyelid ectropion repair using a lateral tarsal strip approach, the authors found a statistically significant change in lower eyelid curvature measurements without a statistically significant change in the LCA.

The lack of any statistically significant change in lateral canthal angle was surprising, as the authors anticipated there would be a decrease in the lateral canthal angle postoperatively. The most likely explanation for this finding is akin to the theory of diminishing returns. When a slack line suspended between fixed points is tightened, the largest vertical delta will be in the center of the line with the smallest delta being closest to the fixed points. Therefore, although the tendon is tightened laterally, the vertical delta of elevation at the lateral limbus is less than in the central eyelid.

The statistically significant change in IOSE in only the left eye cohort was similarly surprising. While there was an overall decrease in IOSE postoperatively in both the right and left eye cohorts, only the left eye cohort had a statistically significant change with a *p* value of 0.014. It is possible that lower eyelid ectropion repair using a lateral tarsal strip reduces scleral exposure as a means of improved patient comfort, but the results only support this for the left eye cohort in regards to IOSE.^{9,10} It

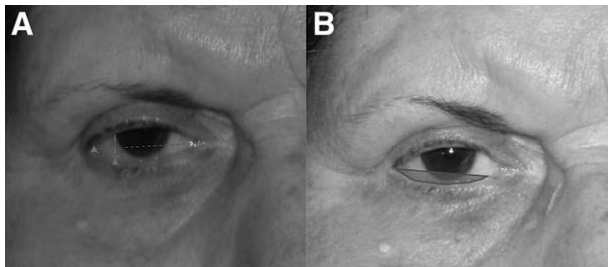


FIG. 1. Illustration of the measurement of LCA and IOSE. In (A), the LCA is the angle from the dotted line between the medial and lateral canthus and the dotted line from the lateral canthus to the lower eyelid margin (intersection point from a vertical line from the lateral limbus). In (B), IOSE is shown as the enclosed area between a line drawn from the inferior punctum to lateral canthus connecting to the margin of the lower eyelid. IOSE, inferior ocular surface exposed; LCA, lateral canthal angle.

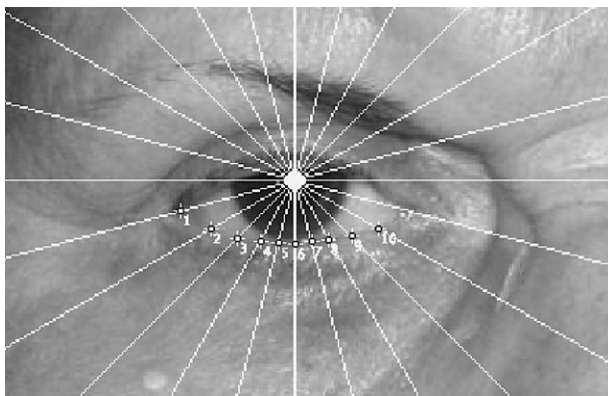


FIG. 2. Illustration of how eyelid curvature points were plotted at the medial and lateral canthus and along the lower eyelid margin at 15° intervals.

TABLE 1. Preoperative, postoperative, and *p* values for LCA and IOSE in both right and left eye cohorts

Right eye LCA (n = 48)			Left eye LCA (n = 46)		
Preoperative	Postoperative	<i>p</i>	Preoperative	Postoperative	<i>p</i>
29.78 ± 6.78	29.66 ± 5.49	0.455	29.41 ± 6.75	28.33 ± 5.35	0.120
Right eye inferior ocular surface exposed in mm ² (n = 48)			Left eye inferior ocular surface exposed in mm ² (n = 46)		
Preoperative	Postoperative	<i>p</i>	Preoperative	Postoperative	<i>p</i>
35.78 ± 11.94	34.40 ± 9.04	0.175	35.49 ± 11.48	32.47 ± 8.74	0.014

IOSE, inferior ocular surface exposed; LCA, lateral canthal angle.

is possible that with increased patient numbers this notion would be further supported by the right eye cohort as well. Another possible explanation for the lack of significant reduction in IOSE is that some patients, such as the one pictured in Figure 4, presented with dystopic lateral canthi. Inferior malpositioning

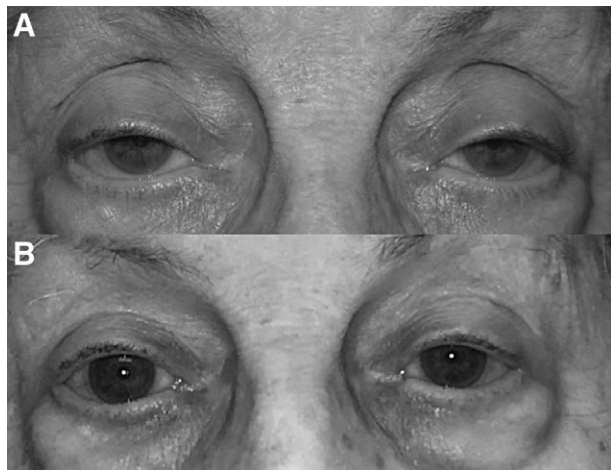

FIG. 3. Illustration showing changes in eyelid parameters following bilateral lower eyelid ectropion repair. Preoperative (A) and postoperative (B) photographs showing an unchanged LCA, decrease in IOSE and decrease in MRD-2 following bilateral lower eyelid ectropion repair. IOSE, inferior ocular surface exposed; LCA, lateral canthal angle; MRD-2, margin-to-reflex distance 2.

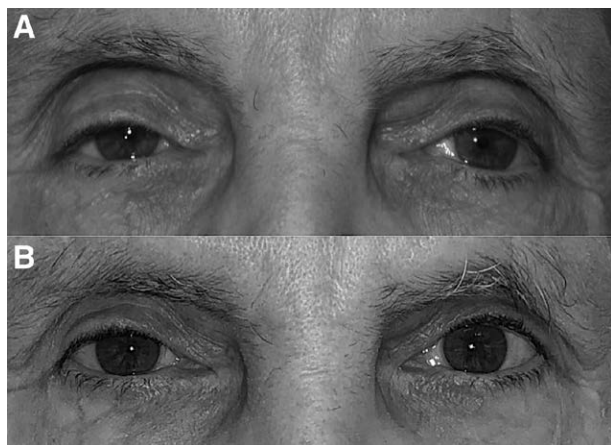

FIG. 4. Influence of dystopic lateral canthi on IOSE measurements. Preoperative (A) and postoperative (B) photographs showing a relative increase in IOSE following bilateral lower eyelid ectropion repair. IOSE, inferior ocular surface exposed.

of the lateral canthus places it nearer to the inferior punctum in the coronal plane. The limited vertical difference between these two points impacts the preoperative measurement of IOSE by the method demonstrated in Figure 1B. Following surgery, these patients had elevated lateral canthi, increasing IOSE.

Lower eyelid curvature should change following lower eyelid ectropion repair due to correction of lower eyelid laxity and improved lower eyelid position. Coefficients in a polynomial equation describe the curvature of the line with a decrease in the absolute value of the coefficient indicating a flatter or more gradual curvature of the lower eyelid. The absolute value of all the coefficients decreased, but statistical significance was achieved with only *b*, *d*, and *e*. This indicates that the lower eyelid curvature postoperatively became flatter or more gradual when compared with the preoperative curvature. Additionally, the MRD-2 is equivalent to *e* coefficient and was statistically significantly reduced between preoperative and postoperative time points. These findings physiologically agree with the authors' anatomic understanding that by tightening the attachment of the tarsus to the periosteum, the horizontal laxity is reduced and the eyelid curvature is similarly reduced or flattened.^{9,10}

This study has inherent limitations. Although photography was performed using a previously established and standardized technique with the patient in the frontal position, eyelids open, and facial muscles relaxed, there is still potential for variations that can affect measurements.¹¹ Another potential limitation was the inclusion of patients with upper eyelid pathology, but measuring only the inferior portion of the LCA controlled this variable. Building a cohort without upper eyelid pathology may provide a better assessment of the LCA.

Overall, there was a statistically significant change in some of the lower eyelid curvature measurements, which indicates a more gradual lower eyelid curvature. There was also a statistically significant decrease in the IOSE in the left eye cohort and a significant decrease in the MRD-2 in both right and left eyes that underwent lower eyelid ectropion repair using a lateral tarsal strip technique. There was no statistically significant change in LCA.

REFERENCES

1. Odunze M, Rosenberg DS, Few JW. Periorbital aging and ethnic considerations: a focus on the lateral canthal complex. *Plast Reconstr Surg* 2008;121:1002–1008.
2. Choudhary MM, Chundury R, McNutt SA, Perry JD. Eyelid contour following conjunctival mullerectomy with or without tarsectomy blepharoptosis repair. *OPRS* 2016; 32:361–365.
3. Danesh J, Ugradar S, Goldberg R, et al. Significance of early postoperative eyelid position on late postoperative result in Mueller's muscle conjunctival resection and external levator advancement surgery. *Ophthalmic Plast Reconstr Surg* 2018;34:432–435.
4. Danesh J, Ugradar S, Goldberg R, et al. A novel technique for the measurement of eyelid contour to compare outcomes following Muller's muscle-conjunctival resection and external levator resection surgery. *Eye (Lond)* 2018;32:1493–1427.

TABLE 2. Lower eyelid curvature polynomial equations for right and left eye cohorts showing each coefficient preoperatively and postoperatively in millimeters along with the associated *p* value

Right eye polynomial (n = 48)				Left eye polynomial (n = 46)			
Coefficient	Preoperative	Postoperative	<i>p</i>	Coefficient	Preoperative	Postoperative	<i>p</i>
<i>a</i>	5.084E-05	6.175E-05	0.465	<i>a</i>	8.938E-05	7.653E-05	0.650
<i>b</i>	-7.324E-04	-2.110E-04	0.014	<i>b</i>	2.495E-04	-1.213E-04	0.090
<i>c</i>	2.586E-02	2.489E-02	0.466	<i>c</i>	2.579E-02	2.554E-02	0.848
<i>d</i>	0.1132	8.096E-02	0.006	<i>d</i>	-9.412E-02	-5.586E-02	0.046
<i>e</i> /MRD-2	-6.082	-5.605	0.001	<i>e</i> /MRD-2	-5.827	-5.332	0.0005

Statistically significant values shown in bold.

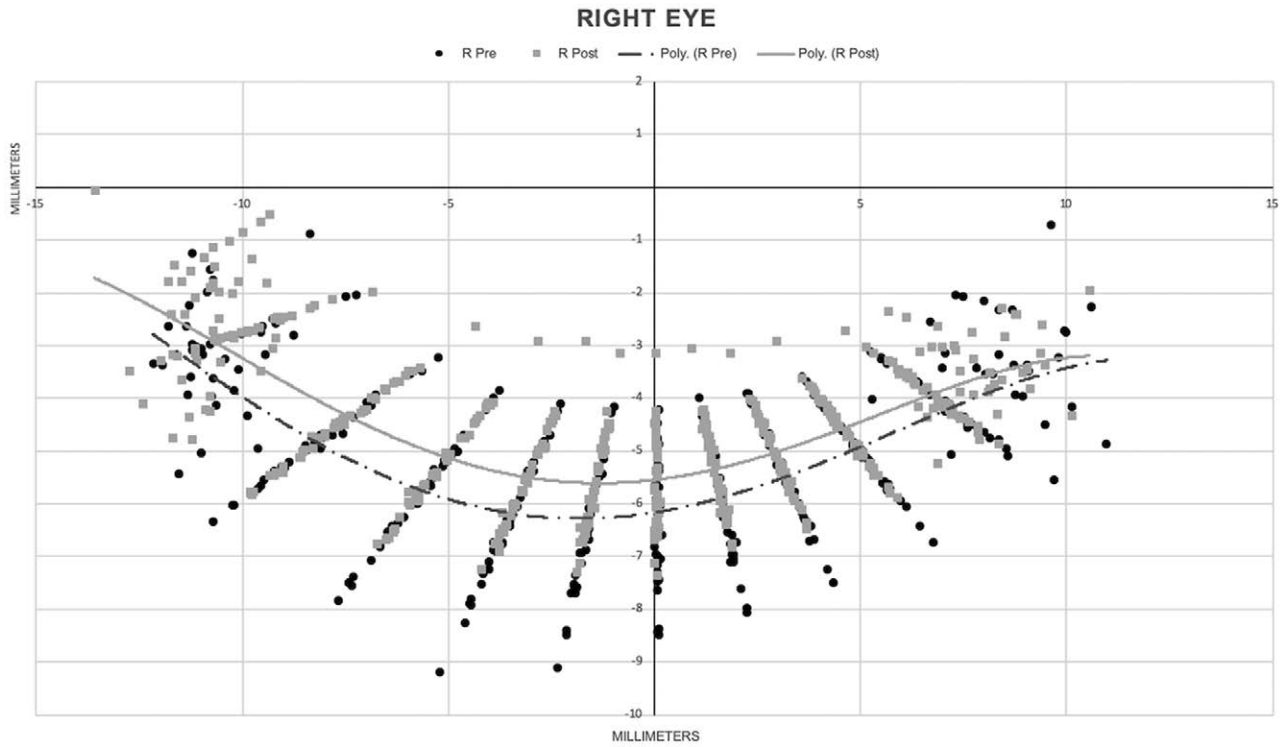


FIG. 5. Lower eyelid curvature in right eyes showing preoperative points (black circles) and postoperative points (gray squares) along with the net trendline generated for preoperative (black) and postoperative (gray) points.

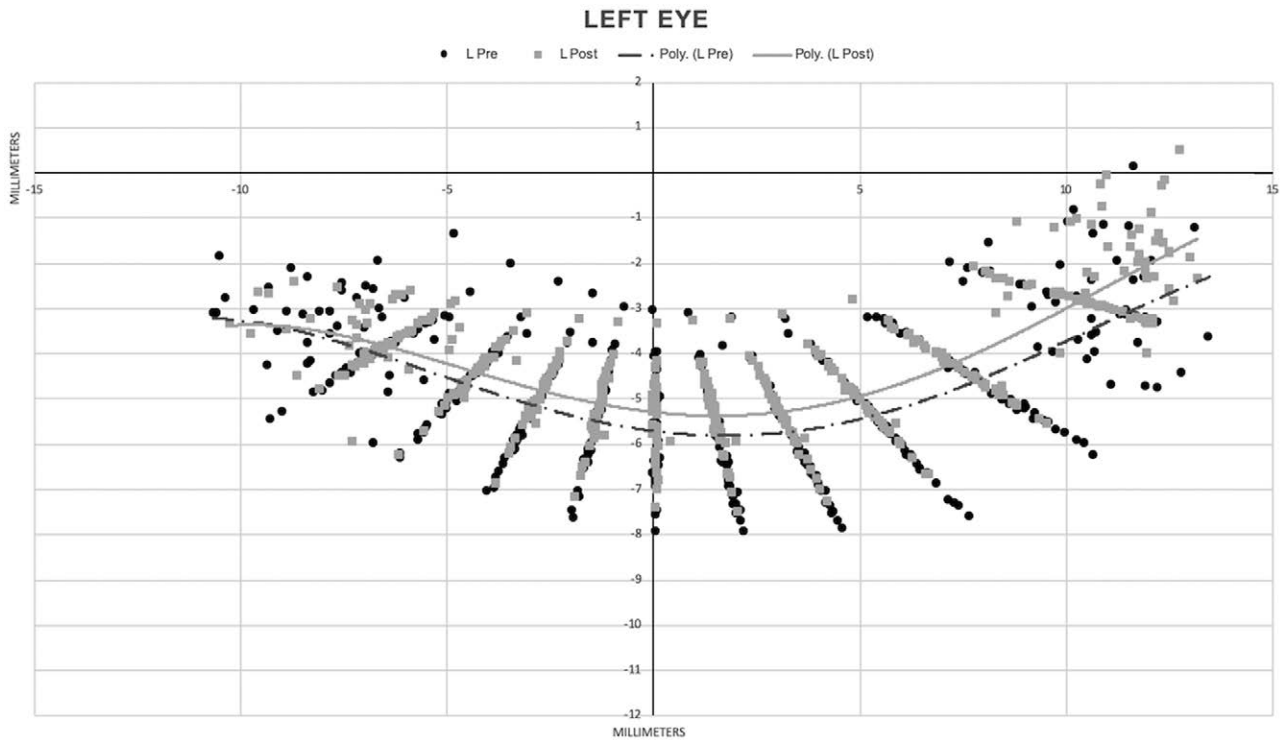


FIG. 6. Lower eyelid curvature in left eyes showing preoperative points (black circles) and postoperative points (gray squares) along with the net trendline for preoperative (black) and postoperatively (gray) points.

5. Kang D, Lee J, Park J, et al. Analysis of lid contour in thyroid eye disease with upper and lower eyelid retraction using multiple radial midpupil lid distances. *J Craniofac Surg* 2016;27:134–136.

6. Mocan MC, Ilhan H, Gurcay H, et al. The expression and comparison of healthy and ptotic upper eyelid contours using a polynomial mathematical function. *Curr Eye Res* 2014;39:553–560.

7. Pieroni Goncalves AC, Gupta S, Monteiro MLR, et al. Customized minimally invasive orbital decompression surgery improves lower eyelid retraction and contour in thyroid eye disease. *Ophthalmic Plast Reconstr Surg* 2017;33:446–451.
8. Rüfer F, Schröder A, Erb C. White-to-white corneal diameter: normal values in healthy humans obtained with the Orbscan II topography system. *Cornea* 2005;24:259–261.
9. Jindal K, Sarcia M, Codner MA. Functional considerations in aesthetic eyelid surgery. *Plast Reconstr Surg* 2014;134:1154–1170.
10. Liebau J, Schulz A, Arens A, et al. Management of lower lid ectropion. *Dermatol Surg* 2006;32:1050–1056; discussion 1056–7.
11. Edwards DT, Bartley GB, Hodge DO, et al. Eyelid position measurement in Graves' ophthalmopathy: reliability of a photographic technique and comparison with a clinical technique. *Ophthalmology* 2004;111:1029–1034.