

# Excision of Periorbital Hemangiomas to Correct Visual Abnormalities

Daniel Schneider, MD; Michael S. Lee, MD; Andrew R. Harrison, MD; James Sidman, MD

**Objective:** To determine whether early surgical excision of complicated periorbital hemangiomas (CPHs) reversed refractive errors and prevented further visual complications; CPHs can cause visual complications including astigmatism, strabismus, and occlusion of the visual axis with resultant amblyopia.

**Design:** Retrospective review of patient series from a tertiary care pediatric referral center. Nine patients with CPHs were managed by otolaryngology and ophthalmology services with complete surgical excision. Preoperative eye examination findings were compared with postoperative findings.

**Results:** Comparison of preoperative and postoperative refraction measurements and/or eye examination findings indicated reduction of astigmatism and substantial improvement in vision as measured by refractive changes and reduction of pupillary occlusion.

**Conclusions:** Total excision of CPHs is a safe and effective approach. When completed early, excision provides definitive therapy, reduces or eliminates astigmatism, and can prevent amblyopia in pediatric patients when pupillary occlusion is present.

*Arch Facial Plast Surg.* 2011;13(3):195-198

**H**EMANGIOMA OF INFANCY (HOI) is the most common vascular tumor in children, with an estimated incidence of 4% to 10% in the first year of life. Approximately 80% of hemangiomas occur in the head or neck.<sup>1</sup> The specific cause of hemangioma formation is unclear. There is a higher incidence of HOI in premature infants.

The natural history of HOI is biphasic, with an early period of rapid growth (proliferating phase) often seen in the first 2 weeks of life and lasting up to 1 year followed by a slow regression period (involuting phase) over 5 to 8 years. Fifty percent of HOIs involute completely by age 5 years, and 70% by age 7 years.<sup>2</sup> Hemangiomas can proliferate in the superficial and/or deep dermis. Eighty percent of lesions are isolated; the remaining 20% occur at multiple sites.

The benign history of most hemangiomas allows for careful observation. However, periorbital hemangiomas can induce astigmatism and may threaten normal visual development owing to obstruction of the visual axis that manifests as ptosis, gaze obstruction, or visual field defects. The most common cause of subsequent amblyopia is a result of anisometropic amblyopia.<sup>3</sup> Anisometropic amblyopia is defined as a measurable difference in refraction or focusing errors between the 2 eyes

and is associated with periorbital hemangiomas because of the pressure placed on the anterior segment of the eye.

Current accepted treatment for periorbital hemangiomas to prevent permanent visual loss includes careful observation, administration of systemic and intralesional steroids, propranolol, interferon therapy, superficial radiotherapy, laser therapy, and surgery. Each has its own associated complications and response rate.<sup>4,5</sup> Surgery for these lesions has been criticized in the past owing to concern over postoperative scarring, infection, and risk to the eye and adnexal structures.<sup>6</sup>

In the present case series of patients, we examine the multidisciplinary treatment by the otolaryngology and ophthalmology services of complicated periorbital hemangiomas treated with surgery to reverse pupillary occlusion, refractive changes, and/or abnormal ophthalmologic eye examination findings to prevent permanent amblyopia.

## METHODS

Nine children treated with surgery at Children's Hospitals and Clinics of Minnesota and the University of Minnesota Medical Center between 2003 and 2007 were identified. All children treated were younger than 11 months and underwent ophthalmologic examination by non-surgical ophthalmologists prior to surgery. Patient characteristics are summarized in the **Table**.

**Author Affiliations:**  
Departments of Otolaryngology–Head and Neck Surgery (Drs Schneider, Harrison, and Sidman), Ophthalmology (Drs Lee and Harrison), Neurology (Dr Lee), and Neurosurgery (Dr Lee), University of Minnesota Medical School, Minneapolis; and Children's Hospitals and Clinics of Minnesota, Minneapolis (Dr Sidman).

**Table. Characteristics Before and After Excision of Periorbital Hemangioma**

Patient No./ Sex/Age at Presentation, mo	Imaging	Preoperative Therapy	Lesion Location	Pathologic Size, cm	Preoperative Refraction	Postoperative Refraction
1/M/6	CT	Kenalog <sup>a</sup> injection (1)	L glabella/medial canthus	3.0 × 2.8 × 1.5	-5.00 +5.50 × 170	-2.50 +1.50 × 170
2/M/5	MRI	Kenalog <sup>a</sup> Injection (2), laser therapy (2)	R medial canthus/upper cheek	4.2 × 3.3 × 2.3	+3.00 +3.00 × 130	+3.50 +1.00 × 100
3/F/8	None	Pulsed-dye laser (2)	R medial canthus/upper lid	2.2 × 1.1 × 1.0	+2.25 +1.25 × 70	+1.00 +1.25 × 45
4/F/5	CT	None	R upper lateral lid	1.6 × 1.1 × 0.7	NA	NA
5/F/12	None	Kenalog <sup>a</sup> /betamethasone (2)	L upper lid	1.2 × 1.0 × 0.6	+0.50 +3.50 × 135	+2.50 Sphere
6/F/2.5	None	Pulsed-dye laser (9)	R upper lateral lid	1.0 × 0.5 <sup>b</sup>	-2.75 +2.00 × 105	-375 +200 × 115
7/F/11	None	None	L lateral canthus	2.2 × 0.3 × 0.9	NA	NA
8/M/7	MRI	None	L lateral lower lid	1.5 × 0.9 × 0.7	NA	NA
9/M/6	None	None	L lower lid	NA	NA	NA

Abbreviations: CT, computed tomography; L, left; MRI, magnetic resonance imaging; NA, not applicable; R, right.

<sup>a</sup>Proprietary name for triamcinolone acetonide manufactured by Bristol Myers Squibb, New York, New York.

<sup>b</sup>Third dimension is not available.

Preoperatively, 3 patients underwent corticosteroid injections with incomplete response. Prior to referral to our institution, 2 patients received laser therapy from a dermatologist, 1 with carbon dioxide laser and the other with potassium titanyl phosphate laser, to treat the superficial components. Both laser treatments were unsuccessful. One patient required intravenous antibiotic therapy for dacryocystitis due to outflow obstruction. All patients underwent a period of contralateral eye patching preoperatively to assure equal visual development.

Surgery was performed only after ophthalmologic recommendation owing to (1) continued rapid growth with associated pupillary occlusion that was not responding to medical therapy; (2) worsening refraction; and/or (3) large size of tumor (>2 cm). Surgery was performed under general anesthesia with local anesthesia (lidocaine, 1%, with 1:100 000 epinephrine) to assist with intraoperative hemostasis.

Surgical technique involved lid crease incisions, infra-brow and modified Lynch incisions with delicate dissection in a tangential direction to the lesion with the use of a "Colorado" needle monopolar cautery for dissection, and bipolar cautery for hemostasis. Care was taken to avoid violating the skin flap while also avoiding entry into the lobular portion of the hemangioma. Skin excision was performed when the lesion involved the skin. The aim of the surgery was complete excision to prevent recurrence. No substantial bleeding occurred at the time of surgery in any patient. No transfusions were needed, and all operations were done on an outpatient basis.

All of the hemangiomas were well circumscribed despite preoperative appearance. Surgery was indicated in each patient owing to lack of improvement using less invasive medical therapies as well as a lack of currently accepted standard of duration of observation in patients with periorbital hemangiomas where prevention of amblyopia and permanent visual loss is paramount.

## RESULTS

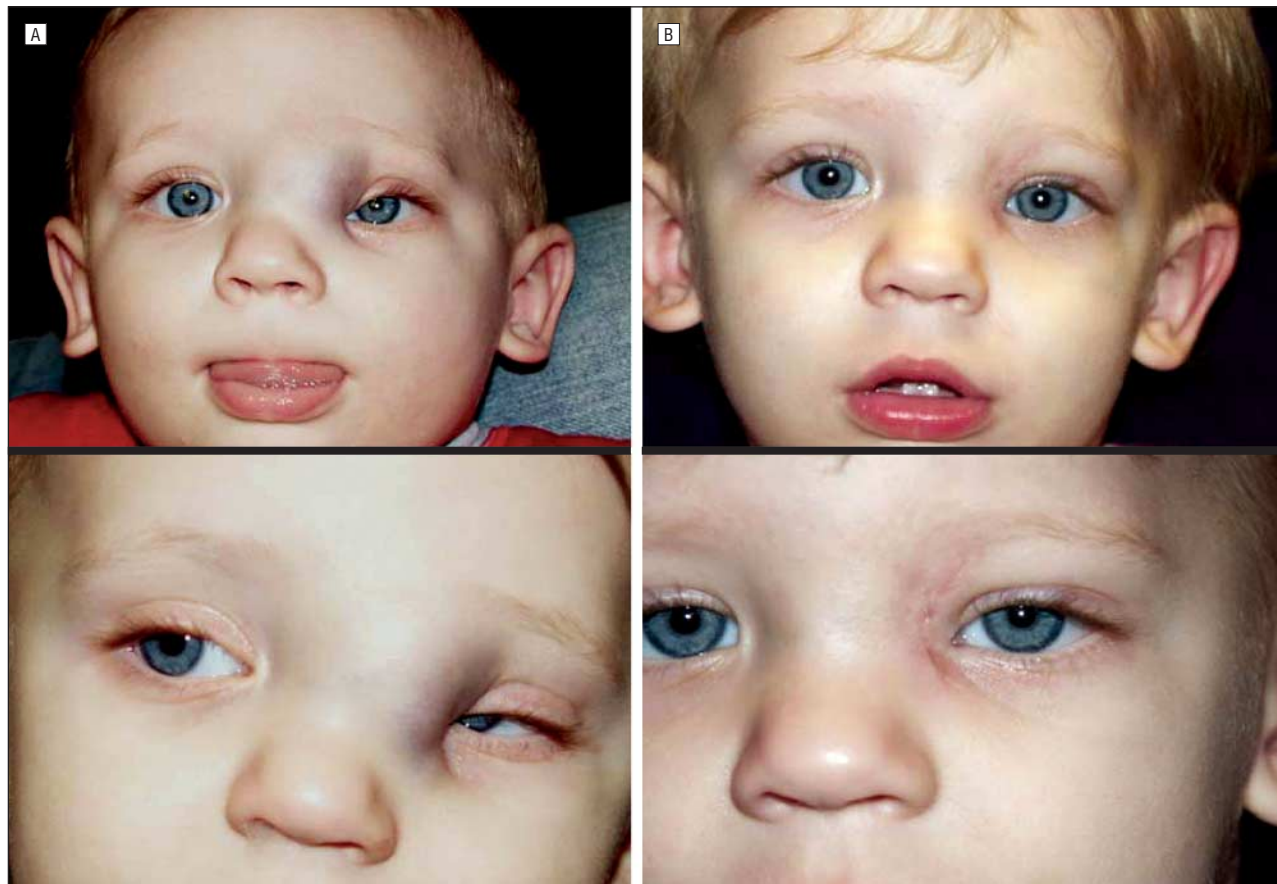
A total of 9 infants (4 boys and 5 girls) underwent surgical excision of complicated periorbital hemangiomas to treat refractive error and/or abnormal eye examination findings during the study period. All patients had abnormal eye examination findings prior to surgery. Four of the patients underwent computed tomography or magnetic resonance imaging prior to surgical excision to rule out an orbital component.

Refractive measurements were made in 5 of 9 patients preoperatively and postoperatively, including in the contralateral eye. Postoperatively, all 9 patients showed improvement in their original eye examination findings, as determined by a nonsurgical pediatric ophthalmologist, and all of those who had refractive errors measured preoperatively also showed improvements postoperatively. At the last follow-up, none of the patients showed evidence of amblyopia, lagophthalmos, eyelid ptosis, or signs of recurrence. All patients demonstrated substantial improvement in cosmetic and functional results with no apparent visual sequelae. Three patients developed superficial infections that were managed with oral antibiotics and topical wound care. Excellent surgical results were obtained with normal appearance by 2 to 3 weeks postoperatively, as shown in the **Figure**. Given the retrospective nature of this case series, data on average scar length and width were not obtained.

## COMMENT

Periorbital hemangiomas may threaten visual development for several reasons: they can cause refractive errors; strabismus may occur if the ocular muscles or their associated cranial nerves are involved; amblyopia develops when prolonged visual obstruction occurs; and optic atrophy and even loss of the eye have been reported. Frequent ophthalmologic examination is warranted to follow the progression of the astigmatism and monitor occlusive effects on the visual axis. Most hemangiomas in the periorbital region will not require treatment because they are small and do not affect vision. However, if close observation of patients with these lesions demonstrates worsening of refractive measurements or pupillary obstruction, surgical therapy should be considered.

A recent survey by Wasserman et al<sup>7</sup> revealed that obstruction of the visual axis, induced astigmatism, and poor cosmesis were the most common indications for any interventional therapy. Intralesional steroid therapy remains the most common treatment, but excision is gain-



**Figure.** Patient 1 had left glabella/medial canthus deep hemangioma. A, Preoperative images. B, Postoperatively, note resolution of the edema and no evidence of residual hemangioma at 3-week follow-up.

ing acceptance. Schwartz et al<sup>8</sup> sought to identify the risk factors of subsequent development of amblyopia due to anisometropia from capillary hemangiomas of the eyelids and orbit. They concluded that lesions larger than 1 cm are more likely to cause blepharoptosis and have enough mass effect to exert pressure on the anterior segment of the eye with resultant refractive changes. Their work also suggests that nasal location of the hemangioma, rather than temporal location, is more likely to cause amblyopia. Proptosis and globe displacement were also identified as substantial risk factors for visual changes. Bramhall and Quaba<sup>9</sup> reported that any degree of pupillary obstruction will result in visual complications and that refractive errors occur at a high rate prior to the development of amblyopia.

Corticosteroids remain the mainstay of treatment for periorbital HOI. Ranchod et al<sup>10</sup> systematically evaluated the literature and found few objective studies documenting the efficacy of topical, intralesional, and systemic steroids in terms of pretreatment and posttreatment refractive measures. Of those treated with corticosteroids, we have found success using intralesional injection consisting of a 50-50 mixture of betamethasone, 4%, and triamcinolone for initial therapy. Other equally potent steroid mixtures have been shown to be equally effective.<sup>11</sup> Intralesional steroid injection treatment has been shown to improve refraction; however, considerable variation in posttreatment refraction measurements was present

within this published series.<sup>11</sup> Risk of embolization of steroid particles has been reported and includes ophthalmic artery occlusion, retinal embolization, and central retinal artery occlusion.<sup>12</sup> Local adverse effects include eyelid hypopigmentation, subcutaneous fat atrophy, sclerodermiform linear atrophy, periocular calcification, and eyelid necrosis.<sup>13</sup>

Systemic corticosteroids administered at doses between 3 and 4 mg/kg of prednisone are typically used for 6 to 8 weeks if signs of involution are present after 7 to 10 days of therapy.<sup>14</sup> Systemic steroids will accelerate involution in 30% of lesions and cause stabilization in 40%, while the remaining 30% of lesions display no response.<sup>2</sup> Early signs of involution usually occur within several days to 1 week of treatment initiation and manifest as lightening of hemangioma color, tissue softening, and diminished growth. Steroid therapy in patients who are unresponsive after several days to 1 week should be tapered off. Systemic corticosteroids have been shown to accelerate the involution of both superficial and deep portions of the hemangioma, but substantial adverse effects have been reported, including development of cushingoid features, growth deceleration, irritability, personality changes, gastrointestinal upset, weight gain, adrenal suppression, increased susceptibility to infection, and hypertension.<sup>15</sup> Newer treatments with propranolol<sup>16</sup> and low-dose cyclophosphamide with interferon have been described in small series.<sup>5,17</sup>

Surgical excision of hemangiomas that are well circumscribed and noninfiltrating is a straightforward procedure: the tumor behaves similar to a tissue expander with a small number of feeding vessels that can be carefully cauterized with meticulous surgical technique. Blood transfusions have been avoided with this technique. Soft-tissue closure is uncomplicated, and postoperative eyelid malposition is unlikely owing to skin excess at the time of closure as a result of the underlying soft-tissue expanding nature of the hemangioma. This type of hemangioma does not require preoperative embolization, and sclerotherapy has not been used owing to the additional risks of skin necrosis and the potential for systemic dissemination of the sclerosant.<sup>18</sup>

Controversy remains regarding the optimal timing of surgical treatment. Levi et al<sup>19</sup> discussed surgical excision of periorbital hemangiomas resistant to steroid treatment and found success when this technique was used on patients younger than 21 months to relieve pupillary occlusion and decrease astigmatism. Our criteria for surgical intervention relied on ophthalmologic determination of worsening eye examination findings and/or refractive changes with or without failure of corticosteroid therapy. This is in contradistinction to the approach outlined by Pasyk et al,<sup>20</sup> who recommend surgery for advanced periorbital hemangiomas that are rapidly growing and unresponsive to steroid therapy or when vision is impaired or completely occluded. We have developed our approach based on our experience of complete resection without visual or aesthetic complications.

## CONCLUSIONS

Patients with periorbital hemangiomas may present prior to consultation with the ophthalmology service but long after refractive changes have occurred. The traditional "wait and see" management of these lesions may lead to unnecessary visual sequelae when appropriate referral and treatment is not delivered in a timely manner. If medical therapy fails or the patient presents with refractive changes or pupillary occlusion, surgery alone can be used to successfully treat and correct early-onset astigmatism and vision changes and reduce the number of office visits and the potential need for other therapies. Surgical complications are less likely when lesions are smaller, circumscribed, noninfiltrating, and lack an orbital component. Periorbital hemangiomas unresponsive to less invasive therapies should be strongly considered for early surgical excision, especially when refractive changes and/or pupillary occlusion are present.

Surgical excision of periorbital hemangiomas can reduce astigmatism, improve visual field defects, and prevent subsequent amblyopia when instituted in a timely manner. Surgery should be considered early in the management of these patients because it can be done safely and with minimal morbidity.

Accepted for Publication: April 29, 2010.

Correspondence: James Sidman, MD, Pediatric ENT Associates, Children's Specialty Center, 2530 Chicago Ave S, Ste 450, Minneapolis, MN 55404 (sidma001@umn.edu).

Author Contributions: Study concept and design: Schneider, Harrison, and Sidman. Acquisition of data: Schneider, Harrison, and Sidman. Analysis and interpretation of data: Schneider, Lee, and Sidman. Drafting of the manuscript: Schneider and Sidman. Critical revision of the manuscript for important intellectual content: Schneider, Lee, Harrison, and Sidman. Administrative, technical, and material support: Schneider, Harrison, and Sidman. Study supervision: Harrison and Sidman.

Financial Disclosure: None reported.

## REFERENCES

- Boye E, Jinnin M, Olsen BR. Infantile hemangioma: challenges, new insights, and therapeutic promise. *J Craniofac Surg*. 2009;20(suppl 1):678-684.
- Enjolras O, Riche MC, Merland JJ, Escande JP. Management of alarming hemangiomas in infancy: a review of 25 cases. *Pediatrics*. 1990;85(4):491-498.
- Plager DA, Snyder SK. Resolution of astigmatism after surgical resection of capillary hemangiomas in infants. *Ophthalmology*. 1997;104(7):1102-1106.
- Slaughter K, Sullivan T, Boulton J, O'Reagan P, Gole G. Early surgical intervention as definitive treatment for ocular adnexal capillary haemangioma. *Clin Experiment Ophthalmol*. 2003;31(5):418-423.
- Fabian ID, Ben-Zion I, Samuel C, Spierer A. Reduction in astigmatism using propranolol as first-line therapy for periocular capillary hemangioma. *Am J Ophthalmol*. 2011;151(1):53-58.
- Walker RS, Custer PL, Nerad JA. Surgical excision of periorbital capillary hemangiomas. *Ophthalmology*. 1994;101(8):1333-1340.
- Wasserman BN, Medow NB, Homa-Palladino M, Hoehn ME. Treatment of periocular capillary hemangiomas. *J AAPOS*. 2004;8(2):175-181.
- Schwartz SR, Blei F, Ceisler E, Steele M, Furlan L, Kodsi S. Risk factors for amblyopia in children with capillary hemangiomas of the eyelids and orbit. *J AAPOS*. 2006;10(3):262-268.
- Bramhall RJ, Quaba A. A review of 58 patients with periorbital haemangiomas to determine appropriate cases for intervention. *J Plast Reconstr Aesthet Surg*. 2008; 61(2):138-149.
- Ranchod TM, Frieden IJ, Fredrick DR. Corticosteroid treatment of periorbital haemangioma of infancy: a review of the evidence. *Br J Ophthalmol*. 2005;89(9): 1134-1138.
- Weiss AH, Kelly JP. Reappraisal of astigmatism induced by periocular capillary hemangioma and treatment with intralesional corticosteroid injection. *Ophthalmology*. 2008;115(2):390-397, e1.
- Egbert JE, Schwartz GS, Walsh AW. Diagnosis and treatment of an ophthalmic artery occlusion during an intralesional injection of corticosteroid into an eyelid capillary hemangioma. *Am J Ophthalmol*. 1996;121(6):638-642.
- Sutula FC, Glover AT. Eyelid necrosis following intralesional corticosteroid injection for capillary hemangioma. *Ophthalmic Surg*. 1987;18(2):103-105.
- Edgerton MT. The treatment of hemangiomas: with special reference to the role of steroid therapy. *Ann Surg*. 1976;183(5):517-532.
- Bennett ML, Fleischer AB Jr, Chamlin SL, Frieden IJ. Oral corticosteroid use is effective for cutaneous hemangiomas: an evidence-based evaluation. *Arch Dermatol*. 2001;137(9):1208-1213.
- Léauté-Labrèze C, Dumas de la Roque E, Hübiche T, Boralevi F, Thambo JB, Taïeb A. Propranolol for severe hemangiomas of infancy. *N Engl J Med*. 2008;358(24):2649-2651.
- Wilson MW, Hoehn ME, Haik BG, Rieman M, Reiss U. Low-dose cyclophosphamide and interferon alfa 2a for the treatment of capillary hemangioma of the orbit. *Ophthalmology*. 2007;114(5):1007-1011.
- Kane WJ, Morris S, Jackson IT, Woods JE. Significant hemangiomas and vascular malformations of the head and neck: clinical management and treatment outcomes. *Ann Plast Surg*. 1995;35(2):133-143.
- Levi M, Schwartz S, Blei F, et al. Surgical treatment of capillary hemangiomas causing amblyopia. *J AAPOS*. 2007;11(3):230-234.
- Pasyk KA, Dingman RO, Argenta LC, Sandall GS. The management of hemangiomas of the eyelid and orbit. *Head Neck Surg*. 1984;6(4):851-857.