

# Anatomic Variations of the Musculocutaneous Nerve and Clinical Implications for Restoration of Elbow Flexion

Praveen Bhardwaj, MS,\* Hari Venkatramani, MS, MCh,\* Brahman Sivakumar, MBBS, MSc,†‡§¶||  
David J. Graham, MBBS, BPhy(Hons),‡§¶†‡‡ Varadharajan Vigneswaran, MS,\*  
S. Raja Sabapathy, MS, MCh\*

**Purpose** The restoration of elbow flexion is of primary importance in the management of patients with brachial plexus injuries. Superior functional outcomes via fascicle transfer from the ulnar and median nerves have resulted in this transfer being considered the mainstay of recovery of elbow flexion in patients with intact C8 and T1 function. An understanding of the anatomy of the musculocutaneous nerve (MCN) and its branching pattern is key while performing these transfers.

**Methods** A prospective cohort study was conducted in patients who underwent nerve transfer for the restoration of elbow flexion following a traumatic brachial plexus injury. The anatomic course and branching pattern of the MCN were recorded in eligible cases, both as a line diagram and using intraoperative photographs.

**Results** One hundred fifty patients underwent nerve transfer for the restoration of elbow flexion following an injury to the brachial plexus. The MCN in 138 patients (92%) was found to pierce the coracobrachialis muscle before emerging lateral to it. One hundred thirty-four patients (89.3%) demonstrated the “classical” anatomy. One hundred fifteen patients (76.6%) had a single primary branch to the biceps, whereas 25 patients (16.6%) demonstrated a discrete motor branch to each head. One hundred thirty-three dissections (88.6%) revealed a single muscular branch to the brachialis arising posteromedially from the MCN, distal to the origin of the branch to the biceps brachii. Notable unreported variations, such as the MCN penetrating the biceps as it descended, multiple brachialis branches, and trifurcation of divisions of the MCN, were documented.

**Conclusions** Variations in MCN anatomy are quite common, and even unreported variations can be encountered.

**Clinical relevance** Exploration of the MCN and its branches for nerve transfers requires knowledge of these anatomic variations and vigilance to prevent inadvertent injuries while

From the \*Department of Plastic, Hand and Microsurgery, Ganga Medical Centre & Hospital Pvt. Ltd., Coimbatore, India; the †Department of Hand and Peripheral Nerve Surgery, Royal North Shore Hospital, New South Wales, Australia; the ‡Australian Research Collaboration on Hands, Mudgeeraba, Queensland, Australia; the §Department of Orthopaedic Surgery, Hornsby Ku-ring-gai Hospital, Hornsby, New South Wales, Australia; the ||Department of Orthopaedic Surgery, Nepean Hospital, Kingswood, New South Wales, Australia; the ¶Department of Surgery, University of Sydney, Camperdown, New South Wales, Australia; the #Discipline of Surgery, Sydney Medical School, the Faculty of Medicine and Health, University of Sydney, Sydney, Australia; the \*\*Department of Musculoskeletal Services, Gold Coast University Hospital, Southport, Queensland, Australia; the ††School of Medicine and Dentistry, Griffith

University, Southport, Queensland, Australia; and the ‡‡Department of Orthopaedic Surgery, Queensland Children's Hospital, South Brisbane, Queensland, Australia.

Received for publication October 31, 2021; accepted in revised form July 13, 2022.

No benefits in any form have been received or will be received related directly or indirectly to the subject of this article.

**Corresponding author:** S. Raja Sabapathy, MS, MCh, Ganga Hospital, 313 Mettupalayam Road, Coimbatore, Tamil Nadu, 641043, India; e-mail: [rajahand@gmail.com](mailto:rajahand@gmail.com).

0363-5023/22/4710-0001\$36.00/0

<https://doi.org/10.1016/j.jhsa.2022.07.014>

dissecting them for nerve transfer surgery. (*J Hand Surg Am.* 2022;47(10):970–978. Copyright © 2022 by the American Society for Surgery of the Hand. All rights reserved.)

**Key words** Anatomic variation, brachial plexus, median nerve, musculocutaneous nerve, nerve transfer.

**T**HE RESTORATION OF ELBOW flexion is of utmost importance in the treatment of patients with brachial plexus injuries.<sup>1–3</sup> Therapeutic options include nerve grafting, nerve transfers, and pedicled or free functional muscle transfers. Nerve transfers involve harvesting of donor motor fascicles, which are then neurotized to musculocutaneous nerve (MCN) branches to the biceps, and, potentially, the brachialis muscle. Although encouraging results have been reported with the use of the spinal accessory or intercostal donor nerves, superior functional outcomes via single or double fascicular transfer from the ulnar and median nerves (MN) have made this the mainstay of treatment in patients with intact C8 and T1 function.<sup>3–6</sup> An intimate understanding of the anatomy of the MCN and its branching pattern is critical while performing these transfers.

A number of variations in the anatomy of the MCN have been described and classified. Le Minor<sup>7</sup> reported variations in the origin of the MCN and MN and proposed a classification system to describe their relationship (Fig. 1). Type I is defined by a lack of communication between the MCN and MN and has been reported to be the most common formation of the MN.<sup>8</sup> Type II has some fibers of the lateral cord contribution to the MN passing through the MCN and joining the MN at a second point distally in the midarm. In type III anatomy, fibers of the lateral cord contribution to the MN pass along the MCN for a distance before exiting to form the lateral cord contribution to the MN proper. The coalescence of the medial and lateral cord contributions to form the MN is more distal in type III than in the other variations. Type IV is defined by fibers of the MCN coalescing with the lateral cord contribution to the MN before the MCN arises from the MN proper more distally. In type V anatomy, there is no MCN proper and branches of the MCN appear to arise from the coalesced MCN and MN.

Yang et al<sup>9</sup> explored the anatomy of the branch of the MCN to the biceps brachii in 24 cadavers and described 3 variations: those with a common primary branch that bifurcates to supply the 2 heads (type I, 83.4%); those with 2 separate primary branches (type II, 8.3%); and those with a primary branch that

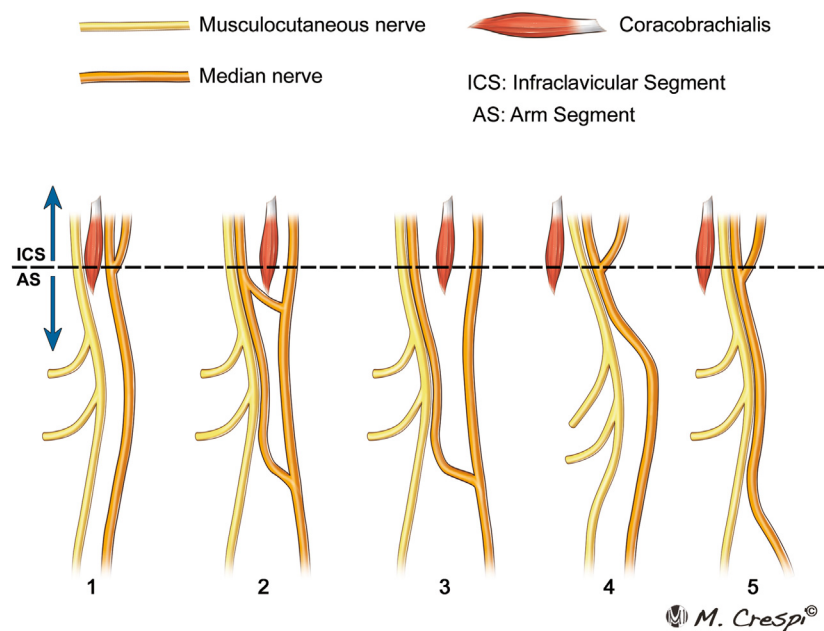
bifurcates to the individual heads and an additional distal branch that innervates the common belly of the biceps muscle (type III, 8.3%). In a study in which 112 cadavers were dissected, Chiarapattanakom et al<sup>10</sup> altered the type III subgroup to 3 discrete primary branches from the MCN, with the most distal branch supplying either a vestigial third head or the common belly of the biceps. Both Yang et al<sup>9</sup> and Chiarapattanakom et al<sup>10</sup> noted that the innervation pattern to the brachialis could be either single (95.8%) or double (4.2%) primary branches.

Despite this, the literature surrounding the frequency and distribution of these variations remains scarce and variable. The data predominantly arise from cadaveric studies, with a paucity of clinical studies reporting the anatomy and variations. In general, *in vivo* anatomic studies are preferable because they allow for confirmation of physiology via electric stimulation to confirm innervation patterns, in addition to anatomy, and are not limited by the altered tissue quality and planes associated with cadavers.

Thus, the aim of this study was to describe the authors' intraoperative findings from a series of patients who underwent nerve transfer for the restoration of elbow flexion in the setting of brachial plexus injury, and discuss the clinical implications of variant anatomy.

## MATERIALS AND METHODS

This study was approved by the institutional ethics review committee. All patients who presented to our quaternary-level hand and peripheral nerve surgery referral institute in Coimbatore, India, in the period between October 2016 and December 2019, for nerve transfer for the restoration of elbow flexion following a traumatic brachial plexus injury were eligible for inclusion. Patients who underwent alternative therapeutic procedures or those in whom nerve transfer could be performed without the dissection and visualization required to adequately explore the anatomy of the MCN were excluded. The anatomic course and branching pattern of the MCN were recorded in eligible cases, both as a line diagram and using intraoperative photographs. In particular, 3 findings



**FIGURE 1:** Le Minor classification of the relationship between the MN and MCN. AS, arm segment; ICS, infraclavicular segment.

were recorded: the relationship of the MCN with the MN and coracobrachialis muscle, the anatomy of the branch of the MCN to the biceps brachii, and the course of the branch of the MCN to the brachialis.

## RESULTS

Over the period of interest, 150 patients underwent nerve transfer for the restoration of elbow flexion following injury to the brachial plexus. The mean age of the patients was 29.4 years (range, 16–64 years). All but 4 patients were male. The mechanism of injury in 145 patients was a road traffic accident, with 2 wheelers (motorbike or pushbike) involved in 141 of these cases.

### Relationship of the MCN with the coracobrachialis muscle and MN

The MCN in 138 of the 150 patients (92.0%) was found to pierce the coracobrachialis muscle before emerging lateral to it. In the remainder, the nerve descended medial to the coracobrachialis muscle, along with the MN.

One hundred thirty-four patients (89.3%) demonstrated no connecting fibers between the 2 nerves (Le Minor type I, Fig. 2). The remaining 16 intraoperative dissections (10.7%) revealed some degree of interconnection between the MN and MCN. Ten patients (6.7%) demonstrated Le Minor type IV anatomy, with fibers of the MCN passing through the lateral cord contribution to the MN and exiting from the MN proper (Fig. 3). All MCNs exhibiting this relationship

traveled medial to the coracobrachialis before traversing laterally between the brachialis and biceps brachii muscles upon exiting the MN.

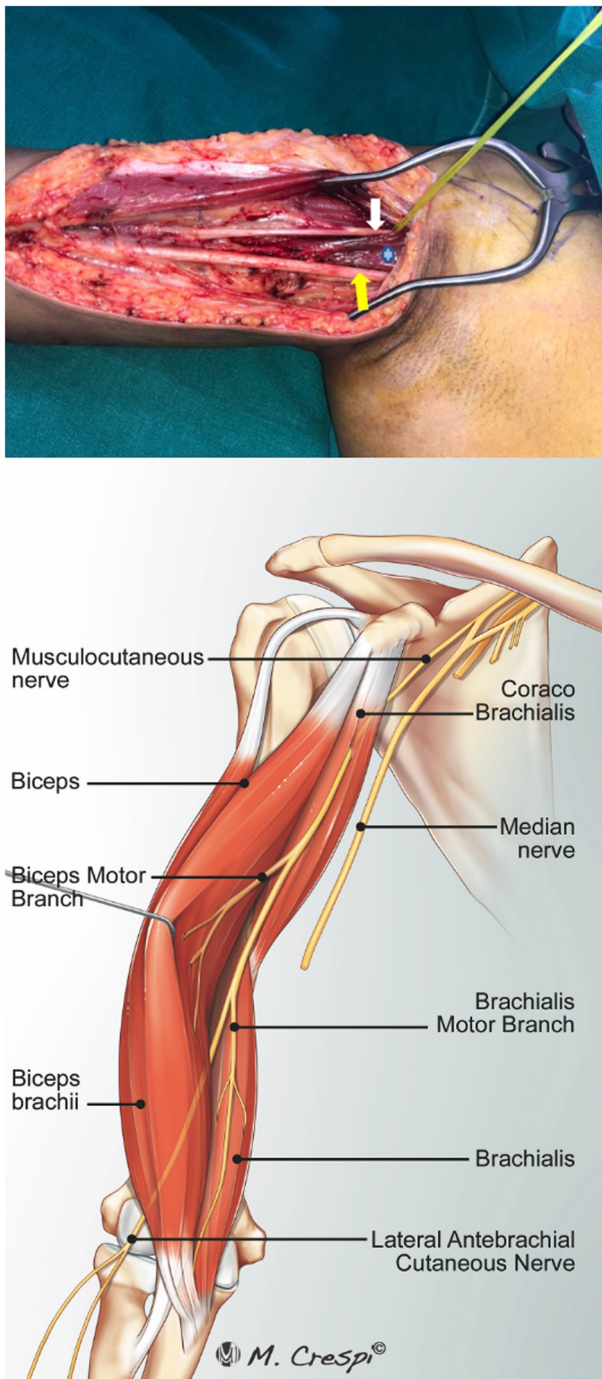
Le Minor type II and type III variations were noted in 2 patients each. Although 2 patients were found to have a single nerve, consistent macroscopically with Le Minor type V, with branches exiting laterally to supply the brachialis and biceps brachii muscles, careful dissection under magnification revealed the nerves to be separable from a single encompassing sheath, rendering it similar to Le Minor type IV (Figs. 4, 5).

### Anatomy of the MCN branch to the biceps brachii muscle

The anatomy of 143 patients (95.3%) could be categorized using the classification system proposed by Chiarapattanakom et al<sup>10</sup> (Fig. 6). One hundred fifteen patients (76.6%) had a single primary branch to the biceps brachii. This branch then divided into 2 to supply the long and short heads of the muscle. Twenty-five patients (16.6%) had a discrete motor branch from the MCN to each head of the biceps brachii, with the 2 branches arising within a few centimeters of each other. In this subgroup, 5 patients demonstrated division of the proximal branch into 2 further branches; this configuration was reversed in 2 patients, with a single proximal branch and a divided distal branch (type II A and B). Three patients demonstrated type III branching pattern, with 3 branches to the biceps.

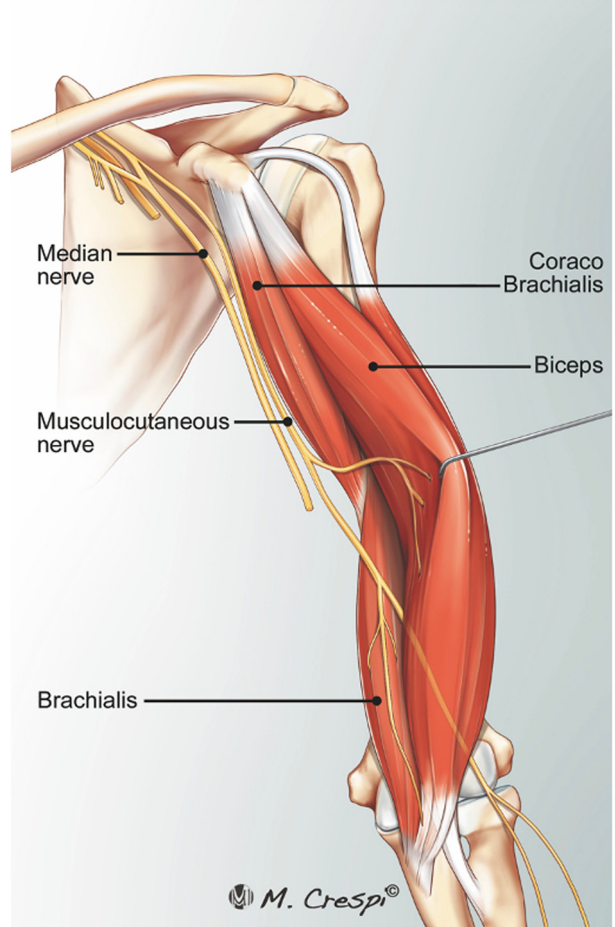
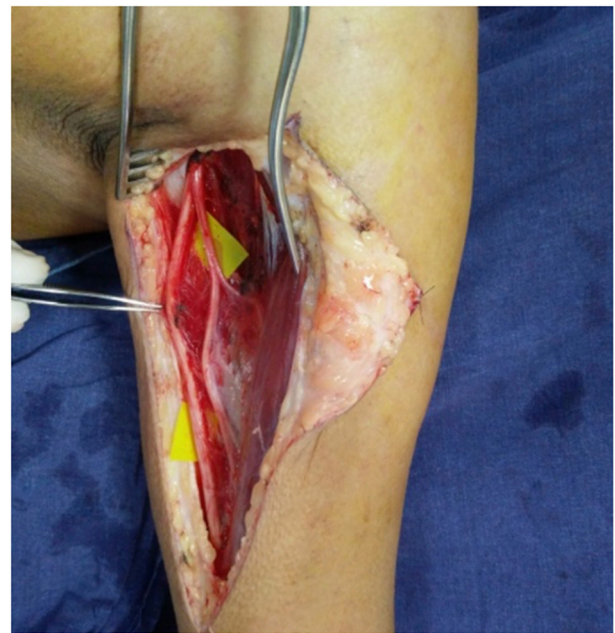Five dissections revealed a single primary branch trifurcating into 3 secondary branches (type IV,





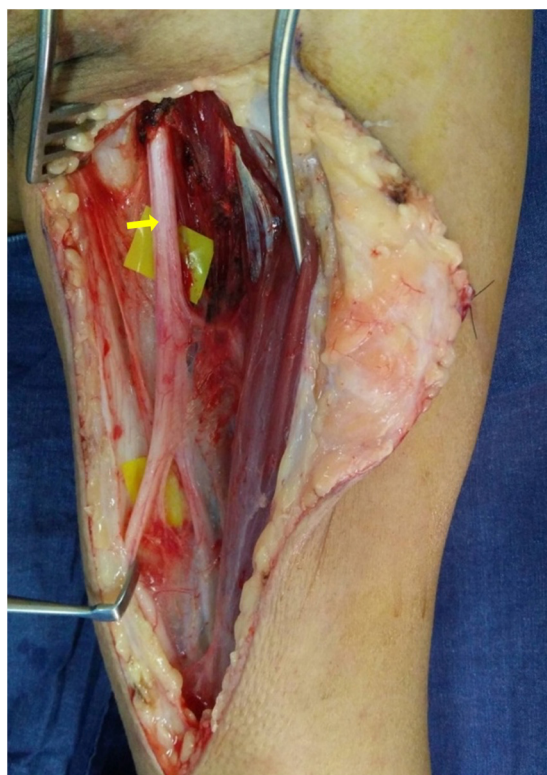**FIGURE 2:** Anatomic relationship of the MCN (white arrow) with the MN (yellow arrow) and coracobrachialis (cross) in Le Minor type I (classical anatomy).

**Fig. 6).** In another 2 patients, the MCN was found to pierce and pass through the undersurface of the biceps brachii, supplying it with multiple intramuscular branches. The MCN then exited the biceps brachii at the level of the midarm to join a branch of the MN, with the conjoint nerve supplying an additional branch to the biceps and a branch to the brachialis before continuing distally as the lateral cutaneous



**FIGURE 3:** Le Minor type IV anatomy of the MCN observed in 10 out of 150 cases.

nerve of the forearm (**Figs. 6, 7**). A similar innervation pattern was described by Chiarapattanakom et al<sup>10</sup> in their cadaveric study.



**FIGURE 4:** Le Minor type V anatomy, with the MCN medial to the coracobrachialis muscle and traveling in a common sheath (arrow) with the MN.

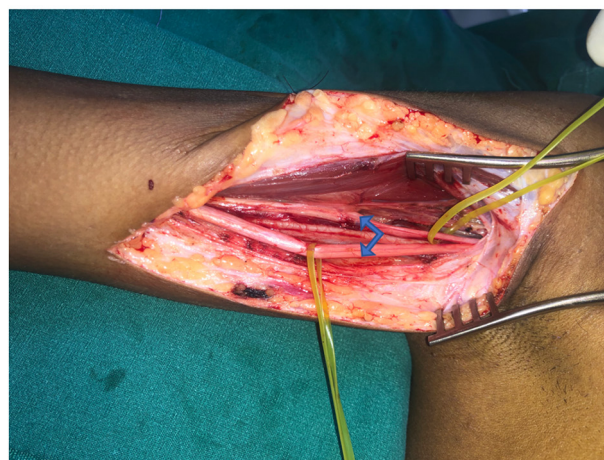
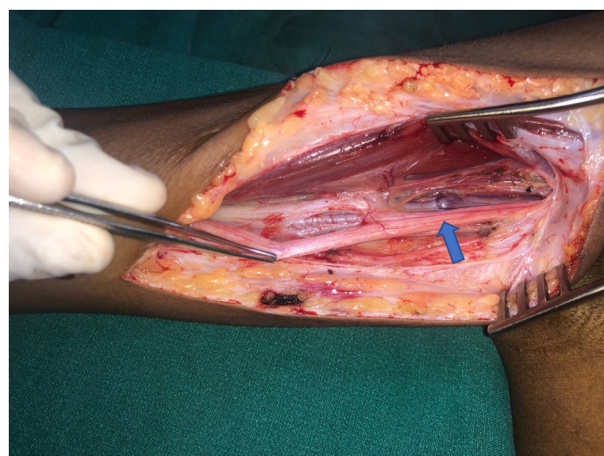
#### Anatomy of the MCN branch to the brachialis muscle

One hundred thirty-three patients (88.6%) had a single muscular branch to the brachialis arising posteromedially from the MCN, distal to the origin of the branch to the biceps brachii (Fig. 8). Twelve patients (8.0%) had 2 discrete branches innervating the muscle (Fig. 8).

The remaining 5 patients revealed variations that did not correspond to previously described types (3.3%).<sup>9</sup> In 3 patients, the MCN presented 3 sequential individual branches to the brachialis (Figs. 8, 9). In the remaining 2 patients, the MCN came to a terminal trifurcation to yield branches to the brachialis and biceps brachii as well as the lateral cutaneous nerve of the forearm (Figs. 9, 10).

#### DISCUSSION

Intimate knowledge of the anatomy of the MCN is critical while performing nerve transfer surgery for the restoration of elbow flexion in patients with brachial plexus injuries involving the upper trunks. This study found that variations in the classically described anatomy are common. An understanding of



**FIGURE 5:** Le Minor type V anatomy, with the MCN medial to the coracobrachialis muscle and traveling in a common sheath with the MN (arrow). However, the nerves were separable (2 arrows) under magnification, rendering them similar to the Le Minor type IV anatomy.

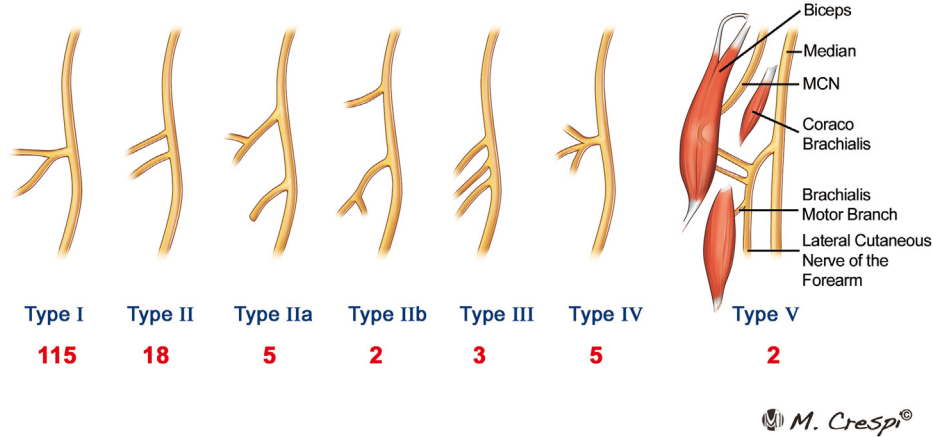
these variations is necessary to prevent inadvertent iatrogenic damage during dissection.

In 8% (12 cases) of patients in this study, the MCN descended medial to the coracobrachialis muscle. This must be kept in mind if the MCN cannot be located in its standard position between the biceps brachii and the coracobrachialis. Extensive dissection in this setting may damage the motor branches that traverse the region distal to the coracobrachialis to reach the biceps brachii and brachialis, complicating or precluding nerve transfer surgery.

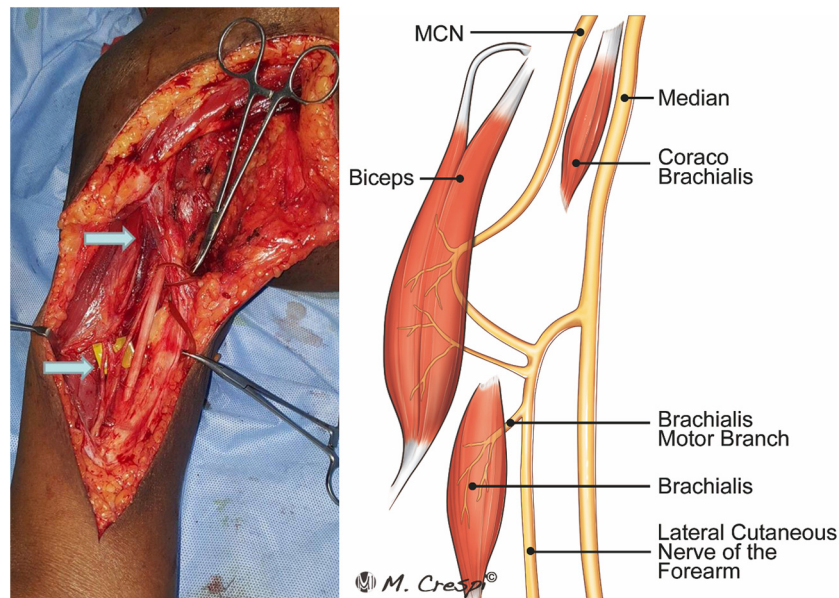
Variations in the relationship between the MCN and MN must also be considered and addressed appropriately. Eighty-nine percent of the patients in this cohort exhibited the classical anatomy, with no communication between the 2 nerves. In this pattern, the MCN can be located between the biceps brachii and coracobrachialis and its branches identified via



## Branching Pattern of Biceps Motor Branch



**FIGURE 6:** Anatomy of the musculocutaneous branch to the biceps brachii and their incidence noted in our study.



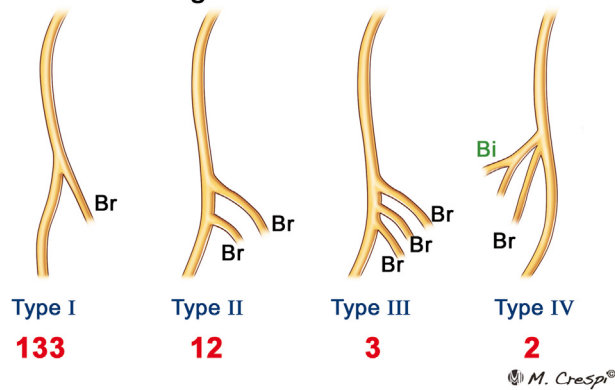
**FIGURE 7:** A rare variation in which the MCN was found to pierce and pass through the undersurface of the biceps brachii, supplying it with multiple intramuscular branches. The MCN then exited the biceps brachii at the level of the midarm to join a branch of the MN, with the conjoined nerve supplying another branch to the biceps and one to the brachialis before continuing distally as the lateral cutaneous nerve of the forearm.

distal exploration. These fascicles can then be separated via proximal intraneural dissection to obtain adequate length for nerve transfer.

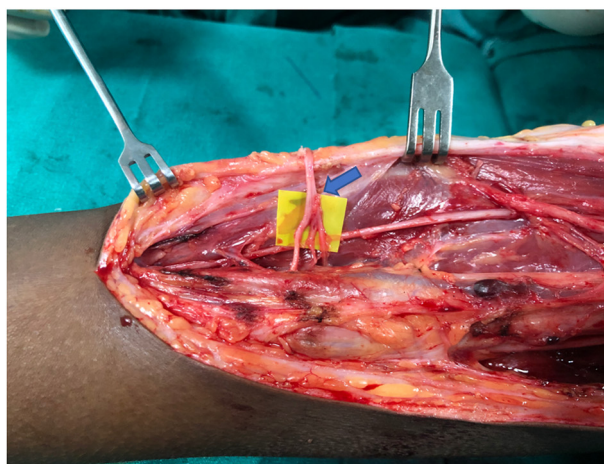
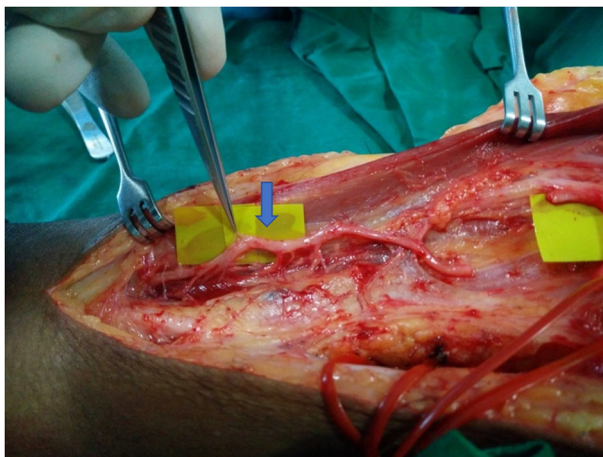
We observed an 11% prevalence of variant anatomy. This is consistent with previous cadaveric studies in which variations were reported to range from 13% to 37%.<sup>11–13</sup> A recent systematic review of variations in cadaveric MCN reported a pooled prevalence of 20%.<sup>13</sup> In cases in which the MCN communicates with either the MN or its roots (Le minor types II to V), identification of the terminal branches to the biceps

brachii and brachialis and subsequent retrograde intrafascicular neurolysis allow separation of the appropriate neural elements for coaptation. Again, care must be taken during preliminary dissection and identification because the aberrant MCN is often medial to the coracobrachialis muscle. We do not consider Le Minor type V to be without the MCN; rather, the MCN and MN are contained within a common epineural sheath, much like the sciatic nerve, where the 2 components are separate but travel within the same sheath for a variable distance.<sup>14,15</sup>

### Branching Pattern of Brachialis



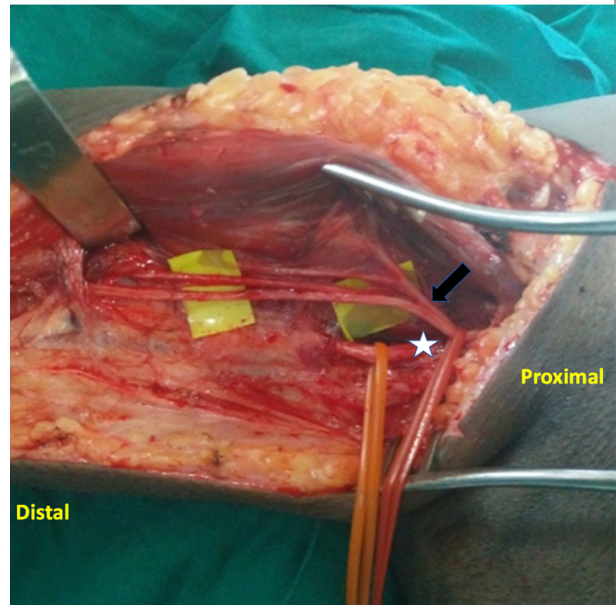
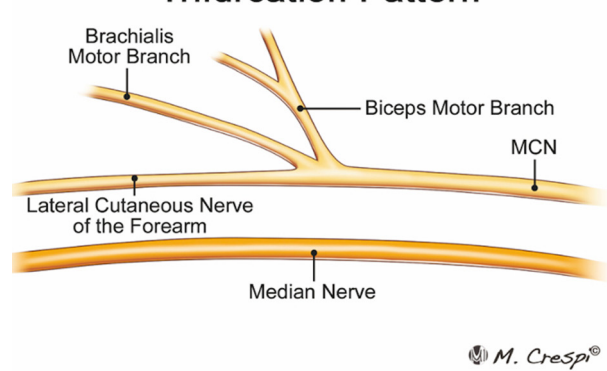
**FIGURE 8:** Anatomy of the musculocutaneous branch to the brachialis and its incidence noted in our series. Bi, biceps motor branch (red); Br, brachialis motor branch (blue).



**FIGURE 9:** Variant anatomy of the MCN, with 3 or more individual muscular branches to the brachialis (arrow).

Both Chiarapattanakom et al<sup>10</sup> and Yang et al<sup>9</sup> investigated the branching pattern of the MCN to the biceps brachii and brachialis and reported that the first branch to the biceps usually exits the main trunk

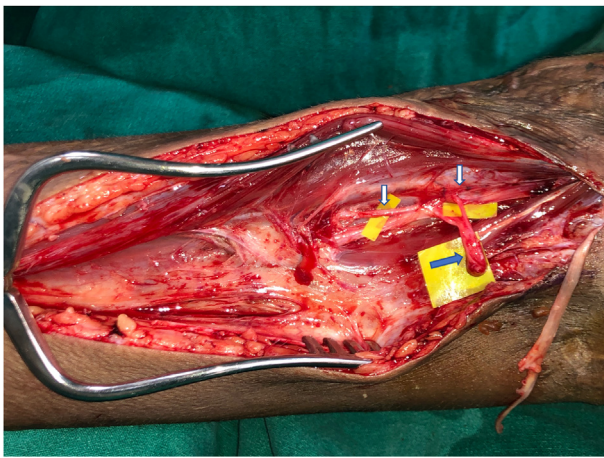
### Trifurcation Pattern



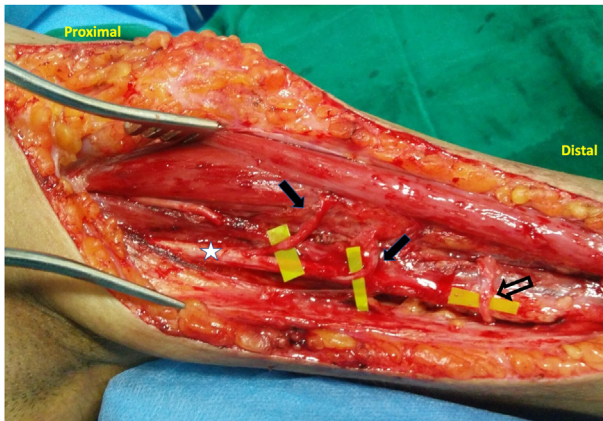
**FIGURE 10:** Variant anatomy of the MCN, with trifurcation of terminal branches. The arrow marks the trifurcation of the terminal part of the MCN; the star marks the MN.

at an average distance of 130 mm from the acromion, with the mean length of this branch being approximately 9 mm prior to bifurcation. Chiarapattanakom et al<sup>10</sup> found that additional branches, when present, arose an average of 22.3 mm (range, 5–53 mm) distal to the initial branch. The nerve to the brachialis was found to exit the MCN approximately 170 mm distal to the acromion, with an average length of 34 mm and diameter of 0.8 mm.<sup>9,10</sup> Our intraoperative findings were consistent with these descriptions. We identified anatomic variations based on previous descriptions of the branching pattern to the biceps brachii in 7 patients and of that to the brachialis in 5 patients (Figs. 6–10). Even in the presence of multiple branches to either muscle, careful retrograde dissection allowed access to a single encompassing fascicular stump to act as a recipient nerve in almost all the cases (Fig. 11). This stump was separated proximally from its point of exit for a distance of 3 to





**FIGURE 11:** A patient with 2 branches to the biceps (type II pattern) (white arrows), wherein we could dissect the 2 branches to a single stump (blue arrow) via intraneural dissection under a microscope.



**FIGURE 12:** The only case in which 2 MCN branches to the biceps could not be dissected to a single branch and required neurotization using a fascicle from the MN at 2 levels (also detailed in the text). The closed arrow marks the 2 motor branches to the biceps at 2 levels and their individual coaptation with a fascicle from the MN at 2 levels; the open arrow marks the coaptation of the ulnar nerve fascicle to the brachialis; the star marks the MN.

5 cm, allowing adequate length for neurorrhaphy. This technique was not possible in a single case, and we used 2 donor fascicles from the MN to allow direct coaptation to the 2 terminal branches of the biceps (Fig. 12). In this case, both recipient nerves were of a shorter length, and coaptation to the adjacent MN was preferred over the standard transfer of the ulnar nerve fascicle to the biceps motor branch.

This study has some limitations. Formal measurement of the origin of the nerve branches was not

performed because of previous comprehensive descriptions in cadaveric studies. The data were collected from an Indian cohort and need to be correlated with other populations to establish generalizability. However, the study did identify that 8% of patients undergoing nerve transfer surgery for the restoration of elbow flexion following brachial plexus injury may have variations in the anatomic course of the MCN as well as the branching pattern to the biceps brachii and brachialis. It described hitherto unclassified variations in branching patterns and highlighted the clinical implications of these variations, adding to the literature in this field.

Single or double fascicular transfers to MCN branches to the biceps brachii and brachialis are reliable methods of restoring elbow flexion in the setting of brachial plexus injury. This study is the largest *in vivo* series to describe the anatomy of the MCN and highlights variations in the anatomic course and branching patterns. While exploring the MCN, it is suggested that the surgeon should initially explore the interval between the biceps and coracobrachialis. If the MCN is not readily visualized in this interval, we recommend exploration of the MN to exclude the possibility of an anomalous MCN traveling with the MN. In this setting, extensive dissection distal to the usual anatomic course of the MCN may result in iatrogenic injury to branches traversing laterally from the medially located anomalous nerve. Although variations in branching patterns to the biceps brachii and brachialis exist, in most cases, careful retrograde microsurgical dissection can yield a single large branch for neurotization. Thorough knowledge of anatomy and possible variations will result in safer surgical explorations and improved outcomes.

## REFERENCES

1. Oberlin C, Beal D, Leechavengvongs S, Salon A, Dauge MC, Sarcy JJ. Nerve transfer to the biceps muscle using a part of ulnar nerve for C5–C6 avulsion of the brachial plexus: anatomical study and report of four cases. *J Hand Surg Am.* 1994;19(2):232–237.
2. Liverneaux PA, Diaz LC, Beaulieu JY, Durand S, Oberlin C. Preliminary results of double nerve transfer to restore elbow flexion in upper type brachial plexus palsies. *Plast Reconstr Surg.* 2006;117(3):915–919.
3. Mackinnon SE, Novak CB, Mykатыn TM, Tung TH. Results of reinnervation of the biceps and brachialis muscles with a double fascicular transfer for elbow flexion. *J Hand Surg Am.* 2005;30(5):978–985.
4. Merrell GA, Barrie KA, Katz DL, Wolfe SW. Results of nerve transfer techniques for restoration of shoulder and elbow function in the context of a meta-analysis of the English literature. *J Hand Surg Am.* 2001;26(2):303–314.
5. Chuang DC. Nerve transfers in adult brachial plexus injuries: my methods. *Hand Clin.* 2005;21(1):71–82.



6. Sungpet A, Suphachatwong C, Kawinwonggowit V, Patradul A. Transfer of a single fascicle from the ulnar nerve to the biceps muscle after avulsions of upper roots of the brachial plexus. *J Hand Surg Br.* 2000;25(4):325–328.
7. Le Minor JM. A rare variation of the median and musculocutaneous nerves in man. *Arch Anat Histol Embryol.* 1990;73:33–42.
8. Sharma V, Babu CR, Gupta V. Variation of roots in the formation of median nerve. *Int J Anat Res.* 2018;6(4.2):5853–5860.
9. Yang ZX, Pho RW, Kour AK, Pereira BP. The musculocutaneous nerve and its branches to the biceps and brachialis muscles. *J Hand Surg Am.* 1995;20(4):671–675.
10. Chiarapattanakom P, Leechavengvongs S, Witoonchart K, Uerpaiojkit C, Thuvasethakul P. Anatomy and internal topography of the musculocutaneous nerve: the nerves to the biceps and brachialis muscle. *J Hand Surg Am.* 1998;23(2):250–255.
11. Budhiraja V, Rastogi R, Asthana AK, Sinha P, Krishna A, Trivedi V. Concurrent variations of median and musculocutaneous nerves and their clinical correlation—a cadaveric study. *Ital J Anat Embryol.* 2011;116(2):67–72.
12. Ballesteros LE, Forero PL, Buitrago ER. Communication between the musculocutaneous and median nerves in the arm: an anatomical study and clinical implications. *Rev Bras Ortop.* 2015;50(5):567–572.
13. Sirico F, Castaldo C, Baiocco V, et al. Prevalence of musculocutaneous nerve variations: systematic review and meta-analysis. *Clin Anat.* 2019;32(2):183–195.
14. Lang J, Spinner M. An important variation of the brachial plexus—complete fusion of the median and musculocutaneous nerves. *Bull Hosp Joint Dis.* 1970;31(1):7–13.
15. Saeed M, Rufai AA. Median and musculocutaneous nerves: variant formation and distribution. *Clin Anat.* 2003;16(5):453–457.