



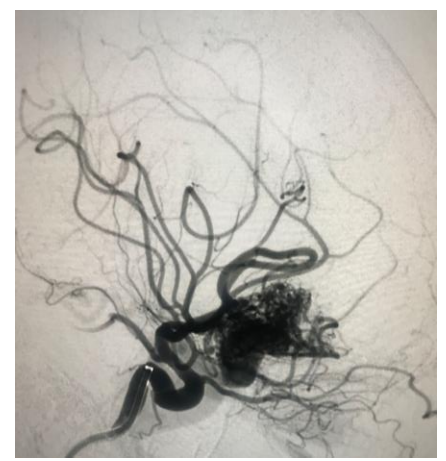
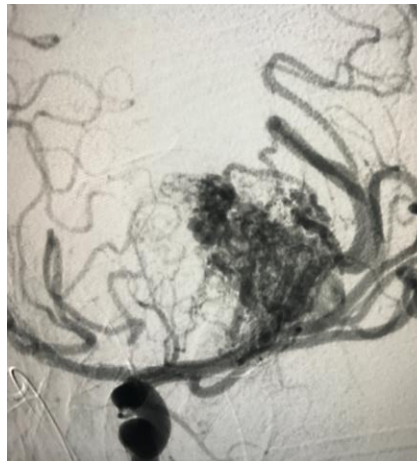
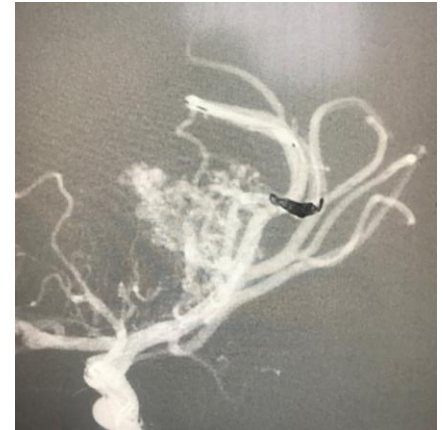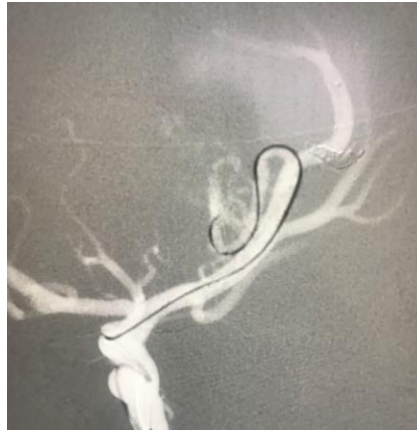AVM CASES

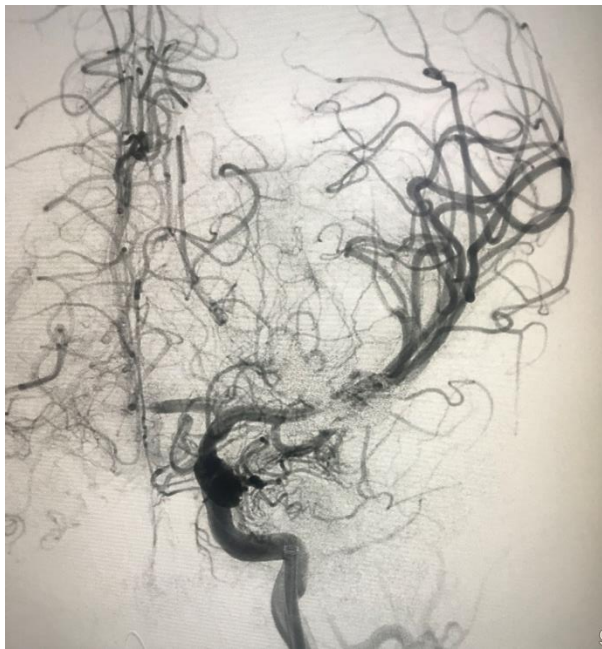
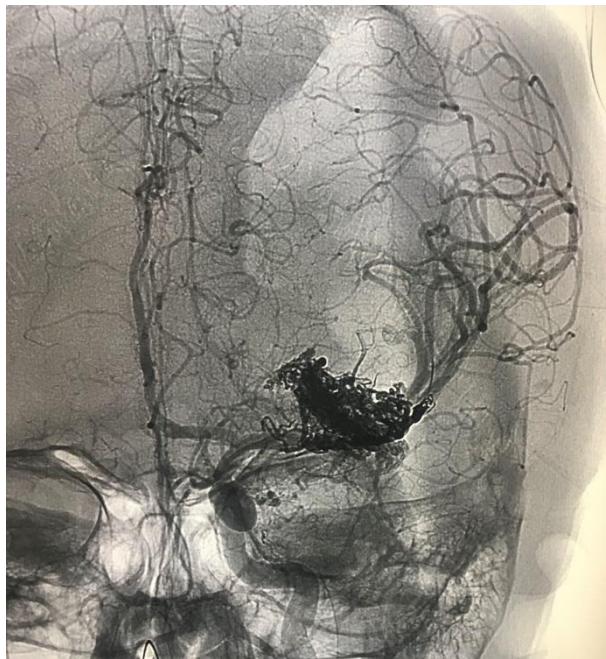
Dr Vikash Jain

Ruptured left frontal AVM in a 24/F.

AVM embolization done with

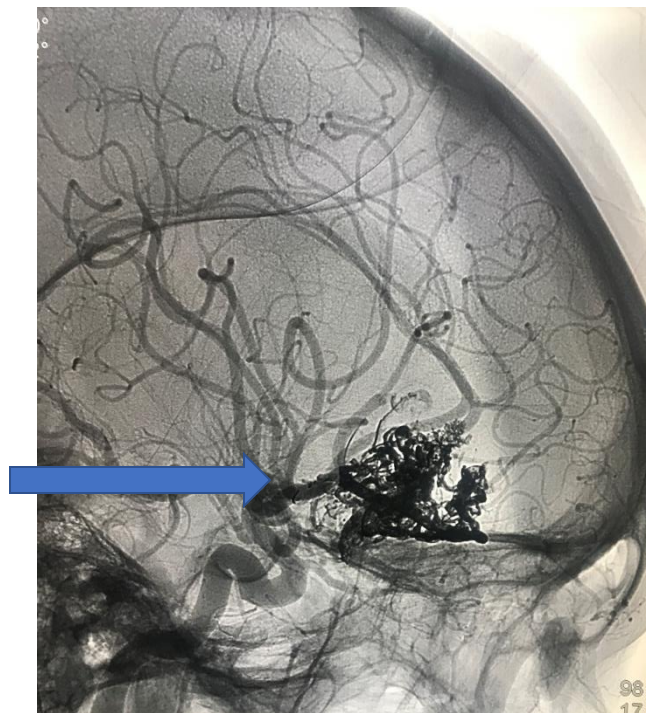
- "Pressure cooker" &
- "Double catheter technique".



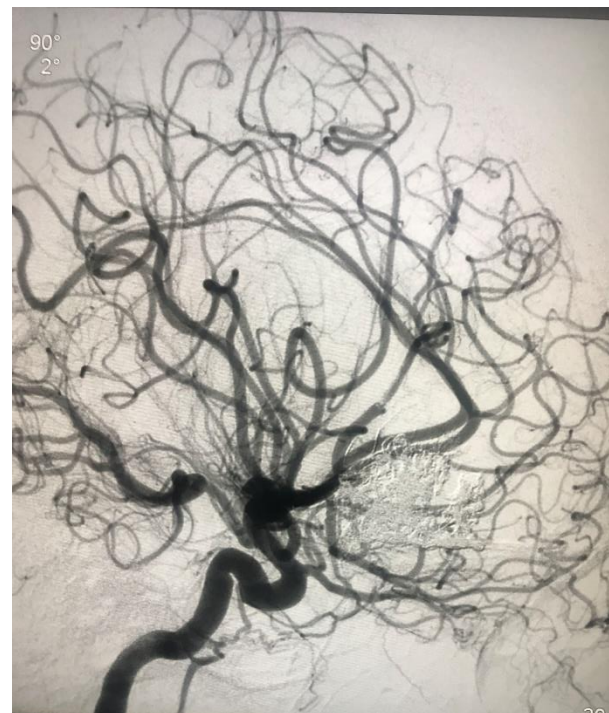


Complete AVM occlusion

Onyx cast

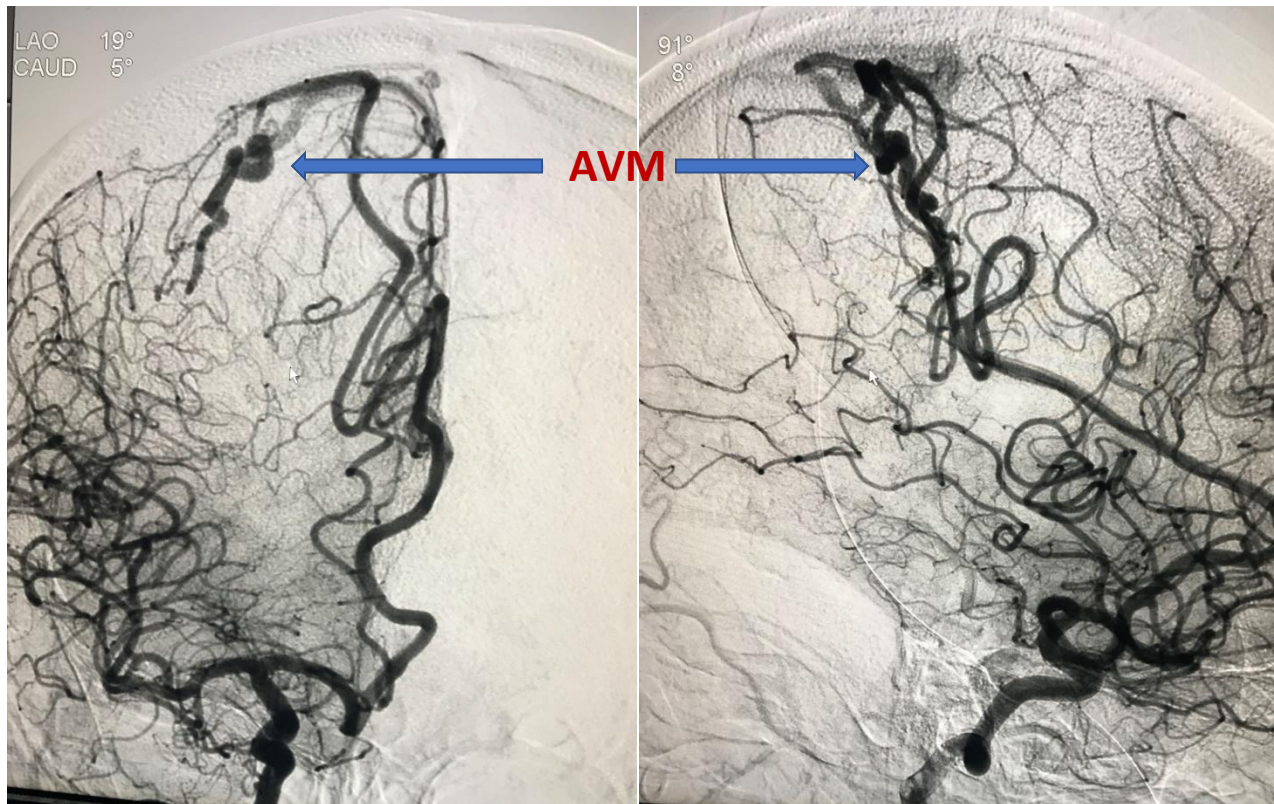


Patient doing well

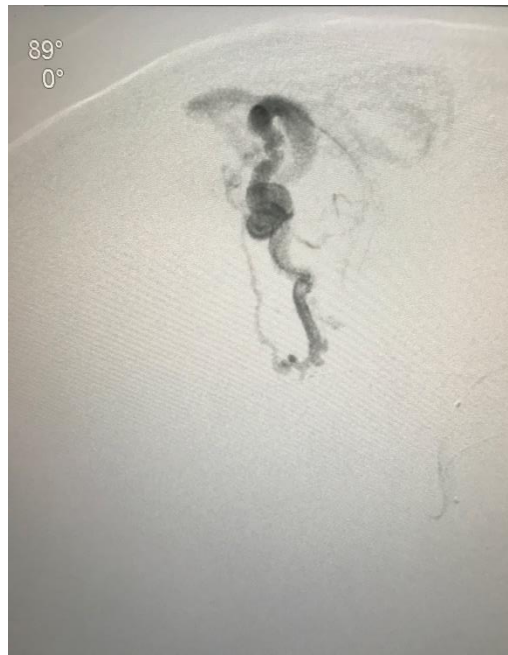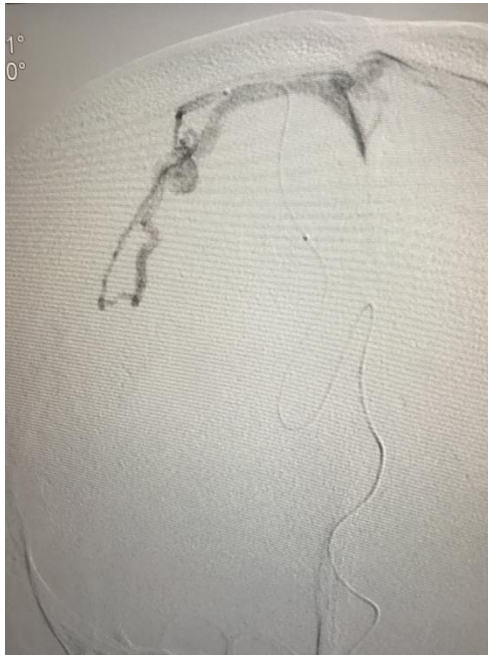


25/F

- Diagnosed with ruptured right parietal AVM.

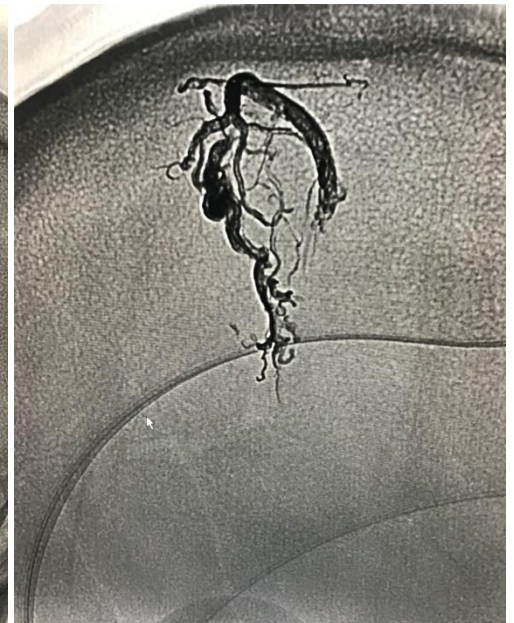
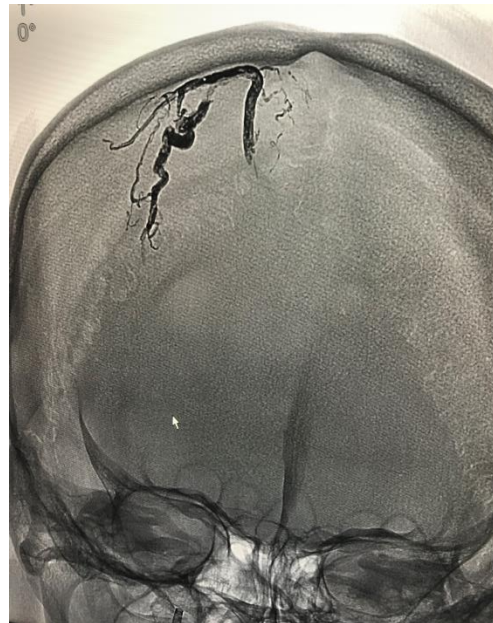

DSA shows small right parietal AVM



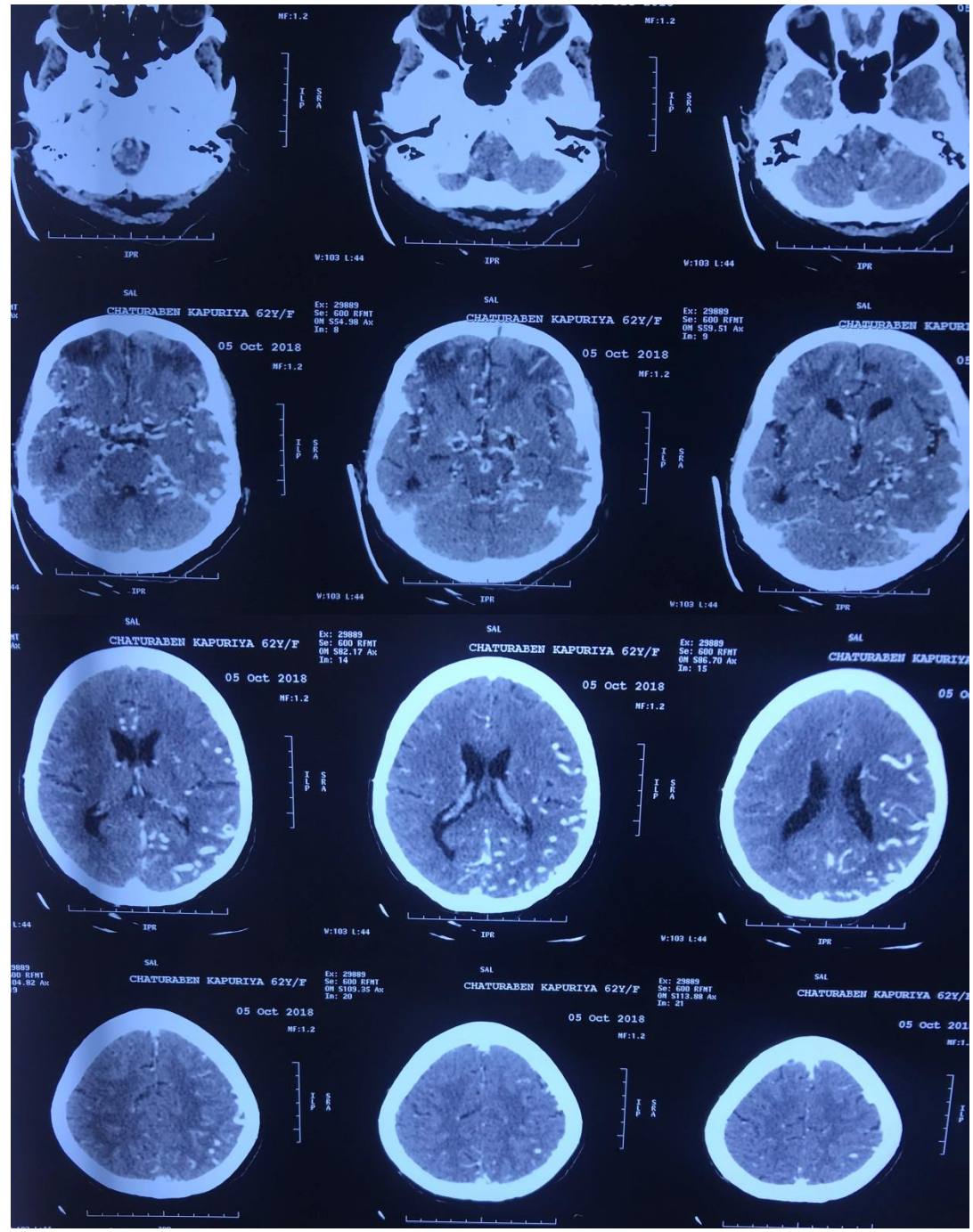
Microcatheter angiogram in AP and lateral projection

**Onyx cast,
Complete AVM occlusion**

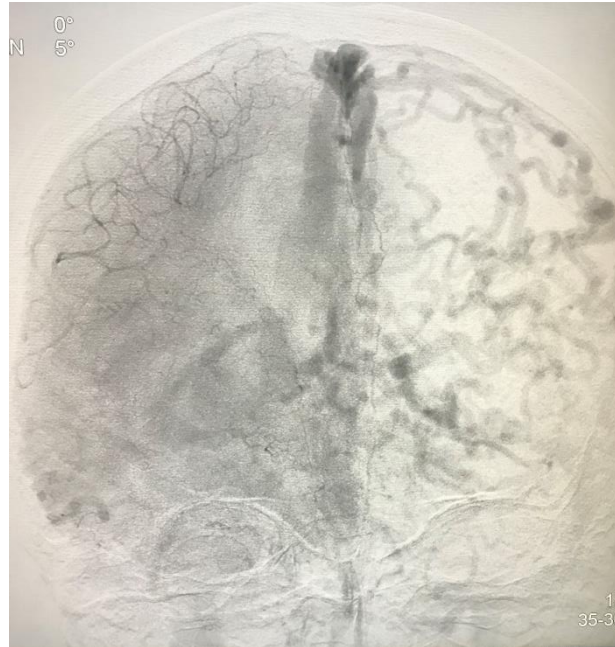
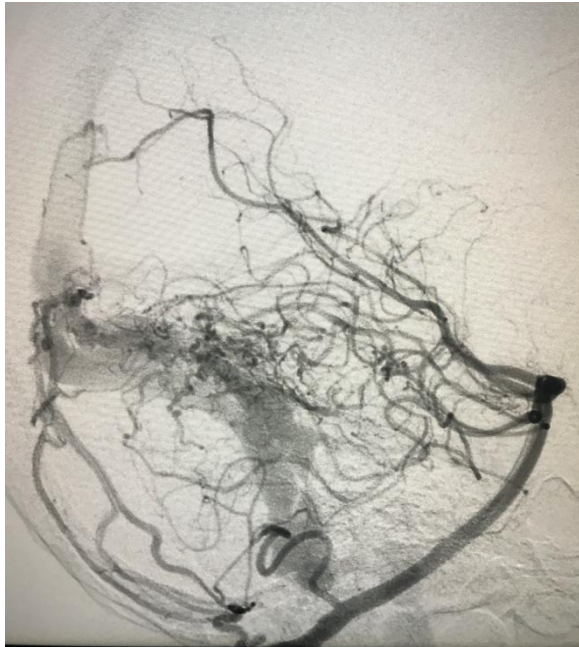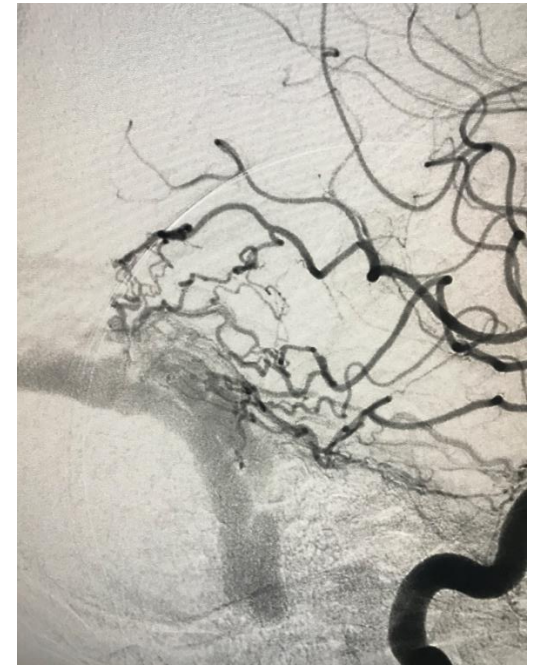

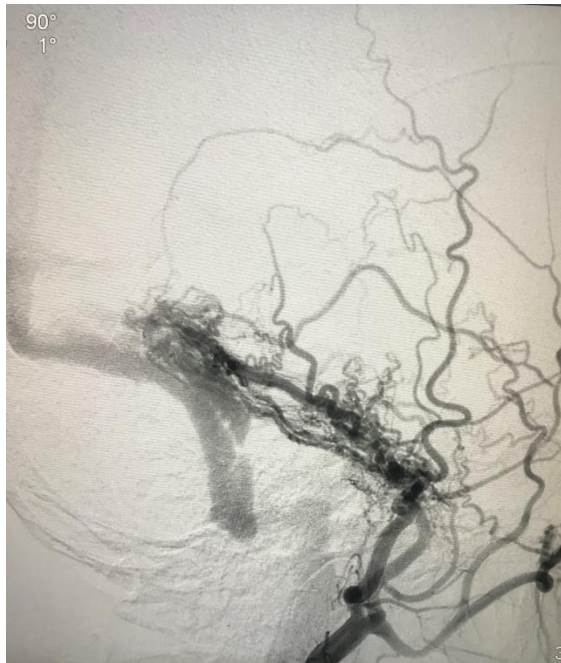
60/F Dural AVF

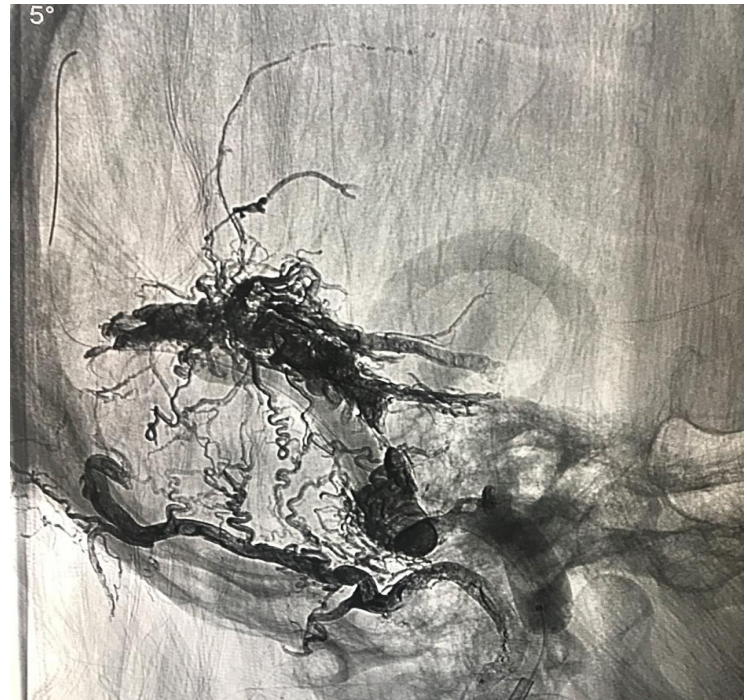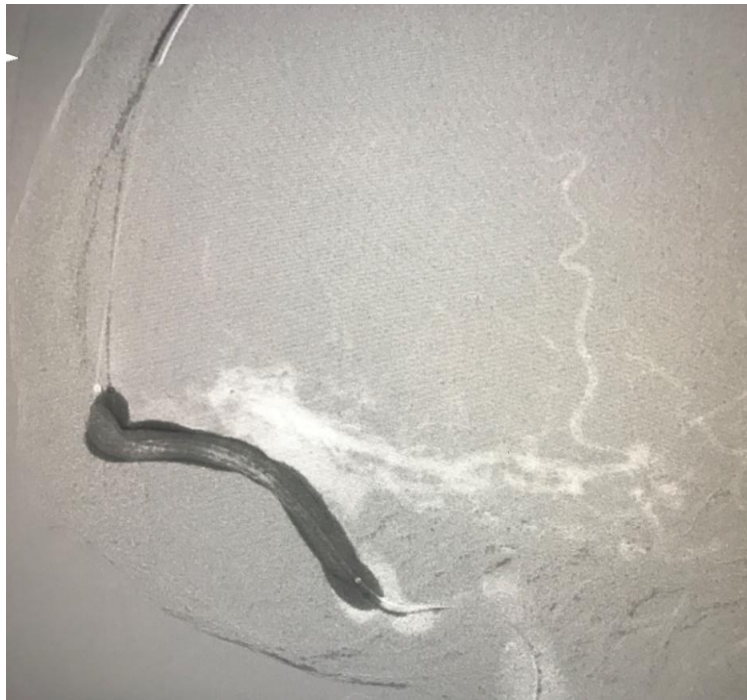- Presented with generalized and progressive slowing of mental process and loss of memory, difficulty in word finding (dementia).
- CT : shows cerebral venous congestion, edema and prominent veins s/o **Dural AVF**.



DSA shows dural AVF involving superior compartment of right transverse sinus supplied by multiple arteries.



Dural AVF embolized with onyx using balloon protection



- **Complete occlusion of fistula with patent right transverse sinus**

