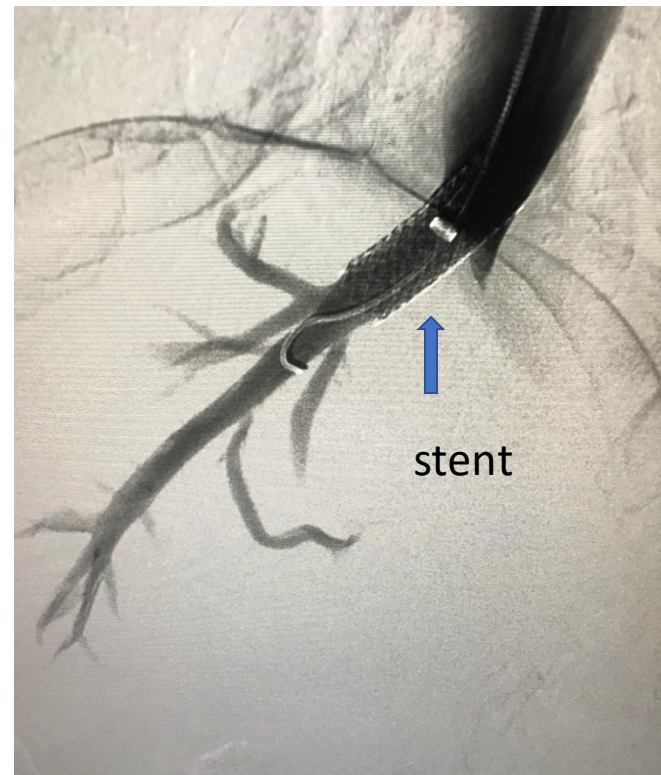
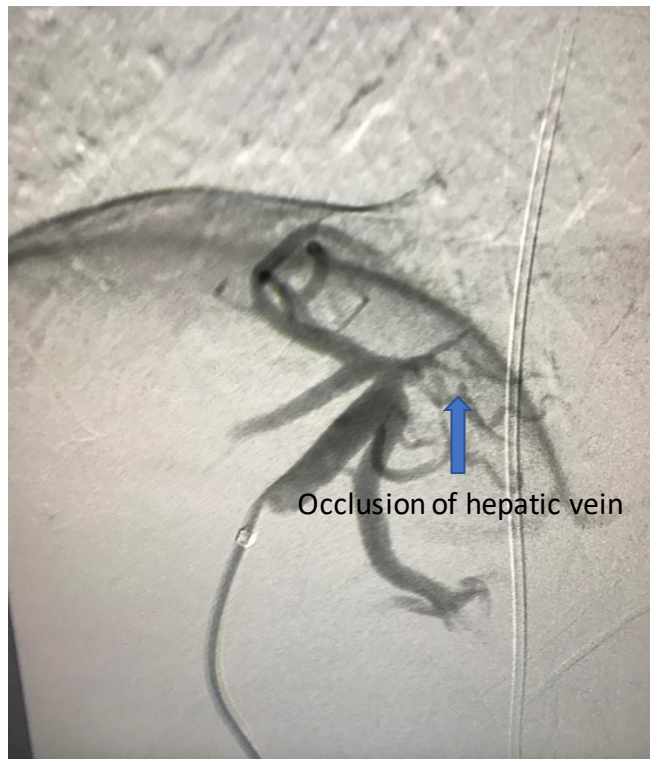

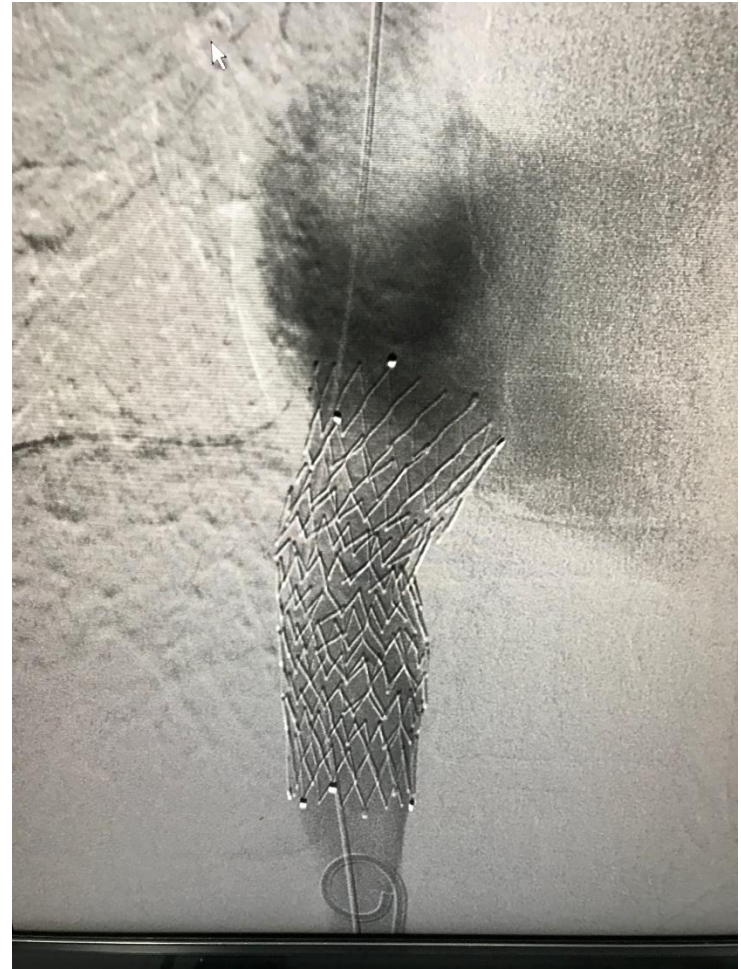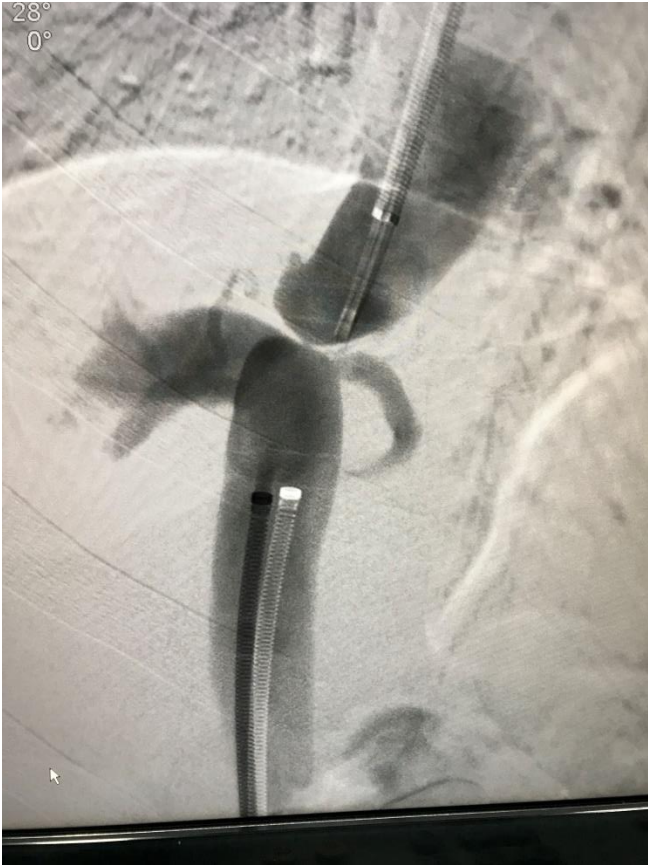# Budd Chiari Syndrome Cases

Dr Vikash Jain

24/ M with right hepatic vein stenosis.  
Hepatic vein stent done



21/M with membranous IVC occlusion. IVC stent done



20/F. Occluded all hepatic veins with ostial stenosis of hypertrophied caudate lobe vein. Accessory hepatic vein (caudate lobe vein) stenting.

