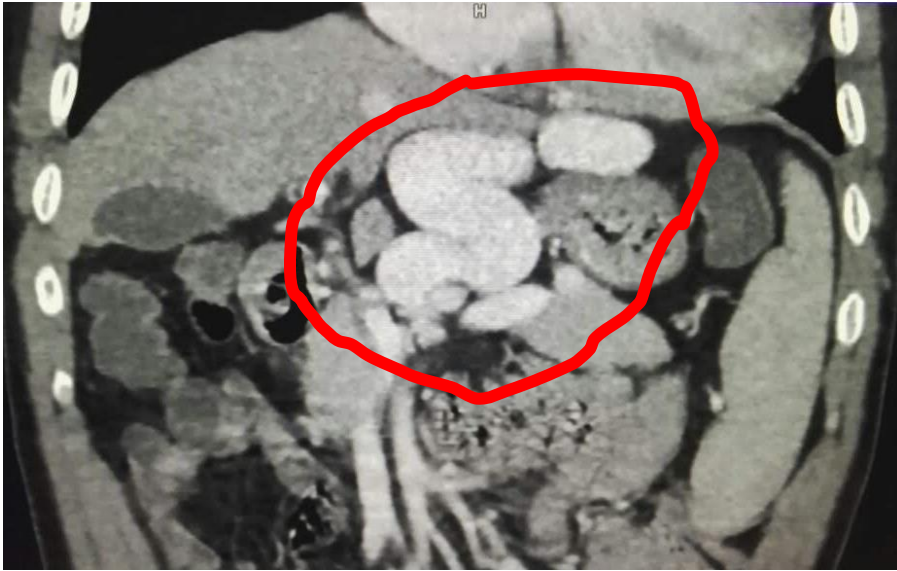


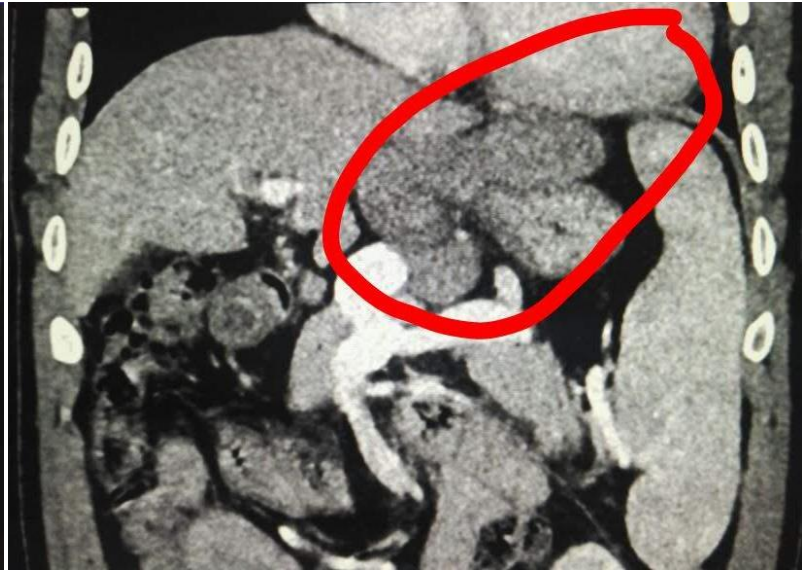

BRTO CASE IMAGES

Dr Vikash Jain

BRTO

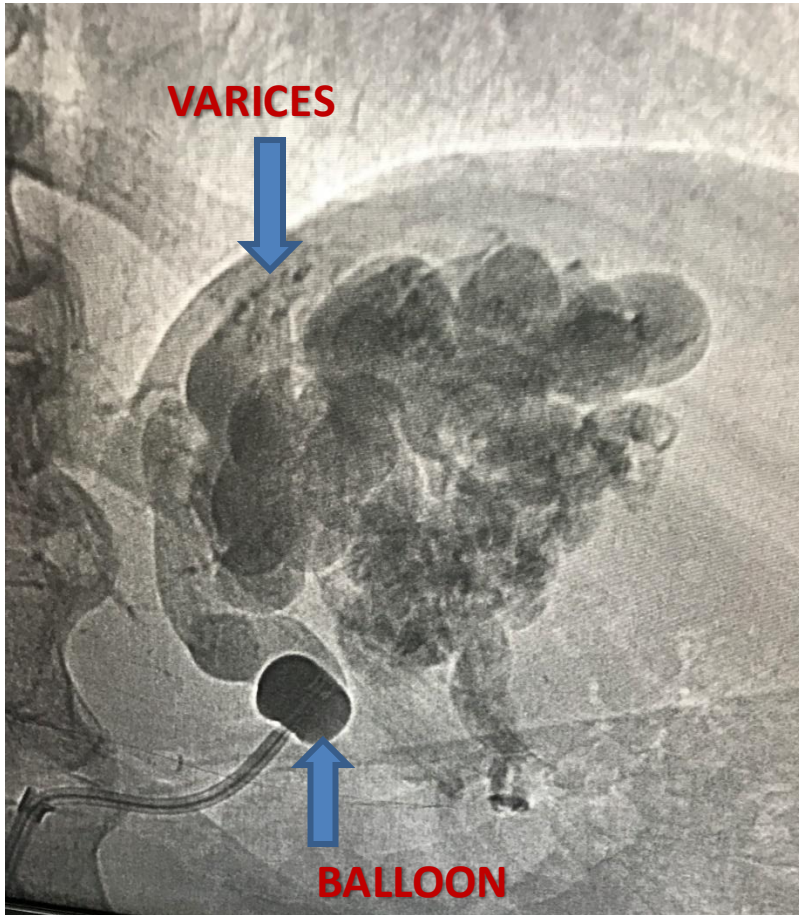


Flowing blood in varices



Obliterated varices

BRTO



PARTO

