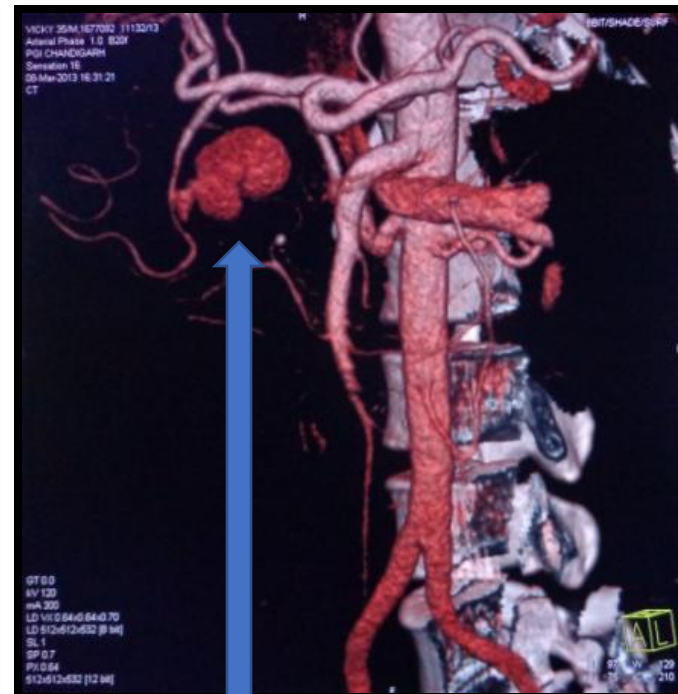


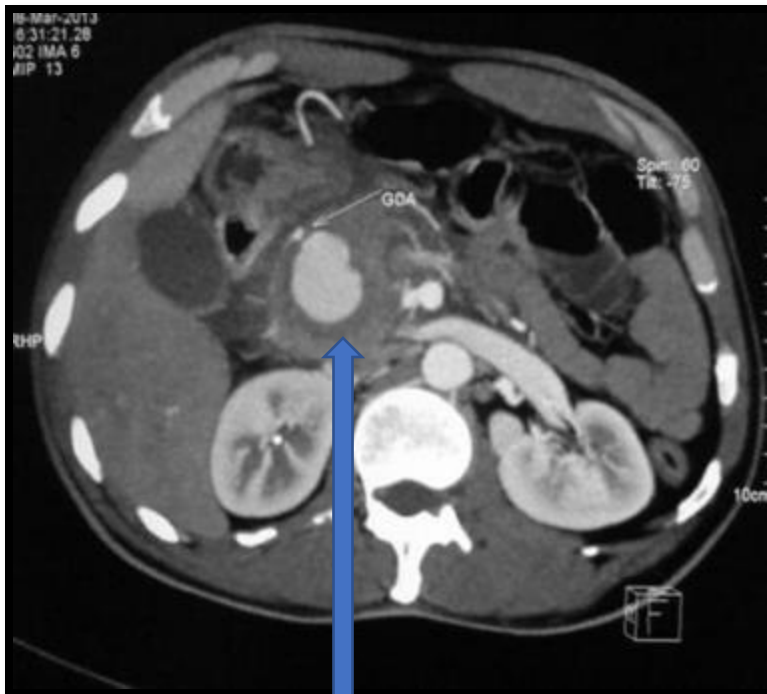Mesenteric Angiography & Embolization for Gastrointestinal Haemorrhage

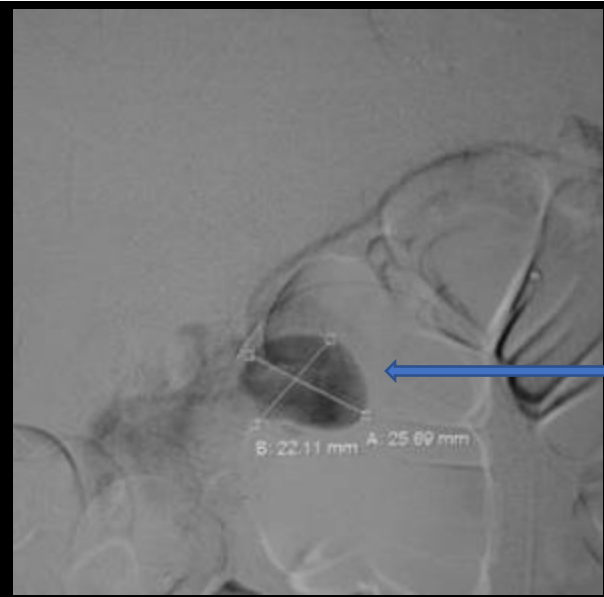
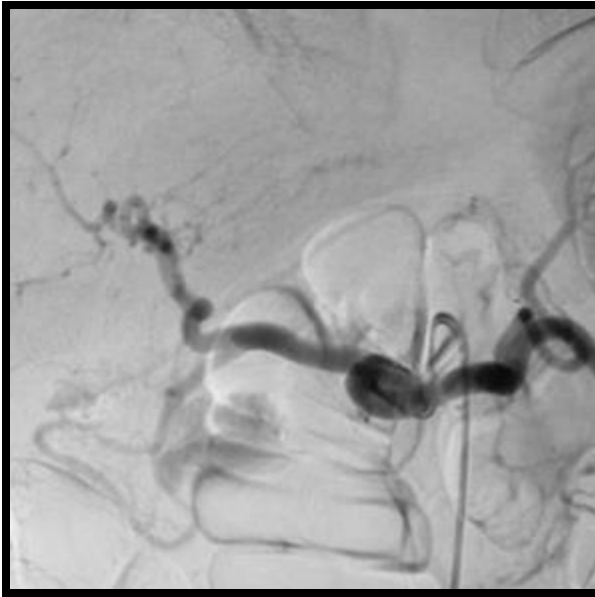
Dr. Vikash Jain

Case 1: Blood in vomit

- 35/M with pancreatitis presented with sudden onset massive bleeding in vomit.
- CT angiography shows large bulge(pseudoaneurysm) in the artery adjacent to the pancreas suggesting the site of bleeding.

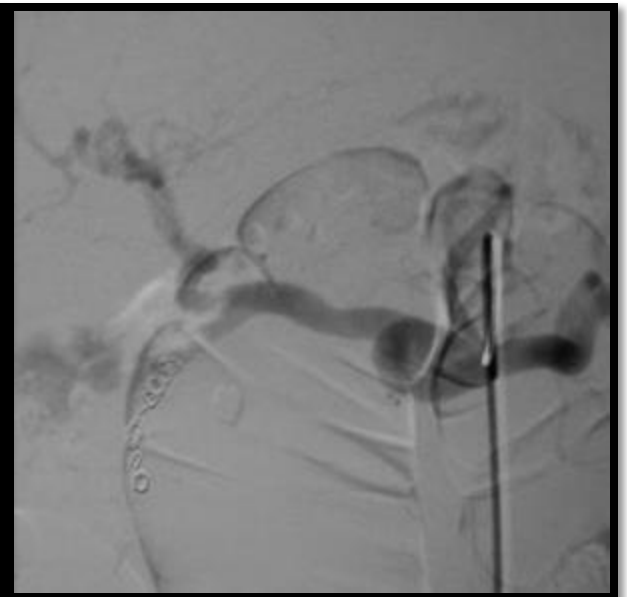
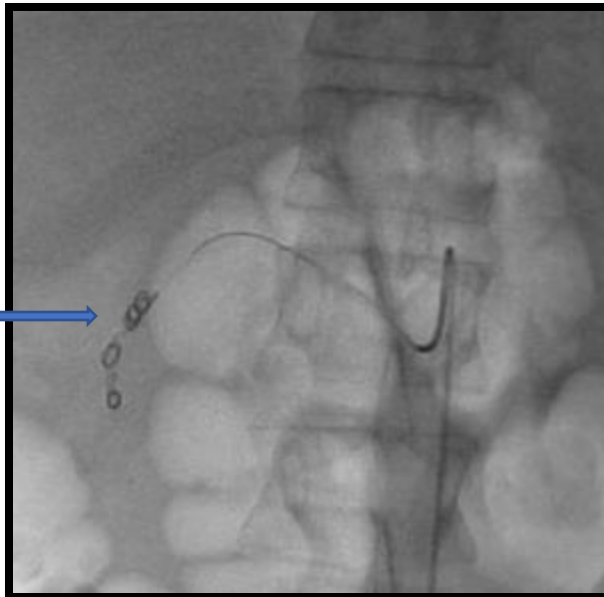


Gastro-duodenal artery Psuedoaneurysm



Large bulge in the artery
(pseudoaneurysm)
representing the site of
bleeding

The artery supplying
pseudoaneurysm is occluded with
multiple wires called coils thereby
completely stopping the bleed



Case 2:

Bleeding in stool

Severe bleeding into the large bowel (arrow)

Treated with selective
Blockage of the bleeding
artery

Emergency surgery
avoided

