

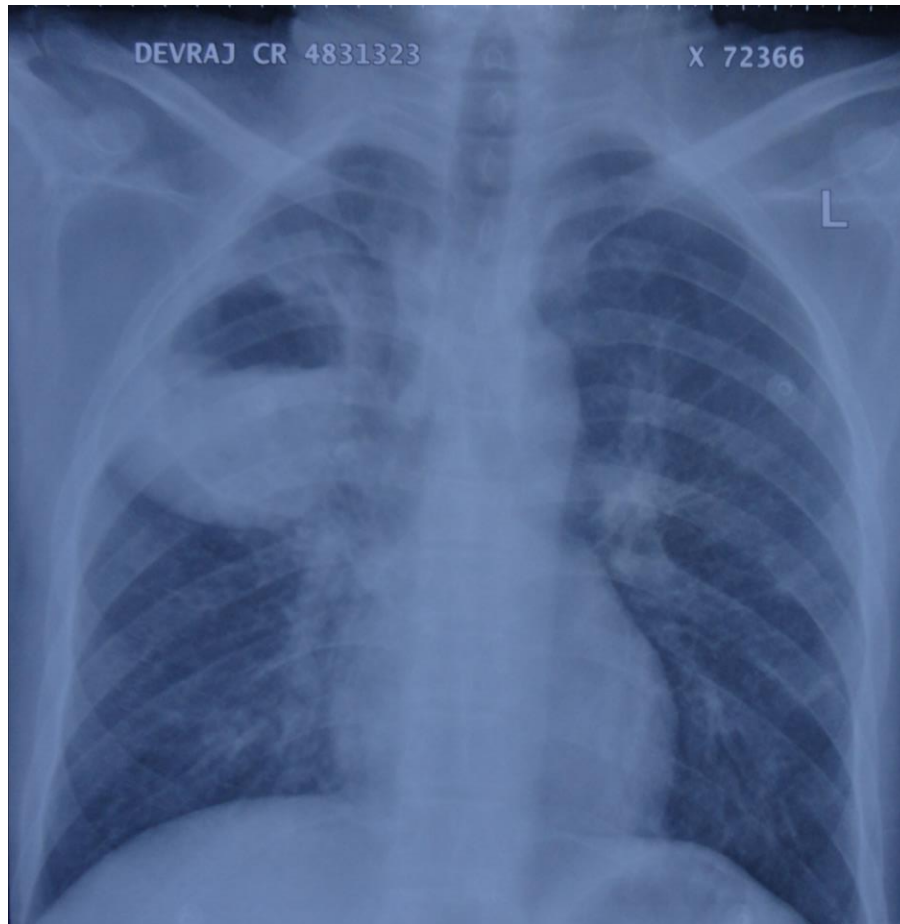
# Bronchial Artery Embolization for the Management of Hemoptysis

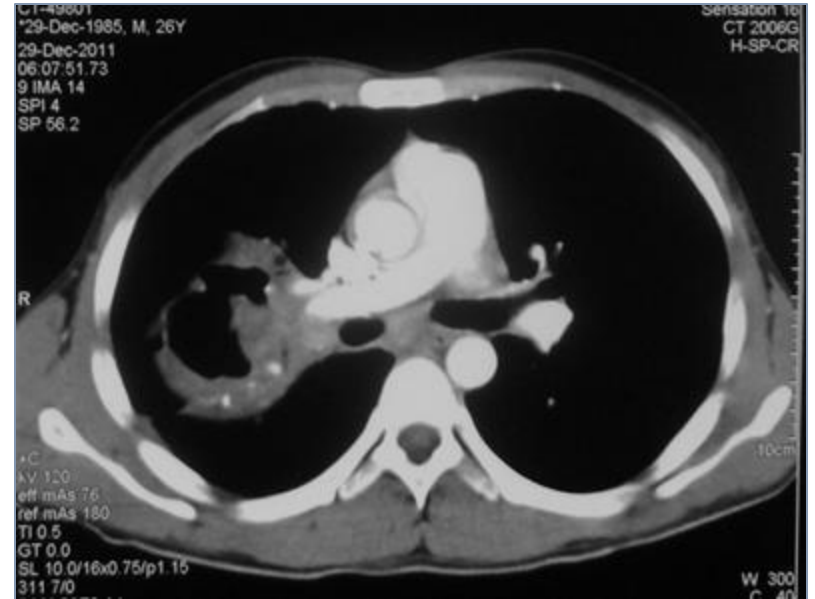
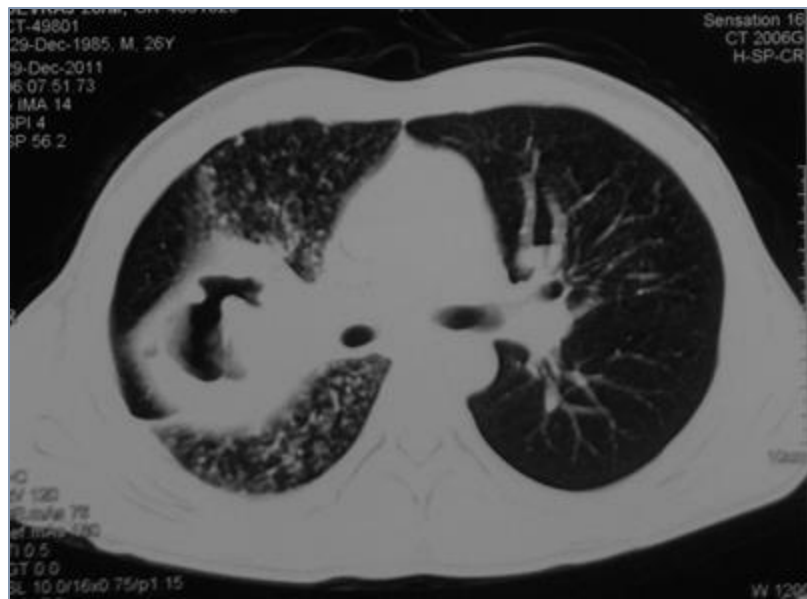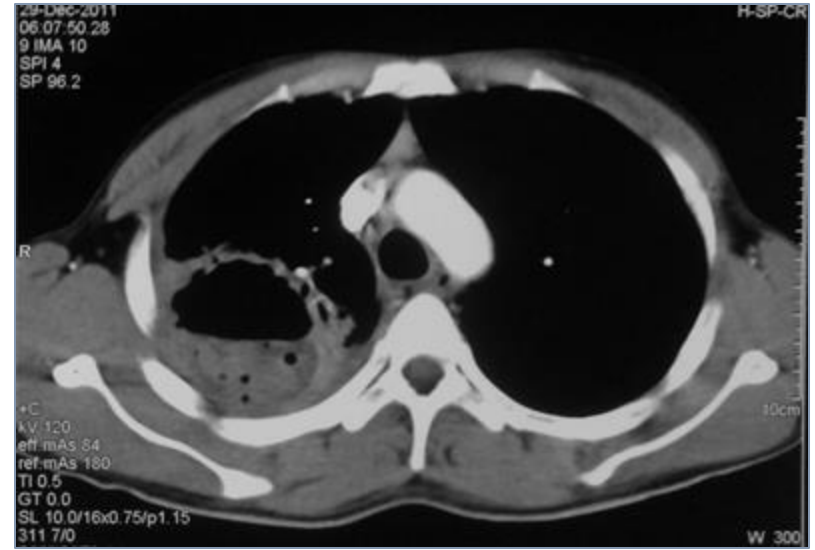
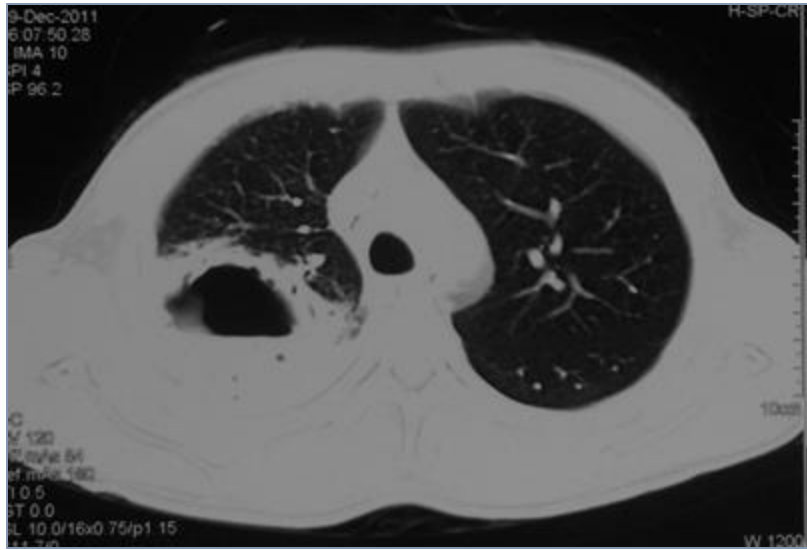
Dr. Vikash Jain

26 yrs/M

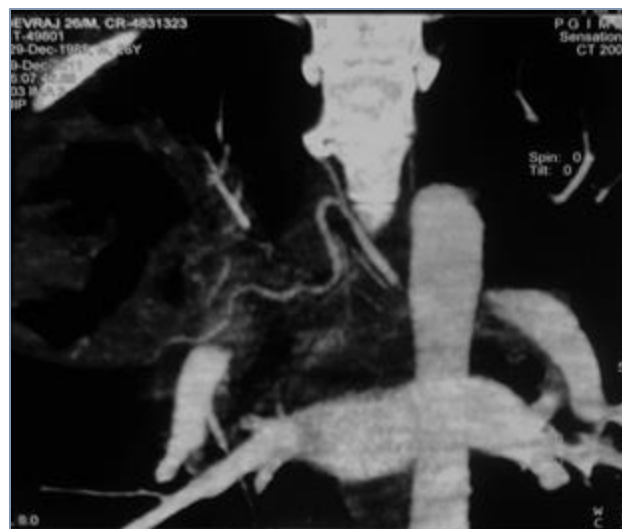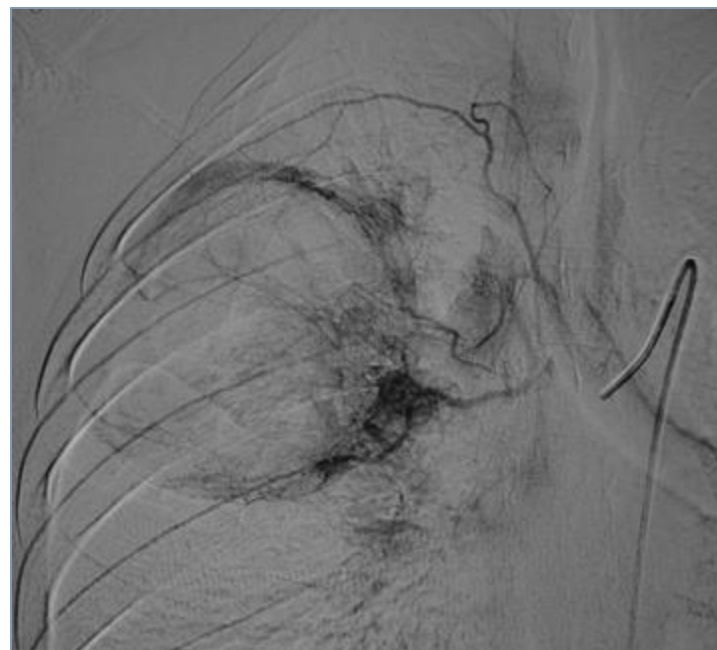
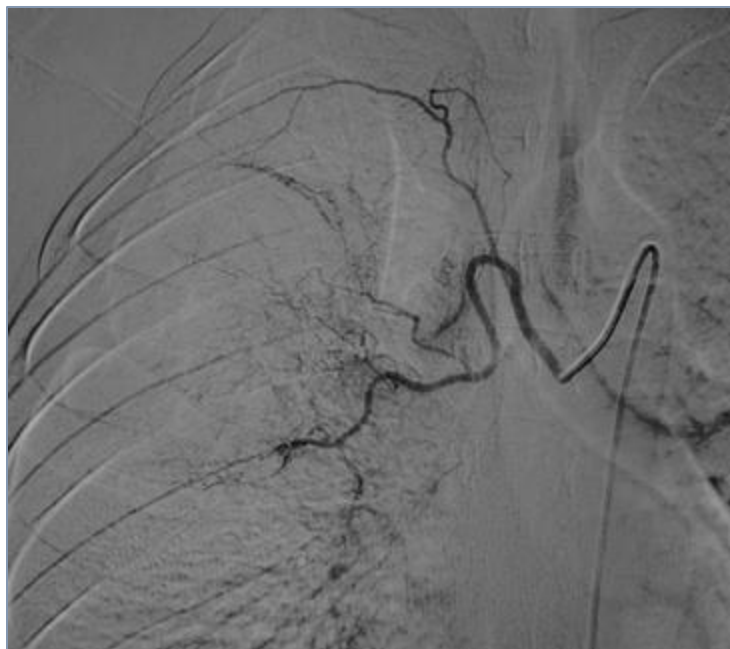
- Clinical details:
- K/c/o Pulmonary tuberculosis on treatment since 10 days.
- c/o Massive Hemoptysis ~ 800 ml in 24 hrs.
- Hb – 8.2 gms %.

# Chest x ray: Abscess in right upper lobe of lung

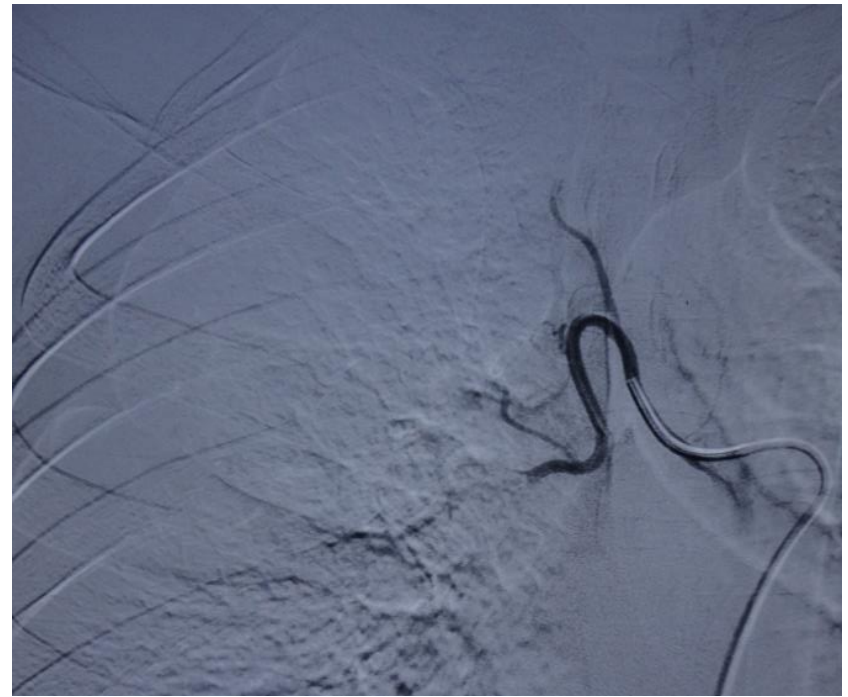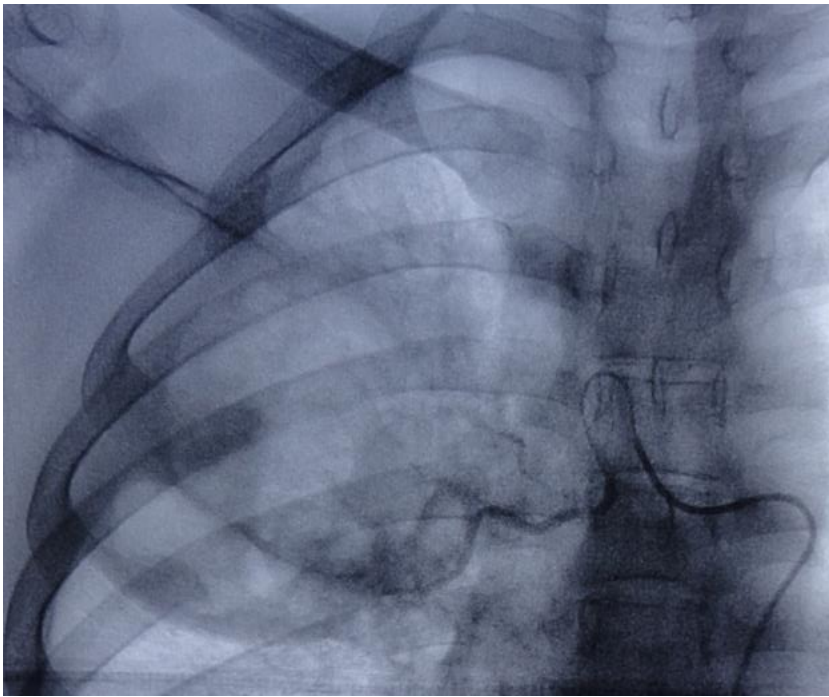




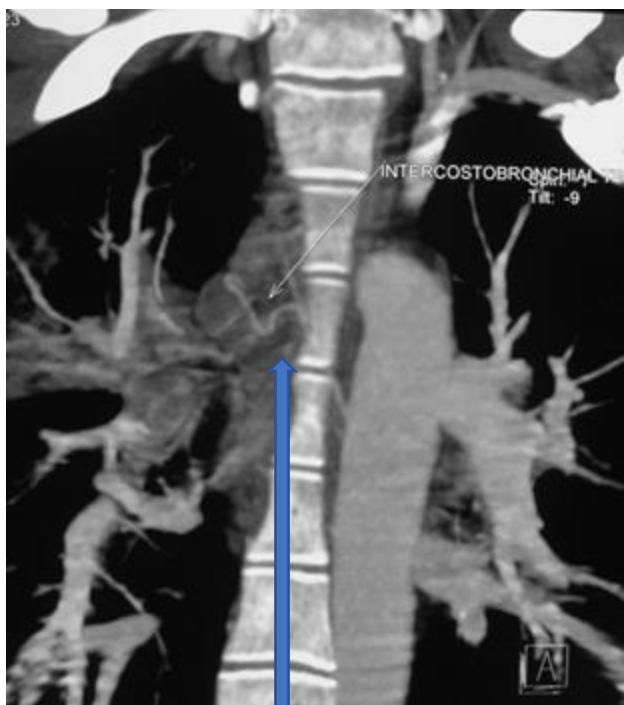
# Hypertrophied bronchial artery supplying wall of abscess



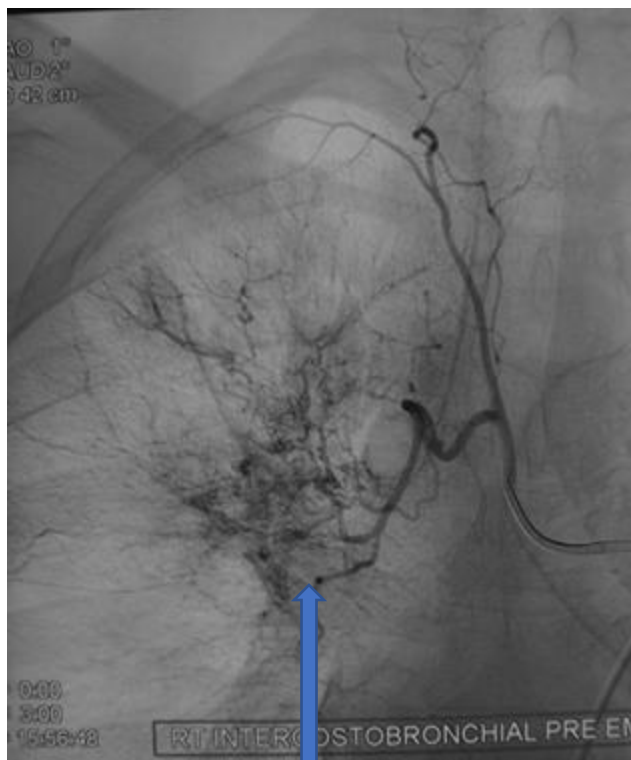# Bronchial artery supplying abscess embolized thereby providing cure for hemoptysis



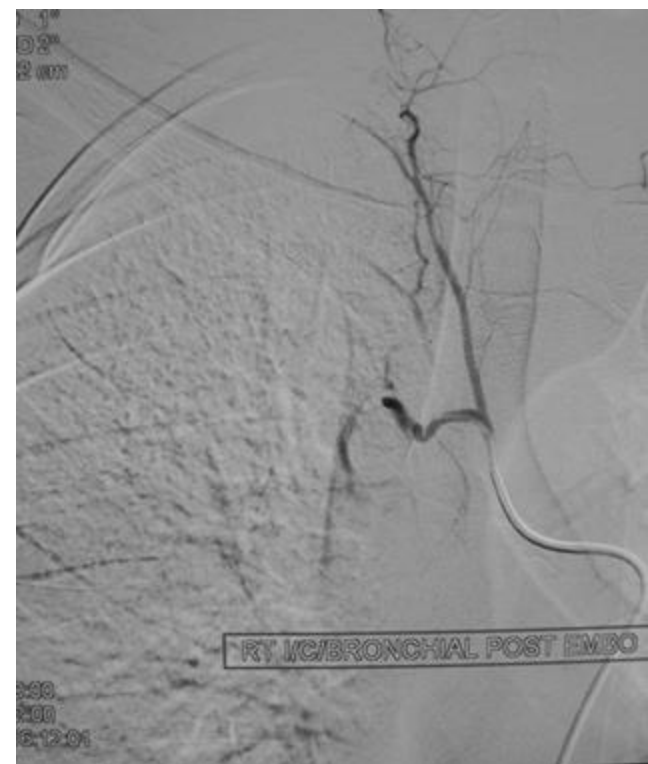# Another case showing prominent ICBT, hemoptysis stopped after embolization



Prominent Intercostobronchial artery



Abnormal vascular blush



Complete embolization

# Left Bronchial artery supplying disease lung, embolization taking care of hemoptysis

