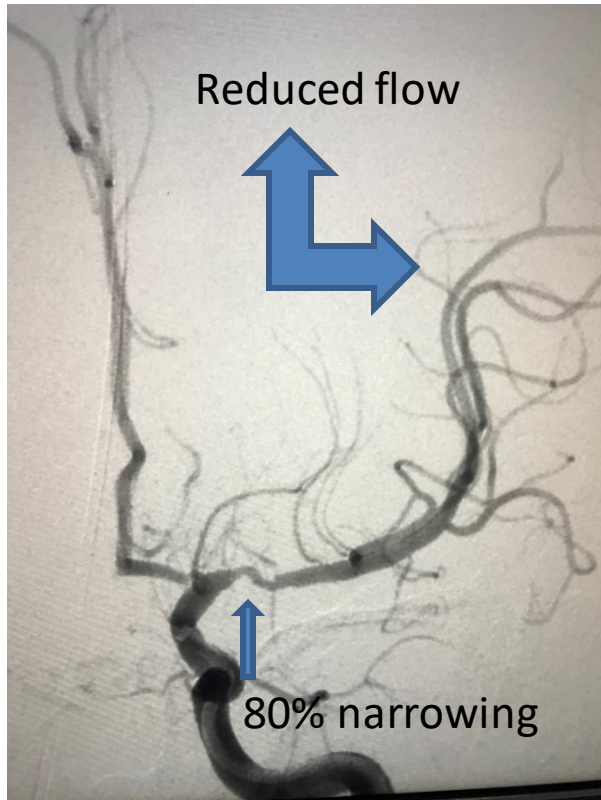




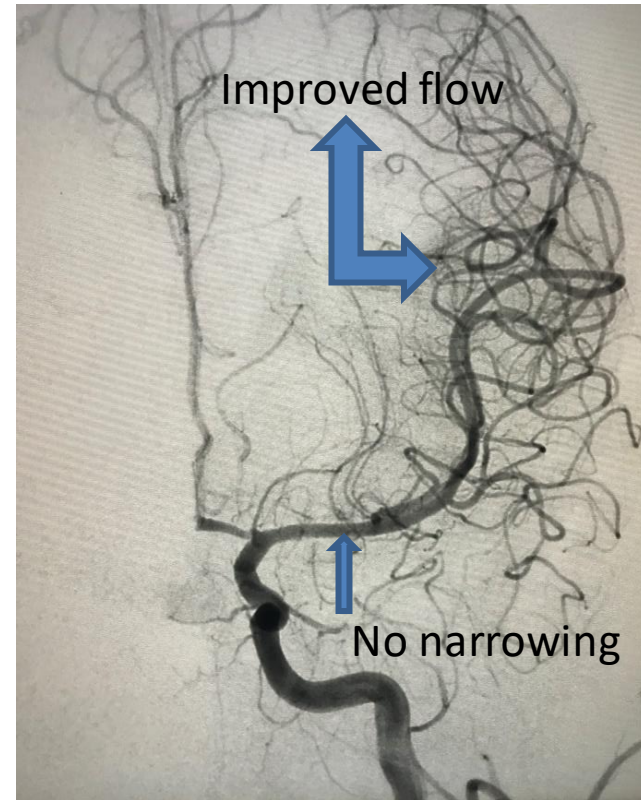
ICAD CASES

Dr. Vikash Jain

59 Year old Lady with Recurrent Stroke



Left middle cerebral artery 80% stenosis and hypoperfusion related infarcts



Complete recanalization after stenting with improved flow