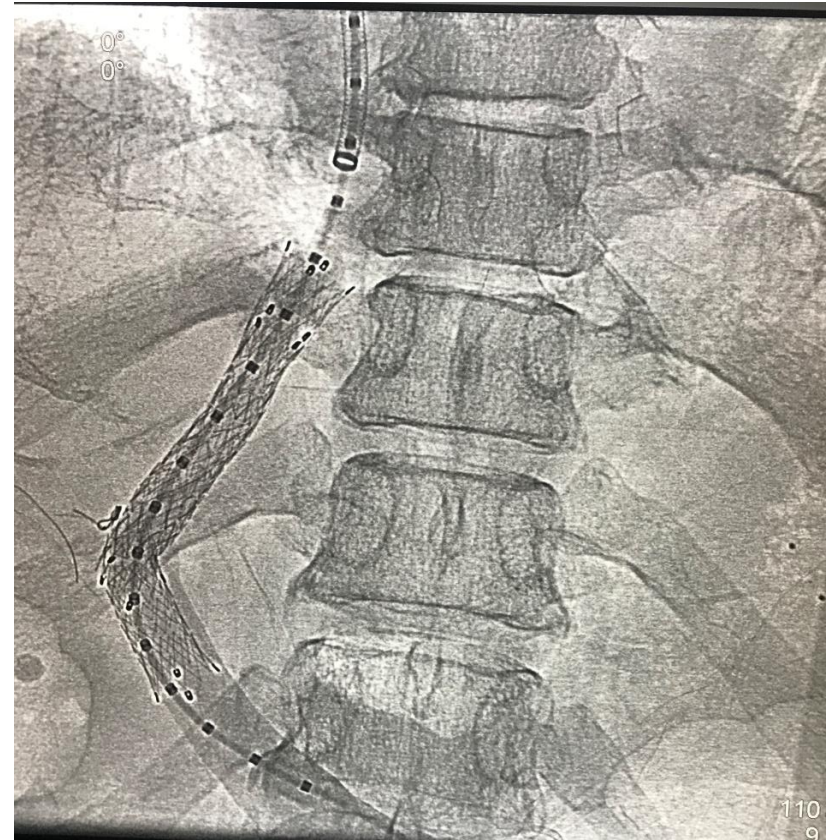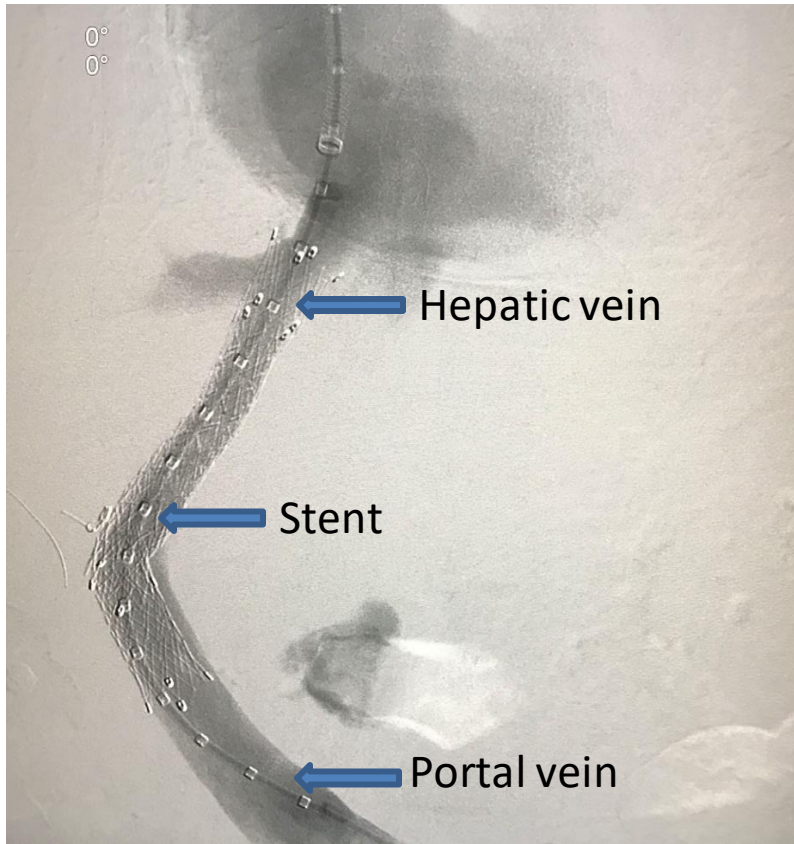




TIPSS CASES

Dr. Vikash Jain

TIPSS



TIPSS done in a 55 years old patient with refractory ascites (accumulation of fluid in abdomen) due to chronic liver disease. Post procedure no requirement of tapping.