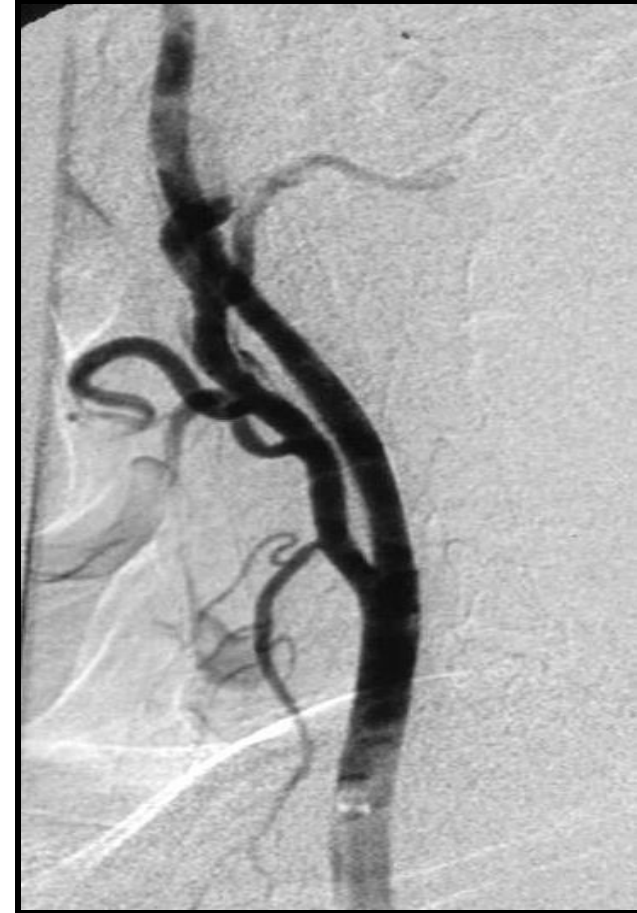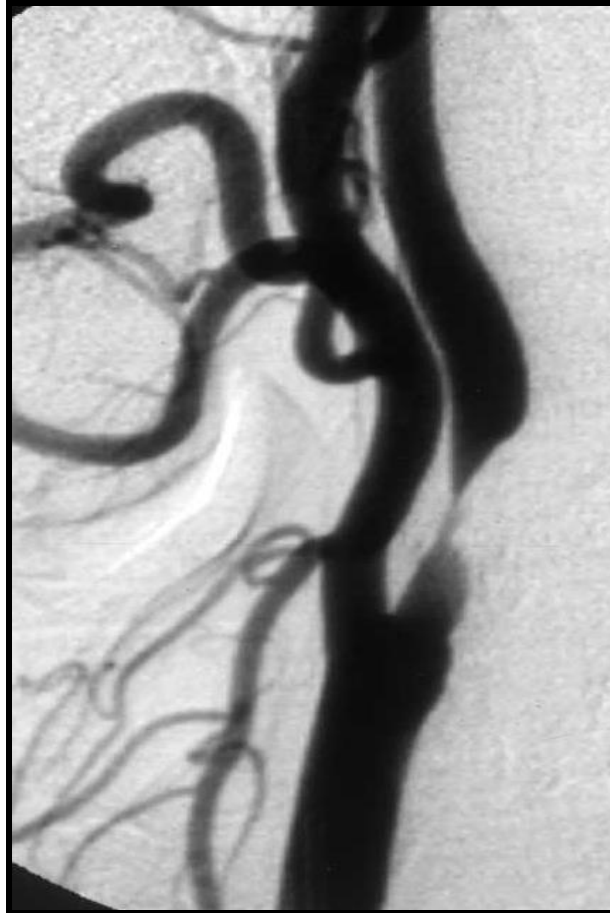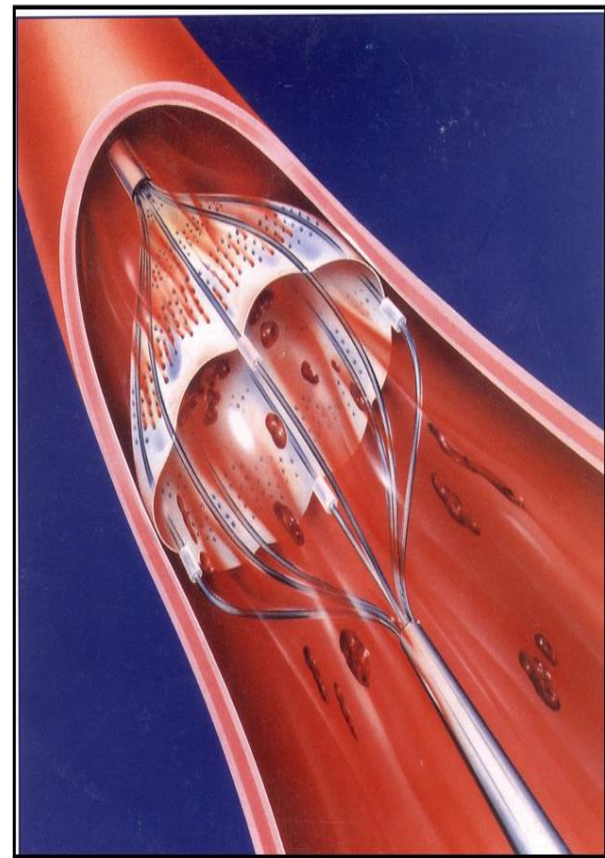


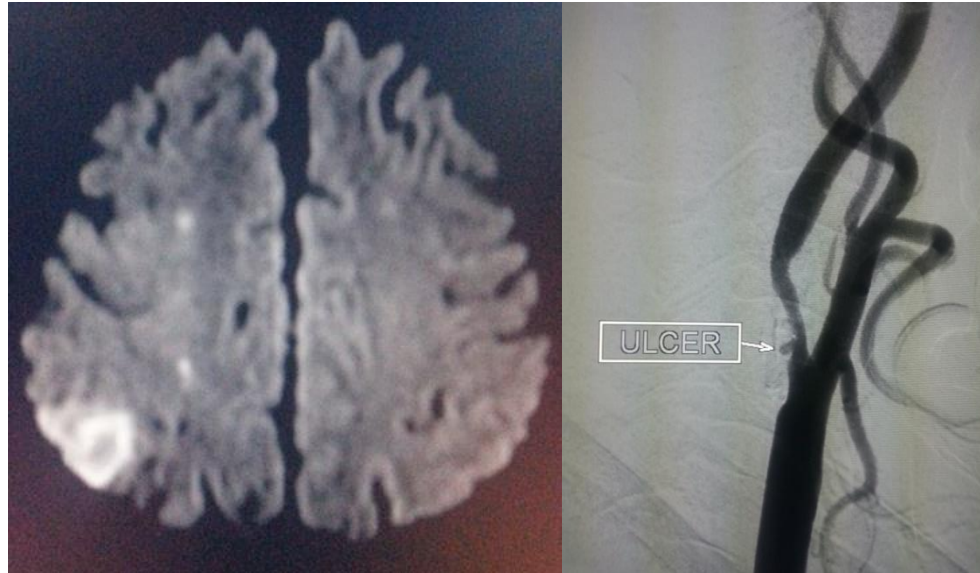# Carotid Stenting Cases

Dr Vikash Jain

# Carotid Stenting



# Carotid Stenting



- 54/M patient presented with left upper limb mild weakness.
- MRI: watershed infarct in right side.
- DSA: ulcerated right carotid stenosis.

- Right carotid stenting done reopening the artery and thereby preventing further stroke.

