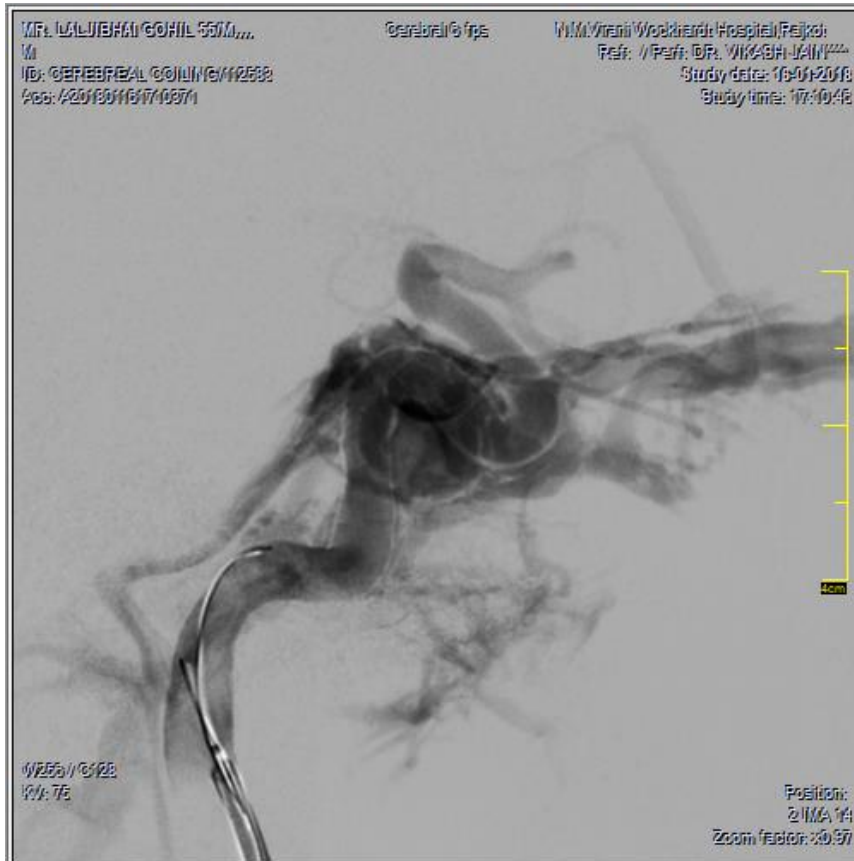




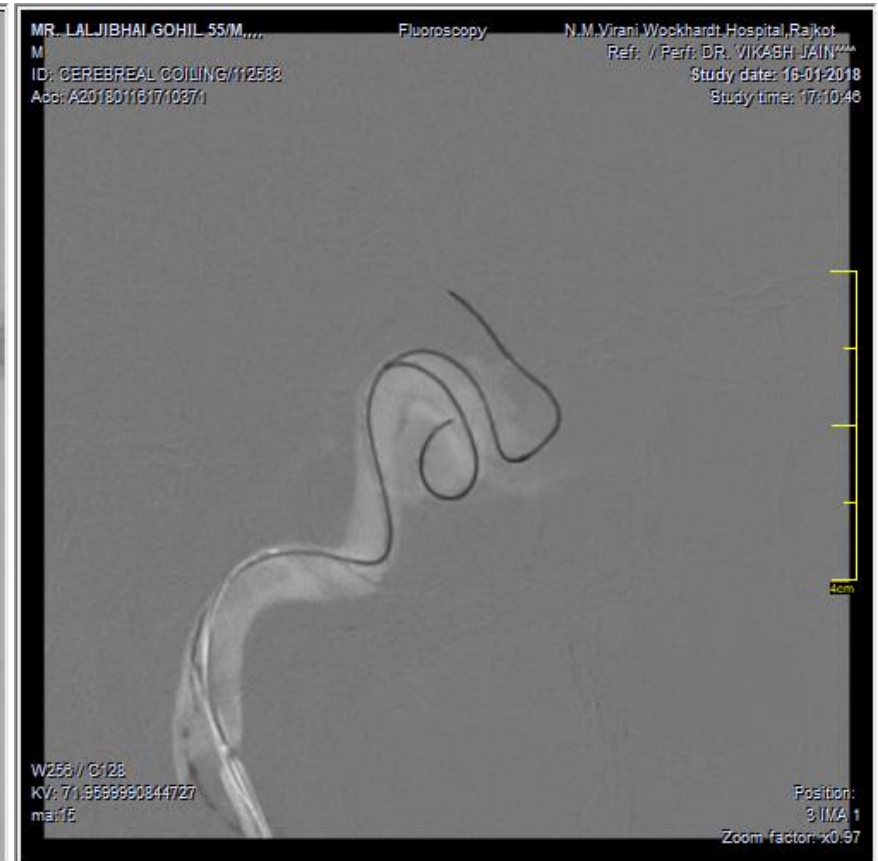
# CCF CASES

Dr. Vikash Jain

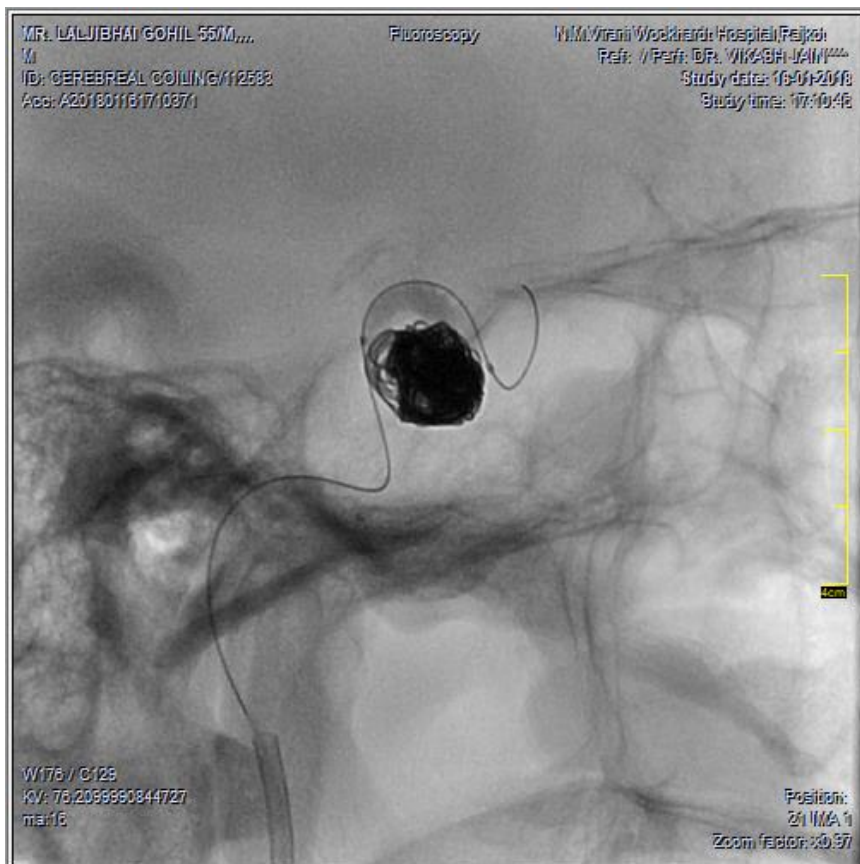
49/M presented with redness and bulging of eye, eye lid swelling and dimness of vision two days after road traffic accident



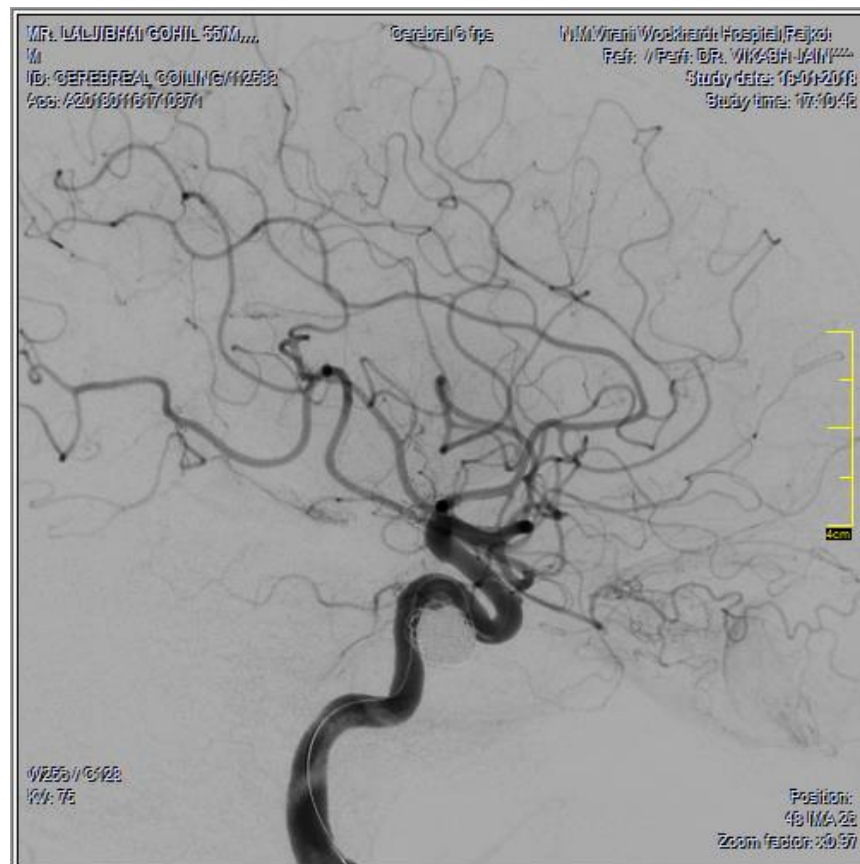
Early contrast staining of cavernous sinus, orbital veins and petrosal veins with visualization of rent in cavernous segment of ICA suggestive of direct CCF



Cavernous sinus cannulated with microcatheter



Cavernous sinus embolized with coils and onyx.



Post coiling angiogram revealed complete occlusion of CCF