



## Patient Report

## Challenging diagnosis between intussusception and necrotizing enterocolitis in premature infants

Hakan Taşkınlar,<sup>1</sup> Gökhan Gündoğdu,<sup>3</sup> Yalçın Çelik,<sup>2</sup> Dinçer Avlan<sup>1</sup> and Ali Naycı<sup>1</sup>*Departments of <sup>1</sup>Pediatric Surgery and <sup>2</sup>Pediatrics, Division of Neonatology, School of Medicine, Mersin University, Mersin and <sup>3</sup>Department of Pediatric Surgery, School of Medicine, Bezmialem Vakıf University, Istanbul, Turkey*

**Abstract** Although necrotizing enterocolitis (NEC) is a frequently encountered entity in premature infants in the neonatal intensive care unit, intussusception is extremely rare. Abdominal distension, bilious/non-bilious gastric residuals and bloody stool are the common clinical findings of both entities. Here we present three cases of intussusception misdiagnosed as NEC, two of which were complicated with intestinal perforation. Similar clinical findings of NEC and intussusception leads to misdiagnosis and delay in treatment, particularly in premature infants with intussusception.

**Key words** intestinal perforation, intussusception, necrotizing enterocolitis, newborn, prematurity.

Although intussusception is a well-known cause of intestinal obstruction in infants commonly between the ages of 3 and 18 months, it can rarely be detected in the neonatal period. Abdominal distension, feeding difficulties, bilious vomiting and bloody stool in the neonatal period, especially in premature infants, are usually thought to be due to necrotizing enterocolitis (NEC).<sup>1,2</sup> Due to the similar symptomatology of NEC and intussusception and the high prevalence of NEC in this age group, we highlight the difficulties in the differential diagnosis and the delay in treatment of intussusception in premature infants.

### Case reports

#### Case 1

A 725 g girl was born at 25 weeks' gestation by cesarean section to a 32-year-old gravida 3, para 1 mother with premature rupture of the membranes. Apgar scores were 7 and 8 at 1 and 5 min, respectively. The infant was admitted to the neonatal intensive care unit (NICU) and required prolonged mechanical ventilation. On day 11 sudden deterioration with abdominal distension and bilious gastric residuals occurred. Complete blood count indicated anemia without thrombocytopenia and mild leukocytosis. On blood biochemistry, serum electrolytes, liver and renal function tests were within normal limits. Pneumoperitoneum was detected on plain abdominal X-ray. A diagnosis of intestinal perforation due to NEC was suspected and a Penrose drain was placed. Next day an exploratory laparotomy was done. Ileo-ileal invagination with a perforation proximal to the invagination site was detected. There was no lead point or necrotic area in any part of the intestinal system. Resection and primary anastomosis was

performed. The patient recovered soon after the operation, enteral feeding started on day 7 and she was discharged home in good general condition.

#### Case 2

A 700 g girl was born at 29 weeks' gestation by normal spontaneous vaginal delivery to a 27-year-old mother with premature rupture of the membranes. Apgar scores were 5 and 7 at 1 and 5 min, respectively. The baby was intubated immediately due to respiratory distress and was admitted to NICU. When she was 8 days old she had abdominal distension with bilious gastric residuals. Abdominal tenderness was also present. On plain abdominal X-ray pneumoperitoneum was detected. Blood biochemistry indicated mild hyponatremia. Exploratory laparotomy was performed and an ileo-ileal intussusception with a lead point of Meckel's diverticulum was found. The invaginated intestinal segment was necrotic and perforated, therefore resection of the necrotic segment and ileo-ileostomy was performed. The postoperative course was uneventful. Enteral feeding started on postoperative day 9 and she was good in general condition when discharged from hospital.

#### Case 3

An 1800 g boy was born at 31 weeks' gestation by normal spontaneous vaginal delivery with placental abruption. Apgar scores were 5 and 7 at 1 and 5 min, respectively. The infant had significant respiratory distress with circulatory failure and was intubated immediately. He was mechanically ventilated for 4 days and supported with nasal continuous positive airway pressure for 2 days. Feeding was attempted via oro-gastric tube with small amounts of mother milk. When he was 15 days old abdominal distension and bilious vomiting occurred. During follow up, abdominal tenderness and bloody stool was also seen. Abdominal X-rays indicated dilatation of the small bowel. Neither abdominal ultrasonography nor radiopaque colon X-ray showed any

Correspondence: Hakan Taşkınlar, MD, Department of Pediatric Surgery, School of Medicine, Mersin University, Mersin 33050, Turkey. Email: hakantaskinlar@gmail.com

Received 12 June 2013; revised 8 January 2014; accepted 21 January 2014.

pathological sign. When he was 18 days old, exploratory laparotomy was performed and ileo-ileal intussusception was found 40 cm proximal to the terminal ileum with no sign of perforation or lead point, but the invaginated bowel segment was necrotic. Also another spontaneously resolved ileo-ileal invaginated necrotic segment was found 20 cm proximal to the terminal ileum (Fig. 1). The necrotic ileal segment was resected and ileo-ileal anastomosis was performed. The patient did well soon after the operation, and tolerated enteral feeding without any problem.

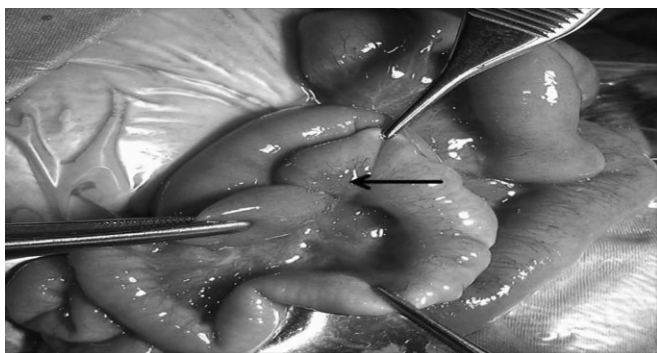
Demographics and clinical characteristics of the cases are summarized in Table 1.

## Discussion

It is not unusual for the intussusception symptoms of paroxysmal abdominal cramps, palpable abdominal mass, and jelly-bloody to be seen in patients aged 3–18 months, whereas it is an extremely rare intestinal entity among premature infants. Intussusception in premature infants accounts for only 0.3% of all cases of intussusception.<sup>1</sup>

Signs and symptoms such as abdominal distension, feeding difficulties, bilious vomiting and positive blood test in stool, especially in preterm infants, usually suggest NEC, which has a high prevalence in this age group. Early diagnosis of intussusception is crucial for treatment and requires a high index of suspicion. The diagnosis of intussusception should be suspected, especially in patients who are otherwise in good general condition, clinically stable, without thrombocytopenia and who have negative inflammation indicators or are non-responsive to medical treatment.<sup>2</sup> Among the present patients, one of them was in good general condition but the other two were mechanically ventilated due to lung hypoplasia. All patients had normal thrombocyte count and a minimal rise in C-reactive protein.

Necrotizing enterocolitis usually occurs in the second to third week of life or can occur as late as 3 months of age in premature and low-birthweight infants.<sup>3</sup> Additionally, spontaneous intestinal perforation (SIP), which is a separate clinical entity from NEC, and results in focal perforation of the intestines, is commonly found in very/extremely low-birthweight infants and low gestational age patients such as the present patients 1 and 2.<sup>4,5</sup> In SIP, the perforation is typically found in the terminal ileum, and



**Fig. 1** Ileo-ileal intussusception (arrow).

**Table 1** Subject characteristics

	Patient 1	Patient 2	Patient 3
Gestation age (weeks)	25	29	31
Birthweight (g)	725	700	1800
Sex	F	F	M
Age at onset of signs (days)	11	8	15
Age at surgery (days)	11	8	18
Gastric residuals	Bilious	Bilious	Bilious
Abdominal distension	+	+	+
Bloody stool	–	–	+
Abdominal tenderness	+	+	+
Mechanical ventilation	+	+	–
Location of intussusception	Jejuno-ileal	Ileo-ileal	Ileo-ileal
Perforation	+	+	–
Platelets ( $\times 10^3/\mu\text{L}$ )	154	176	198
White blood cells ( $\times 10^3/\mu\text{L}$ )	18.07	16.49	14.05
Hemoglobin (g/dL)	10.5	9.6	12.7
Hematocrit (%)	29.4	27.2	34.8
Lead point	–	Meckel's diverticulum	–

the bowel proximal and distal to the perforation is found to be normal. In the present patients 1 and 2, as in SIP, the entire bowel seemed normal except for the invaginated and perforated site. Definitive diagnosis of SIP is usually made intraoperatively on direct visualization of perforation in otherwise healthy intestine. The diagnosis would have been SIP if invaginated intestine had not been seen in the present patients 1 and 2. Signs and symptoms in the present patients started on days 8, 11 and 15, respectively, which is suggestive of a diagnosis other than NEC. Unlike in NEC patients, SIP usually starts in the first to second week of life, as in the present cases. Prematurity is the only well-defined risk factor for SIP. Severe placental chorioamnionitis, mechanical ventilation, glucocorticoids or NSAIDs, are thought to be other risk factors of SIP.<sup>5,6</sup> The etiology of most intussusceptions, however, is unknown. There are some risk factors such as gastrointestinal tract infection or introduction of new food proteins that cause swelling in Peyer patches and lymphoid nodular hyperplasia in the terminal ileum, or the no longer available tetravalent rhesus-human reassortant rotavirus vaccine immunization. Correlation with a concurrent or prior upper respiratory tract infection or complication of Henoch–Schonlein purpura has also been noted.<sup>3</sup> A pathologic leading point such as enlarged mesenteric lymph node, Meckel's diverticulum, duplication cyst, or hamartoma is considered to play a role in 58% of all full-term infant intussusceptions, but the exact etiology of neonatal intussusception in premature infants is still unknown.<sup>2</sup> Neonatal intussusception occurring in the intrauterine period usually results in intestinal atresia.<sup>7</sup> Prematurity, low birthweight, mechanical ventilation, hypoxic and low perfusion state events affecting the intestinal system, which are also thought to be triggers for NEC, are risk factors for intussusception due to stricture formation and intestinal dysmotility. In the literature there are also concomitant cases of NEC and intussusception, which makes the diagnosis of this entity more complicated.<sup>8</sup> Dysmotility due to these strictures

may act as a trigger point for intussusception in preterm infants. We found only Meckel's diverticulum as a lead point in one of the present patients.

Due to the similar symptomatology and clinical features of neonatal intussusception and NEC, it is difficult to differentiate between the two entities in premature infants. Serial abdominal X-ray for following NEC patients is recommended due to the patients' general condition. Radiologic findings without portal venous gas, or pneumatosis intestinalis (reported to occur in >50% of all intussusception cases) and with air-fluid level in dilated bowel loops are signs of intussusception misdiagnosed as NEC. Dilated bowel loops have been noted as the most common radiologic finding of intussusception in premature infants.<sup>9,10</sup> It has been reported that the absence of certain risk factors or a clear distinction between NEC and intussusception in clinical and diagnostic characteristics, and the mimicking symptomatology, have resulted in delays of approximately 7 days in the diagnosis of intussusception in preterm infants. It is important to confirm the presence of intussusception before surgery, in order to reduce complications such as perforations, as in the present cases. It has also been reported that perforation of the intestines shortens the time to correct diagnosis of intussusception in premature infants.<sup>1</sup> Free air on plain abdominal X-ray showing an intestinal perforation is a strong indication for laparotomy. Two of the present patients underwent laparotomy on the same day that their signs and symptoms started. They were in poor general condition and mechanically ventilated. After detecting pneumoperitoneum on abdominal X-ray, urgent laparotomy was done and jejuno-ileal perforations were detected due to ileo-ileal and jejuno-ileal intussusception. In the third case, the patient was in good condition but he had feeding intolerance, bilious gastric residuals, moderate abdominal distension and bloody stool. He was misdiagnosed as having NEC until the diagnosis of intussusception was made during exploratory laparotomy at 16 days after clinical presentation.

Intussusception tends to occur in the ileo-colic region in childhood but in preterm infants it usually occurs in the ileo-ileal segments of the intestinal system, and does not involve colonic segments.<sup>1,6</sup> Contrast enemas used in upper gastrointestinal contrast studies for the diagnosis and treatment of intussusception in infants between 3 and 18 months of age are usually non-effective due to the difficulty of high-density contrast material passing through preterm infants' ileo-cecal valve. It has been postulated that it is better not to use contrast material for the diagnosis of intussusception because of the high perforation risk due to the already compromised bowel.<sup>8</sup> Although abdominal ultrasonography (USG) has been shown to be useful in diagnosis and also helpful in the treatment of intussusception in older children, there

is not sufficient data with regard to premature infant intussusception. Abdominal USG in the present cases showed no intestinal pathology. In the literature most of the diagnoses of intussusception in premature infants were usually made intraoperatively. Diagnoses in the present patients were also made intraoperatively. Two of the present patients had ileo-ileal intussusception and perforations in the ileal segments, and one had two intussusception segments without perforation. It has been reported that segmental resection and primary anastomosis of the bowel are commonly performed in premature intussusception, in contrast to full-term infant intussusception. Primary anastomosis can be safely performed without increasing morbidity and mortality, while also avoiding a second operation.<sup>9</sup> Resection and primary anastomosis were carried out without complications in all of the present patients.

Abdominal distension, gastric bilious residuals, and blood in stool, especially in premature infants, usually suggest NEC in NICU. Although intussusception is a rare entity in this age group, it should be suspected in patients without positive laboratory findings of inflammation or sepsis, and who are clinically stable.

## References

- 1 Wang NL, Yeh ML, Chang PY *et al*. Prenatal and neonatal intussusception. *Pediatr. Surg. Int.* 1998; **13**: 232–6.
- 2 Loukas I, Baltogiannis N, Plataras C, Skiathitou AV, Sihanidou S, Geroulanos G. Intussusception in a premature neonate: A rare often misdiagnosed cause of intestinal obstruction. *Case Rep. Med.* 2009; **2009**: 607989.
- 3 Kliegman MR, Behrman ER, Jenson BH, Stanton FB. *Nelson Textbook of Pediatrics*, 18th edn. Saunders, Philadelphia, PA, 2007.
- 4 Koshinaga T, Gotoh H, Sugito K, Ikeda T, Hagiwara N, Tomita R. Spontaneous localized intestinal perforation and intestinal dilatation in very-low-birthweight infants. *Acta Paediatr.* 2006; **95**: 1381–8.
- 5 Okuyama H, Kubota A, Oue T, Kuroda S, Ikegami R, Kamiyama M. A comparison of the clinical presentation and outcome of focal intestinal perforation and necrotizing enterocolitis in very-low-birth-weight neonates. *Pediatr. Surg. Int.* 2002; **18**: 704–6.
- 6 Kawase Y, Ishii T, Arai H, Uga N. Gastrointestinal perforation in very low-birthweight infants. *Pediatr. Int.* 2006; **48**: 599–603.
- 7 Todani T, Tabuchi K, Tanaka S. Intestinal atresia due to intrauterine intussusception: Analysis of 24 cases in Japan. *J. Pediatr. Surg.* 1975; **10**: 445–51.
- 8 Smith VS, Giacoia GP. Intussusception associated with necrotizing enterocolitis. *Clin. Pediatr. (Phila)* 1984; **23**: 43–5.
- 9 Avansino JR, Bjerke S, Hendrickson M, Stelzner M, Sawin R. Clinical features and treatment outcome of intussusception in premature neonates. *J. Pediatr. Surg.* 2003; **38**: 1818–21.
- 10 Görden-Pauly U, Schultz C, Kohl M, Sigge W, Möller J, Gortner L. Intussusception in preterm infants: Case report and literature review. *Eur. J. Pediatr.* 1999; **158**: 830–32.