



Unusual complication of a urinary stone in a child: spontaneous rupture of the renal pelvis with the migration of calculus into the retroperitoneum

Hakan Taşkınlar, Doğan Yigit, Dinçer Avlan, Ali Naycı

ABSTRACT

Spontaneous perforation of the renal pelvis and extravasation of urine into the perinephric space is an extremely rare condition in childhood. It is mostly related to underlying congenital urinary tract abnormalities and caused by urolithiasis or infection in the setting of urinary obstruction. Here, we report a case of an 18-month-old female patient with rupture of the renal pelvis by an extruded kidney stone and its management.

Keywords: Children; perforation; renal pelvis; urinoma; urolithiasis

Introduction

Calculus located in the urinary system that leads to spontaneous rupture of the renal pelvis is an extremely rare complication of urinary stone disease.^[1] Although a case series of spontaneous ureteral ruptures caused by ureterolithiasis in adults have been reported; there is no case of spontaneous perforation of the renal pelvis by a calculus in childhood.^[2] Here, we report renal pelvis rupture and perirenal urinoma caused by a calculus and its management with a review of the literature.

Case presentation

An 18-month-old previously healthy female patient presented to a primary health center with the complaints of fever, vomiting, and abdominal pain. She was referred to the pediatric oncology department with an initial diagnosis of retroperitoneal tumor after revealing a complex lobulated cystic mass of 153 × 31 mm pushing the left kidney forward on the left retroperitoneal side on performing abdominopelvic ultrasonography. On conducting a physical examination, the patient was pale, faint, had mild dehydration and abdominal tenderness on the left flank region. Her fever was 38.6°C, heart rate was 145/min, and respiratory rate was 32/min. She had no known medical or family history of urinary or metabolic disease. Based on the initial labora-

tory findings, she was anemic (Hgb 7.3 g/dL; Hct 22.9%) had leukocytosis (33.470 per mcL) and elevated CRP and procalcitonin (286.1 mg/L and 73.81 ng/mL, respectively) levels. Her BUN level was 76.17 mg/dL, creatinine level was 1.83 mg/dL, sodium level was 129.08 mEq/L, potassium level was 4.94 mEq/L, and albumin level was 2.44 g/dL. Urinalysis revealed leukocyturia, hematuria, and bacteriuria. Antibiotics were initiated and urine cultures were obtained. She was referred to our department after a contrast-enhanced abdominopelvic computed tomography (CT) scan showed a complex cystic mass of 6 × 4.5 cm and contrast extravasation from the collector system into the mass, with a 10 mm stone formation inside the mass (Figure 1). Perirenal urinoma was the diagnosis, and an ultrasound-guided drainage catheter was initially placed into the urinoma. Plain roentgenogram showed the drainage catheter and a radio-opacity consistent with the presence of urinary stone (Figure 2). To achieve a better drainage and to aid better healing of the collecting system, we intended to place a double-J (JJ) stent into the renal pelvis via cystoscopy. However, we were not able to place a JJ catheter because of the wide perforation site in the renal pelvis that caused the catheter to move directly outside the kidney. The drainage catheter that was initially placed in the urinoma was kept for 4 weeks until urine drainage stopped. Plain roentgenogram

Department of Pediatric Surgery,
Mersin University School of
Medicine, Mersin, Turkey

Submitted:
07.02.2015

Accepted:
05.05.2015

Correspondence:
Hakan Taşkınlar
E-mail:
hakantaskinlar@gmail.com

©Copyright 2016 by Turkish
Association of Urology

Available online at
www.turkishjournalofurology.com

and repeated control ultrasonographies revealed a normal left kidney with no perirenal urinoma and an absence of the stone (Figure 3). Drainage catheter was removed, and the patient had no other complaints during her follow-up.

Discussion

Spontaneous rupture of the urinary collecting system is a rare condition usually associated with predisposing factors, such as infection, malignancy, urolithiasis, or interventional procedures, leading to urinary tract obstruction in adults.^[3] This phenomenon in childhood is extremely rare and usually occurs in the presence of congenital anomalies such as obstruction of posterior urethral valves and ureterovesical and ureteropelvic junctions. The excessive increase in the intraluminal pressure in the urinary tract results in a forniceal rupture, which is the weakest part of the collecting system. Rupture of fornices leads to perinephric collection of urine.^[4,5] To the best of our knowledge, spontaneous perforation of the renal pelvis caused by a calculus in children has not been reported in the literature. In the present case, our patient had a spontaneous rupture of the renal pelvis, extrusion of the calculus, and perirenal urinoma. The pelvic wall may have become thinner, fragile, and partially hypoxic because of nephrolithiasis and chronic hydronephrosis. Acute or intermittent changes in the renal pelvic pressure, such as coughing, sneezing, and vomiting, may induce the rupture of renal pelvis and an extrusion of the calculus.

Ultrasonography, intravenous urography, and contrast-enhanced abdominal (CT) are not only helpful in the diagnosis of leaks in the collecting system but also help in the cause and extent of the pathology. Although ultrasonography shows cystic masses perirenal urinoma, hydronephrosis, or obstruction site, it is less sensitive to identify small urinary stones, particularly those located outside the renal parenchyma. However, plain radiographs are helpful to identify radiopaque stones (Figure 3). The most useful imaging study to identify cystic or solid masses with calcifications is abdominal CT. Additionally, delayed images usually show extravasation of the contrast medium and provides information regarding the perforation site.^[6,7] In the present study, we confirmed not only the contrast medium extravasation but also showed extruded calculus in the perirenal space by contrast-enhanced CT study. To avoid unnecessary exposure to radiation to a growing female child, we only followed the patient with plain roentgenogram and ultrasound studies; hence, we did not perform a second CT after no calculus was revealed in plain X-ray and ultrasonographic images.

Treatment of the urinary extravasation depends on the etiology and should be individualized in each case. Placement of a ureteral stent that splints the ruptured area may be used for initial treatment.

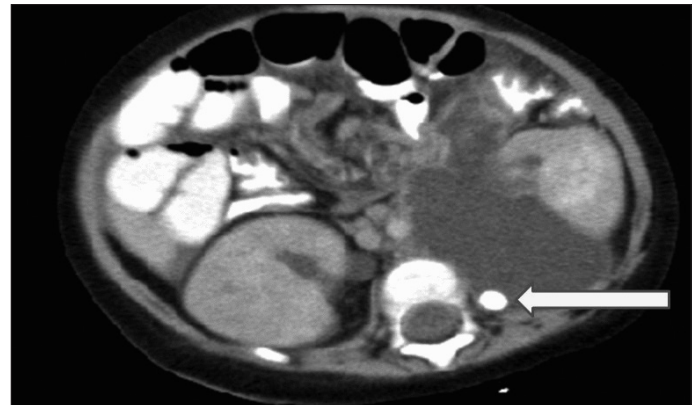

Figure 1. [Contrast-enhanced CT]. Arrow show left perirenal urinoma and an extruded calculus in the urinoma

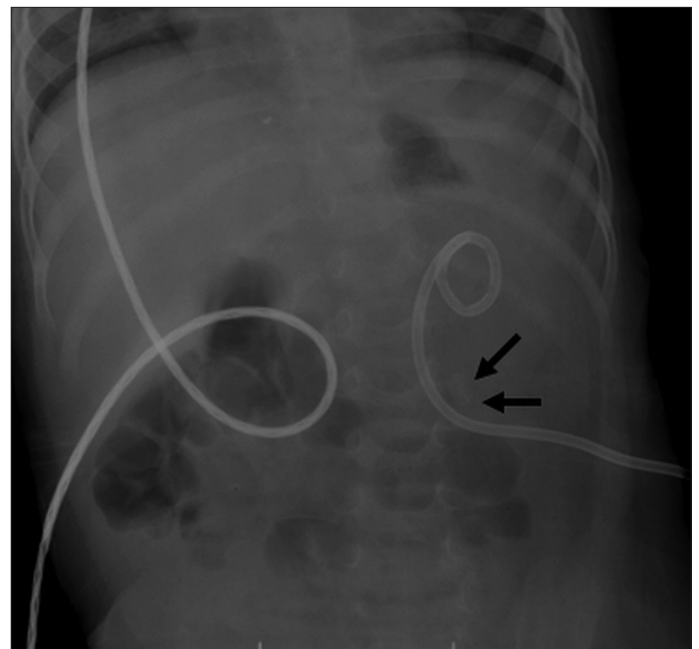


Figure 2. [Plain roentgenogram]. Arrow shows radio-opacity consistent with the presence of urinary stone

However, ureteral stenting may be inadequate for the drainage of perirenal urinoma. According to the guidelines of the American College of Radiology, percutaneous drainage of the pelvicalyceal system not only provides a better drainage than a JJ stent alone but also helps to heal the pelvicalyceal perforation.^[8] Under the guidance of ultrasonography or CT, a urinoma drainage catheter may also be placed into the urinoma. Drainage of the urinoma improves renal healing and helps in the preservation of renal functions.

Placement of only a nephrostomy catheter may not be enough, and combined placement of a nephrostomy catheter and a ureteral stent catheter is warranted in some persistent leakages of the collecting systems of the urinary tract. Additional use of a

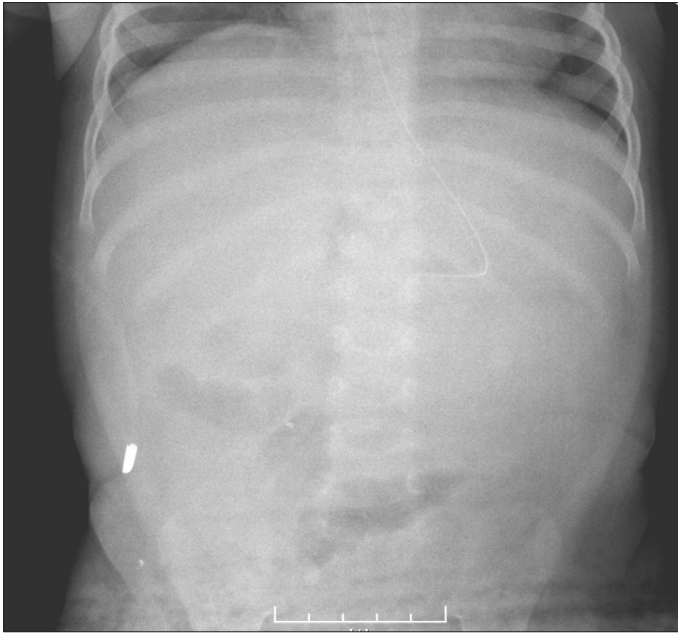


Figure 3. [Plain roentgenogram]. Absence of radio-opacity after the removal of drainage catheter

nephrostomy catheter or a ureteral stent with a percutaneous drainage catheter improves the diversion of the urine from the ruptured area and accelerates healing of the injured collecting system.^[7] In our case, we initially placed an ultrasound-guided drainage catheter into the urinoma; then, the placement of a JJ stent was attempted but was unsuccessful. The catheter was kept for 4 weeks until the urine output stopped by the end of this 4-week period. Surprisingly, extruded stone in the perirenal space had disappeared. The patient was also followed up by the pediatric nephrology department for the presence of any metabolic disorders; however, no metabolic disorder was detected.

This study shows the first case of a patient with spontaneous pelvic rupture by nephrolithiasis and an extrusion of the calculus in childhood. Conservative treatment with the drainage of the perirenal urinoma using a percutaneous catheter is generally satisfactory.

Informed Consent: Written informed consent was obtained from the patients.

Peer-review: Externally peer-reviewed.

Author Contributions: Concept - H.T., D.A.; Design - H.T.; Supervision - D.A., A.N.; Funding - H.T.; Materials - D.Y.; Data Collection and/or Processing - H.T., D.Y.; Analysis and/or Interpretation - H.T., D.A.; Literature Review - H.T., D.Y.; Writer - H.T.; Critical Review - D.A., A.N.

Conflict of Interest: The authors declared no conflict of interest.

Financial Disclosure: The authors declared that this study has received no financial support.

References

1. Diaz ES, Buenrostro FG. Renal pelvis spontaneous rupture secondary to ureteral lithiasis. Case report and bibliographic review. *Arch Esp Urol* 2011;64:640-2.
2. Leuthard R, Bernhardt E, Gasser T, Kummer M. Spontaneous perforation of the ureter: a rare complication of urolithiasis. *Eur J Pediatr Surg* 1994;4:205-6. [\[CrossRef\]](#)
3. Gershman B, Kulkarni N, Savani DV, Eisner BH. Causes of renal forniceal rupture. *BJU Int* 2011;108:1909-12. [\[CrossRef\]](#)
4. Tseng PC, Liu TY, Pan SJ, Sung DS. Spontaneous perirenal urinoma associated with ureteropelvic junction obstruction in a child: a case report. *Pediatr Neonatol* 2009;50:121-4. [\[CrossRef\]](#)
5. Ahmed S, Borghol M, Hugosson C. Urinoma and urinary ascites secondary to calyceal perforation in neonatal posterior urethral valves. *Br J Urol* 1997;79:991-2. [\[CrossRef\]](#)
6. Gayer G, Zissin, R, Apter S, Garniek A, Ramon J, Kots E, Hertz M. Urinomas caused by ureteral injuries: CT appearance. *Abdom Imaging* 2002;27:88-93. [\[CrossRef\]](#)
7. Titton RL, Gervais DA, Hahn PF, Harisinghani MG, Arellano RS, Mueller PR. Urine leaks and urinoma: diagnosis and imaging-guided intervention. *Radiographics* 2003;23:1133-47. [\[CrossRef\]](#)
8. Kolbeck KJ, Ray CE Jr, Lorenz JM, Assimos DG, Burke CT, Darcy MD, et al. Expert Panel on Interventional Radiology. ACR Appropriateness Criteria® radiologic management of urinary tract obstruction. [online publication]. Reston (VA): American College of Radiology (ACR), 2013.