


Triplanar 1st MTP Arthrodesis

Key Steps and Fluoro Checks



For use with Lapiplasty® Anatomic Biplanar™ Plating

Triplanar 1st MTP Arthrodesis

An instrumented approach to triplanar correction of the 1st MTP joint with sterile-packed Lapiplasty® Biplanar™ Plating

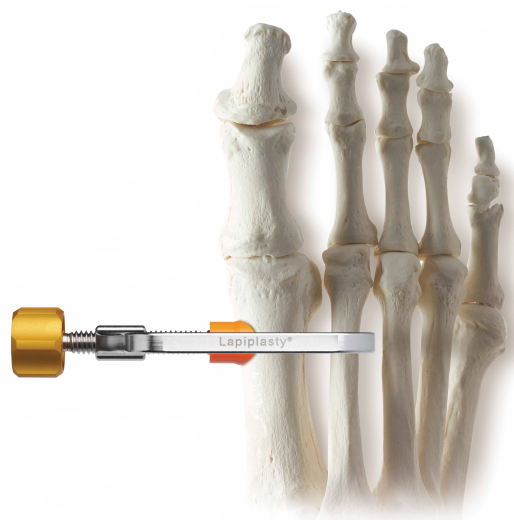Instrumented Prep

The **Lapiplasty® MTP Reamers** are designed for efficient preparation of conforming cup-cone joint surfaces, providing the ability to easily adjust hallux alignment in all 3 planes.



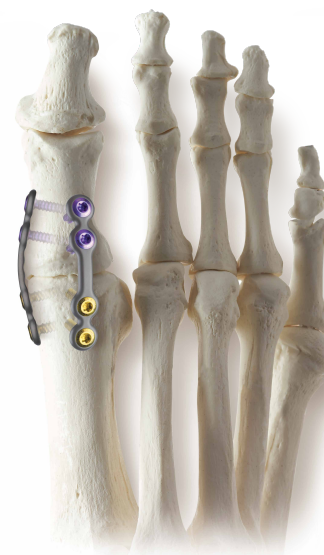Triplanar Correction

The **Lapiplasty® Positioner** allows you to dial-in and hold the metatarsal and sesamoids in anatomic position while you set the triplanar 1st MTP joint alignment.



Multiplanar Fixation

Low profile **Lapiplasty® Biplanar™ Plating** designed to provide multiplanar stability with standard-sized locking screws to eliminate intra-op measuring.



Key Steps: Triplanar 1st MTP Arthrodesis

With Lapiplasty® Anatomic Biplanar™ Plating

Surgical Approach

Perform a dorsal longitudinal incision medial to the extensor hallucis longus (EHL) tendon, beginning just proximal to the interphalangeal joint and extending 2-3cm proximal to the 1st metatarso-phalangeal (MTP) joint (**Fig. 1**).

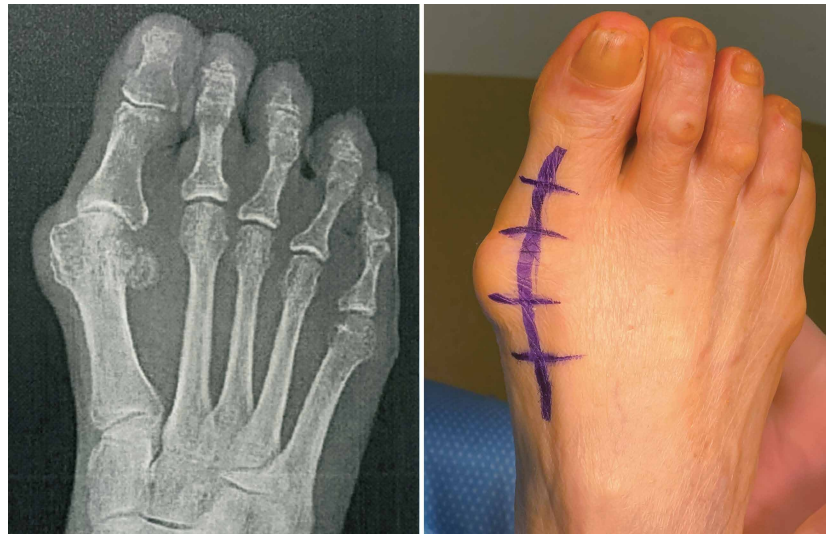


Figure 1

Use a curved McGlamry elevator or other similar instrument to perform a complete release of the sesamoid complex to allow relocation of the sesamoids under the 1st metatarsal head. (**Fig. 2**).

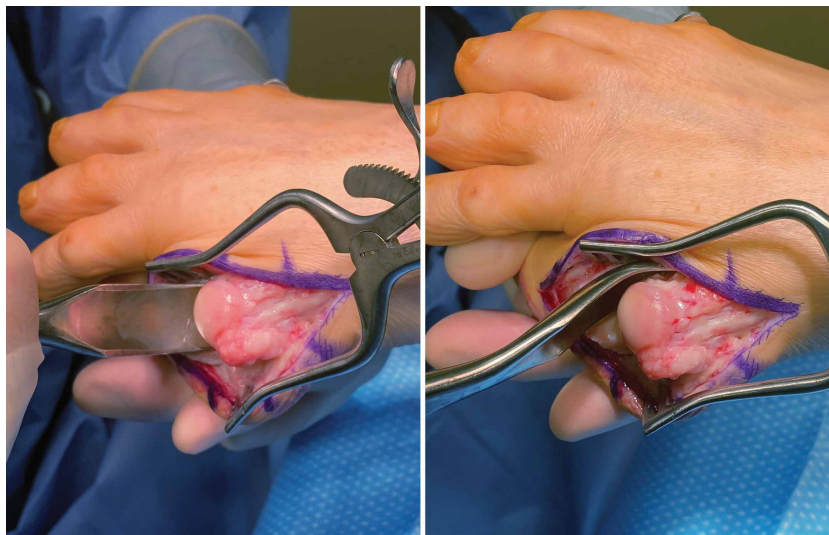


Figure 2

1st MTP Joint Preparation

A cup and cone reaming system (or other methods of cartilage resection such as saw cuts, rongeurs, etc) is utilized to denude the 1st MTP joint of any remaining cartilage and sub-chondral bone.

Insert a 1.6mm K-wire into the central aspect of the metatarsal head. Attach the appropriate size concave Metatarsal Reamer onto an AO adapter on a powered driver (**Fig. 3**). Place the Metatarsal Reamer over the 1.6mm K-wire and ream in a pulsing motion until bleeding bone is present.

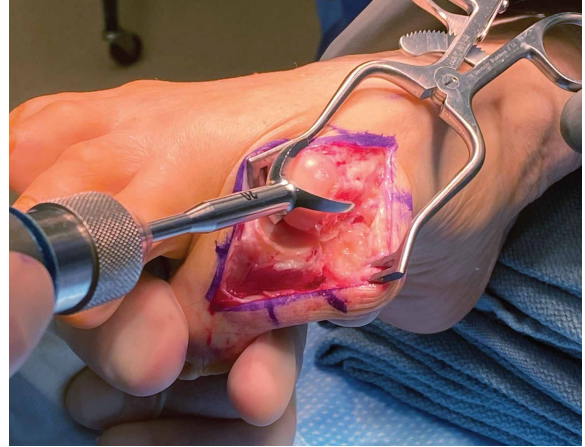


Figure 3

Plantarflex the great toe to expose the phalangeal articular surface and repeat the above steps on the phalanx with the Phalangeal Reamer. A curved McGlamry or Hohman retractor (not provided) can be helpful for exposure and protecting the metatarsal during reaming (**Fig 4**).

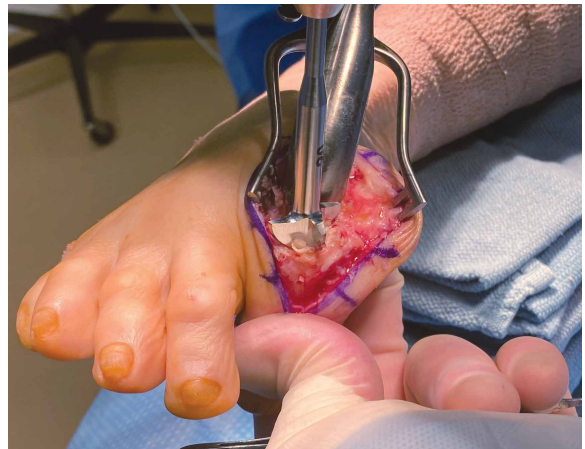


Figure 4

Remove any excess cartilage or bony fragments with a rongeur or other preferred method. Use a 2.0mm Fluted Drill to aggressively fenestrate the metatarsal and phalangeal joint surfaces (**Fig. 5**).

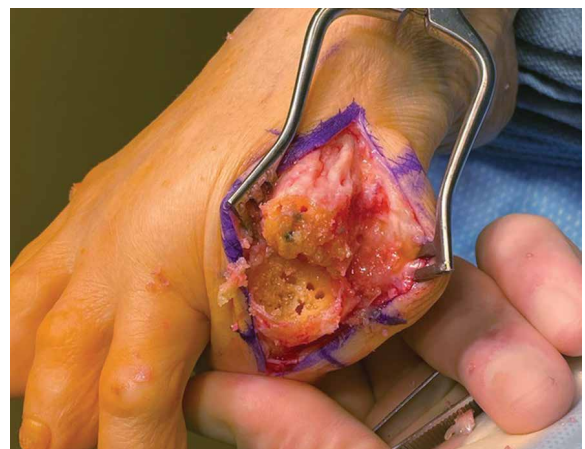


Figure 5

Triplanar Correction

For provisional fixation, drive a 1.6mm K-wire antegrade from the proximal phalanx out the distal end of the toe. The Lapiplasty® Positioner can be utilized to perform a triplanar correction of the 1st metatarsal alignment (transverse and frontal plane correction, while maintaining sagittal plane declination). Apply the Positioner to two-finger tightness to reduce the deformity, proceeding cautiously to avoid overcorrection, and confirm the alignment on fluoroscopy (**Fig. 6**).

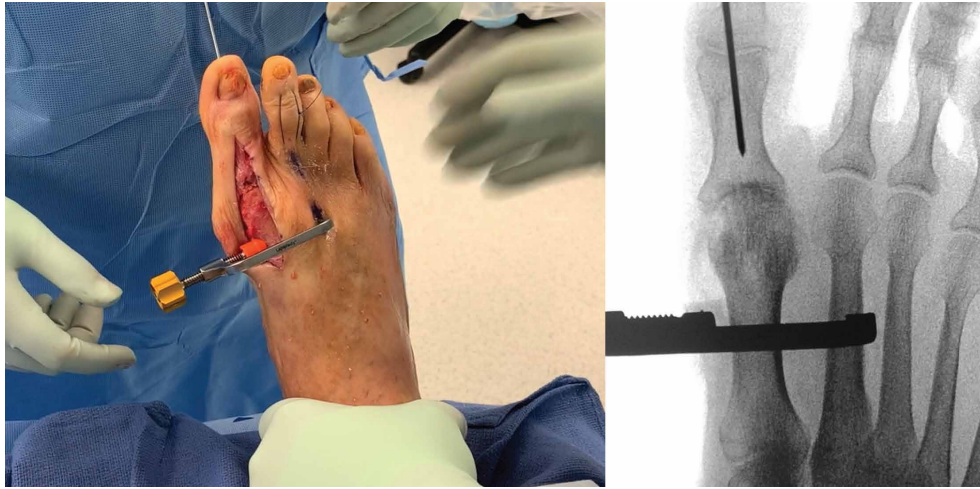


Figure 6

Manually position the hallux in the desired sagittal and transverse plane alignment, then advance the K-wire retrograde into the 1st metatarsal to secure the alignment in place (**Fig 7**). Remove the Positioner and confirm the alignment on fluoroscopy.

Note: The axial provisional fixation K-wire allows for manual compression of the prepared 1st MTP joint surfaces and adjustment of the frontal-plane rotational alignment of the hallux. The Lapiplasty® Compressor may optionally be used at this step to compress the 1st MTP joint and maintain the reduction.

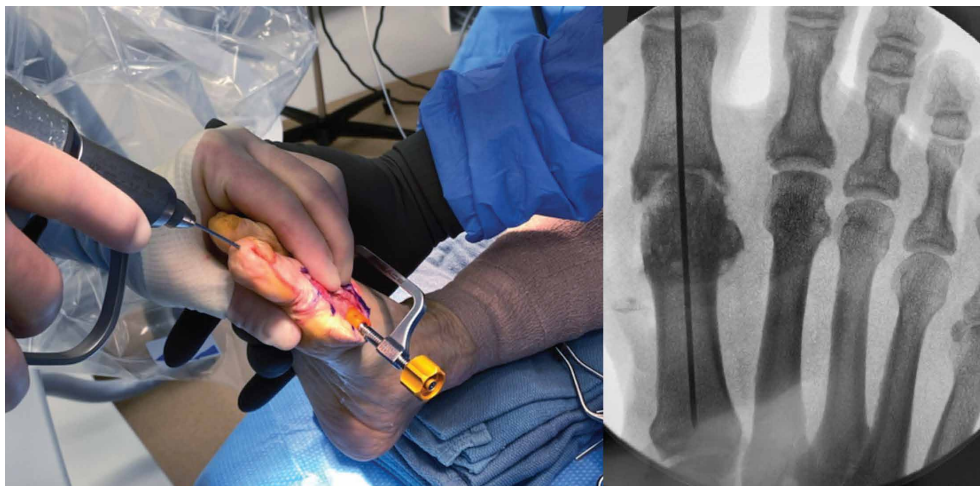


Figure 7

Provisional Fixation

Utilize a firm, flat plate to assess the sagittal plane alignment of the hallux, confirming that the plantar head of the proximal phalanx is positioned just off the weight-bearing surface (or at your preferred position) (**Fig. 8**).

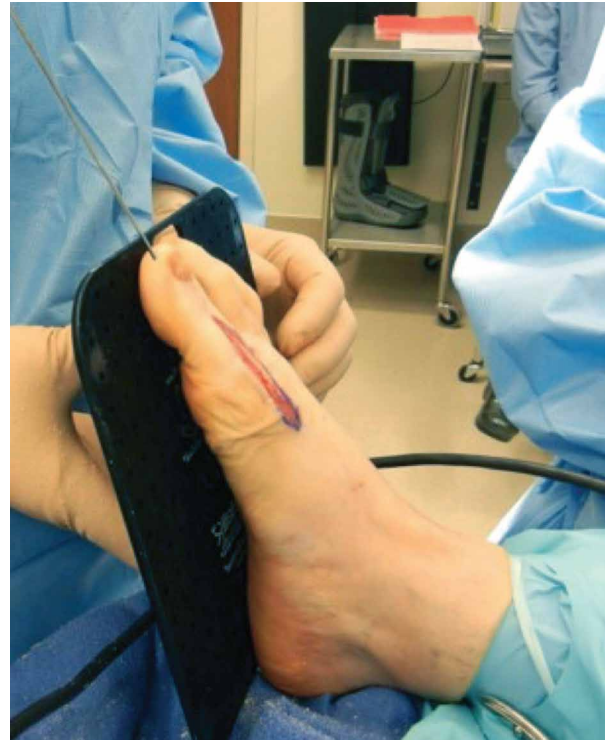


Figure 8

Manually de-rotate the hallux into slight supination in the frontal plane and axially compress the 1st MTP joint. A 2.0mm Threaded Olive Wire (or optionally a 1.6mm K-wire) can be inserted from the dorsomedial base of the proximal phalanx across the 1st MTP joint as a second point of fixation to pre-compress the joint and secure the frontal plane alignment (**Fig. 9**).

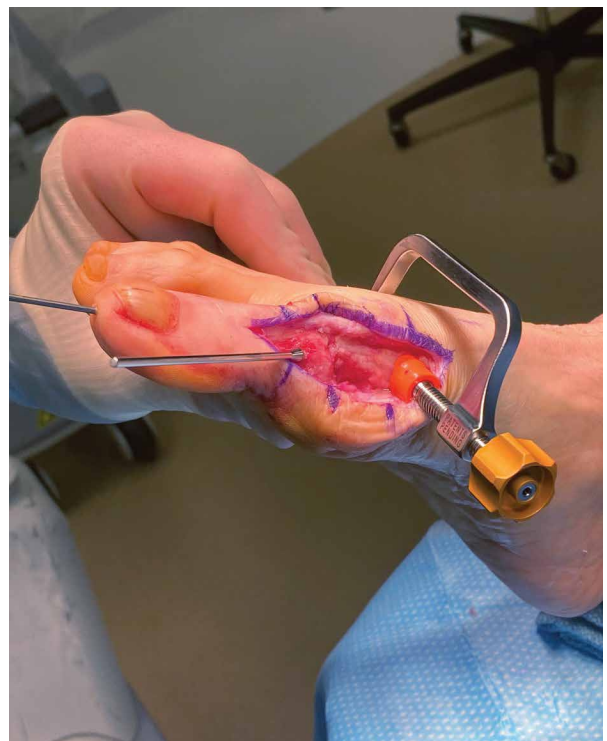


Figure 9

Lapiplasty® Biplanar™ Plating

Select a 4-hole Lapiplasty® Biplanar™ Plate and assess the contour of the plate relative to the 1st MTP joint anatomy. Adjust the plate contour prior to fixating the plate to the bone (**Fig. 10**).

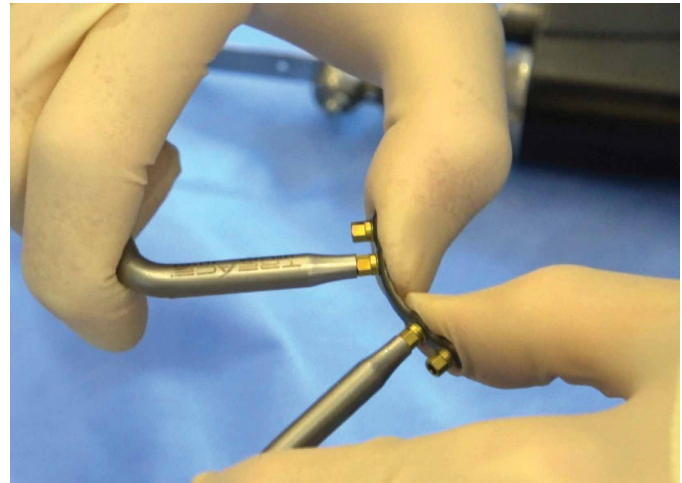


Figure 10

Apply the plate to the dorsolateral bone surface in such a way that the mid-section of the plate spans the arthrodesis site, ensuring that there is adequate room for two screws to be placed on either side of the joint. (**Fig. 11**).

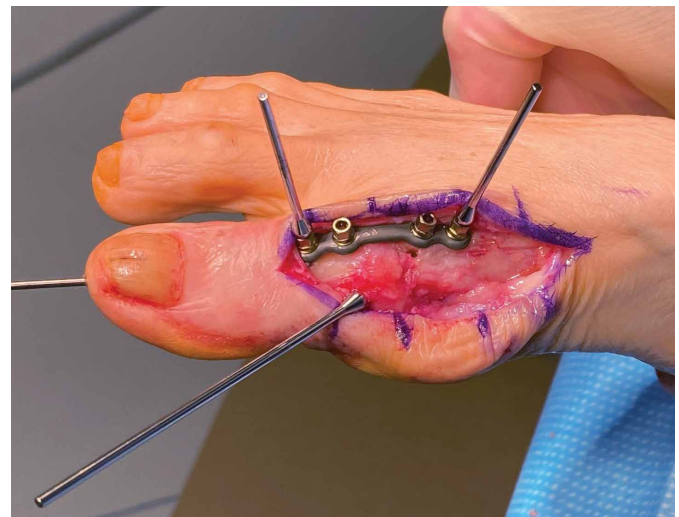


Figure 11

Lapiplasty® Biplanar™ Plating (cont.)

Utilize a rongeur or power saw to remove any irregularities and reshape the medial aspect of the 1st MTP joint to prepare for application of a second plate (**Fig. 12**).

Select a second 4-hole Lapiplasty® Biplanar™ Plate and place it medially across the 1st MTP joint, approximately at a 90° angle or greater relative to the dorsolateral plate (**Fig 13**).

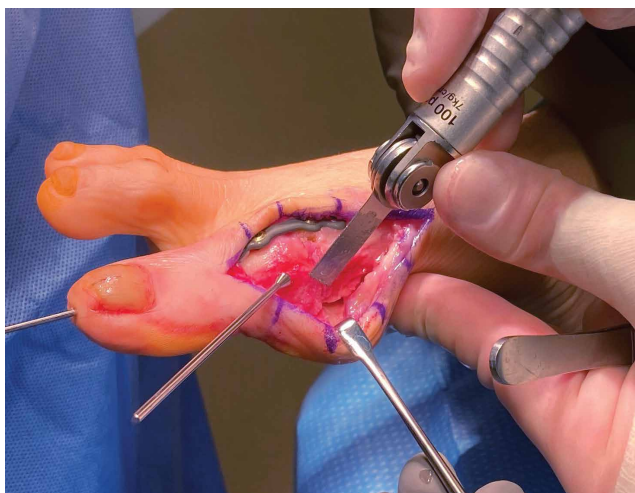


Figure 12

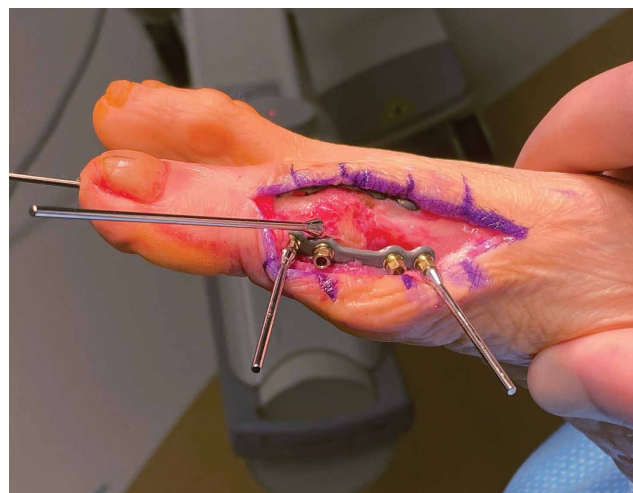

Figure 13

Remove the 1.6mm K-wire(s) or 2.0mm Threaded Olive Wires used for provisional fixation. Check the final clinical alignment (**Fig. 14**) and use fluoroscopy to confirm the final correction (**Fig. 15**).

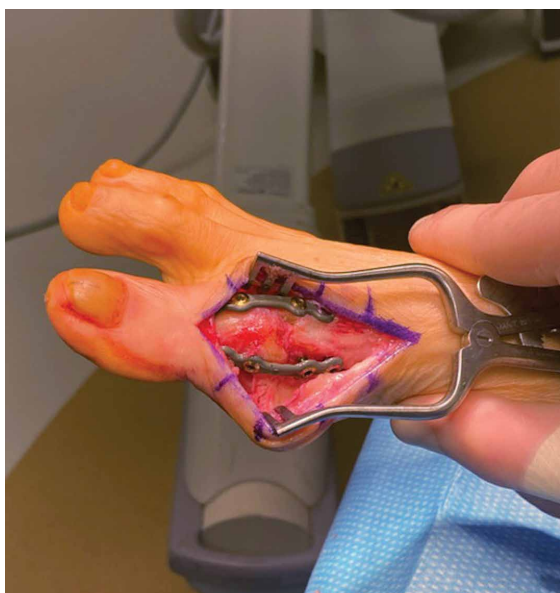


Figure 14

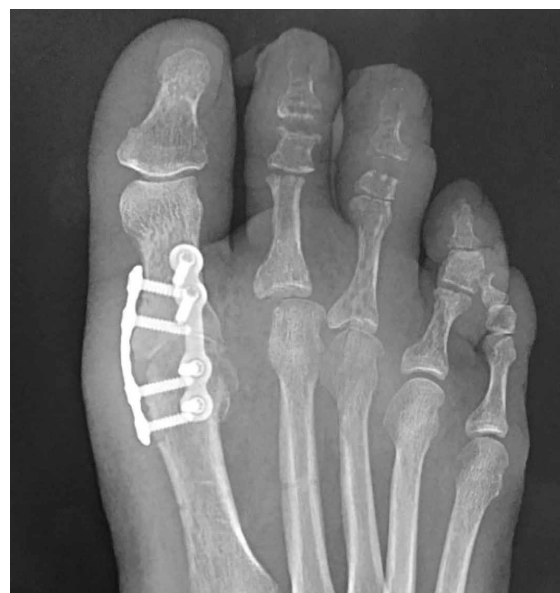

Figure 15

See surgical technique (LBL 1405-9001) and instructions for use (LBL 1405-9005) on www.treace.com for complete indications, contraindications, warnings, and precautions.

The Leader in Hallux Valgus Surgery™

TREACE[®]
Medical Concepts, Inc.

203 Fort Wade Rd. | Suite 150 | Ponte Vedra, FL 32081 | 904.373.5940 | www.treace.com
Pat. www.treace.com/patents ©2020 Treace Medical Concepts, Inc. All Rights Reserved.

LBL 1405-9157A 2/20