

# LATERAL ANKLE STABILIZATION

## A SURGICAL TECHNIQUE GUIDE



DYNAMIC REINFORCEMENT  
Featuring the FLEXBAND® SOLO and MULTI Systems





## WHAT IS INCLUDED

# FLEXBAND<sup>®</sup> SOLO

FROM ARTELON

Tissue Protector

4.25mm Cannulated  
Drill Bit


**FLEXBAND ANCHOR with Driver #1**

3.85mm FLEXBAND Anchor  
pre-loaded with 0.5 x 8cm  
FLEXBAND Matrix

**FLEXBAND ANCHOR with Driver #2**

3.85mm FLEXBAND Anchor  
with suture loop

Guidewire (x2)

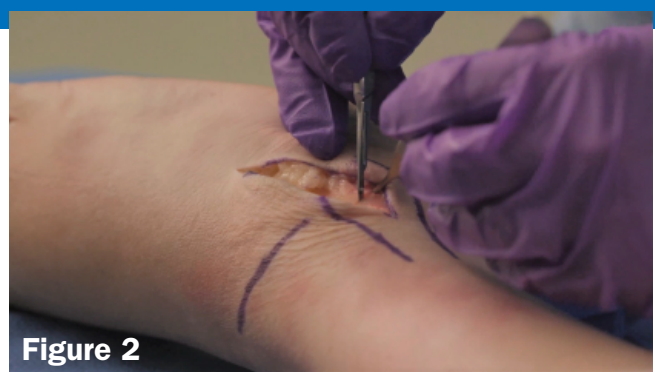



APPROACH

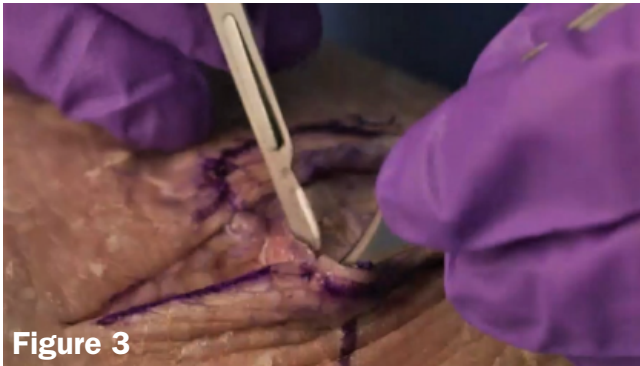

**Figure 1**



**Figure 2**

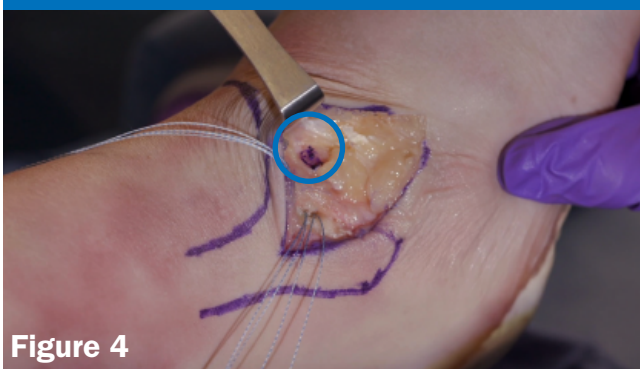
Compared to a traditional Broström, the incision for the FLEXBAND™ Solo System should be extended by 1cm both proximally and distally. Curving the distal incision anteriorly is helpful to gain greater exposure to the talus (**Figure 1**). Once the ankle capsule is exposed, an incision down to bone is made across the fibula that begins 1 to 1.5cm proximal to the tip of the talus (**Figure 2**).



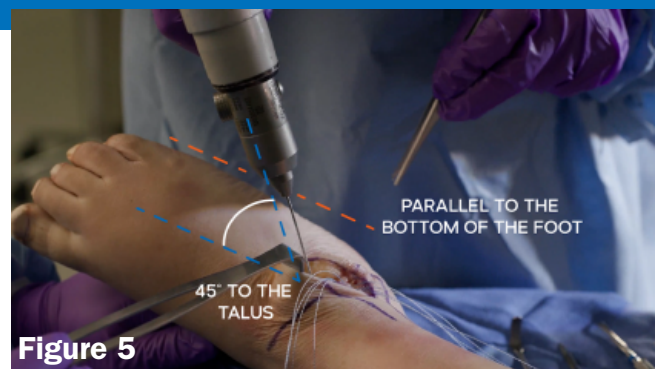
**Figure 3**

The fibular periosteum is peeled distally and dissection is continued underneath the ATFL to fully release the ligament. The incision is then extended anterior following the distal profile of the fibula, creating an ankle arthrotomy and exposing the lateral portion of the talus (**Figure 3**). This provides a fully mobilized ATFL segment.

TALAR PREPARATION

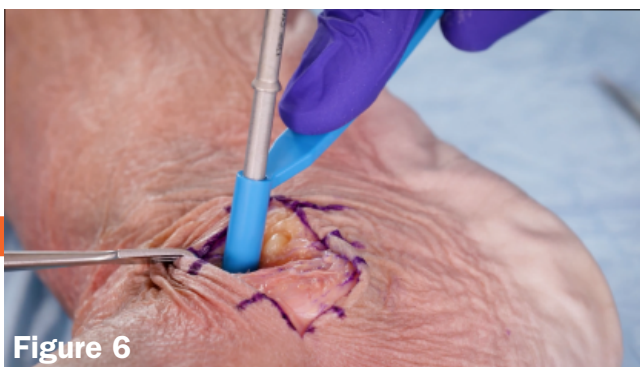

**Figure 4**

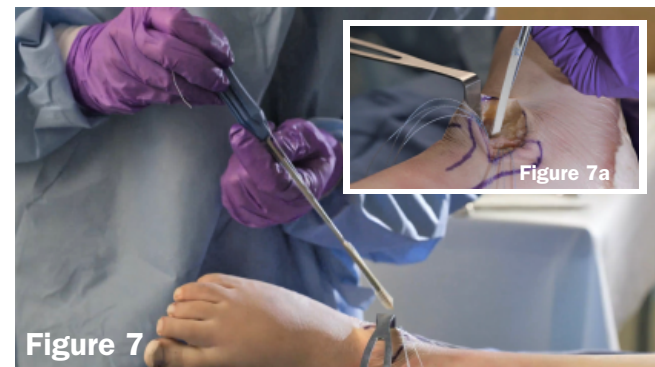

**Figure 5**

Just anterior to the fibula, you can palpate a defined ledge with a corresponding 1 x 1 cm flat area of bone with no cartilage. This is where the ATFL inserts, and is the target zone for placement of the first FLEXBAND ANCHOR (**Figure 4**). Place the provided guidewire in the center of the ATFL target zone. The guidewire should be driven in parallel with the bottom of the foot, and 45° to the talus. (**Figure 5**).



**Figure 6**



**Figure 7**

The 4.25 mm cannulated drill bit and tissue protector are slid over the guidewire and drilled until reaching the positive stop (**Figure 6**). Next, the FLEXBAND ANCHOR with pre-loaded with a 0.5 x 8 cm FLEXBAND is oriented in the same plane as the guidewire (**Figure 7**), turned to ensure the long leg of the FLEXBAND is facing the fibula (**Figure 7a**), and placed into the talus.

## ATFL RECONSTRUCTION

### TALAR PREPARATION

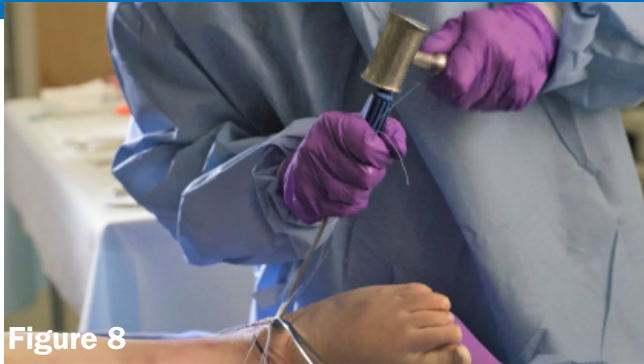

Figure 8

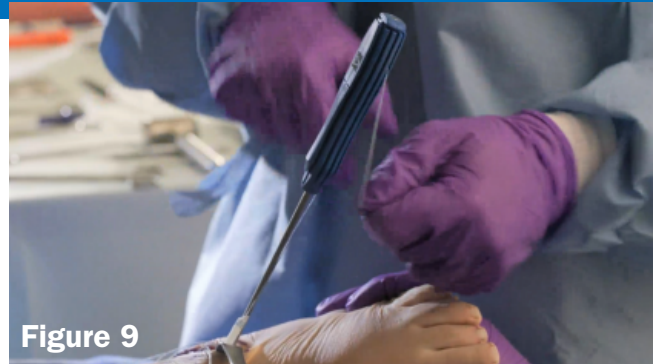

Figure 9

Once in the correct position, the FLEXBAND ANCHOR is impacted into place (**Figure 8**). After the FLEXBAND ANCHOR is seated, the suture tails are unwound from the impactor, and the driver is removed (**Figure 9**).

**NOTE: FLEXBAND Anchors are intended for impaction placement only, not screw placement.**

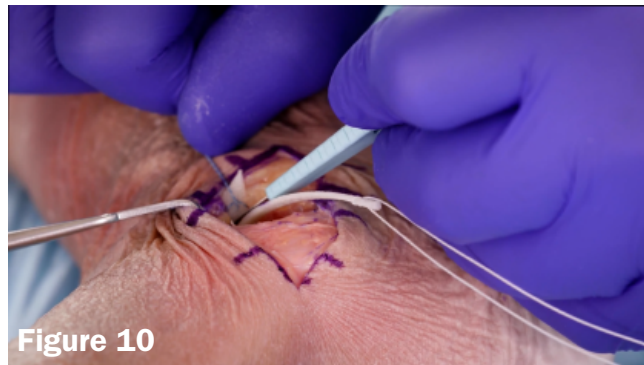

Figure 10

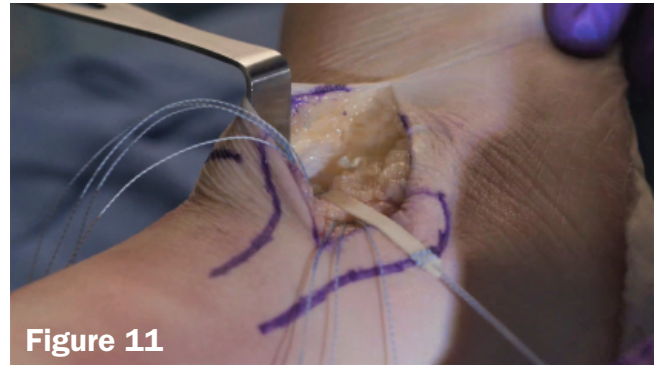


Figure 11

The remaining short leg of FLEXBAND is trimmed flush (**Figure 10**), and the talar insertion is complete (**Figure 11**).

### FIBULAR PREPARATION

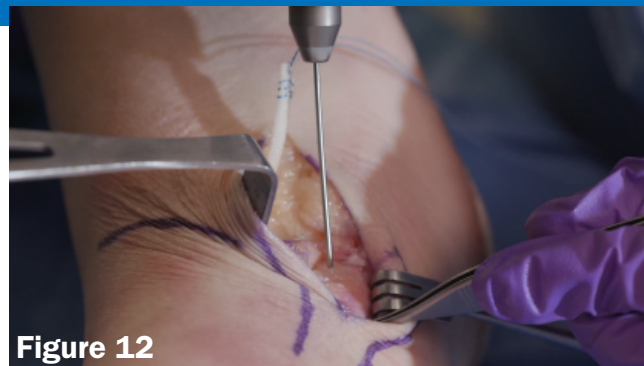

Figure 12

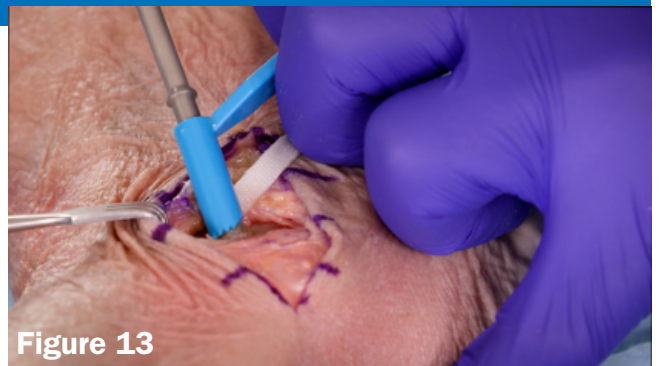

Figure 13

Turning attention to the fibula, a guidewire is placed anterolaterally and driven posteriorly toward the retrofibular groove (**Figure 12**). The 4.25mm cannulated drill with tissue protector are placed over the guidewire and drilled until it reaches the positive stop (**Figure 13**). Drill guide, drill bit, and guide wire are all removed.

**This is typically the time to place your suture anchors of choice into the fibula for the Broström procedure (not shown).**

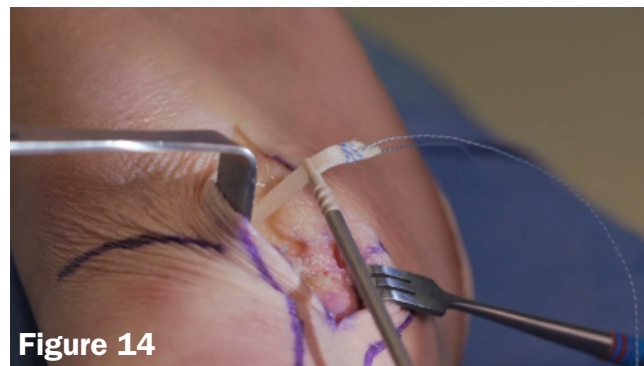

Figure 14

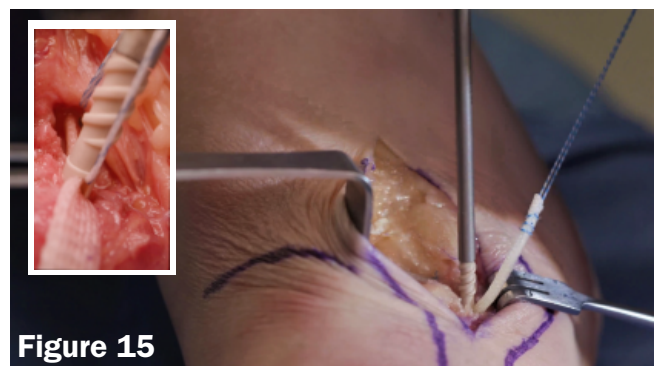


Figure 15

The long tail of the FLEXBAND is now threaded through the aperture of the FLEXBAND ANCHOR in preparation of placement into the fibula (**Figure 14**). The ANCHOR is then placed over the fibular hole and the FLEXBAND is held taut while the tip of the anchor is pushed firmly inside the drill hole, locking the FLEXBAND position (**Figure 15**).

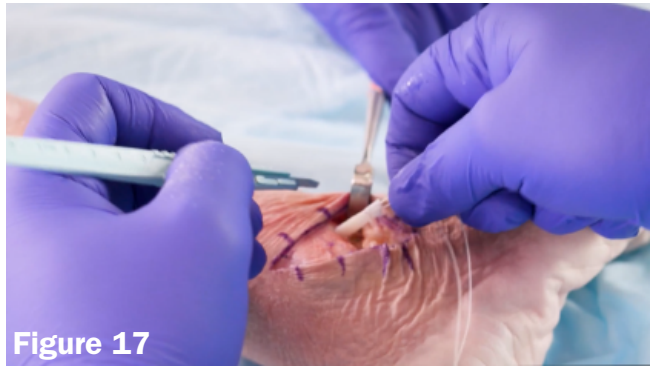
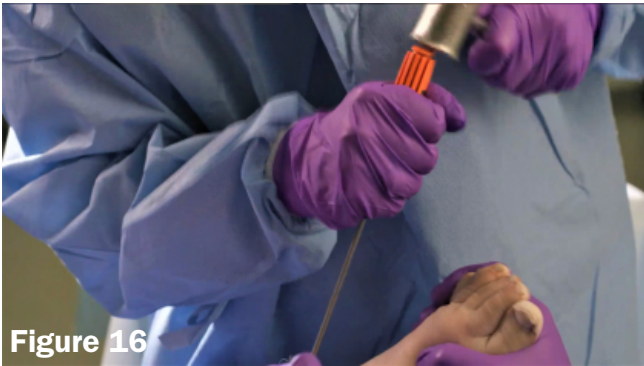
Figure 16

Figure 17

The FLEXBAND ANCHOR will auto-tension the FLEXBAND as it is impacted into place (**Figure 16**). Once the anchor is fully seated, the impactor can be removed, and the excess FLEXBAND is trimmed flush to the bone (**Figure 17**).

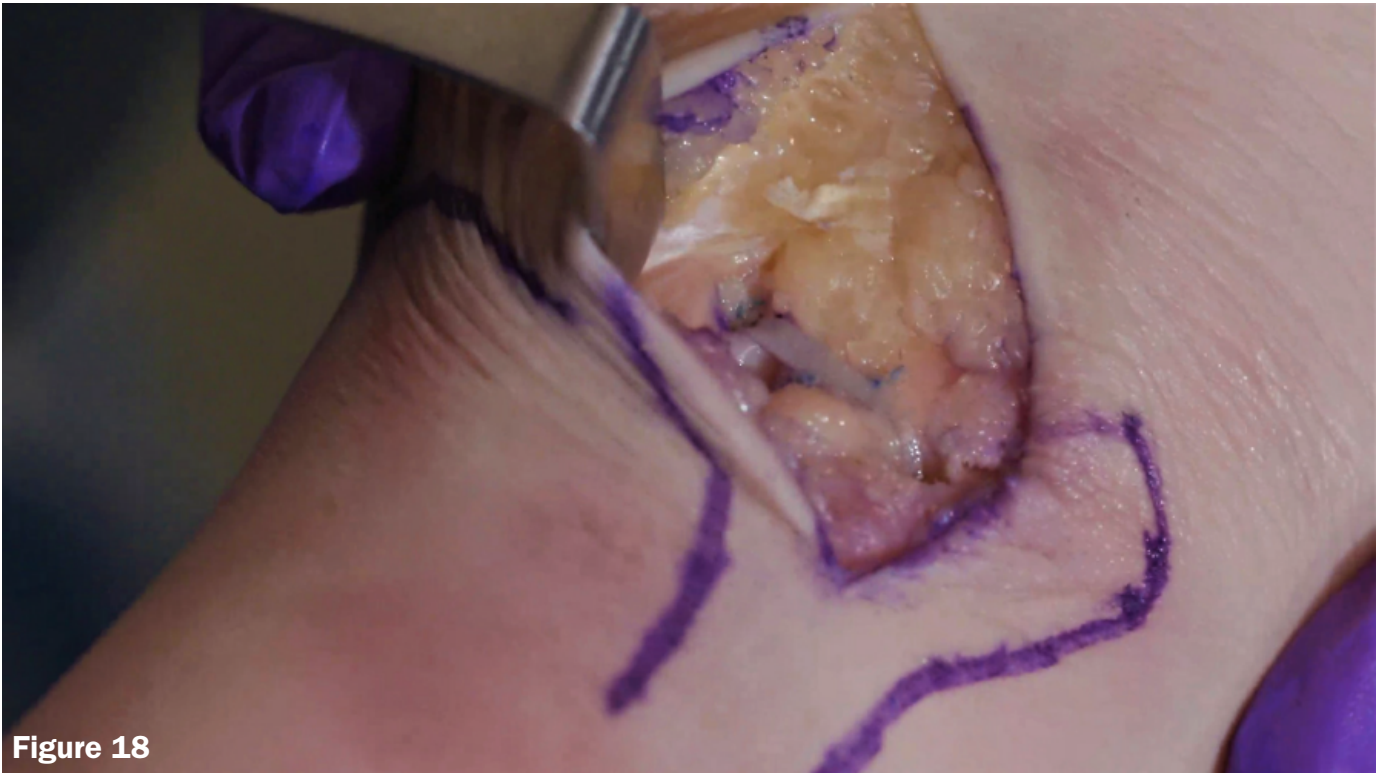

Figure 18

With the FLEXBAND Solo Reinforcement finished (**Figure 18**), the Broström procedure is completed, and the surgeon can move to final closure.

IMPLANTS USED



FLEXBAND<sup>®</sup> SOLO  
FROM ARTELON  
 P/N 71016





## WHAT IS INCLUDED

# FLEXBAND® MULTI

FROM ARTELON

Passing Wire

Drill Guide for  
4.25mm Drill Bit


4.25mm Cannulated  
Drill Bit

**FLEXBAND ANCHOR with Driver #1**  
3.85mm FLEXBAND Anchor  
pre-loaded with 0.5 x 24cm  
FLEXBAND Matrix and size 0  
poly-braid suture

**FLEXBAND ANCHOR with Driver #2**  
3.85mm FLEXBAND Anchor  
and suture loop

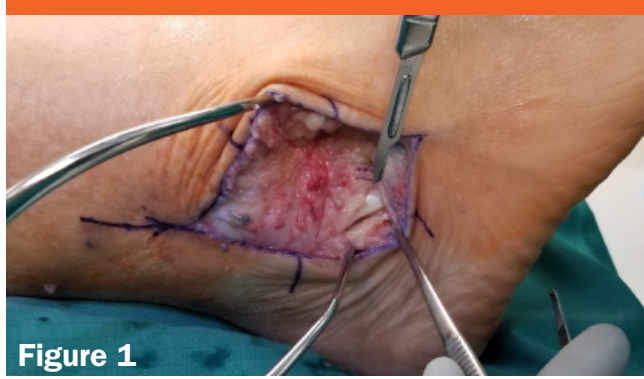
Guidewire (x2)

**FLEXBAND ANCHOR with Driver #3**  
(Sold Separately)  
3.85mm FLEXBAND Anchor  
and suture loop

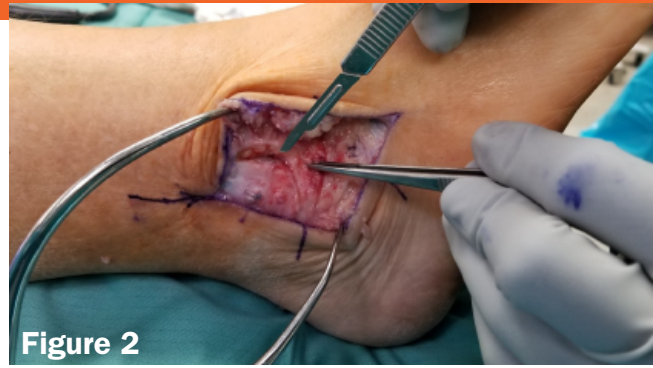



APPROACH

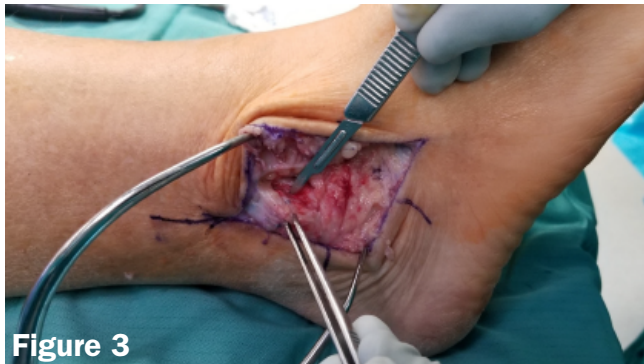

**Figure 1**

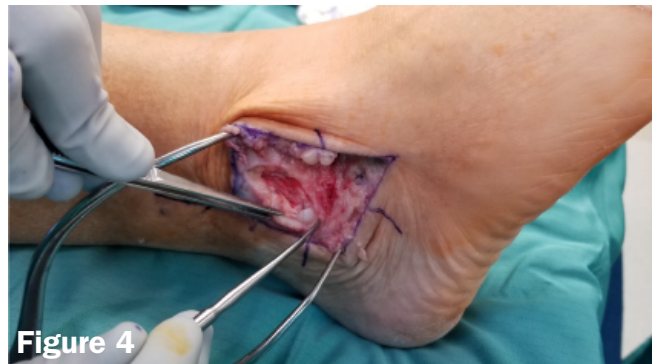

**Figure 2**

Once the incision is made, open the peroneal tendon sheath distally (**Figure 1**). Then reflect the ATFL/CFL sleeve off of the fibula (**Figure 2**).

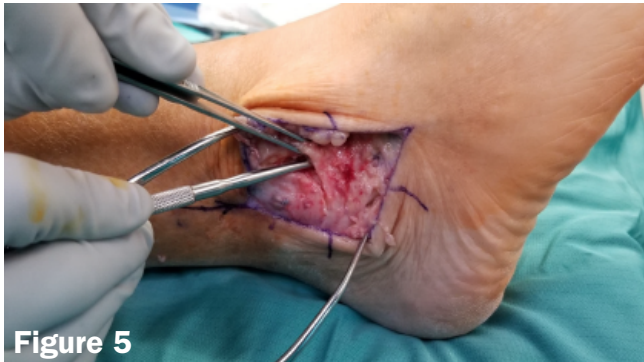

**Figure 3**

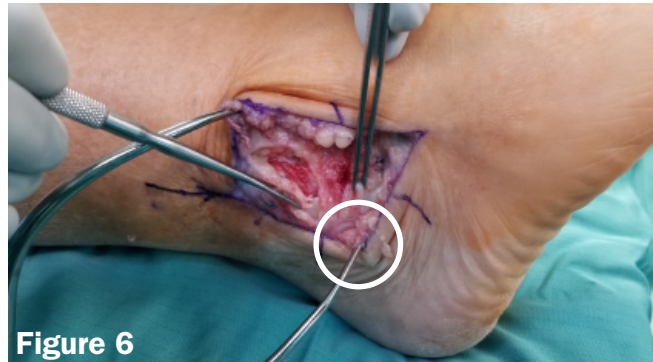


**Figure 4**

A fibular periosteal flap is then elevated (**Figure 3**). Continue to visualize the peroneals as you dissect down (**Figure 4**).



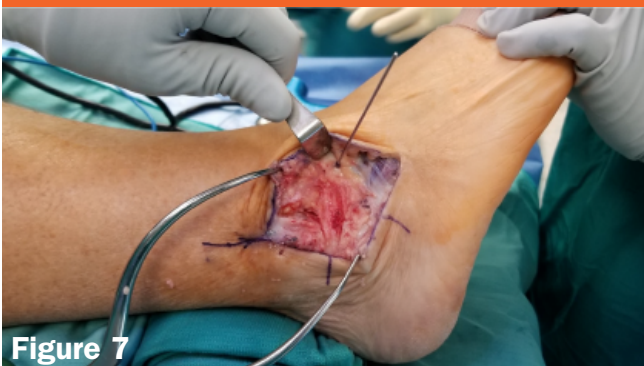**Figure 5**



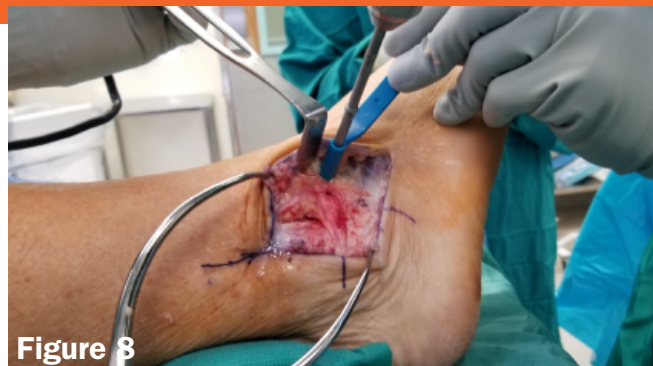**Figure 6**

Use the blunt end of an elevator to mobilize the soft-tissue sleeve (**Figure 5**). This is especially important in a revision surgery. Make sure to preserve the retinaculum attached to the calcaneus (**the tissue in the forceps Figure 6**) as it will be an important part of the repair later.

TALAR PREPARATION



**Figure 7**



**Figure 8**

With the cuff mobilized, talar preparation is initiated. The first 1.4mm guidewire is driven through the tissue flap, and placed into the talar neck in (**Figure 7**). The drill should be parallel to the bottom of the foot, driving at a 45° angle off of the anterior plane. Once the guidewire is placed, the 4.25mm cannulated drill and blue tissue protector are slid over and drilled to the hard stop (**Figure 8**).

# ATFL + CFL RECONSTRUCTION

TALAR PREPARATION

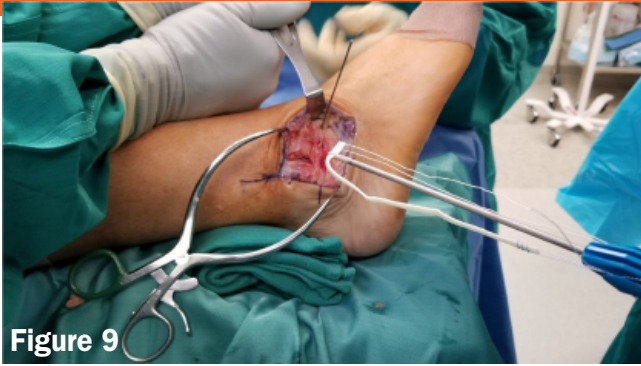

Figure 9

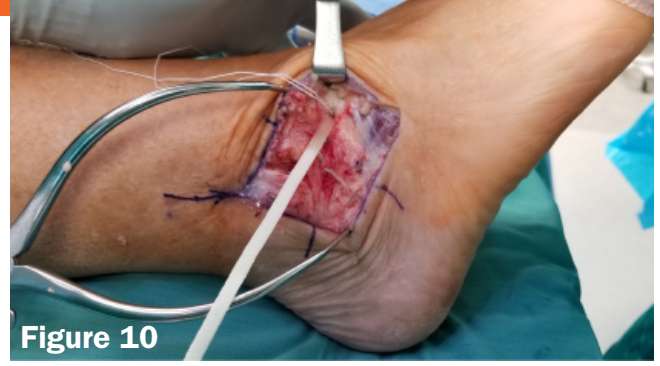

Figure 10

After drilling, replace the guidewire into the drilled hole and use as an orientation reference for placement of the anchor and FLEXBAND. Take the FLEXBAND ANCHOR and driver with 24cm FLEXBAND, unwind the suture tails from the handle and readjust the FLEXBAND so that 2cm of matrix is on one side of anchor and  $\approx 22$  cm is on the other (**Figure 9**). Once FLEXBAND is reset, remove the guidewire and place the FLEXBAND ANCHOR into the talar hole with the long FLEXBAND leg facing the fibula, taking care to mimic the guidewire orientation, and impact until the anchor is seated at or just below the cortical bone (**Figure 10**).

FIBULAR PREPARATION

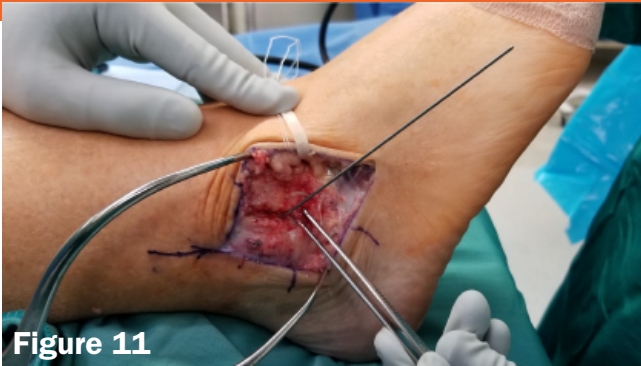

Figure 11

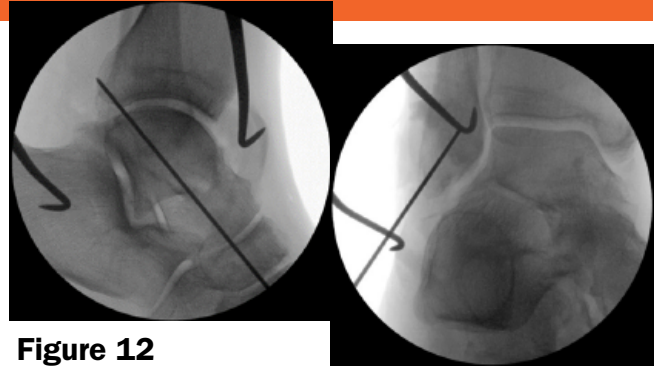


Figure 12

With the talus complete, we turn to the fibula. With a wire driver, place a 1.4mm guidewire into the fibula (**Figure 11**). The tip should be placed  $\approx 1$  cm from the distal tip on the anterior face and driven posteromedially (**Figure 12**).

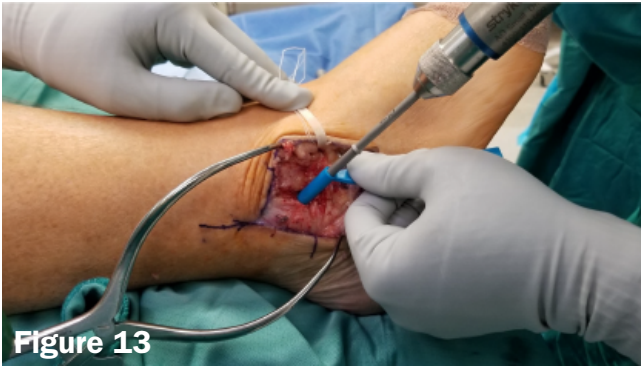

Figure 13

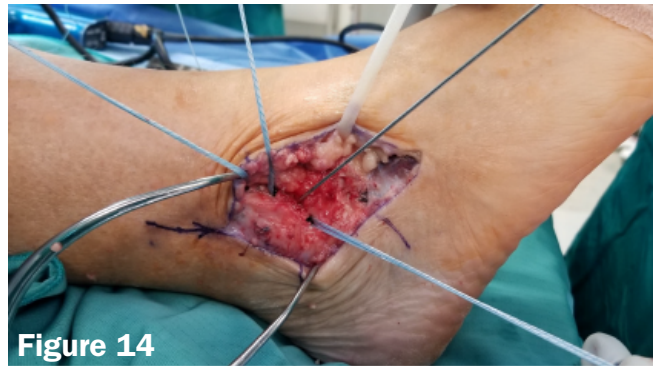

Figure 14

Once the guidewire is placed, the 4.25mm cannulated drillbit and tissue protector are slid over, and the fibular hole is drilled to the hard stop (**Figure 13**). After drilling, utilize the guidewire as a fibular placeholder while your suture anchors of choice are placed into the fibula for the Broström (**Figure 14**).

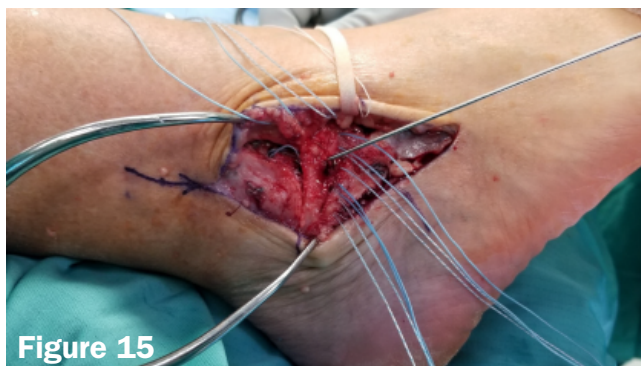

Figure 15

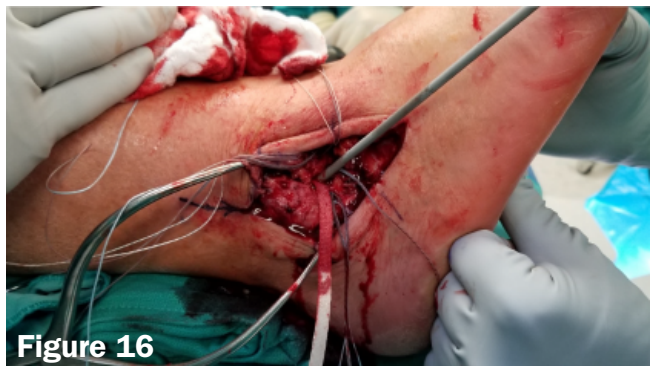

Figure 16

After the suture anchors are placed, the guidewire is removed and the tissue cuff is pulled up to the fibula. The guidewire is then used to perforate the cuff and relocate the fibular drillhole (**Figure 15**). With the guidewire in place, the tissue cuff is then secured to the fibula. Next, the long leg of the FLEXBAND is laced through the second FLEXBAND ANCHOR aperture and all slack is removed as it is properly oriented and set firmly into the fibular drill hole. Once aligned, the FLEXBAND ANCHOR is impacted into place (**Figure 16**).





CALCANEAL PREPARATION

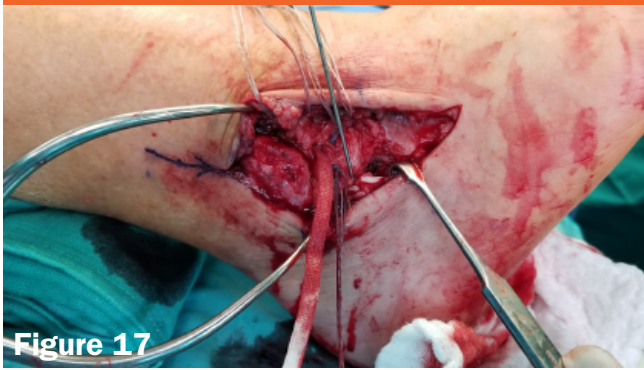


Figure 17

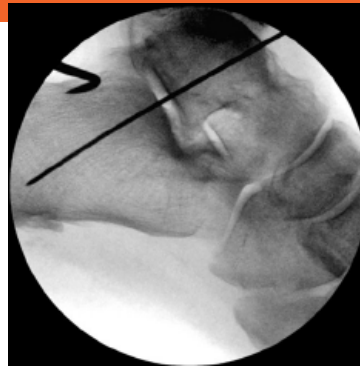

Figure 18

With the ATFL reconstruction complete, we now turn to focus on the CFL. Utilizing the mobile retinaculum sleeve to visualize and avoid the peroneal tendons, a 1.4mm guidewire is driven into calcaneus (**Figures 17 & 18**).

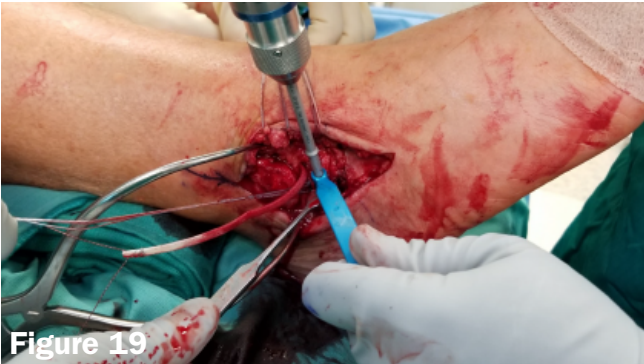

Figure 19

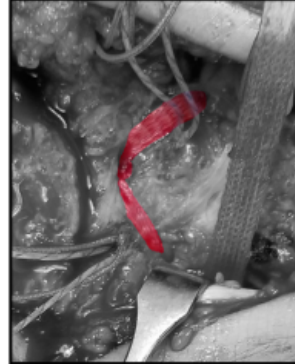

Figure 20

Once the guidewire is set, the 4.25mm cannulated drill and tissue protector are used once again to prepare a hole for the anchor (**Figure 19**). After drilling, make sure to pass the un-anchored FLEXBAND tail deep to the peroneals, then lace it into the FLEXBAND ANCHOR. With the FLEXBAND loaded into the FLEXBAND ANCHOR, remove all slack and firmly set the tip of the anchor into the calcaneal drill hole at the same orientation as the guidewire was driven and impact it into place. After the final anchor is seated, trim away the excess FLEXBAND matrix (**Figure 20**).

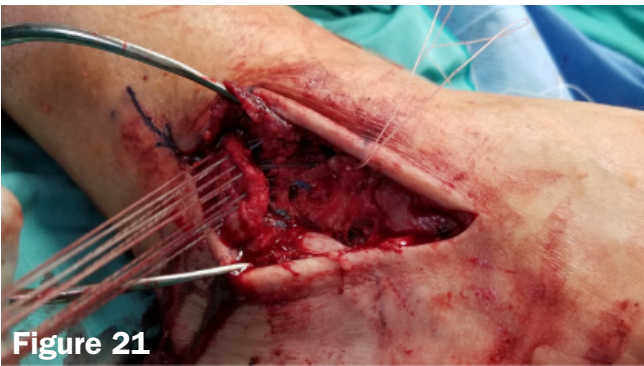


Figure 21

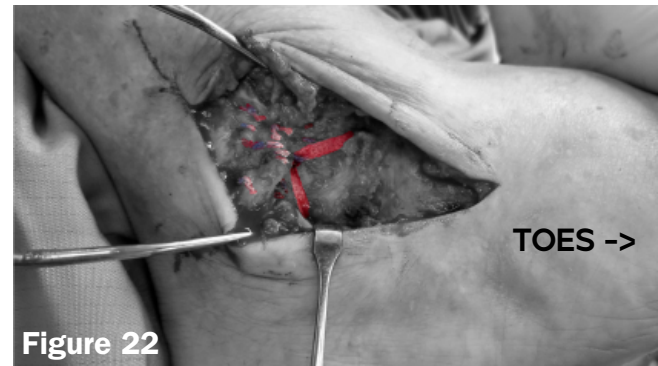

Figure 22

With everything now implanted and tensioned, sutures are passed through the fibula periosteal sleeve (**Figure 21**), and the reconstruction is completed (**Figure 22**).


IMPLANTS USED



FLEXBAND<sup>®</sup> MULTI  
 FLEXBAND<sup>®</sup> ANCHOR

P/N 71016

P/N 81001





Scan to see patient experiences,  
or learn more about Artelon and  
our FLEXBAND systems

## ORDERING INFORMATION

### FLEXBAND<sup>SOLO</sup> SYSTEM

P/N 51004

|  |     |
|--|-----|
| 3.85 x 17 mm FLEXBAND ANCHOR w Driver  | x 2 |
| 0.5 x 8 cm FLEXBAND Plus Angled Matrix | x 1 |
| Cannulated Drill Bit                   | x 1 |
| Guidewire                              | x 2 |

### FLEXBAND<sup>MULTI</sup> SYSTEM

P/N 71016

|   |     |
|---|-----|
| 3.85 x 17 mm FLEXBAND ANCHOR w Driver   | x 2 |
| 0.5 x 24 cm FLEXBAND Plus Angled Matrix | x 1 |
| Cannulated Drill Bit                    | x 1 |
| Guidewire                               | x 2 |
| Passing Wire                            | x 1 |

## OPTIONAL ACCESSORIES

|                                       |     |           |
|---------------------------------------|-----|-----------|
| 3.85 x 17 mm FLEXBAND ANCHOR w Driver | x 1 | P/N 81001 |
| Pilot Tip Drill (non-cannulated)      | x 1 | P/N 61018 |