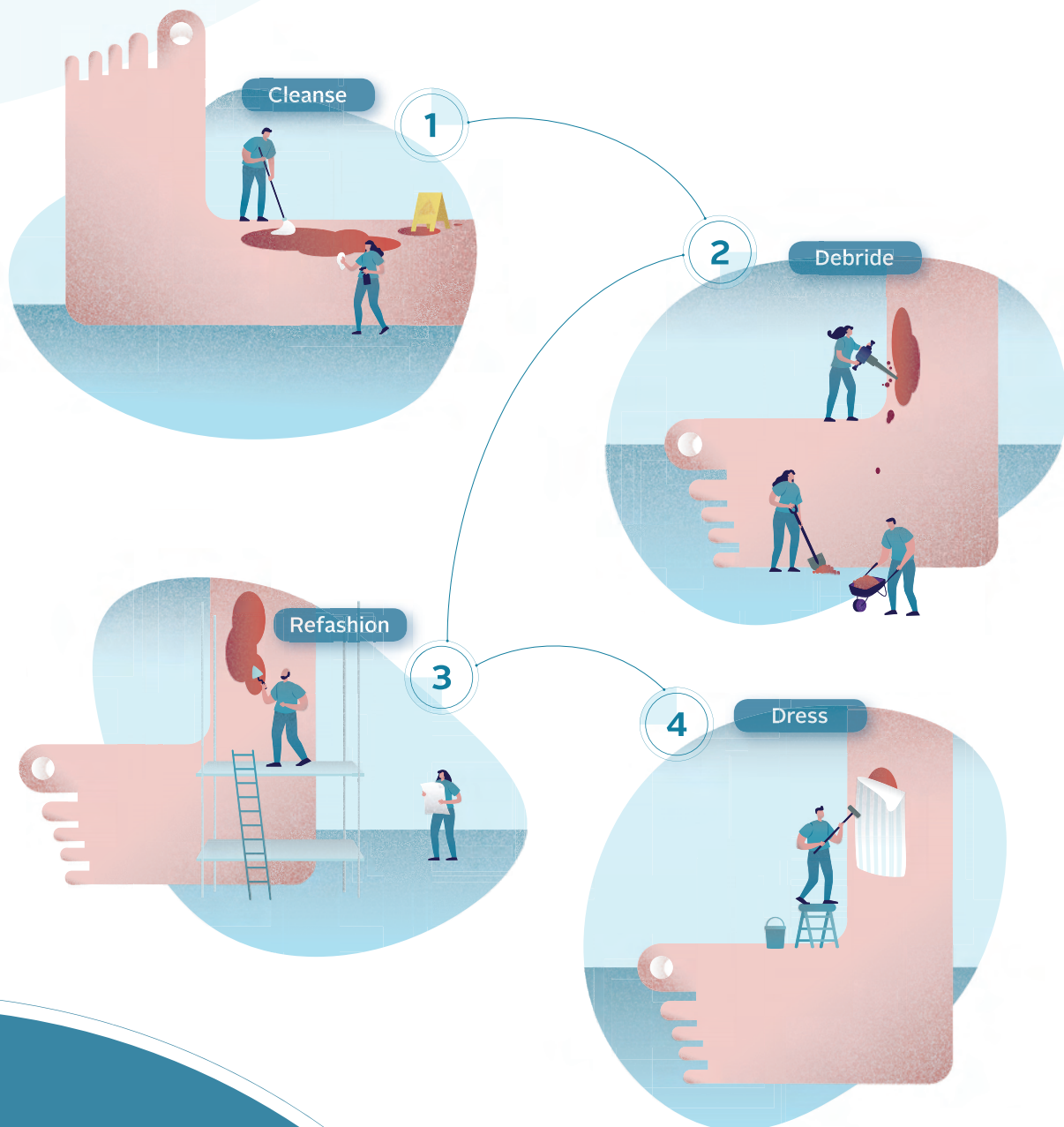


Defying hard-to-heal wounds with an early antibiofilm intervention strategy: wound hygiene



Authors:

- **Christine Murphy**, PhD, RN, WOC(C), Vascular Nurse Specialist, The Ottawa Hospital Limb Preservation Centre, Ottawa, Canada
- **Leanne Atkin**, MHSc, RGN, PhD, Vascular Nurse Consultant, Mid Yorkshire Hospitals NHS Trust and University of Huddersfield, UK
- **Terry Swanson**, Nurse Practitioner, Wound Management, Warrnambool, Victoria, Australia
- **Masahiro Tachi**, MD, PhD, Professor, Department of Plastic and Reconstructive Surgery, Graduate School of Medicine, Tohoku University, Sendai, Japan
- **Yih Kai Tan**, MD, FRCSEd, CWSP, Director of Vascular Services, Consultant Vascular and Endovascular Surgeon, Changi General Hospital, Singapore
- **Melina Vega de Ceniga**, MD, Consultant Angiologist, Vascular and Endovascular Surgeon, Galdakao-Usansolo Hospital, Bizkaia, Spain
- **Dot Weir**, RN, CWON, CWS, Saratoga Hospital Center for Wound Healing and Hyperbaric Medicine, Saratoga Springs, New York, US
- **Randall Wolcott**, MD, CWS, Southwest Regional Wound Care Center, Lubbock, Texas, US

Reviewer panel:

- **Júlia Černožorská**, PhD, Dermatologist, Dermal Centre, Mělník, Czech Republic
- **Guido Ciprandi**, MD, PhD, Chief Wound Care Surgical Unit, Division of Plastic and Maxillofacial Surgery, Bambino Gesù Children's Hospital, Research Institute, Rome, Italy
- **Joachim Dissemund**, MD, Professor of Dermatology and Venerology, University of Essen, Germany
- **Garth A James**, PhD, Associate Research Professor of Chemical and Biological Engineering, Director, Medical Biofilms Laboratory, Center for Biofilm Engineering, Montana State University, Bozeman, Montana, US
- **Jenny Hurlow**, GNP-BC, WOCN, Wound Specialized Advanced Practice Nurse, Advanced Wound Care, Southaven, Mississippi and West Memphis, Arkansas, US
- **José Luis Lázaro Martínez**, DPM, PhD, Professor and Chief of Diabetic Foot Unit, Complutense University of Madrid, Spain
- **Beata Mrozikiewicz-Rakowska**, MD, PhD, Associate Professor, Diabetology and Metabolic Diseases Department, Medical University of Warsaw, Warsaw, Poland
- **Pauline Wilson**, BSc (Hons) SRChE, MCPod, MChSI, Pg(Dip), FFPM RCPS (Glas), Clinical Specialist Podiatrist, St James's Hospital, Dublin, Republic of Ireland

This document was supported by: ConvaTec Limited.

Suggested citation for this document: Murphy C, Atkin L, Swanson T, Tachi M, Tan YK, Vega de Ceniga M, Weir D, Wolcott R. International consensus document. Defying hard-to-heal wounds with an early antibiofilm intervention strategy: wound hygiene. J Wound Care 2020; 29(Suppl 3b):S1–28.

Editor: Tracy Cowan
Senior Project Manager and Chief Sub Editor: Camila Fronzo
Project Manager: Mercedes Arrieta
Medical Writer: Stephanie Wasek
Managing Director: Anthony Kerr: anthony.kerr@markallengroup.com

Published by: MA Healthcare Ltd, St Jude's Church, Dulwich Road, London, SE24 0PB, UK
Tel: +44 (0)20 7738 6726 Web: www.markallengroup.com

© MA Healthcare Ltd 2020

ConvaTec, the ConvaTec logo, the Wound Hygiene logo and the cover artwork are trademarks or registered trademarks or copyrighted materials of ConvaTec Inc. Any use without the express written consent of ConvaTec Inc. is forbidden.
All rights reserved

Table of contents

Foreword	S4
The rationale for wound hygiene	S5
Biofilm: the primary barrier to healing? <ul style="list-style-type: none">▪ Lessons from oral hygiene▪ Translation to wound hygiene Wound hygiene: steps in the strategy	
Wound hygiene: stage 1—cleanse	S11
<ul style="list-style-type: none">▪ Cleanse the skin and wound▪ The importance of using an appropriate cleanser▪ Practical tips for cleansing	
Wound hygiene: stage 2—debride	S14
<ul style="list-style-type: none">▪ Importance of proactive debridement in wound hygiene▪ Wound bed fragility and pain▪ Options for initial debridement▪ Practical tips for debridement	
Wound hygiene: stage 3—refashion the wound edges	S18
<ul style="list-style-type: none">▪ Practical tips for refashioning	
Wound hygiene: stage 4—dress the wound	S20
<ul style="list-style-type: none">▪ Optimising the skin▪ Using antimicrobial wound dressings▪ Taking a step-up/step-down approach	
Implementing wound hygiene	S22
<ul style="list-style-type: none">▪ Wound hygiene can be safely implemented in any setting▪ Anticipated benefits▪ Implementation of wound hygiene, as demonstrated by Randy Wolcott	
Consensus statements summary	S26

Foreword



The enormous health and financial burdens incurred by delayed wound healing—often uninspiringly termed ‘chronic wounds’—are acknowledged globally in research documents with alarming frequency. Affected individuals suffer increased pain and are vulnerable to recurrent

infections, as they live with a health condition that is poorly understood by many healthcare providers. These wounds are commonly expected not to resolve. It might even be said this outcome is simply accepted.

In recent years, evidence has been growing that a key pathology of non-healing wounds is biofilm, just like plaque in dental disease. In biofilm disorders, pain and infection increase the need for analgesics, opioids and antibiotics, making it highly desirable to address the pathology before the disease escalates. Biofilm management is vital, therefore, to achieving better outcomes and reducing the disease burden. Much like dental hygiene, wound hygiene aims to root out the cause of a common pathology in the global population.

The concept of wound hygiene arose during an expert advisory board meeting held in early 2019. There, the international panel agreed that almost all hard-to-heal wounds contain biofilm, which delays or stalls healing. This led to the publication of an expert opinion article in *JWC* that posed the important question: is the current standard of care for wound management adequate, given what we now know about biofilm?¹

There was a growing perception among the panel that wound care is in crisis. Perhaps it is. Globally, there is a perfect storm brewing in wound care: an ageing population; an increase in age- and lifestyle-associated

conditions such as vascular disease, diabetes (which is pandemic) and obesity; economic strains in healthcare systems worldwide; overuse of antibiotics alongside increasing antibiotic resistance; and the ongoing severe impact of wounds on quality of life. Despite all the new products and best practices, the burden of wounds is not getting smaller. There is no magic recipe that rapidly improves non-healing wounds with consistent, reproducible results in all settings.

It is clear that the puzzle is missing a piece. Evidence is mounting that this piece is biofilm management, which is increasingly recognised as a factor in a multitude of chronic disease conditions. It may be time to rethink what constitutes best practice, particularly in wounds that are colonised by biofilm or infected.

At the expert advisory meeting, the panel discussed ways of embedding real change into generalist practice. Hence, it devised the concept of wound hygiene, which is based on the premise that, just as we follow basic hygiene everyday by washing our hands, brushing our teeth and showering to keep clean and ward off germs, so we should apply basic hygiene to wounds.

The panel met in summer 2019 to discuss the structure and content of this concept, with a view to publishing a consensus document in *JWC*. The result is this publication, which defines wound hygiene, describes how it can help reduce antibiotic usage and advises how it can be implemented into day-to-day practice. The international panel recognises this might need to take into account local standards and guidelines.

Christine Murphy
Panel chair

1. Murphy C, Atkin L, Dissemond J et al. Defying hard-to-heal wounds with an early antibiofilm intervention strategy: “wound hygiene.” *J Wound Care* 2019;28:818–22. <https://doi.org/10.12968/jowc.2019.28.12.818>

The rationale for wound hygiene

Despite advances in dressing technology and best practice, wound care is in crisis: the number of hard-to-heal wounds is increasing and the implications for the healthcare system, including greater antibiotic usage, are challenging (Figure 1).¹⁻¹³ To improve the management of hard-to-heal wounds, it is necessary to address the tenacious biofilm that is present in most of them.¹⁴

Biofilm management involves regular debridement followed by antibiofilm re-formation strategies, including the use of topical antimicrobial dressings.¹⁴ This consensus document suggests there is a need to go further by implementing a new strategy, called wound hygiene, which involves two additional stages: cleansing the wound and periwound skin, and refashioning the wound edge. Wound hygiene is a structured method for overcoming the barriers to healing associated with biofilm. This document therefore dispenses with the term chronic wounds in favour of hard-to-heal wounds, signifying that these barriers can be overcome.

Biofilm: the primary barrier to healing?

When a wound is hard-to-heal, the interruption in the healing process is largely associated with the presence of tenacious biofilm (a community of multispecies microbes). Although other underlying host factors may also present obstacles to healing, it is increasingly acknowledged that a majority—if not all—non-healing wounds contain biofilm, which is a key barrier to healing.^{15,16} Figure 2 illustrates how biofilm develops.

An increase in the number and complexity of microbes in any tissue environment will increase the risk of infection. This risk multiplies where there is increased microbial virulence, antibiotic/antimicrobial resistance and tolerance, and/or the host defences are impaired—for example, due to diabetes and obesity.¹⁷

Lessons from oral hygiene

In oral health, the presence of biofilm (dental plaque) on the teeth and between the enamel and gums (gingival crevices) is the most widely accepted cause of periodontal diseases.¹⁸

Oral biofilm re-forms quickly—within 24 hours of oral hygiene.¹⁸ This is why it is recommended to floss and brush twice daily, each time approximately halfway through this cycle of biofilm re-formation.¹⁹ It is estimated that 50-90% of adults worldwide are affected by gingivitis, which is a mild, reversible form of periodontal disease that can be managed with improved oral hygiene.¹⁸ The importance of repetitive, regular and frequent oral hygiene cannot be overstated.

There are lessons from this for wound care. Wound biofilm is an independent factor that delays or stalls healing. In the past, before the effects of wound biofilm were understood, wounds were regarded as being akin to a garden that needs gentle tending. However, it could be more appropriate to perceive the wound bed as a battlefield, where biofilm is the enemy whose presence can result in stalled or non-healing, amputation, impaired quality of life and a large associated socioeconomic burden.^{20,21} The health professional therefore engages in battle when managing the hard-to-heal wound, where the goal is to disrupt and remove the wound biofilm and prevent its re-formation. Wound hygiene provides health professionals with a toolkit to do this.

Translation to wound hygiene

The presence of biofilm in hard-to-heal wounds and its significant contribution to delayed healing is well documented.^{14,15,22-24} To initiate and support healing, the biofilm must therefore be disrupted/removed.²⁵

There is still debate about the signs and symptoms associated with wound biofilm, but there is a growing consensus that these include both the covert and overt signs of local wound infection.²⁴ Furthermore, although some say that when a biofilm is mature, a slimy film may

✘ MYTH | You need to see biofilm in order to manage it.

✔ REALITY | A thin slimy film on the wound surface is considered by some to be a sign of wound biofilm. However, microbes are invisible; therefore, lack of visible film is not an indicator that the wound is biofilm-free. The panel proposes it should be assumed that biofilm is present in all hard-to-heal wounds.

The rationale for wound hygiene

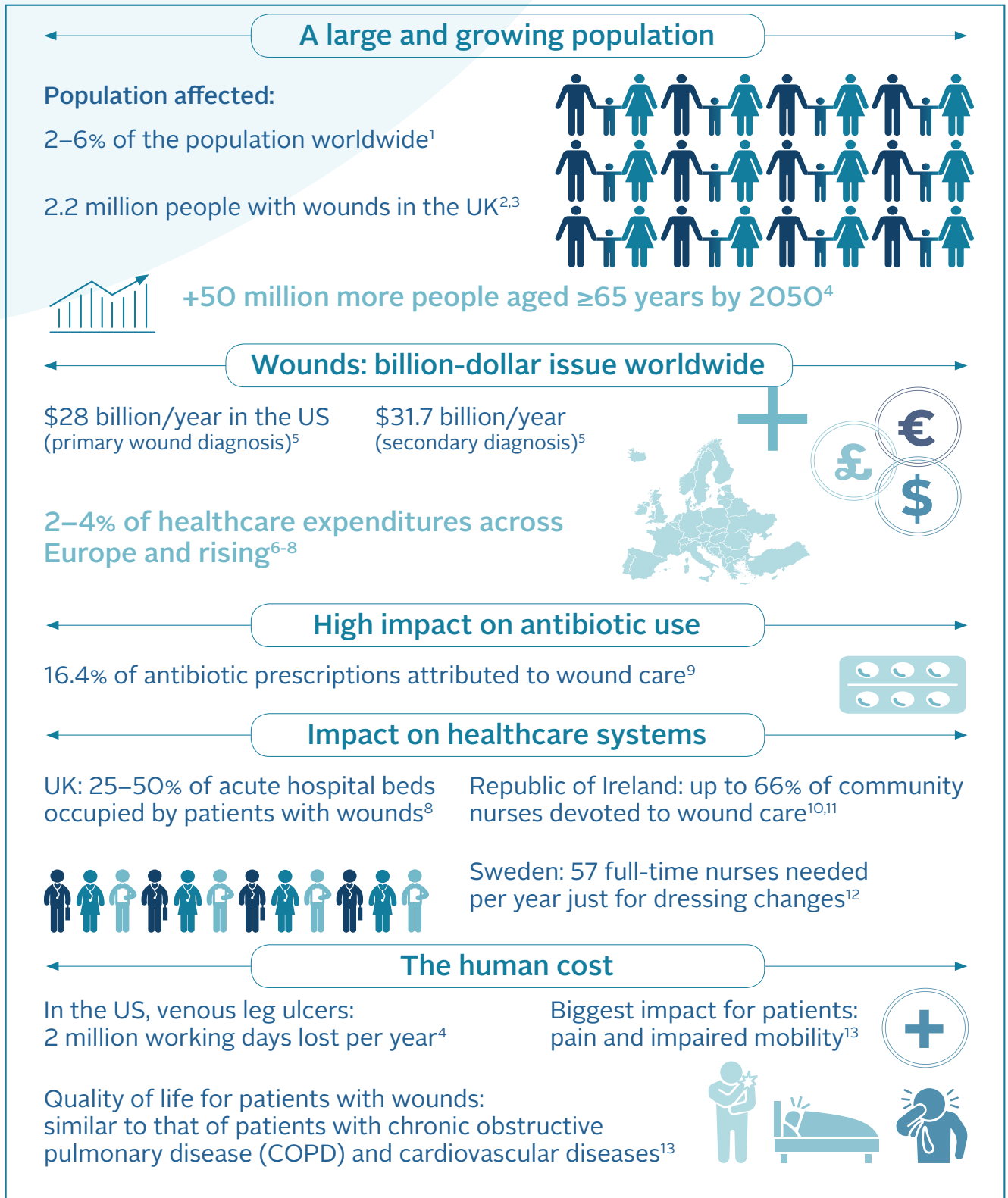


Figure 1. Wound care in crisis

Key term

Hard-to-heal wound

A wound that has failed to respond to evidence-based standard of care. The concept of wound hygiene is based on the premise that all hard-to-heal wounds contain biofilm. Because of the speed with which wound biofilm forms, a wound that exhibits exudate, slough and an increase in size by the third day of its occurrence may already be defined as hard-to-heal.

form on the wound surface, this is contested,²⁶ and all agree it is not possible to make a definitive diagnosis by eye alone.¹⁵ Advanced molecular biology and microscopy techniques are required to confirm its presence, but these are expensive and not widely available to most health professionals. The panel therefore proposes that it should always be assumed that hard-to-heal wounds contain biofilm, which is located primarily on the wound surface (although aggregates may appear in deeper tissue) and is inconsistently distributed across and within the wound.^{15,16,27}

Based on the evidence and current state of practice, a well-planned and systematic approach to wound cleansing is needed to prepare hard-to-heal wounds for management.²⁸ The wound hygiene concept was developed to meet this need. It proposes that, to promote healing, the biofilm must be managed early with a strategy comprising:

- Cleansing (of both the wound and periwound skin)
- Debridement (initial aggressive debridement if necessary, as well as maintenance)
- Refashioning the wound edges
- Dressing the wound.

At times, these approaches will need to overlap. Implementation of the wound hygiene concept can help convert the wound biofilm battleground into a more peaceful landscape, in which the wound can progress towards healing.

Key term

Wound biofilm

A complex community of different species of bacteria and fungi that causes a sustained subclinical wound infection, but can protect itself from the host's immune response and is tolerant to antibiotics and antiseptics.²⁴ Biofilm can form within hours and can reach maturity in 48–72 hours³⁰ (Figure 2).

✘ MYTH | Addressing the wound pathophysiology and patient comorbidities will address the cause of the wound.

✔ REALITY | Wound hygiene should be implemented at the same time that the underlying causes of the wound and the patient's morbidities are being addressed. This will ensure that the wound pathology and wound biofilm are managed simultaneously.

Wound hygiene: steps in the strategy

Hygiene is, of course, a fundamental and long-accepted concept. Implementation of hygiene strategies, such as hand hygiene and surgical asepsis, have radically improved population health.

Wound hygiene is a powerful toolkit. Its use in combination with the TIMERS (tissue, inflammation, moisture, edge, regeneration/repair, social factors) framework²⁹ will help establish biofilm management as the optimal wound-care strategy. It can be used on all wounds, including acute and postoperative.

The core principle of wound hygiene is to remove or minimise all unwanted materials, including biofilm, devitalised tissue and foreign debris, from the wound, address any residual biofilm, and prevent its re-formation. This will kickstart healing.

Like all forms of hygiene, the hallmark of wound hygiene is repetition: the wound must be cleansed, debrided and

The rationale for wound hygiene

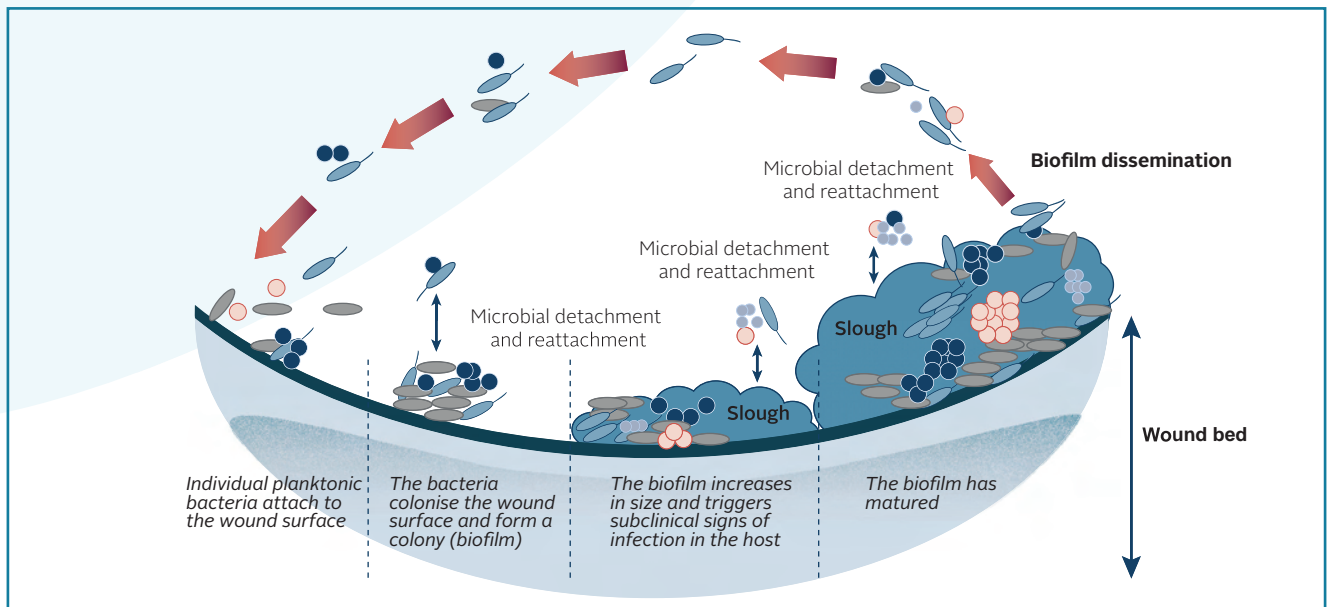


Figure 2. Illustration depicting the stages of biofilm formation and maturity. Adapted from Percival³¹

The wound hygiene concept proposes that wound biofilm can be managed, provided that all underlying aetiologies, such as chronic venous insufficiency or peripheral arterial disease, are addressed and the patient receives gold standard care. A full holistic assessment is essential to achieve this

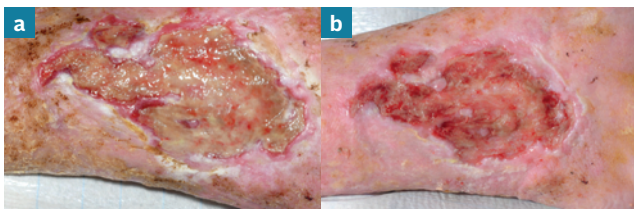


Figure 3. Wound before (a) and 10 minutes after (b) wound hygiene. Note the superficial slough and condition of the peri-wound skin pre-wound hygiene

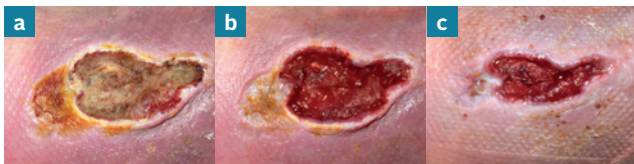

Figure 4. Wound before (a) and 10 minutes after (b) wound hygiene. The same wound after the next episode of wound hygiene, one week later (c)

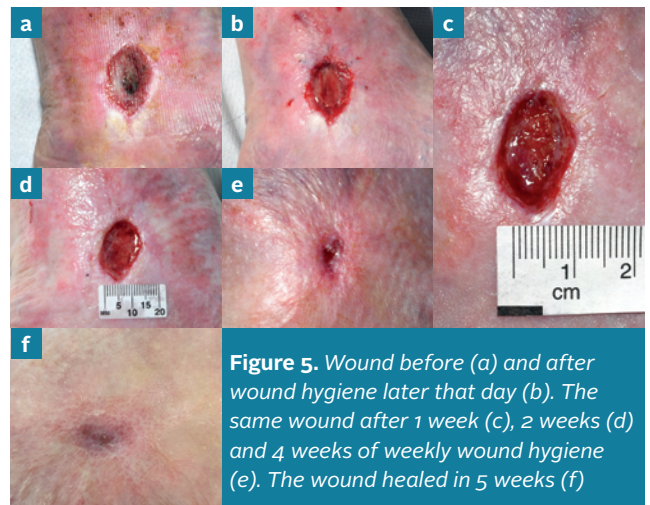


Figure 5. Wound before (a) and after wound hygiene later that day (b). The same wound after 1 week (c), 2 weeks (d) and 4 weeks of weekly wound hygiene (e). The wound healed in 5 weeks (f)

its edges refashioned at every assessment and dressing change. Like hygiene in general, it is not an optional activity.

The goal of this document is to establish the concept of wound hygiene as a core and non-negotiable component of wound care. Figures 3–5 show how implementation of wound hygiene promotes healing. Table 1 describes and Figure 6 illustrates the four activities of wound hygiene.

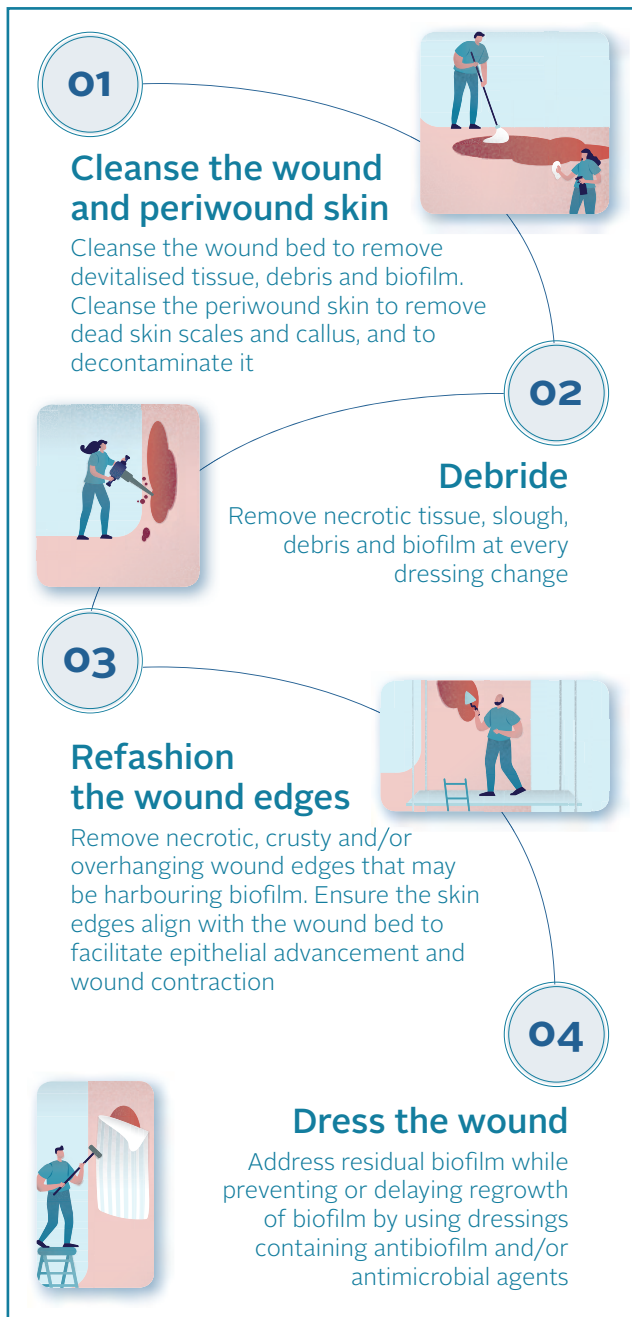

Figure 6. The four activities of wound hygiene

References

- Järbrink K, Ni G, Sönnergren H et al. The humanistic and economic burden of chronic wounds: a protocol for a systematic review. *Systematic Reviews* 2017;6:15
- Campbell D. Chronic wounds: the hidden health crisis hitting 2m Britons. *The Guardian* 2019 July 29. <https://tinyurl.com/yy2xtjfn> (accessed 14 February 2020)
- Guest JF, Ayoub N, McIlwraith T et al. Health economic burden that wounds impose on the National Health Service in the UK. *BMJ Open* 2015;5
- Sen CK, Gordillo GM, Roy S et al. Human skin wounds: a major and snowballing threat to public health and the economy. *Wound Repair Regen* 2009;17:763–71
- Nussbaum SR, Carter MJ, Fife CE et al. An economic evaluation of the impact, cost, and medicare policy implications of chronic nonhealing wounds. *Value in Health* 2018;21:27–32. <https://doi.org/10.1016/j.jval.2017.07.007>
- Purwins S, Herberger K, Debus ES et al. Cost-of-illness of chronic leg ulcers in Germany. *Int Wound J* 2010;7:97–102
- Hjort A, Gotttrup F. Cost of wound treatment to increase significantly in Denmark over the next decade. *J Wound Care* 2010;19:173–4, 176, 178, 180, 182, 184. <https://doi.org/10.12968/jowc.2010.19.5.48046>
- Posnett J, Gotttrup F, Lundgren H et al. The resource impact of wounds on health-care providers in Europe. *J Wound Care* 2009;18:154–61. <https://doi.org/10.12968/jowc.2009.18.4.1607>
- Dolk FC, Pouwels KB, Smith DR et al. Antibiotics in primary care in England: which antibiotics are prescribed and for which conditions? *J Antimicrob Chemother* 2018;73:ii2–10. <https://doi.org/10.1093/jac/dkx504>
- Clarke-Moloney M, Keane N, Kavanagh E. An exploration of current leg ulcer management practices in an Irish community setting. *J Wound Care* 2006;15:407–10. <https://doi.org/10.12968/jowc.2006.15.9.26963>
- Clarke-Moloney M, Keane N, Kavanagh E. Changes in leg ulcer management practice following training in an Irish community setting. *J Wound Care* 2008;17:116, 118–21. <https://doi.org/10.12968/jowc.2008.17.3.28669>
- Lindholm C, Bergsten A, Berglund E. Chronic wounds and nursing care. *J Wound Care* 1999;8:5–10. <https://doi.org/10.12968/jowc.1999.8.1.25828>
- Olsson M, Järbrink K, Divakar U et al. The humanistic and economic burden of chronic wounds: A systematic review. *Wound Repair Regen* 2019;27:114–25.
- Bjarnsholt T, Eberlein T, Malone M et al. Management of biofilm. *Wounds International* 2017;8(2).
- Schultz G, Bjarnsholt T, James GA et al. Consensus guidelines for the identification and treatment of biofilms in chronic nonhealing wounds. *Wound Repair Regen* 2017;25:744–57. <https://doi.org/10.1111/wrr.12590>
- Malone M, Swanson T. Biofilm-based wound care: the importance of debridement in biofilm treatment strategies. *Br J Community Nurs* 2017;22:S20–5.
- Centers for Disease Control (CDC). The biggest antibiotic-resistant threats in the U.S. Centers for Disease Control and Prevention 2019. <https://www.cdc.gov/drugresistance/biggest-threats.html> (accessed 14 February 2020)
- Mancl KA, Kirsner RS, Ajdic D. Wound biofilms: lessons learned from oral biofilms. *Wound Repair Regen* 2013;21:352–62. <https://doi.org/10.1111/wrr.12034>
- Stewart PS. Biophysics of biofilm infection. *Pathog Dis* 2014;70:212–8.
- Wolcott RD, Rhoads DD, Bennett ME et al. Chronic wounds and the medical biofilm paradigm. *J Wound Care* 2010;19:45–6, 48–50, 52–3.
- Nussbaum SR, Carter MJ, Fife CE et al. An economic evaluation of the impact, cost, and medicare policy implications of chronic nonhealing wounds. *Value Health* 2018;21:27–32. <https://doi.org/10.1016/j.jval.2017.07.007>
- Atkin L, Bučko Z, Montero EC et al. Implementing TIMERS: the race against hard-to-heal wounds. *J Wound Care* 2019;28:51–50
- Haesler E, Swanson T, Ousey K et al. Clinical indicators of wound infection and biofilm: reaching international consensus. *J Wound Care* 2019;28:S4–12. <https://doi.org/10.12968/jowc.2019.28.Sup3b.S4>
- International Wound Infection Institute (IWII). Wound infection in clinical practice: international consensus update 2016. *Wounds International* 2016.
- Metcalf DG, Bowler PG. Biofilm delays wound healing: A review of the evidence. *Burns Trauma* 2013;1:5–12. <https://doi.org/10.4103/2321-3868.113329>
- White RJ, Cutting KF. Wound biofilms-are they visible? *J Wound Care* 2012;21:140–1.
- Hurlow J, Blanz E, Gaddy JA. Clinical investigation of biofilm in non-healing wounds by high resolution microscopy techniques. *J Wound Care* 2016;25 Suppl 9:S11–22. <https://doi.org/10.12968/jowc.2016.25.Sup9.S11>
- Percival SL, Mayer D, Kirsner RS et al. Surfactants: Role in biofilm management and cellular behaviour. *International Wound Journal* 2019;16:753–60.
- Atkin L, Bučko Z, Montero EC et al. Implementing TIMERS: the race against hard-to-heal wounds. *J Wound Care* 2019;28:51–49
- Wolcott RD, Rumbaugh KP, James G et al. Biofilm maturity studies indicate sharp debridement opens a time- dependent therapeutic window. *J Wound Care* 2010;19:320–8. <https://doi.org/10.12968/jowc.2010.19.8.77709>
- Percival SL. Importance of biofilm formation in surgical infection. *Br J Surg* 2017;104:e85–94. <https://doi.org/10.1002/bjs.10433>

CALL TO ACTION

Service providers should ensure that policies are in place so that every health professional (generalist and specialist) can undertake some degree of wound hygiene. The panel believes that implementing wound hygiene can result in better healing rates and times, fewer antibiotic prescriptions, improved quality of life and wellbeing for patients, and significant cost savings for buyers and purchasers

The rationale for wound hygiene

Table 1. Components of wound hygiene

Component	Activities	Tools	Rationale
1. Cleanse: wound and periwound	<p>Cleanse the wound bed sufficiently to loosen superficial devitalised tissue, wound debris, foreign debris and biofilm. Cleanse the periwound skin to remove scales and callus, and to decontaminate the area.</p> <p>Using gentle force where necessary and as tolerated, cleanse the skin located 10–20cm around the wound, complying with local guidance when cleansing 'clean' (farthest from the wound) and 'dirty' areas (nearest the wound or the wound itself).</p> <p>Ideally, use an antiseptic or antimicrobial wash or surfactant solution to aid surface and periwound cleansing.</p>	<p>Gauze or commercially available cleansing pads.</p> <p>Antiseptic or antimicrobial wash, or surfactant for the wound and periwound skin.</p> <p>Medical skin cleansing wipes.</p> <p>Forcept.</p>	<p>Saline or water rinses/flushes will not remove biofilm.¹⁹</p> <p>Cleansing with intent and appropriate tools/solutions prepares the wound bed for debridement. It is essential that the periwound skin is cleansed to remove further sources of contamination.</p>
2. Debride	<p>Remove all attached devitalised tissue, wound/foreign debris and biofilm. Continue until pinpoint bleeding occurs (where the patient consents and tolerates it, and local practice permits), leaving the wound bed in a condition that will optimise the performance of a wound dressing.</p> <p>The wound bed should be cleansed again after debridement to remove any remaining debris.</p>	<p>Mechanical, sharp, ultrasonic or biological debridement.</p> <p>For post-debridement cleansing of the wound and periwound skin, use an antiseptic or antimicrobial wash, or surfactant.</p>	<p>Debridement that does not achieve pinpoint bleeding, such as autolytic debridement, may not physically remove the biofilm.</p> <p>Applied mechanical force and shear is required to break up and disrupt biofilm.¹⁹ This can be optimised by using a surfactant, antiseptic or antimicrobial solution as well.</p>
3. Refashion the wound edge	<p>Continually assess and agitate the wound edges until pinpoint bleeding occurs; remove curled or rolled-under tissue, dry, callused or hyperkeratotic tissue, and necrotic tissue to kill or minimise any biofilm colonising the wound edges.</p>	<p>Active (mechanical), sharp, ultrasonic or biological debridement.</p>	<p>Removal of callus, hyperkeratotic debris and senescent cells at the wound edges, to expose healthy tissue, allows advancement of healthy tissues.</p>
4. Dress the wound	<p>Choose a dressing that can address any residual biofilm and prevent contamination and recolonisation and, therefore, biofilm re-formation. It should also manage exudate effectively, thereby promoting healing.</p>	<p>Dressings containing antibiofilm and antimicrobial agents that can also absorb and retain exudate.</p>	<p>Biofilm can re-form rapidly, and repeated debridement alone is unlikely to prevent its regrowth. Application of effective topical antimicrobials and antibiofilm agents after biofilm has been physically disrupted can address residual biofilm and suppress its re-formation.¹⁵</p>

Assess the wound at each dressing change to ensure that it is progressing towards healing. As the wound begins to heal, continue to cleanse, although less debridement and refashioning of the wound edges will be necessary. In addition, consider whether to step down by using a non-antimicrobial dressing.

Wound hygiene: stage 1—cleanse

Cleansing helps to achieve the goals of wound hygiene by removing loose material, excess exudate and debris, and disrupting biofilm.^{1,2} It sets the stage for biofilm disruption, the removal of residual biofilm and prevention of biofilm re-formation. As the wound bed and periwound skin are likely to contain biofilm, both areas must be cleansed. This should be done with as much physical force as the patient can tolerate. The procedure should be repeated at each dressing change and after debridement. The selection of cleansing agents and choice of cleansing techniques will be based on clinical assessment.

Key term

Cleansing for wound hygiene

Actively removing surface contaminants, loose debris, slough, softened necrosis, microbes and/or remnants of previous dressings from the wound surface and its surrounding skin.¹⁰

Cleansing the skin and wound

Cleansing the periwound skin and wound bed to remove unwanted material—both visible and invisible to the naked eye—is a cornerstone of wound care, as it promotes a balanced environment in which healing can take place.³ As well as biofilm, the periwound skin can contain debris comprising lipids, fragments of keratinised cells, sebum and sweat, in which small amounts of electrolytes, lactate, urea and ammonia are found. These create an ideal environment for microbial proliferation and biofilm formation. Figure 7 shows an example of cleansing the skin.

Importance of using an appropriate cleanser

Standard use of saline or water rinses will not remove biofilm.⁴ Instead, surfactants are widely used to help remove foreign matter, biological debris⁵ and biofilm.⁶ The surfactant lowers the surface or interfacial tension between a liquid and a solid (such as debris and biofilm), helping to disperse the latter, which can then be removed more easily with a cleansing pad or cloth.⁶

According to Malone and Swanson, loose, non-viable or devitalised tissue can be removed if covered with a surfactant-based wound solution or gel for sufficient time (usually 10–15 minutes) and lightly cleansed with sterile

gauze. However, the evidence on the ability of surfactants to remove wound biofilm is low and mainly *in vitro*.⁶

The panel encourages the use of surfactant-containing antiseptics or pH-balanced solutions to cleanse both the wound bed and periwound skin as part of wound hygiene, where possible in accordance with local practice.⁷ Highly cytotoxic solutions, such as those containing povidone-iodine and hydrogen peroxide, are not recommended.¹⁸ Ideally, a skin cleanser designed for daily use should be chosen, to balance the need to disrupt the microbial load while maintaining skin integrity.⁹

Table 2 outlines solutions that can be used to cleanse the wound and periwound skin, although selection might depend on local guidelines.

✘ MYTH | Never put anything into a wound that you wouldn't put into your eye.

✓ REALITY | The wound bed is not a fragile flower, it is a battleground that requires active intervention with cleansing, debridement, refashioning of the wound edges and strategies to prevent biofilm re-formation. This will create the conditions in which the battleground can become a 'garden' and healing can occur. Agents that may be toxic or too strong should be avoided once a positive healing trajectory has been established.

Key term

Hyperkeratotic tissue

A thick, scaly, outer layer of the skin that can present as red and dry, with brown or grey patches that are scaly, cracked or fissured in appearance; it can cover a small, distinct patch of skin, or all the skin of the lower limb¹¹

Practical tips for cleansing

For the purposes of wound hygiene, careful attention should be paid to the skin approximately 10–20 cm from the wound edges, or the area that had been covered by a dressing or device (e.g. total-contact cast, compression bandages), whichever is larger, taking the anatomical location into consideration. For wounds on the lower limbs, consider cleansing ‘up one joint’—for example, cleansing the entire foot in the case of a diabetic foot ulcer or up to the knee in the case of a venous leg ulcer.

Implement strategies that will avoid contamination from the environment or health professionals. For example, use dedicated equipment to collect wound irrigation fluid or solutions. Do not reuse cleansing cloths; to prevent cross-contamination, use different cloths to cleanse the skin and wound. Avoid putting contaminated cloths in wound cleansing solution. Do not put the contaminated cloth back into the bowl of solution.

References

1. Wolcott R, Fletcher J. The role of wound cleansing in the management of wounds. *Wounds International* 2014;1(1):25–30.
2. Gabriel A, Schraga ED, Windle ML. Wound irrigation. *Medscape* 2013. <https://tinyurl.com/kpzjc6m> (accessed 14 February 2020)
3. Kamolz L-P, Wild T. Wound bed preparation: The impact of debridement and wound cleansing. *Wound Medicine* 2013;1:44–50
4. Stewart PS. Biophysics of biofilm infection. *Pathog Dis* 2014;70:212–8. <https://doi.org/10.1111/2049-632X.12118>
5. Alwadani N, Fatehi P. Synthetic and lignin-based surfactants: Challenges and opportunities. *Carbon Resources Conversion* 2018;1:126–38. <https://doi.org/10.1016/j.crcon.2018.07.006>
6. Malone M, Swanson T. Biofilm-based wound care: the importance of debridement in biofilm treatment strategies. *Br J Community Nurs* 2017;22:S20–5. <https://doi.org/10.12968/bjcn.2017.22.Sup6.S20>
7. Assadian O, Kammerlander G, Geyrhofer C et al. Use of wet-to-moist cleansing with different irrigation solutions to reduce bacterial bioburden in chronic wounds. *J Wound Care* 2018;27:S10–6. <https://doi.org/10.12968/jowc.2018.27.Sup10.S10>
8. Sibbald RG, Leaper DJ, Queen D. Iodine made easy. *Wounds International* 2011;2(2).
9. Konya C, Sanada H, Sugama J et al. Does the use of a cleanser on skin surrounding pressure ulcers in older people promote healing? *J Wound Care* 2005;14:169–71. <https://doi.org/10.12968/jowc.2005.14.4.26758>
10. Rodeheaver GT, Ratliff CR. Wound cleansing, wound irrigation, wound disinfection. In: Krasner DL, van Rijswijk L, eds. *Chronic Wound Care: The Essentials e-Book*. Malvern, PA: HMP; 2018:47–62.
11. Crook H, Frowen E, Mahoney K et al. The All Wales guidance for the management of hyperkeratosis of the lower limb. *Wounds UK*: London, 2014. <https://tinyurl.com/kzsvq8> (accessed 14 February 2020).
12. Trautmann M, Lepper PM, Haller M. Ecology of *Pseudomonas aeruginosa* in the intensive care unit and the evolving role of water outlets as a reservoir of the organism. *Am J Infect Control* 2005;33:S41–49. <https://doi.org/10.1016/j.ajic.2005.03.006>

✘ MYTH | Cleansing is needed only if debris is present, as the wound bed is fragile and must be protected from disruption.

✓ REALITY | Friable, fragile tissue is likely to be infected with biofilm. To progress the wound towards healing, interventions such as cleansing and debridement are required to disrupt the biofilm and remove devitalised tissue and debris. This will promote a clean environment in which healing can occur.

13. Mena KD, Gerba CP. Risk assessment of *Pseudomonas aeruginosa* in water. *Rev Environ Contam Toxicol* 2009;201:71–115. https://doi.org/10.1007/978-1-4419-0032-6_3
14. Jefferies JMC, Cooper T, Yam T et al. *Pseudomonas aeruginosa* outbreaks in the neonatal intensive care unit—a systematic review of risk factors and environmental sources. *J Med Microbiol* 2012;61:1052–61. <https://doi.org/10.1099/jmm.0.044818-0>
15. Percival SL, Chen R, Mayer D et al. Mode of action of poloxamer-based surfactants in wound care and efficacy on biofilms. *Int Wound J* 2018;15:749–55. <https://doi.org/10.1111/iwj.12922>
16. Bradbury S, Fletcher J. Protosan made easy. *Wounds International* 2011;2(2).
17. Braun M, McGrath A, Downie F. Octenilin range made easy. *Wounds UK* 2013;9(4):1–4. <https://tinyurl.com/yxy76kxb> (accessed 14 February 2020)
18. Selkon JB, Cherry GW, Wilson JM et al. Evaluation of hypochlorous acid washes in the treatment of chronic venous leg ulcers. *J Wound Care* 2006;15:33–7. <https://doi.org/10.12968/jowc.2006.15.1.26861>

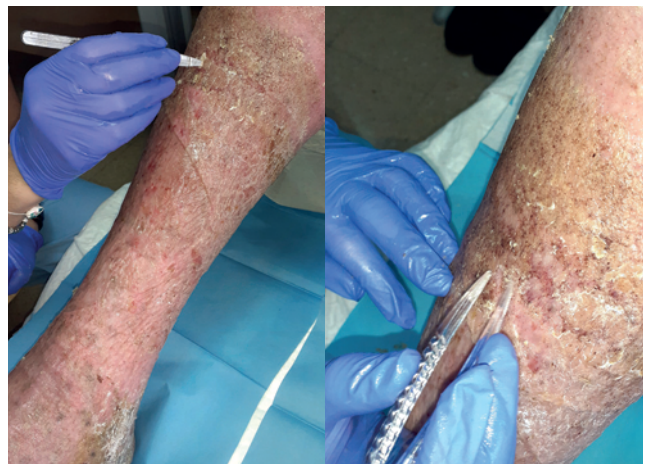

Figure 7. Cleansing the periwound skin as part of wound hygiene: removal of skin scales throughout the limb, up to the knee

Table 2. Solutions for cleansing in wound hygiene*

Solution	Rationale
Non-antiseptic	
Water	<ul style="list-style-type: none"> ▪ Ineffective in reducing bacterial load.^{2,4} ▪ Taps can be colonised with viable microbes: the presence of <i>Pseudomonas aeruginosa</i> in plumbing systems is well documented.¹²⁻¹⁴ ▪ Ineffective in reducing bacterial load.^{2,4} ▪ Single-use sterile containers are no longer sterile after opening.²
Saline	<ul style="list-style-type: none"> ▪ Ineffective in reducing bacterial load.^{2,4,9} ▪ Low toxicity.^{2,4} ▪ Single-use, as bacterial growth can occur within 24 hours of opening.²
Surfactant-containing solution	<ul style="list-style-type: none"> ▪ Due to their surfactant content, some formulations have been shown to disrupt microbial load when less force is applied.² ▪ Some formulations have shown antibiofilm capabilities <i>in vitro</i> by reducing microbial attachment and biofilm formation.¹⁵ ▪ Gentle to healthy cells and can restore cellular integrity.^{2,15}
Antiseptics	
Polyhexamethylene biguanide	<ul style="list-style-type: none"> ▪ Some formulations also contain an antimicrobial substance and a surfactant.¹⁶ ▪ Broad spectrum of activity against microbes with no evidence of resistance.¹⁶
Octenidine dihydrochloride	<ul style="list-style-type: none"> ▪ Some formulations contain a preservative and a surfactant-like molecule that loosens dressings and aids cleansing.¹⁷ ▪ Shown to prevent and remove the growth of bacterial biofilms.¹⁷
Hypochlorous acid	<ul style="list-style-type: none"> ▪ Rapid, broad-spectrum antimicrobial activity with low cytotoxicity.^{18,19} ▪ Can be used to loosen dressings as well as for cleansing.^{18,19}
Chlorhexidine gluconate	<ul style="list-style-type: none"> ▪ Widely used in diluted concentrations for skin and oral applications. ▪ Laboratory tests have shown it is effective against a variety of bacteria and fungi, including <i>Staphylococcus</i> and methicillin-resistant <i>Staphylococcus aureus</i>, <i>Pseudomonas aeruginosa</i> and <i>Candida albicans</i>.²⁰ ▪ Antimicrobial activity is more effective with longer dwell times.²⁰ ▪ Allergic-reaction rate in surgical patients is approximately 0.78 per 100,000 exposures, but it can also cause irritant contact dermatitis or allergic contact dermatitis.²¹

* Follow local protocols for using solutions in practice

† Study did not include examination for and cannot be interpreted for biofilm infection (non-acute infection)

19. Hoon R, Rani SA, Wang L et al. Antimicrobial activity comparison of pure hypochlorous acid (0.01%) with other wound and skin cleansers at non-toxic concentrations. SAWC Spring and WHS 2013.
 20. Koburger T, Hübner N-O, Braun M et al. Standardized comparison of antiseptic efficacy of triclosan, PVP-iodine, octenidine dihydrochloride, polyhexanide and chlorhexidine digluconate. J Antimicrob Chemother 2010;65:1712-9. <https://doi.org/10.1093/jac/dkq212>

21. Garcez T. Chlorhexidine. Report and findings of the 6th National Audit Project Royal College of Anaesthetists. London: Royal College of Anaesthetists, November 2013, pp 197-202. <https://tinyurl.com/v6hkkj> (accessed 14 February 2020)

Wound hygiene: stage 2—debride

The goal of debridement is to remove/minimise all unwanted materials (Box 1), even if some healthy tissue is also removed. Debridement is required as part of the biofilm ‘weeding’ process, to convert the hostile wound battleground into a blossoming ‘tissue garden’ (Table 3). A variety of debridement methods can be used, potentially starting with more intensive methods, if necessary, and then progressing to mechanical debridement. This process is a vital part of wound hygiene and should be administered to all hard-to-heal wounds.

Autolytic debridement—use of the body’s own naturally occurring enzymes to break down devitalised tissue—is insufficient to meet the debridement requirements of wound hygiene, as it takes a long time to occur, requires numerous dressing changes and can increase the risk of infection in hard-to-heal wounds.^{1,2} Furthermore, it relies on the efficiency and effectiveness of the host processes, which are likely to be compromised in hard-to-heal wounds.³

A faster and more effective method is needed to disrupt biofilm, address any residual biofilm and prevent re-formation in hard-to-heal wounds: debridement (Table 3).

Importance of proactive debridement in wound hygiene

Proactive debridement is an integral part of wound hygiene, as it will help any wound not covered with granulation tissue to progress towards healing.⁴ Selection of the method of debridement should be based on assessment of the wound bed, the periwound skin, and the patient’s pain and tolerance levels. Mechanical force, in combination with a surfactant or antimicrobial solution, are effective ways of breaking up and clearing biofilm.⁵

Combined use of a topical surfactant-based wound cleansing solution and a debridement pad or gauze will augment cleansing sufficiently to disrupt and remove biofilm. When physical debridement is contraindicated, it might be possible to use this approach instead.⁶ The result is a well-tended ‘garden’ in which the undesirable matter has been ‘weeded’ out, to provide a healthy environment for growth—in this case, of new tissue.⁷ Debridement decontaminates the wound bed and removes biofilm, thereby preparing it for dressing application, in line with the principles of wound bed preparation.⁸

Box 1. Targets of removal with debridement in wound hygiene^{8,14}

Biofilm
Devitalised tissue (necrosis, slough, eschar)
Excess exudate
Impaired tissue (inflamed or infected)
Serocrusts
Hyperkeratosis
Pus
Haematomas
Foreign bodies
Debris
Remains of previous dressings
Any other types of bioburden/barriers to healing

✘ MYTH | Wet-to-dry dressings provide adequate debridement for healing to occur.

✔ REALITY | The wet-to-dry method can cause substantial pain and distress, resulting in poor patient concordance or adherence to management. With wound hygiene, the wound bed can be debrided without traumatising patients and the biofilm disrupted, removed and its re-formation prevented.

To avoid the risk of injury, the panel acknowledged the need to use caution when considering debriding lower extremity wounds in patients with poorly perfused limbs and autoimmune conditions such as pyoderma gangrenosum.

Similarly, mechanical debridement should be undertaken with caution in patients with bleeding disorders or who are on anticoagulation therapy, and/or who are in intolerable or unpreventable pain. A full clinical assessment by a

Debridement

Key term

The physical removal of biofilm, devitalised tissue, debris and organic matter using mechanical aids such as sterile gauze, soft debridement pads or gauze, curettes, surgical blades, or, when available, ultrasonic debridement.^{6,15} Old methods were considered painful and non-selective, but new technology has made mechanical debridement a more effective, easy-to-implement option.²

Box 2. When to swab and culture the wound

The purpose of culture is to identify organisms to inform the antibiotic plan. However, culture cannot identify all microbes responsible for a wound infection.

In situations where the local protocol does not call for more traditional culture but the nature of the inflammation or the appearance of classic signs of acute infection (increasing inflammation, new or increasing pain, local heat, increasing swelling, advancing redness and purulence) raise concern, consider semiquantitative culture. Here, instead of a swab, exudate or wound tissue from debridement may be sent for analysis to confirm, within 24–72 hours, microbial growth for most microorganisms including *Staphylococcus aureus*, *Pseudomonas aeruginosa* and β -haemolytic streptococci^{6,17}

specialist must be undertaken before these wounds are debrided. In the period pending assessment, they can be cleansed and an antimicrobial dressing applied.

Wound bed fragility and pain

The perception that a wound bed is fragile should not be considered a major barrier to debridement. Although care should be taken to prevent damage, removing all devitalised tissue is a key first step in wound hygiene. Holistic assessment should help guide the extent to which aggressive debridement can be performed.

When it is safe to implement mechanical debridement, it is important to manage the patient's expectations of pain. Topical anaesthetic, such as lidocaine combination gels or creams, may be applied when necessary in accordance with local standards of care. Surfactants can decrease pain, as they help loosen debris, making it easier to remove.⁹ Warming solutions to body temperature can also help ease pain.^{10,11}

Options for initial debridement

At first presentation, the hard-to-heal wound and periwound skin may require a more intensive or targeted method to expose the full extent of the wound, thereby aiding assessment (Table 3). The method chosen should be based on holistic assessment and comply with local guidelines. All instruments or devices used for debridement must be sterile to prevent additional contamination. Figure 8 demonstrates debridement in practice.

Practical tips for debridement

According to an analysis of more than 154 000 patient records over a 4-year period, nearly twice as many hard-to-heal wounds healed with frequent repeated debridement compared with those treated less frequently.¹² Frequent debridement also resulted in shorter healing times for all wound types.¹²

Wound hygiene should therefore be routinely performed every time the clinician assesses or manages the wound. Regular debridement should thus be regarded as standard practice for hard-to-heal wounds.¹²

Before debridement, the wound should be cleansed with an antimicrobial or pH-balanced surfactant solution. After debridement, the wound and periwound skin should be rinsed, ideally with an antiseptic solution, to avoid contamination with surface microbes and to kill bacteria exposed by the procedure.¹³

✘ MYTH | Effective debridement requires specialist surgeon intervention.

✔ REALITY | The wound hygiene concept offers alternatives to surgical debridement, such as the combined use of gauze with cleansers, debridement pads and curettes. In appropriately trained hands, these can safely and effectively improve the condition of the wound and periwound skin.

Wound hygiene: stage 2—debride

Table 3. Debridement options		
Approach	Description	Key points
Surgical	Procedure performed in the surgical suite/ operating theatre, frequently under general, regional or local anaesthesia, using various surgical instruments to cut away tissue. ⁸	The patient's condition, the skill level required of the health professional and lack of reimbursement can limit referral for and implementation of surgical debridement. Removes tissue and disrupts biofilm at both the surface and in deeper tissues. ¹⁸
Sharp (curette, scalpel, scissors and forceps)	An often less-aggressive procedure that can be performed at the bed- or chairside. Using an aseptic technique, debris and devitalised tissue are physically removed with sharp instruments. ⁸	Removes superficial tissue and disrupts biofilm. ¹⁸ Effective in stimulating healing of hard-to-heal wounds. ¹⁹ Safe, well tolerated and can be performed in an outpatient setting. ¹⁹ Skills required of the health professional can limit implementation.
Larval* (also known as biosurgery)	Specific species of live maggots, raised and disinfected for patient use, are placed on devitalised tissue, where they secrete enzymes that liquify the tissue prior to ingestion; the maggots also secrete antimicrobial substances. ⁸	Disrupts the tissue-collagen matrix and exerts a bacteriostatic effect. ⁸ Promotes wound healing and amplifies human fibroblast and chondrocyte growth. ⁸ Good <i>in vitro</i> evidence of biofilm removal. ¹⁸

Continued opposite

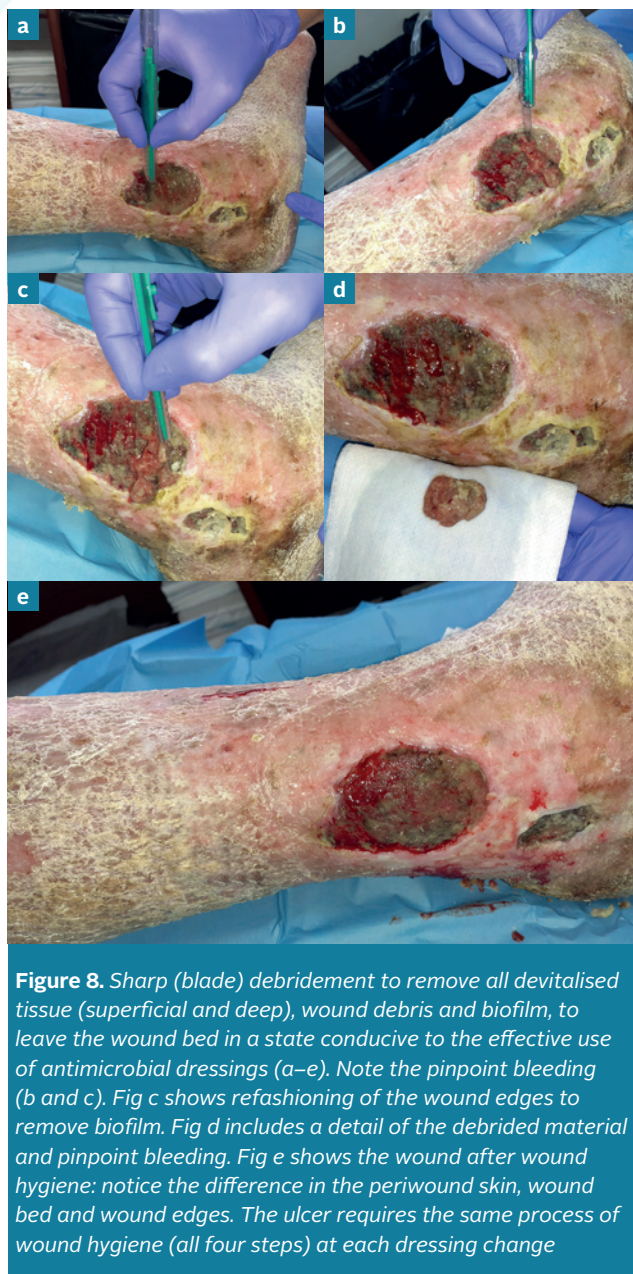


Figure 8. Sharp (blade) debridement to remove all devitalised tissue (superficial and deep), wound debris and biofilm, to leave the wound bed in a state conducive to the effective use of antimicrobial dressings (a–e). Note the pinpoint bleeding (b and c). Fig c shows refashioning of the wound edges to remove biofilm. Fig d includes a detail of the debrided material and pinpoint bleeding. Fig e shows the wound after wound hygiene: notice the difference in the periwound skin, wound bed and wound edges. The ulcer requires the same process of wound hygiene (all four steps) at each dressing change

✘ MYTH | Do not remove loose scales, scabs or slough, as healing is occurring underneath them.

✓ REALITY | Slough inhibits healing. Scales and scabs harbour microbes and so must be removed to promote healing.

Table 3. Debridement options (continued)

Approach	Description	Key points
Ultrasonic*	Direct application to the wound base of sound-wave energy, delivered from a device, which disrupts biofilm, induces light bleeding to stimulate growth factors, and improves granulation and local perfusion.	Can destroy, dislocate or physically modify tissue and biofilm. ⁸ Statistically significant reduction in bacterial load compared with surgical debridement after 6 weeks' follow-up. ²⁰ Exhibits some levels of disruption and biofilm removal, leaving behind a small amount of contaminants. ^{18,21}
Mechanical debridement*	Soft debridement pad, gauze or wipes to physically remove devitalised tissue, debris and organic matter.	Can be undertaken by all clinicians with minimal training. Exhibits some levels of disruption and biofilm removal. ¹⁸ Efficiently removes debris, slough, dried exudate and crusts without damaging the periwound skin. ²

* Types of biological debridement

† Types of mechanical debridement

Before using an antiseptic solution, if indicated, the wound might need to be swabbed and cultured. Box 2 describes how to do this.

References

- Gray D, Acton C, Chadwick P et al. Consensus guidance for the use of debridement techniques in the UK. *Wounds UK* 2010;6(4).
- Atkin L. Understanding methods of wound debridement. *Br J Nurs* 2014;23:S10-12, S14-15. <https://doi.org/10.12968/bjon.2014.23.sup12.S10>
- MacLeod AS, Mansbridge JN. The Innate Immune System in Acute and Chronic Wounds. *Adv Wound Care (New Rochelle)* 2016;5:65-78. <https://doi.org/10.1089/wound.2014.0608>
- Sharp A. Effective debridement in a changing NHS: A UK consensus. *Wounds UK* 2013;9(Suppl 1).
- Stewart PS. Biophysics of biofilm infection. *Pathog Dis* 2014;70:212-8. <https://doi.org/10.1111/2049-632X.12118>
- Malone M, Swanson T. Biofilm-based wound care: the importance of debridement in biofilm treatment strategies. *Br J Community Nurs* 2017;22:S20-5. <https://doi.org/10.12968/bjcn.2017.22.Sup6.S20>
- Schultz GS, Woo K, Weir D et al. Effectiveness of a monofilament wound debridement pad at removing biofilm and slough: ex vivo and clinical performance. *J Wound Care* 2018;27:80-90. <https://doi.org/10.12968/jowc.2018.27.2.80>
- Strohler R, Dissemond J, Jordan O'Brien J et al. EWMA document: Debridement. An updated overview and clarification of the principle role of debridement. *J Wound Care* 2013;22:5. <https://doi.org/10.12968/jowc.2013.22.Sup1.S1>
- Tyldesley HC, Salisbury A, Chen R et al. Surfactants and their role in biofilm management in chronic wounds. *Wounds International* 2019;10(1):20-24.
- Cunliffe PJ, Fawcett TN. Wound cleansing: the evidence for the techniques and solutions used. *Prof Nurse* 2002;18:95-9
- Bishop SM, Walker M, Rogers AA et al. Importance of moisture balance at the wound-dressing interface. *J Wound Care* 2003;12:125-8. <https://doi.org/10.12968/jowc.2003.12.4.26484>
- Wilcox JR, Carter MJ, Covington S. Frequency of debridements and time to heal: a retrospective cohort study of 312 744 wounds. *JAMA Dermatol* 2013;149:1050-8. <https://doi.org/10.1001/jamadermatol.2013.4960>
- Roy R, Tiwari M, Donelli G et al. Strategies for combating bacterial biofilms: A focus on anti-biofilm agents and their mechanisms of action. *Virulence* 2018;9:522-54. <https://doi.org/10.1080/21505594.2017.1313372>
- Schultz G, Bjarnsholt T, James GA et al. Consensus guidelines for the identification and treatment of biofilms in chronic nonhealing wounds. *Wound Repair Regen* 2017;25:744-57. <https://doi.org/10.1111/wrr.12590>
- Choo J, Nixon J, Nelson EA et al. Autolytic debridement for pressure ulcers. *Cochrane Database of Systematic Reviews* 2014. <https://doi.org/10.1002/14651858.CD011331>
- Kallstrom G. Are quantitative bacterial wound cultures useful? *J Clin Microbiol* 2014;52:2753-6. <https://doi.org/10.1128/JCM.00522-14>
- Snyder RJ, Bohn G, Hanft J et al. Wound Biofilm: current perspectives and strategies on biofilm disruption and treatments. *Wounds* 2017;29:S1-17
- International Wound Infection Institute (IWII). Wound infection in clinical practice: international consensus update 2016. *Wounds International* 2016.
- Williams D, Enoch S, Miller D et al. Effect of sharp debridement using curette on recalcitrant nonhealing venous leg ulcers: a concurrently controlled, prospective cohort study. *Wound Repair Regen* 2005;13:131-7. <https://doi.org/10.1111/j.1067-1927.2005.130203.x>
- Van Acker K, Braumann C, Gächter B et al. Report of a closed panel meeting on ultrasound-assisted wound debridement. *J Wound Care* 2020;In press.
- Granick MS, Paribathan C, Shanmugam M et al. Direct-contact low-frequency ultrasound clearance of biofilm from metallic implant materials. *Eplasty* 2017;17

Wound hygiene: stage 3—refashion the wound edges

In all full-thickness wounds, the primary cells that facilitate epithelialisation are located at the wound edges and hair follicles. Biofilm is most active at the wound edges, where it promotes cell senescence (loss of cells' power of division and growth), thereby preventing the ingrowth of new, healthy tissue. Refashioning the wound edges is therefore an important component of wound hygiene.

Refashioning goes one step further than decontaminating the wound edges and removing devitalised tissue, as it uses debridement in the form of sharp debridement or soft debridement pads or gauze to agitate the wound edges to the extent that pinpoint bleeding occurs, where local practice, patient tolerance and consent allow it. Refashioning the wound edges usually presents little risk to the tissue, which naturally regenerates as part of the healing process. The agitation will stimulate the expression of growth factors to kickstart the formation of healthy skin.

Practical tips for refashioning

Biofilm has been observed at the wound edges.¹ The bioburden within the periwound skin, particularly in devitalised tissue, affects the bioburden in the wound and, therefore, its edge.² Clinical evidence for this is presented by panel member, Randy Wolcott. In his practice, the advanced molecular biology technique, polymerase chain reaction (PCR), has consistently identified a higher number of bacterial cells on wound tissue samples from the wound edges than from the centre.

Refashioning the edges to remove devitalised tissue (and thus biofilm) will promote healing. One way to visualise how much tissue to remove at the wound edges is to think about 'cliffs' and 'beaches'. Low-lying beaches need a little scratching to make them smooth, whereas cliffs need some cutting to smooth them out. In Wolcott's clinical

experience, normal skin regrows as healthy tissue in 7–14 days (Figures 9 and 10). Wolcott says a key tip is to pay particular attention to surfaces that touch the wound bed, such as where there is slight undermining or loosely attached epithelial tissue, as they, in particular, harbour biofilm. More detail on refashioning the wound edges is given in Figures 11–13.

Contraindications for refashioning the wound edges are the same as those for debridement described on page S14. If in doubt about mechanically debriding the wound edges to pinpoint bleeding, refer to a more specialist practitioner.

References

1. Bay L, Kragh KN, Eickhardt SR et al. Bacterial aggregates establish at the edges of acute epidermal wounds. *Adv Wound Care (New Rochelle)* 2018;7:105–13.
2. Tomic-Canic M, Ayello EA, Stojadinovic O et al. Using gene transcription patterns (bar coding scans) to guide wound debridement and healing. *Adv Skin Wound Care* 2008;21:487–92; quiz 493–4.
3. Edmonds ME, Foster AVM. Diabetic foot ulcers. *BMJ* 2006;332:407–10

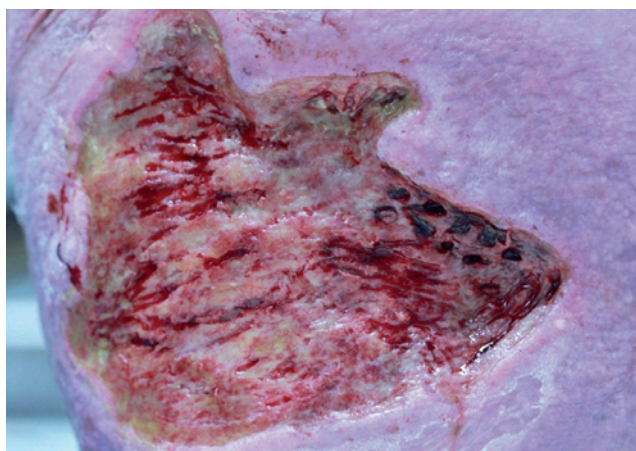


Figure 9. Wound at presentation: a biopsy has been taken at the wound edges

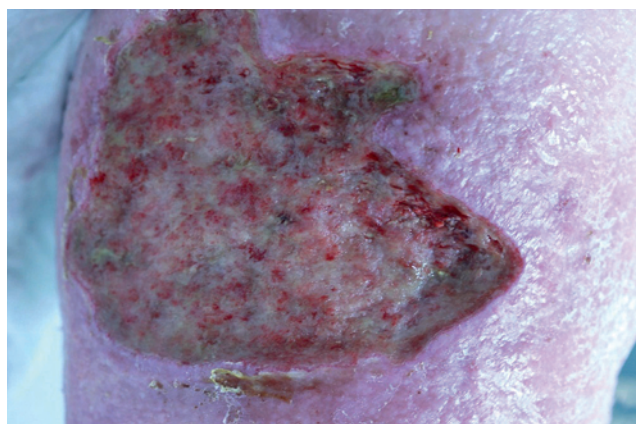


Figure 10. Same wound 12 days later: the tissue from the biopsy area has healed quickly, despite being within the wound edges

Wound hygiene: stage 3—refashion the wound edges

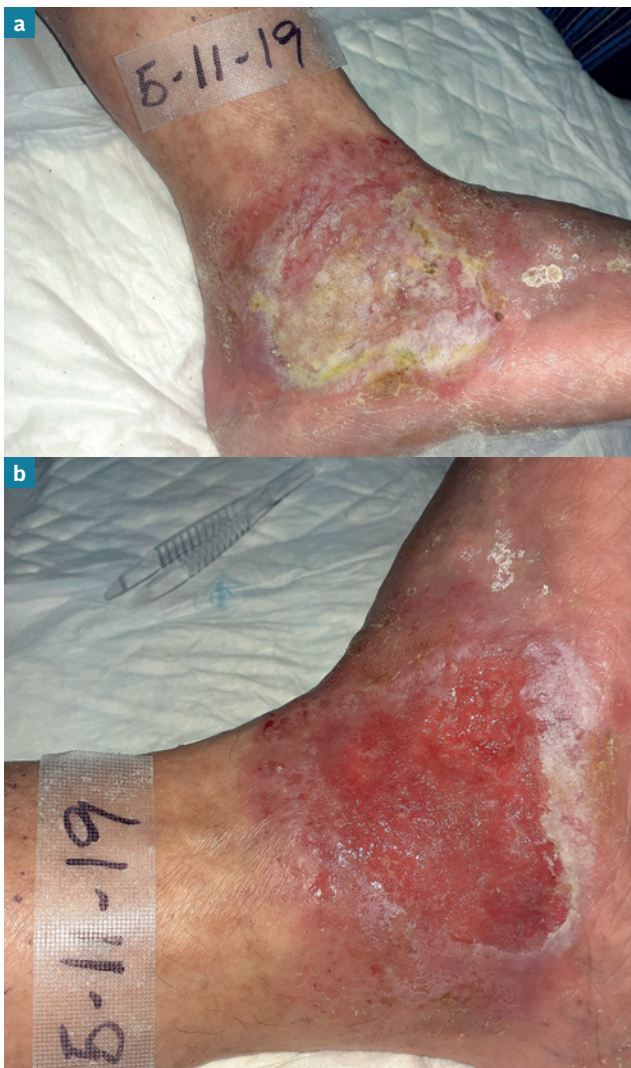

Figure 11. Venous leg ulcer before (a) and after (b) wound hygiene. There is debris on the wound bed, scales and some exudate on the periwound skin pre-wound hygiene (a). During wound hygiene, the periwound area was cleansed, and skin scales and exudate were removed. Similarly, all exudate and debris were removed from the wound bed, leaving good, vital granulating tissue. The wound edges were also debrided and refashioned, aiding epithelialisation

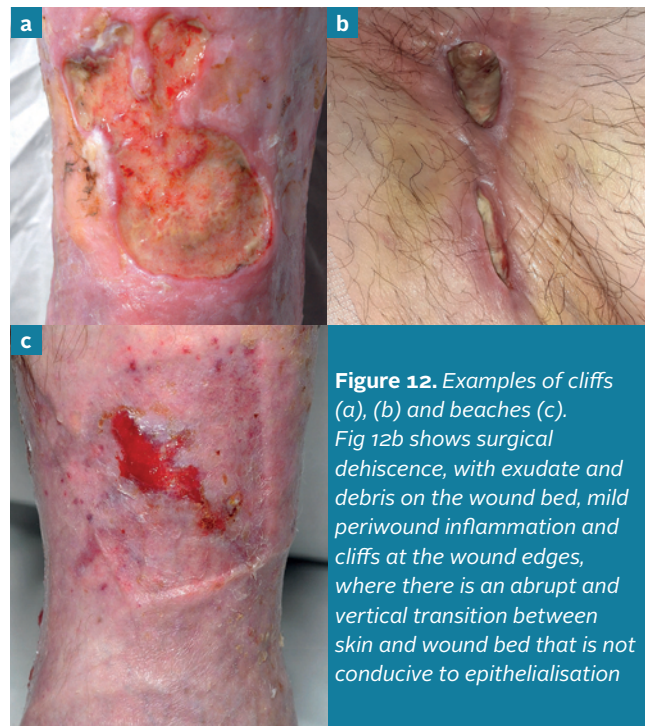

Figure 12. Examples of cliffs (a), (b) and beaches (c). Fig 12b shows surgical dehiscence, with exudate and debris on the wound bed, mild periwound inflammation and cliffs at the wound edges, where there is an abrupt and vertical transition between skin and wound bed that is not conducive to epithelialisation

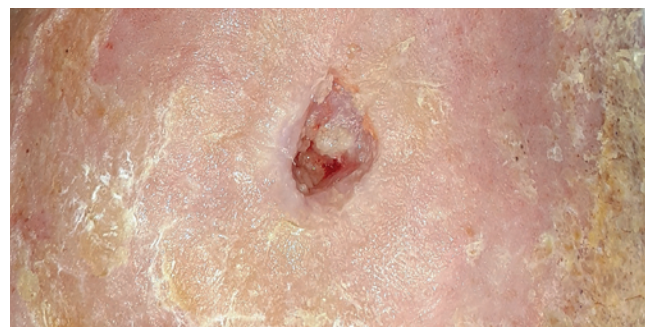


Figure 13. Small ischaemic ulcer after revascularisation: it has both cliffs and beaches. In the upper half of the wound, the granulating wound bed and edges represent beaches, where there are signs of epithelialisation and a smooth transition to the periwound skin. In the bottom half, there is a blunt and vertical transition between the wound and periwound skin (cliffs) that is more resistant to epithelialisation. (The periwound skin debris still needs to be removed)

It is also necessary to remove hyperkeratosis or callus around hard-to-heal wounds. This principle is seen in diabetic foot ulcers, where standard practice has long been to remove callus and crust as part of wound bed preparations³

Wound hygiene: stage 4—dress the wound

After the wound bed and periwound skin have been cleansed, the wound bed has been debrided and the wound edges refashioned, there is a window of opportunity in which to address any residual biofilm that might be present and prevent its re-formation. To maximise this, antimicrobial dressings can be used, when indicated following a holistic assessment.

✘ MYTH | Antimicrobial dressings should only be used for a maximum of 2 weeks.

✓ REALITY | Use of an antimicrobial dressing should be assessed at a minimum of every 2 weeks to determine if continued application remains clinically appropriate. However, antibiofilm strategy (in the form of wound hygiene) needs to be implemented for the duration of the wound healing trajectory.

Optimising the skin

Before applying a wound dressing, the skin should be clean and dry, and steps taken to maintain or protect the health of the periwound skin—for example, by applying a moisturiser or barrier cream, if indicated by a holistic assessment. When using an adhesive dressing, allow time for the moisturiser to absorb into the skin to aid adhesion.

Using antimicrobial wound dressings

The previous stages of wound hygiene clear the barriers to wound healing, helping an antimicrobial dressing to achieve maximum efficacy.¹ Some antiseptics used in antimicrobial wound dressings may play an important role in wound hygiene, as they can help to disrupt biofilm, kill organisms within the biofilm and prevent its re-formation through different modes of action. It is important to be able to differentiate between antimicrobials and antibiofilm agents. When incorporated into dressings, antimicrobials will kill planktonic bacteria, preventing colonisation and biofilm formation, which may facilitate antimicrobial effectiveness. Antibiofilm agents are designed to penetrate and disrupt the biofilm itself. Antimicrobial and antibiofilm agents are described in Table 4.

When choosing an antimicrobial dressing, its antibiofilm properties should be considered, along with other requirements, such as its exudate management capabilities. Before choosing a dressing, a comprehensive assessment of the patient and the wound bed and environment should be conducted to ensure it meets the needs of the patient and the local wound environment. The volume of exudate production should be a key consideration, as excess exudate levels can encourage the spread of biofilm, and impair cell proliferation and wound healing.²

Taking a step-up/step-down approach

Although all wounds deserve wound hygiene as standard care, not all wounds require more aggressive forms of debridement, refashioning or a topical antimicrobial dressing. A step-up/step-down approach should be taken to ensure that antimicrobial dressings are only used when required. This will, in turn, increase the cost-effectiveness of management.

It is important to assess the wound and the effectiveness of the dressing every 2–4 weeks, using a validated or standardised assessment tool, to determine whether it is necessary to step down to a non-antimicrobial dressing because the wound is progressing towards healing, or to try another dressing because the wound has stalled.^{3,4} If the wound assessment indicates there is no longer a need for antimicrobial dressings, the other three aspects of wound hygiene should continue to be administered at each dressing change until the wound is in the final stages of wound healing. Dressing selection should also be made in the context of local protocols, dressing availability and any existing socioeconomic constraints faced by patients.

References

1. Percival SL, Mayer D, Kirsner RS et al. Surfactants: Role in biofilm management and cellular behaviour. *International Wound Journal* 2019;16:753–60. <https://doi.org/10.1111/iwj.13093>
2. Percival SL, McCarty SM, Lipsky B. Biofilms and Wounds: An Overview of the Evidence. *Adv Wound Care (New Rochelle)* 2015;4:373–81
3. Schultz G, Bjarnsholt T, James GA et al. Consensus guidelines for the identification and treatment of biofilms in chronic nonhealing wounds. *Wound Repair Regen* 2017;25:744–57. <https://doi.org/10.1111/wrr.12590>
4. Omar A, Wright JB, Schultz G et al. Microbial biofilms and chronic wounds. *microorganisms* 2017;5. <https://doi.org/10.3390/microorganisms5010009>
5. Kamaruzzaman NF, Chong SQ, Edmondson-Brown KM et al. Bactericidal and anti-biofilm effects of polyhexamethylene biguanide in models of intracellular and biofilm of staphylococcus aureus Isolated from bovine mastitis. *Front Microbiol* 2017;8:1518. <https://doi.org/10.3389/fmicb.2017.01518>
6. Oduwole KO, Glynn AA, Molony DC et al. Anti-biofilm activity of sub-inhibitory povidone-iodine concentrations against *Staphylococcus epidermidis* and *Staphylococcus aureus*. *J Orthop Res* 2010;28:1252–6
7. Hoekstra MJ, Westgate SJ, Mueller S. Povidone-iodine ointment demonstrates in vitro efficacy against biofilm formation. *Int Wound J* 2017;14:172–9
8. Chaw KC, Manimaran M, Tay FEH. Role of silver ions in destabilization of intermolecular adhesion forces measured by atomic force microscopy in *Staphylococcus epidermidis* biofilms. *Antimicrob Agents Chemother* 2005;49:4853–9. <https://doi.org/10.1128/AAC.49.12.4853-4859.2005>
9. Silvestry-Rodríguez N, Bright KR, Slack DC et al. Silver as a residual disinfectant to prevent biofilm formation in water distribution systems. *Appl Environ Microbiol* 2008;74:1639–41. <https://doi.org/10.1128/AEM.02237-07>
10. Cavanagh MH, Burrell RE, Nadworny PL. Evaluating antimicrobial efficacy of new commercially available silver dressings. *Int Wound J* 2010;7:394–405
11. Sharma BK, Saha A, Rahaman L et al. Silver inhibits the biofilm formation of *Pseudomonas aeruginosa*. *Advances in Microbiology* 2015;5:677–85
12. Walker M, Metcalf D, Parsons D et al. A real-life clinical evaluation of a next-generation antimicrobial dressing on acute and chronic wounds. *J Wound Care* 2015;24:11–22. <https://doi.org/10.12968/jowc.2015.24.11>
13. Said J, Walker M, Parsons D et al. An in vitro test of the efficacy of an anti-biofilm wound dressing. *Int J Pharm* 2014;474:177–81

Table 4. Topical antimicrobial and antibiofilm agents commonly used in wound dressings*

Agent	Evidence for antimicrobial/antibiofilm action
Polyhexamethylene biguanide (PHMB)	<ul style="list-style-type: none"> ■ The antimicrobial activities of PHMB were tested against intracellular <i>Staphylococcus aureus</i> in infected host cells.⁵ Results showed that it: <ul style="list-style-type: none"> ■ Killed 99.9% of intracellular <i>S. aureus</i>⁵ ■ Might interact with the bacteria inside the host cells⁵ ■ Reduced biofilm mass by 28–37%⁵ ■ Was tolerated by host cells at high concentrations⁵ ■ Was more effective against intracellular <i>S. aureus</i> than the antibiotic⁵ enrofloxacin.
Povidone iodine	<ul style="list-style-type: none"> ■ Povidone-iodine exhibits antibiofilm activity against <i>Staphylococcus epidermidis</i> and <i>S. aureus</i> at sub-inhibitory concentrations.⁶ ■ Inhibition of biofilm by povidone-iodine correlated with gene transcription processes that repressed reproduction of <i>S. epidermidis</i>.⁶ ■ No viable <i>Pseudomonas aeruginosa</i> biofilm material was recovered after 4 and 24 hours of management with a povidone-iodine ointment at 100% and 10% concentrations.⁷ ■ No <i>Candida albicans</i>/meticillin-resistant <i>Staphylococcus aureus</i> (MRSA) biofilm material was recovered after 4 and 24 hours of management with a povidone-iodine ointment at the 100% concentration.⁷ ■ Even after dilution to 3.3% and 33.3%, the povidone-iodine ointment appeared to exhibit greater biofilm removal than other agents tested by the researchers.⁷
Silver	<ul style="list-style-type: none"> ■ Atomic force microscopy studies suggest that the way silver ions bind to the bacteria destabilises sessile (immobile) <i>S. epidermidis</i> biofilm matrix.⁸ ■ In experiments comparing silver with a control on plastic and stainless steel surfaces, there were no significant differences in biofilms between silver and a control, although in some cases biofilms formed more rapidly with the control than with silver.⁹ ■ A laboratory study of six silver-containing dressings found: (1) only a nanocrystalline silver dressing was bactericidal against <i>S. aureus</i>; (2) a silver collagen matrix dressing was the only other dressing with a log reduction; (3) these two dressings and a silver alginate dressing produced zones of inhibition; and (4) the remaining dressings (two ionic silver foam dressings and a silver sulphate dressing) did not produce zones of inhibition.¹⁰ ■ Silver exhibits considerable antimicrobial property against <i>P. aeruginosa</i>, with a minimum inhibitory concentration (MIC) of 25µg/ml.¹¹ ■ In a real-life, non-randomised evaluation involving 113 patients with hard-to-heal wounds managed with standard care plus a silver-containing dressing, 71 wounds (63%) achieved at least 75% closure, 47 (42%) achieved at least 90% closure, and 19 wounds (17%) healed within the 4-week follow-up period.¹² Approximately three-quarters of the sample had a suspected biofilm, as determined by the investigators, although all would be considered hard-to-heal, as defined by the concept of wound hygiene.
Silver-ethylenediaminetetraacetic acid (EDTA)-benzethonium chloride (BC)	<ul style="list-style-type: none"> ■ The efficacy of silver + EDTA + BC was demonstrated using a biofilm model.¹³ ■ The biofilm remained viable in the presence of unmedicated dressing, silver-containing dressing or silver nitrate solution.¹³ ■ In the presence of silver + EDTA + BC combination, the biofilm was eradicated.¹³ ■ Alone, EDTA and BC did not kill bacteria, meaning the combination of the three agents leads to biofilm eradication.¹³

* This table focuses on antimicrobial agents, not dressing categories, as the vehicle/dressing structure can significantly influence how the agent is made available in the wound.

Implementing wound hygiene

All wounds, particularly hard-to-heal ones, will benefit from wound hygiene (Figure 14), which should be instigated at the first referral, following a full holistic assessment to identify the wound aetiology and comorbidities, and then implemented at every dressing change until full healing occurs. All aspects of the wound hygiene approach are listed in Box 3.

Wound hygiene can be safely implemented in any setting

Wound hygiene can be safely practised by specialist and generalist health professionals (Table 5 and Box 4). It should be applied in all settings, from postoperative to outpatients, GP practices and post-acute community practices (Table 6). As there are multiple methods of debridement to choose from, wound hygiene can be implemented by generalists and non-skilled health workers, provided the method chosen meets the wound's and patient's needs. Implementation involves consecutive application of all four stages and their various components. And yet members of the panel have found that, within their practice, wound

Box 3. Wound hygiene checklist

- Holistic assessment of the patient, wound and environment.
- Implement pain management as needed, in consultation with a specialist and/or anaesthetist, before and during the process.
- Cleanse the periwound skin.
- Cleanse the wound bed.
- Gain patient consent for debridement, in accordance with local policy.
- Ensure the underlying wound pathology does not contradict mechanical debridement.
- Conduct wound debridement in accordance with local policy.
- Cleanse both pre- and post-debridement.
- Refashion the wound edges.
- Select an appropriate dressing.
- Apply an appropriate dressing.
- When in doubt, refer!**

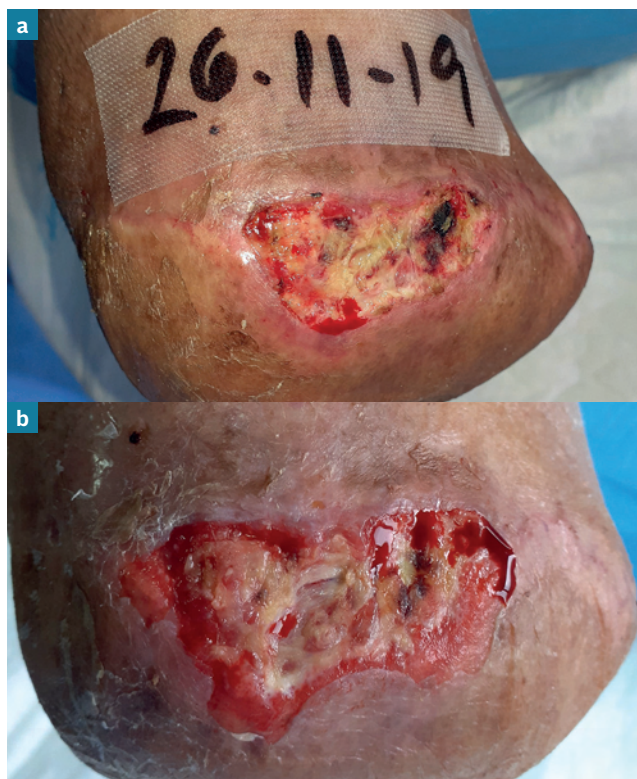


Figure 14. Evolution of an ulcer managed with wound hygiene at every dressing change: after one week (b), there is a significant reduction in the amount of wound debris (and thus biofilm present), with a satisfactory increase in the amount of granulation tissue present on the wound bed, and signs of healing at the wound edges

hygiene can easily be carried out within a 10-minute patient consultation. Figure 15 depicts implementation of wound hygiene, as demonstrated by Dr Wolcott.

Anticipated benefits

The benefits of wound hygiene are expected to include lower rates of infection and chronic inflammation, as well as faster and higher healing rates. This could reduce

Table 5. Implementation of wound hygiene by clinical competency*

Skill level	Wound hygiene tasks
Unregistered/little or no wound training or certification	<ul style="list-style-type: none"> ■ Cleansing the wound bed and periwound skin. ■ Debridement of the wound bed and periwound skin with a soft pad or gauze. ■ Refashion the wound edges with a soft pad or gauze. ■ Assessing for signs of infection. ■ Application of a wound dressing.
Registered/some training in wound care	<ul style="list-style-type: none"> ■ Holistic assessment of the patient, wound (including vascular supply and infection status) and environment. ■ Sharp debridement of non-viable tissue (and ability to determine when it is appropriate). ■ Ultrasonic debridement. ■ Larval therapy. ■ Refashion the edges to achieve pinpoint bleeding. ■ Identification of local and spreading infection. ■ Selection and application of an appropriate dressing.
Expert/advanced (certified wound specialist, surgeon or other specialist consultant)	<ul style="list-style-type: none"> ■ Diagnosis and management of the underlying pathophysiology. ■ Pharmacotherapy, as required. ■ Selecting and undertaking an appropriate method of debridement (e.g. surgical sharp debridement). ■ Refashioning the wound edges. ■ Suturing, if required. ■ Selection and application of an appropriate dressing.

* Providers should follow their competencies and capabilities as determined by their local protocols, regulatory body, legal liability and local governing bodies.

Table 6. Implementation of wound hygiene by clinical settings

Setting	Wound hygiene tasks
Care or nursing home	<ul style="list-style-type: none"> ■ Showering to reduce the overall body microbial load. ■ Cleansing the wound bed and periwound skin using a surfactant or pH-balanced solution and dedicated sterile gauze. ■ Using a dedicated foot sink, washing under the shower head. ■ Debridement with a soft pad or gauze. ■ Refashioning the wound edges with soft pad or gauze. ■ Application of an appropriate dressing.
Community/patient's home	<ul style="list-style-type: none"> ■ Holistic assessment. ■ Cleansing the wound bed and periwound skin using a surfactant or pH-balanced solution. ■ Debriding the wound bed and periwound skin (e.g. with a curette). ■ Refashioning the wound edges. ■ Application of an appropriate dressing.
Outpatient/inpatient specialist	<ul style="list-style-type: none"> ■ Holistic assessment. ■ Diagnosing and managing the underlying pathophysiology. ■ Cleansing the wound bed and periwound skin with a surfactant or pH-balanced cleanser. ■ Debridement of the wound and periwound skin. ■ Other types of mechanical debridement or sharp (surgical, curette, ultrasonic) debridement. ■ Achieving pinpoint bleeding. ■ Refashioning the wound edge. ■ Selection and application of an appropriate dressing.

A moisturiser, barrier cream or topical steroid may be applied to maintain skin health

Implementation

the current high levels of antibiotic usage, as well as the need for ancillary services and more intensive medical management, including amputations. As well as freeing up health resources and lowering costs spent on wound care, wound hygiene might ease both the financial and psychosocial impacts on patients. Finally, the change from wound transaction to wound interaction offers a chance to achieve the goal of providing truly holistic, person-centred wound care.

Reference

1. Percival SL, Mayer D, Kirsner RS et al. Surfactants: Role in biofilm management and cellular behaviour. *International Wound Journal* 2019;16:753–60. <https://doi.org/10.1111/iwj.13093>

✘ MYTH | Antimicrobial dressings should be used only on infected wounds.

✔ REALITY | Antimicrobial dressings can be used to address microbial colonisation and residual biofilm, and to prevent biofilm re-formation in wounds assessed as hard-to-heal.

Box 4. Real-world evidence: Leanne Atkin's experience of implementing wound hygiene at a wound care unit in an UK NHS trust

Wound hygiene was implemented in a wound care unit in an NHS trust in May 2019.

Pre-implementation

Wounds were cleansed with water, with *ad hoc* use of soft debridement pads only if physical debris was visible. If loose necrotic tissue or thick slough was present, wounds were sharp debrided; superficial slough and fibrin were removed using autolytic debridement. The condition of the wound edges was simply observed and documented, with no further action taken. For all patients, the wound aetiology was assessed, and gold standard care, such as compression, offloading and revascularisation, given. Dressing selection was based on the TIMERS paradigm.

Wound outcomes before wound hygiene

Anecdotally, a large proportion of patients in the unit had wounds that remained static, and there was a high occurrence of *Pseudomonas* infection.

Implementation

Three staff in the unit were trained to implement wound hygiene. They all had received prior training on sharp debridement, but, despite some experience, they still lacked the confidence to use a blade. As part of introducing wound hygiene, they were taught how to use a curette. Within 2 weeks, they were fully confident about debriding wounds with this instrument.

Post-implementation

Following implementation of wound hygiene in the unit, it has become standard practice to cleanse the wound bed and periwound skin with wound wipes/skin-cleansing wipes, to debride any devitalised tissue with a curette and to refashion the wound edges, as required, at each dressing change. The only scenario in which the curette is not used is when there is 100% granulation tissue on the wound bed, with perfect 'beach' edges. After this, the health professional decides whether or not an antimicrobial dressing is required, based on the wound characteristics.

Wound outcomes after implementation of wound hygiene

Some 35 patients are managed in the unit each week. The percentage of hard-to-heal wounds has reduced to <5%. Pre-implementation, there were 3–5 cases of *Pseudomonas* infection in the clinic each week; post-implementation, this has reduced to 1 or 2 per month.

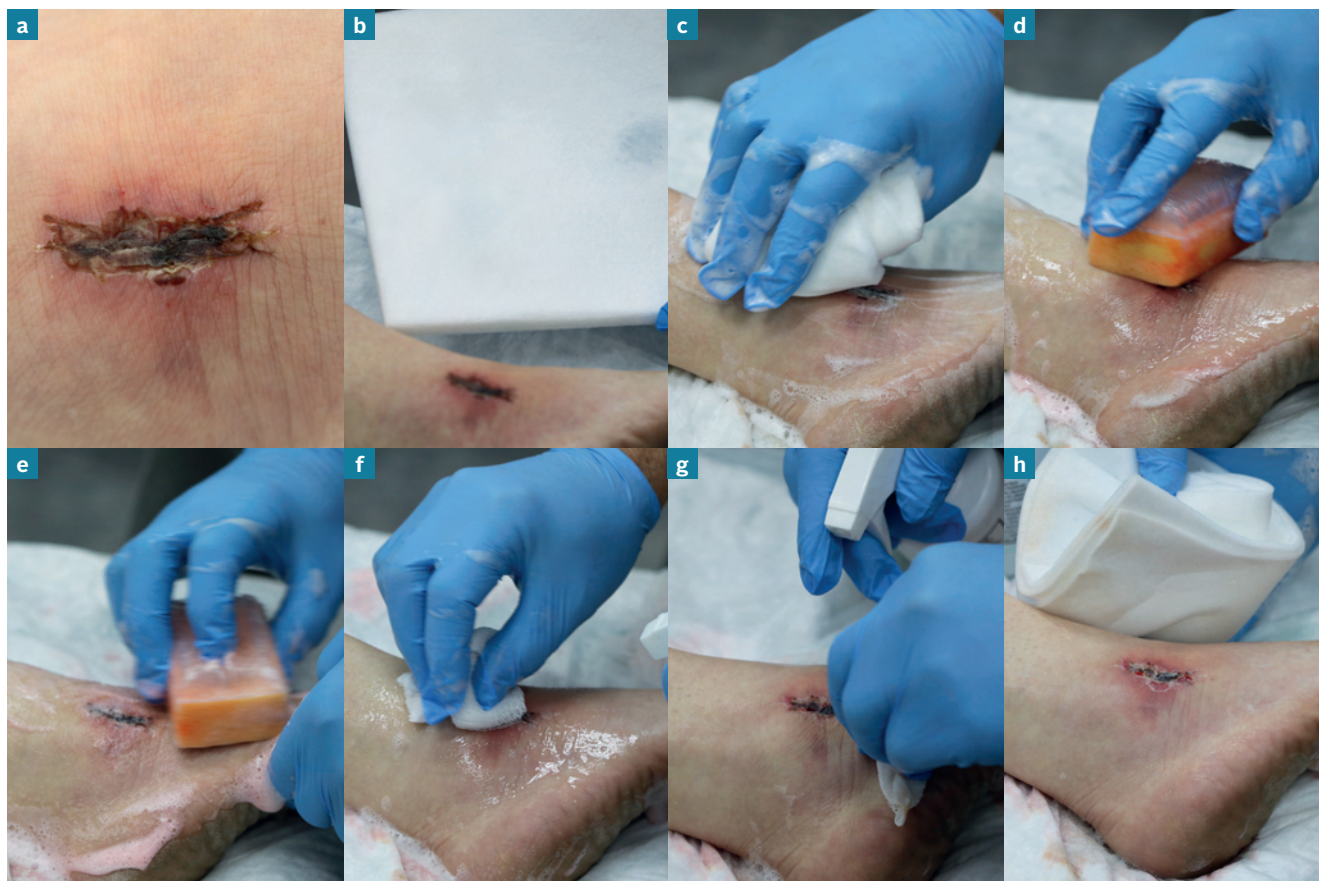

Figure 15. Implementation of wound hygiene, as demonstrated by Randy Wolcott.

At presentation, the wound is covered with eschar (dead and desiccated skin tissue), which contains biofilm (a).

A foam sponge impregnated with an approved surfactant is an excellent choice for removing scale and eschar due to its ability to apply, hold and agitate fluids over the wound (b). The sponge is soaked in a large amount of warm water and wiped over the wound for several minutes to solubilise any adherent tissue. Next, a second foam sponge is soaked in the water and then used to cleanse the periwound skin aggressively to beyond the area that will be covered by a wound dressing, as this will be seeded with numerous packets of detached biofilm. Finally, a third sponge is used to aggressively remove any remaining material, which by now is hydrated after having been soaked (c).

If the condition of the wound bed and periwound skin is such that a more aggressive tool is required, or if dry material, especially eschar, is present, a surgical scrub brush can be considered (d and e). However, a surgical brush may require local anaesthesia and it will also remove viable host tissue, but this will quickly repair itself. Remember: the goal is to remove biofilm as completely and frequently as possible. Using a surgical scrub brush along with an antiseptic may dry the periwound skin, making it helpful to moisturise it. Antiseptics are only minimally effective against biofilm fragments that seed the skin,⁹ so it is better to scrub with surfactants to remove and disrupt the biofilm.

Gauze is an effective substitute to a sponge (f). Additional fluid needs to be added to the gauze almost constantly, and it will soon need to be replaced with a fresh piece of gauze depending on the amount of devitalised tissue it collects. The wound can be scrubbed with gauze until there is pinpoint bleeding or no adherent devitalised tissue is present (g). If the patient finds this too painful, the current session of wound hygiene should be stopped, to be resumed another time. Topical anaesthetics can be considered in such cases.

In this case, most of the eschar was easily removed with soaking and gentle scrubbing (h). A stiffer surgical scrub removed most of the rest, causing minimal pain

Consensus statements summary

General

1. Wound hygiene is a fundamental aspect of care for all patients with an open wound.
2. It should be assumed that all hard-to-heal wounds contain biofilm.
3. Non-healing should be regarded as a pathology that can be successfully addressed with the right tools, provided that the underlying aetiology is managed with gold standard care.
4. Wounds should be triaged by level of risk, regardless of their duration.
5. Wound hygiene should be performed at every dressing change.
6. The skills, materials and time required to carry out wound hygiene make it a cost-effective approach, especially given its potential to promote faster healing.
7. Assess and manage the patient's pain expectations.
8. Even if the wound does not 'look' like it has biofilm, wound cleansing must be a priority.

Cleanse

9. When cleansing the periwound skin, concentrate on the area that is 10–20 cm away from the wound edges, or that is covered by the dressing, whichever is larger.
10. Use an antiseptic wash or surfactant for cleansing, if possible, and avoid cross-contamination.

Debride

11. Debridement is an integral part of wound hygiene; the choice of method should be based on assessment of the wound bed, periwound skin and patient tolerance.
12. Any instrument used for debridement must be sterile.
13. To avoid risk of injury, exercise caution when considering debriding lower extremity wounds in patients with poorly perfused limbs and autoimmune conditions, such as pyoderma gangrenosum.

Refashion the wound edge

14. Wound bed fragility is rarely an issue: removing all devitalised and even some healthy tissue from the wound edges will result in regrowth of healthy tissue.
15. Any undermining, no matter how slight, needs to be addressed either by loosely packing with a dressing material or refashioning the wound edges.

Dress the wound

16. By disrupting and clearing biofilm, and preventing its re-formation, wound hygiene is expected to reduce the risk of infection. This could, in turn, reduce antibiotic usage in wound care.
17. Antimicrobial dressings alone are not sufficient to disrupt and remove biofilm. They should be used as an adjunct to address residual biofilm and prevent its re-formation. This can only be done if effective wound hygiene is carried out.
18. Biofilm is heterogeneous. Antimicrobial dressings are one part of a strategy for preventing biofilm re-formation. Effective suppression may require alternating antimicrobial dressings. Re-assess dressing choice and make adjustments, as needed, based on the wound's progression towards healing and local availability of dressings.

JWC International
Consensus Document