

A Case Study of Chronic Wound Management

by

Al E. Roberts CRRN, CWCA, DMT-A, FACCWS

Nutrition & Wound Specialist

Educator

This case presents with an 86-year-old female patient with a chronic wound on the left lateral ankle, present for over 11 years. She has a history of heart disease with HTN, IDDM I, CKD, PVD, Obesity, Black Race and uncontrolled, chronic, pitting edema with neuropathy in both legs. Amputation was a common end conversation from her visits at the wound centers.

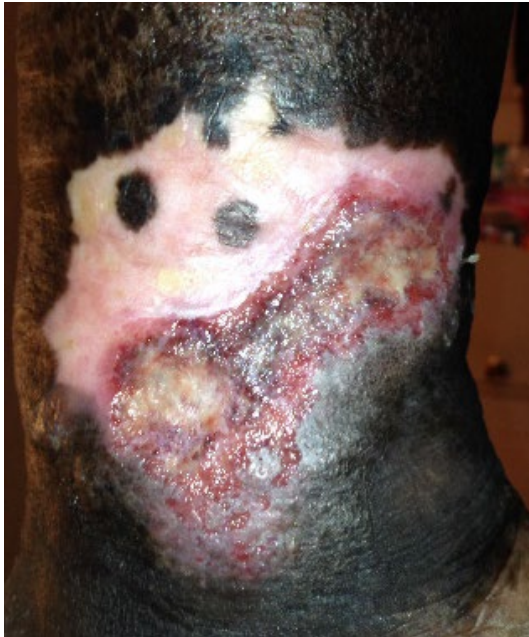She had previously received wound care from several local wound centers over the last decade. She also had home health nursing providing wound care, most of which were daily dressing changes. They were all able to improve her wound to different levels but none able to completely resolve it.

Completing a holistic assessment and working with the PCP, I was able to quickly get her on the right track to resolving her wound. She and her daughter, primary caregiver, had a knowledge deficit related to her wound and the causative factors preventing it from healing. Her diet and nutritional intake were minimal and less than normal body requirements. She did not eat fruits nor vegetables every day and only ate one meal most days. After 11 years of being tossed around in the wound care field of medicine, the patient nor the daughter remember being educated on edema and how it relates to her non-healing wound. Likewise, they were not educated on having an adequate nor a high protein diet for normal body requirements and for wound healing. The daughter remembers being told a time or two that her mom needed to eat more protein, but she thought her diet was ok.

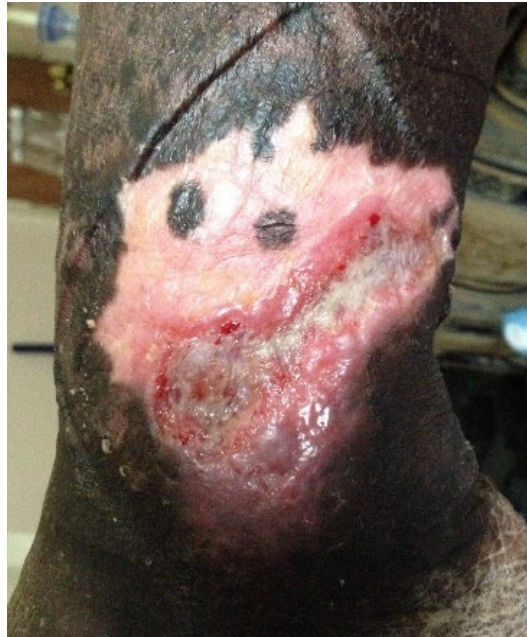The patient and daughter were educated on how and why to manage her chronic edema for proper treatment of her wound. Maintaining her edema will also help prevent wound formation in the future. They were instructed on ways to improve her nutritional intake and even given daily goals for fluid and protein intake. Instruction was given on the DASH diet with an increase protein intake. Nutritional supplements and vitamin and mineral supplements were discussed for assistance in meeting her nutritional goals.

Wound Treatment


The wound took a total of 50 days to resolve, in only 12 visits. Oral and topical antibiotics were used at the beginning of the treatment based on a positive wound culture collected on initial assessment. Polymem foam dressing was the primary dressing used for most of the treatment. Compression therapy was a mainstay in her treatment to manage her chronic edema. She was transitioned into compression stockings at the end of her treatment.




06/05/14



06/13/14




06/22/14



06/26/14



07/02/14



WOUND RESOLVED

07/14/14

Summary

Holistic wound management includes more than just trying to find a dressing to heal a wound. Too often nutritional evaluation is left out of the mix subsequently causing patients to fail. Some providers instruct their patients to “eat more protein.” But if a patient doesn’t believe their diet needs improving, why would they eat more protein?

They Don’t!

Patients want to get better. It’s our job to show them the way.

Feed the Body, Feed the Mind and Feed the Soul with a Healing Wound

Al E. Roberts CRRN, CWCA, DMT-A, FACCWS

Nutrition & Wound Consulting & Education

Jacksonville, FL

thewoundguru.com – healthtoheal.org