

Elimination of High-grade Gliomas Through Induced Cytolysis, Elucidated by Two Patient Cases

CHRISTOS PANOTOPOULOS¹, GEORGE ATHANASIOU¹, STAVROS STAVROPOULOS¹, NICK BOUTOS¹,
SHAILESH RAO², GEORGE PANAYOTOU³, NEELAM K. VENKATARAMANA⁴ and GUNNAR RONQUIST⁵

¹Neurosurgical Department, Mediterraneo Hospital, Glyfada, Greece;

²St. John's National Academy of Health Sciences, Bengaluru, India;

³Biomedical Sciences Research Center "Alexander Fleming", Vari, Greece;

⁴Brains Super Specialty Hospital, Bengaluru, India;

⁵Department of Medical Sciences, Clinical Chemistry, University of Uppsala, Uppsala, Sweden

Abstract. *Background/Aim:* Glioblastoma multiforme (GBM) is the most common and aggressive form of primary malignant tumors in the central nervous system of adults. In practice, all patients with GBM experience relapse, and treatment options become limited following first-line therapy. We previously reported a new, successful treatment approach for a GBM patient, implemented in direct conjunction with surgical intervention. *Case Report:* Here, we present an additional case demonstrating the success of this protocol, along with an overview of its underlying rationale and mechanisms. Following maximal safe tumor resection, our protocol involves the placement of two catheters in the tumor excision bed, connected to drug infusion pumps for continuous administration. The tumor's excision beds are irrigated for 90-120 hours with a slightly alkaline Tris-buffered solution containing L-2,4 diaminobutyric acid, an unnatural amino acid, and Prazosin, a proapoptotic drug widely used as an antihypertensive. Both patients demonstrated marked clinical improvement. Recent contrast-enhanced magnetic resonance imaging revealed no evidence of malignancy, with Case 1 remaining disease-free for seven years and Case 2 for two years of follow-up. *Conclusion:* This innovative approach not only enhances local drug delivery but also minimizes systemic side effects, addressing a critical challenge in GBM treatment. These cases highlight

the potential of this protocol as an adjunct to standard therapies, offering a promising option for managing inoperable or recurrent GBM.

Glioblastomas (glioblastoma multiforme; GBM, WHO grade IV glioma) are the most common malignant primary brain tumors in adults. They arise from glial cells and cause problems for both physicians and patients due to their heterogeneous histology, high invasive capacity, and rapid postsurgical recurrence, notwithstanding full surgical resection followed by combined radiation and alkylating chemotherapy (1, 2). GBM displays distinct characteristics in its intrinsic aggressive behavior and unresponsiveness to therapy. The main "ambition" of GBM cells, similarly to other cancer cells, is to reproduce through cell division (mitosis) that in turn requires an enhanced rate of protein synthesis in comparison with normal cells. Amino acids serve as the building blocks for this synthesis, and as malignancy increases, so does the cell's need to accumulate amino acids intracellularly.

Amino Acid Transport into Human Glia and Glioma Cells

Our previous study concerning the mode of transport of selected amino acids (both physiological and non-physiological) into human glia (normal) and human glioma (highly malignant) cells revealed on comparison an almost 400% higher uptake capacity of selected amino acids by malignant glioma cells (3). The uptake of amino acids into cells is regulated by the chemical constitution of each amino acid and varies according to cell type (4-6). There is corroborative evidence for saturation kinetics in the uptake of amino acids by cells (3-6). However, there is one

Correspondence to: Gunnar Ronquist, MD, Department of Medical Sciences, Clinical Chemistry, University of Uppsala, SE-751 85 Uppsala, Sweden. Tel: +46 186114244, e-mail: gunnar.ronquist@akademiska.se

Key Words: Glioblastoma, DAB, targeted therapy, amino acids, cytolysis, review.

remarkable exception to the rule of saturation kinetics, linked to one artificial (non-physiological) amino acid, that is L-2,4 diamino butyric acid (DAB) (5, 7). It displays an unrestrained, preferential uptake by glioma cells exposed to extracellular DAB for a prolonged time, ultimately leading to cellular lysis due to osmotic imbalance, caused by uncontrolled water influx, which results from the very high intracellular accumulation of DAB. Additionally, the unlimited uptake of DAB by glioma cells is accomplished by the System A transport system at the expense of the sodium ion gradient across the plasma membrane (3, 7, 8), which stimulates the Na⁺ and K⁺ dependent ATPase. Accordingly, a prolonged uptake of DAB by ravenous glioma cells causes a strain on the cellular energy economy, potentially leading to an energy crisis, supplemental to the destructive osmotic effect of DAB on the glioma cells.

Induced Cytolysis of Human Glioma Cells *In Vitro*

We designed *in vitro* incubation experiments based on the substantial difference in uptake capacity of selected amino acids (both physiological and non-physiological) by System A between human glia (normal) and human glioma (malignant) cells (3). Such *in vitro* incubation experiments with 4-8 mmol/l of DAB resulted in an unequivocal outcome, revealing a 100% lethal effect on human glioma cells due to complete and irreversible cellular lysis, while 100% of glia cells remained unharmed under identical conditions (8). The cytotoxic effect of DAB on glioma cells required an incubation medium pH of 7.4-7.8 and was completely abolished by concomitant incubation with methyl-AIB at a concentration as low as 2 mmol/l. This demonstrates that DAB's lethal effect on glioma cells is mediated specifically through System A transport, since methyl-AIB is specific to this transport pathway (8). It is noteworthy that an incubation time of 20-24 h at 37°C was required to achieve a complete cytotoxic effect on human glioma cells *in vitro* (8). The lethal effect of DAB on human glia cells was much more slower and less pronounced. Even after raising the DAB concentration to 20 mmol/l there were no signs of cellular lysis of glia cells upon incubation for 24 h at 37°C. More drastic conditions, such as a further increase in DAB concentration and prolongation of the incubation time, were needed to observe a gradual decline in the viability of normal glia cells (8). These results indicated that the noticed differences between human glia and glioma cells were in this respect quantitative rather than qualitative. It also tallies with our report that the increased transport capacity of human glioma cells *via* System A (in comparison with human glia cells) was caused by an elevated V_{max}-value for transport, while the apparent K_m-values were about the same for human glia and glioma cells (3). The V_{max}-value reflects the number of operative carriers (for selected

amino acids, including DAB) in the plasma membrane, while the K_m-value denotes the affinity of the receptor subunit of the transport system for the specific amino acid (3).

Introductory Patient Studies

The results achieved from experiments on human glia and glioma cells *in vitro* paved the way for a minitrial comprising three patients with inoperable GBM after patients' informed consent and Ethical Committee approval (9). One to three microdialysis probes (primarily developed for analysis of interstitial fluid-constituents of different tissues) were implanted through small dural incisions in brain tumor tissue. Each microdialysis probe was connected to a microsyringe pump maintaining a slow flowrate of 3 ml/24 h. The microsyringe pump was charged with 3 ml of an isotonic Tris-buffered, 125 mmol/l DAB solution containing sodium ions at pH 7.55 (9). The patients did not receive any radiotherapy or chemotherapy prior to or along with the DAB therapy. The patients were treated in this way by continuous intra-tumoral administration of the slightly alkaline DAB-solution for 14-21 days without side effects assignable to DAB (9). Massive tumor glioma cell-lysis occurred as judged by comparison of computed tomography examinations performed before and after DAB treatment. In order to verify the X-ray finding clearly, one patient was subjected to a craniotomy and the loose necrotic tumor tissue could be seen and evacuated (12 ml). Accordingly, the induced cytolytic effect achieved by incubation with DAB on human glioma cells *in vitro* under controlled conditions, could be similarly reproduced under *in vivo* conditions. The patients presented survival times that were about three times longer than the mean survival time for patients with inoperable GBM receiving only radiotherapy (9).

A similar trial as the one described above was subsequently carried out on 10 patients with newly detected GBM (10). The tumors were all centrally located and not suitable for debulking surgery. Seven of the inoperable patients were therapy-naïve while the three others had previously undergone resection or biopsy and radiotherapy for a high-grade astrocytoma. During the DAB treatment using microdialysis probes, no additional therapy was provided. Generally, the patients tolerated the treatment and procedure well, which involved a continuous administration of 100 mmol/l of DAB in a slightly alkaline Tris-buffered solution at a rate of 3 ml/24 h. Mean time for treatment was 9.1 days (range=5-19 days). Again, cytolysis of tumor cells *in vivo* could be presumed, since a malfunction of the catheters was noted as a result of a gradual decrease in dialysate from the catheters, due to an amorphous deposition covering the semipermeable membrane of the microdialysis device (10). Additionally, one patient developed (during ongoing treatment with DAB) fever and leukocytosis without any obvious cause. Catheters were removed after six days; however, culture of the catheters was

negative. Therefore, fever and leukocytosis were interpreted as an immunological reaction due to the exaggerated malignant cell destruction (10).

All patients in this trial had centrally located tumors, which are historically associated with a poor prognosis regardless of the treatment administered. In patients with inoperable, often centrally located GBM, the survival time has been reported to be 3-8 months after biopsy and radiotherapy (11-13). In our trial, comprising seven patients with newly detected, unresectable tumors, the overall median survival time was 8.0 months (range=2-11 months) (10). While this may indicate an improvement, the small sample size limits the conclusion. In addition, it should be kept in mind that in some patients, the catheters started to malfunction early due to the deposition of tumor cell debris on the microdialysis membrane, most probably as a result of DAB-induced cytolysis.

Therapeutic Limitations

Continuous intra-tumoral administration of DAB using analytic microdialysis probes in 13 patients resulted in the safe destruction of GBM cells through DAB-induced cytolysis (9, 10). Still, the efficiency of the whole procedure in terms of influence on overall survival was limited. It could be ascertained that the administration device (aimed at analytical purposes) was too fragile and only suited for very low flow rates. Moreover, the semipermeable dialysis membrane linked to the administration device posed a significant barrier to the removal of unwanted constituents from the tumor microenvironment (TME), which is a complex and dynamic factor that interacts with GBM (14). TME is involved in the process of tumorigenesis, regulating the growth, metabolism, proliferation, and invasion of cancer cells. Additionally, it plays an important role in tumor resistance to the conventional chemoradiotherapies (14). A diversity of cells has been identified within the TME together with an abundance of extracellular vesicles (EVs) (14). The neoplastic heterogeneity typical of GBM generates problems in disease treatment, as established oncological therapeutics fail to target the entire disease burden (15, 16). The radiographical depiction of the disease is insufficient in many cases, since there may be micro-infiltrative tumor cells beyond the margin of the radiographical depiction (15, 17, 18).

We aimed to address these well-known problems in a novel way, keeping in mind that human glioma cells cannot discriminate the unphysiological (artificial) amino acid DAB from physiological amino acids during uptake from the extracellular space to the intracellular space (3-5, 7, 8). DAB is a low-molecular compound with hydrophilic properties that allow for broad distribution within the tumor area, provided the administration time is sufficiently long and the flow rate is properly controlled. Histological analyses have

demonstrated that most tumor recurrences in GBM occur within 2-3 cm of the tumor margin (19). This distance is somewhat longer than the estimated diffusion range of DAB in the brain when administered at a very low flow rate of 3 ml/24 h (10). It should be noted that the flow rates in the two case reports presented below were considerably higher (2-18 ml/h). The purpose was to enhance the diffusion ability of the DAB solution, now also containing μ molar concentrations of Prazosin [an established antihypertensive drug with unique proapoptotic properties against tumor initiating cells (TICs) (20)] to increase local drug penetration into the surrounding brain parenchyma. Prazosin was chosen since it has been shown to target glioblastoma cells *via* the PKC delta-dependent inhibition of the AKT signaling pathway (21). The latter is a well-established component of the PI3-kinase pathway, which is commonly elevated in over 90% of gliomas through activating mutations of upstream kinases or PI3K itself, or through inactivation of the tumor-suppressor PTEN (22). Drug penetration occurs through the brain interstitial space. In addition to the size of the molecules being administered, diffusion through the interstitial space is governed by other factors, such as local molecular charges, composition, and geometry (23). Studies on rat and human brains have revealed that substances slightly larger than 100 nm can diffuse through the interstitial space, provided they are protected from the charge influences of the local environment (24, 25). This means that not only low-molecular compounds like DAB and Prazosin, but also small EVs (exosomes), can spread through the brain's interstitial space.

The Crucial Role of EVs for Glioma Cell Proliferation and Progression

Exosomes are a subclass of membrane-coated EVs with sizes of 40-150 nm, which are released from most cells by exocytosis. There is compelling evidence that exosomes play a role in the spread of cancer from a primary tumor to metastasis sites (26). It was reported in 2009 that glioma cells release EVs with biophysical characteristics and proteomic profiles similar to EVs from other cell types (27). However, some features of glioma-derived EVs were unique, *e.g.*, very basic isoelectric points of some proteins expressing the mutated tumor antigen EGFRvIII and the putative immunosuppressive cytokine TGF- β (27). Gene expansion of growth factor receptors with intrinsic protein tyrosine kinase activity, particularly epidermal growth factor receptor (EGFR) and its mutant version, EGFR variant III (EGFRvIII), are granted signatures of the classical glioblastoma subtype (28). It is noteworthy that EVs derived from glioma cells expressing EGFRvIII execute the transfer of this mutant receptor to glioma cells lacking it, leading to concomitant activation of tumor-promoting signaling pathways associated with EGFRvIII signaling and VEGF release (29). It has been estimated that one primary GBM cell releases 10,000

EVs *in vitro* during 48 h (30, 31). This activity suggests that GBM-derived EVs represent important means of communication within the TME, supporting GBM cell survival and proliferation. In line with this, glioma EVs induce angiogenesis in rapidly growing glioma cells, which require a constant supply of nutrients and oxygen. Moreover, glioma EVs mediate the reprogramming of metabolic activity and immunomodulation of TME, as well as playing a role in the acquisition of drug resistance (14, 32). The corollary is to achieve a mode of removal of EVs from the TME.

We aimed to build on our initial clinical trials and the experiences achieved thereof with a novel approach, giving special emphasis on: a) the demand for a robust administration device capable of supporting a higher flow rate of the drug solution; b) the TME, including its constituents such as an abundance of EVs, and a diversity of cells (14) must be accessible for removal by our slightly alkaline Tris-buffered drug solution. Accordingly, in both Case 1 [previously reported by Ganapathy *et al.*, 2023 (20)] and Case 2 presented here, after maximal safe resection of recurrent tumor, two catheters were placed at the tumor's excision side and connected to drug infusion pumps for administration of the drug solution. This solution was a pH 7.55 Tris-buffered solution containing 100 mmol/l of L-2,4 diamino butyric acid (an artificial amino acid) and either 25 μ mol/l or 500 μ mol/l of Prazosin. Infusion continued for 4 to 5 days at a flow rate of 2-18 ml/h, regulated according to the patient's clinical status and intracranial pressure. Periodic manual aspirations of intratumoral fluid (every 30 min – 4 h) were performed to remove malignant cell debris (resulting from induced malignant cell lysis) together with EVs and a small amount of a diversity of cells, as well as to enhance the drug concentration at the tumor margin.

Case 1 [first reported by Ganapathy *et al.*, 2023 (20)]

A 36-year-old female patient presented to the clinic with prolonged headache and vomiting. On examination, she had features of raised intracranial tension manifested by a grade 2 papilledema in both eyes. MRI was suggestive of an aggressive intrinsic lesion in the right parieto-occipital region of the brain and there was significant perilesional oedema causing a mass effect and midline shift of over 1.7 cm. She was subjected to adjuvant therapy including tumor decompression (20). The patient was seen again within three months due to the recurrence of vigorous symptoms similar to her initial presentation. MRI imaging showed a massive recurrence of the brain tumor and its aggressive nature implied a poor prognosis (20). After Ethical Committee's approval and informed consent from the spouse, the patient was reoperated, and gross total resection of the lesion was performed. Two external ventricular drain tubes were placed in the tumor cavity. The tumor was infused (3-5 ml/h) for 90 h with the slightly alkaline Tris-buffered solution containing

DAB at 100 mmol/l, now also containing Prazosin at 25 μ mol/l. At every 2-4 h the infusion was paused to allow drainage of the necrotic fluid from the cavity, preventing a rise in intracerebral pressure. This also facilitated the washout of cell debris and EVs from the TME. The patient was carefully monitored and eventually discharged for follow up (20). On review, she had improved dramatically. One month later, she was started on adjuvant Temozolomide and radiation therapy and tolerated the sessions well. She gained weight and began attending her activities of daily living. Annual reviews have been conducted for seven years using MRI, which has shown no signs of tumor recurrence so far.

Case 2

A 58 year-male patient with a history of skin melanoma, surgically treated five years ago, presented with a variety of neurological symptoms, including partial epileptic seizures affecting the left side of his face and arm, dysarthria, dysphagia, and drooping of the left side of his mouth. He was subjected to a contrast MRI scan that showed a right temporoparietal brain tumor (Figure 1A). All other patient's examinations were negative for further pathology. The patient, after been fully informed, was adamant about not risking a further neurologic deficit (left hemiparesis) following surgery – hoping his tumor was a melanoma metastasis, which might respond to immunotherapy. He had a neurosurgical intervention, and the pathological examination of the excised tumor revealed highly aggressive glioblastoma (p53 mutant/ATRX wild type). The image in Figure 1B is from the postoperative contrast MRI scan, demonstrating the deliberately non-excised residual tumor due to the risk of iatrogenic injury. After Ethical Committee approval and patient's informed consent, the patient was reoperated for placement of two EVD catheters connected to drug infusion pumps (Figure 1C). The tumor excision site was irrigated for 120 h with the slightly alkaline Tris-buffered DAB solution, which also contained μ molar concentrations of Prazosin. Remarkably, a subsequent contrast MRI showed complete cytolysis and destruction of the residual tumor, as shown in Figure 1D. The patient also received adjuvant Temozolomide and radiation therapy, as in Case 1. To date, he remains ambulatory, and a recent MRI follow up, two years after treatment with the DAB/Prazosin drug combination, revealed no signs of malignancy.

Conclusion

At this stage, we can conclude that our new treatment approach is well-tolerated by patients and is unlikely to lead to drug resistance. GBM tumors are fully liquefied by the end of the treatment, offering a reliable strategy for tumor

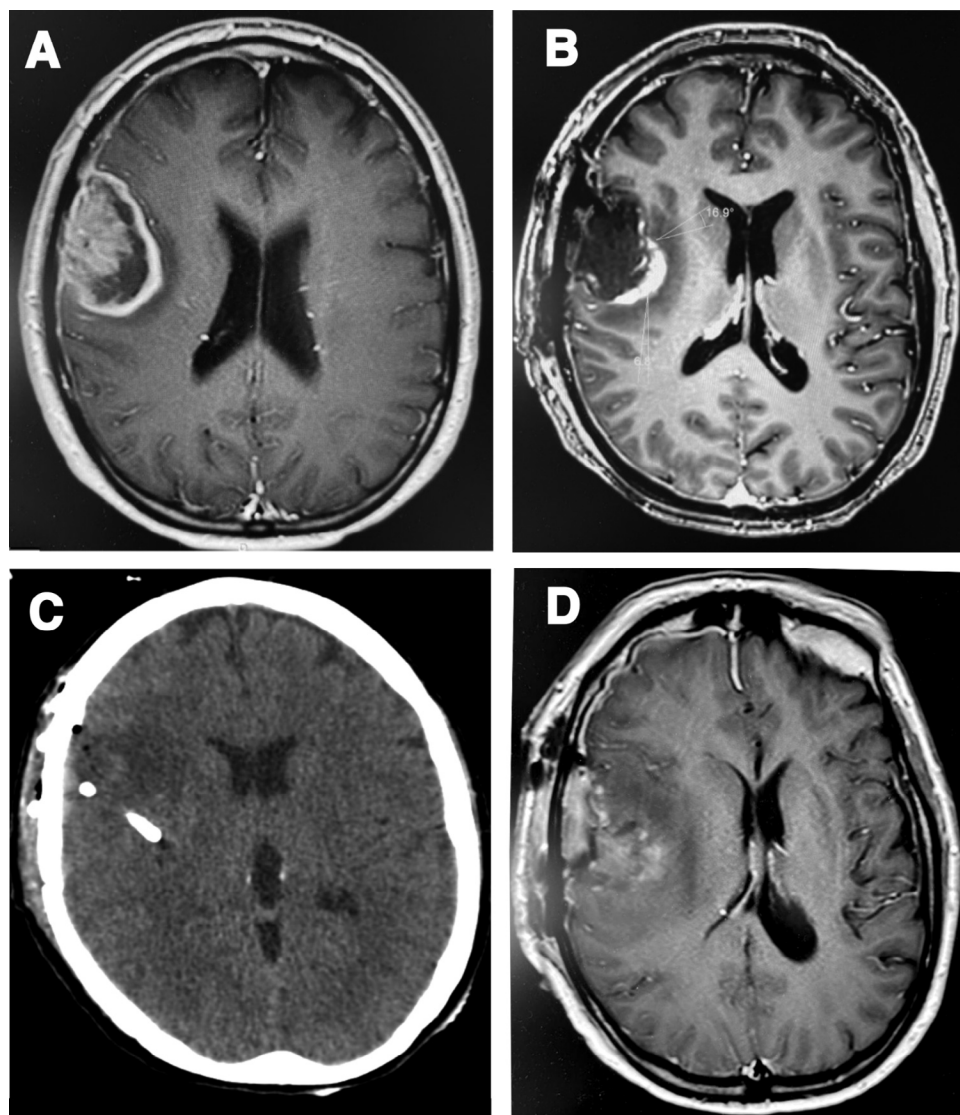


Figure 1. Magnetic resonance imaging (MRI) scans demonstrating the efficacy of the treatment protocol. A) MRI scan showing a right temporoparietal brain tumor in the patient from Case 2. B) Post-operative contrast MRI scan demonstrating the deliberately non-excised residual tumor (due to risk of iatrogenic injury). C) Catheter position. D) MRI scan illustrating the remarkable cytolysis and destruction of the residual tumor directly after completing the L-2,4 diamino butyric acid/Prazosin treatment.

size reduction. When combined with efficient aspiration, as in our drug delivery method, this approach enhances the overall effectiveness. Additionally, preoperative tumor size reduction using this minimally invasive option may render operable tumors that are typically deemed inoperable due to their size, shape, or localization.

Disclosure

The drugs mentioned in this work are not labeled for the use presented here and the described procedures are still investigational.

Conflicts of Interest

None apart from Christos Panotopoulos (CP): Founder and Director of Inderes Ltd. - owner of all intellectual property rights relative to this article.

Authors' Contributions

Conceptualization & Methodology: C. Panotopoulos, G. Ronquist, G. Panayotou; Investigation: C. Panotopoulos, G. Athanasiou, S. Stavropoulos, N. Boutos; Supervision: G. Ronquist, S. Rao, N. K. Venkataramana, C. Panotopoulos; Writing & Editing: G. Ronquist, G. Panayotou, C. Panotopoulos.

References

- 1 Delgado-López PD, Corrales-García EM: Survival in glioblastoma: a review on the impact of treatment modalities. *Clin Transl Oncol* 18(11): 1062-1071, 2016. DOI: 10.1007/s12094-016-1497-x
- 2 Ellingson BM, Wen PY, Chang SM, van den Bent M, Vogelbaum MA, Li G, Li S, Kim J, Youssef G, Wick W, Lassman AB, Gilbert MR, de Groot JF, Weller M, Galanis E, Cloughesy TF: Objective response rate targets for recurrent glioblastoma clinical trials based on the historic association between objective response rate and median overall survival. *Neuro Oncol* 25(6): 1017-1028, 2023. DOI: 10.1093/neuonc/noad002
- 3 Ronquist G, Ågren G, Ponten J, Westermarck B: α -aminoisobutyric acid transport into human glia and glioma cells in culture: AIB transport and glia and glioma cells in culture. *J Cell Physiol* 89(3): 433-439, 1976. DOI: 10.1002/jcp.1040890309
- 4 Christensen HN: Amino acid transport systems in animal cells: Interrelations and energization. *J Supramol Struct* 6(2): 205-213, 1977. DOI: 10.1002/jss.400060206
- 5 Christensen HN, De Cespedes C, Handlogten ME, Ronquist G: Energization of amino acid transport, studied for the Ehrlich ascites tumor cell. *Biochim Biophys Acta* 300(4): 487-522, 1973. DOI: 10.1016/0304-4157(73)90017-8
- 6 Falck B, Bendsoe N, Ronquist G: New mechanism for amino acid influx into human epidermal Langerhans cells: L-dopa/proton counter-transport system. *Experimental Dermatology* 12(5): 602-609, 2003. DOI: 10.1034/j.1600-0625.2003.00019.x
- 7 Christensen H, Ronquist G: Membrane transport properties of L-2,4-diaminobutyrate revisited. *J Membr Biol* 127(1): 1-7, 1992. DOI: 10.1007/BF00232753
- 8 Ronquist G, Westermarck B, Hugosson R: Induction of complete and irreversible damage to malignant glioma cells by L-2,4-diaminobutyric acid. *Anticancer Res* 4: 225-228, 1984.
- 9 Ronquist G, Hugosson R, Sjölander U, Ungerstedt U: Treatment of malignant glioma by a new therapeutic principle. *Acta Neurochirurgica* 114(1-2): 8-11, 1992. DOI: 10.1007/BF01401106
- 10 Bergenheim AT, Roslin M, Ungerstedt U, Waldenström A, Henriksson R, Ronquist G: Metabolic manipulation of glioblastoma in vivo by retrograde microdialysis of L-2, 4-diaminobutyric acid (DAB). *J Neuro Oncol* 80(3): 285-293, 2006. DOI: 10.1007/s11060-006-9186-1
- 11 Fazeny-Dörner B, Wenzel C, Veitl M, Piribauer M, Rössler K, Dieckmann K, Ungersböck K, Marosi C: Survival and prognostic factors of patients with unresectable glioblastoma multiforme. *Anticancer Drugs* 14(4): 305-312, 2003. DOI: 10.1097/00001813-200304000-00008
- 12 Laws ER, Parney IF, Huang W, Anderson F, Morris AM, Asher A, Lillehei KO, Bernstein M, Brem H, Sloan A, Berger MS, Chang S, Glioma Outcomes Investigators: Survival following surgery and prognostic factors for recently diagnosed malignant glioma: data from the Glioma Outcomes Project. *J Neurosurg* 99(3): 467-473, 2003. DOI: 10.3171/jns.2003.99.3.0467
- 13 Quigley MR, Flores N, Maroon JC, Sargent B, Lang S, Elrifai A: Value of surgical intervention in the treatment of glioma. *Stereotact Funct Neurosurg* 65(1-4): 171-175, 1995. DOI: 10.1159/000098962
- 14 Ten A, Kumeiko V, Farniev V, Gao H, Shevtsov M: Tumor microenvironment modulation by cancer-derived extracellular vesicles. *Cells* 13(8): 682, 2024. DOI: 10.3390/cells13080682
- 15 Cho NS, Sanvito F, Thakuria S, Wang C, Hagiwara A, Nagaraj R, Oshima S, Lopez Kolkovsky AL, Lu J, Raymond C, Liao LM, Everson RG, Patel KS, Kim W, Yang I, Bergsneider M, Nghiemphu PL, Lai A, Nathanson DA, Cloughesy TF, Ellingson BM: Multi-nuclear sodium, diffusion, and perfusion MRI in human gliomas. *J Neurooncol* 163(2): 417-427, 2023. DOI: 10.1007/s11060-023-04363-x
- 16 Mendoza MG, Azoulay M, Chang SD, Gibbs IC, Hancock SL, Pollom EL, Adler JR, Harraher C, Li G, Gephart MH, Nagpal S, Thomas RP, Recht LD, Jacobs LR, Modlin LA, Wynne J, Seiger K, Fujimoto D, Usoz M, Von Eyben R, Choi CY, Soltys SG: Patterns of progression in patients with newly diagnosed glioblastoma treated with 5-mm margins in a phase 1/2 trial of 5-fraction stereotactic radiosurgery with concurrent and adjuvant temozolomide. *Pract Radiat Oncol* 13(3): e239-e245, 2023. DOI: 10.1016/j.prro.2023.01.008
- 17 Yan M, Lee M, Myrehaug S, Tseng CL, Detsky J, Chen H, Das S, Yeboah C, Lipsman N, Costa LD, Holden L, Heyn C, Maralani P, Ruschin M, Sahgal A, Soliman H: Hypofractionated stereotactic radiosurgery (HSRS) as a salvage treatment for brain metastases failing prior stereotactic radiosurgery (SRS). *J Neurooncol* 162(1): 119-128, 2023. DOI: 10.1007/s11060-023-04265-y
- 18 Das S, Marsden PA: Angiogenesis in glioblastoma. *N Engl J Med* 369(16): 1561-1563, 2013. DOI: 10.1056/NEJMcibr1309402
- 19 Gebhardt BJ, Dobelbower MC, Ennis WH, Bag AK, Markert JM, Fiveash JB: Patterns of failure for glioblastoma multiforme following limited-margin radiation and concurrent temozolomide. *Radiat Oncol* 9: 130, 2014. DOI: 10.1186/1748-717X-9-130
- 20 Ganapathy S, Venkataramana NK, Rao SA, Nagaraj A, Panayotou G, Panotopoulos C, Ronquist G: Post-resection cavity lavage of high grade glioma with a novel drug combination: a case report. *Anticancer Res* 43(8): 3583-3588, 2023. DOI: 10.21873/anticancer.16537
- 21 Assad Kahn S, Costa SL, Gholamin S, Nitta RT, Dubois LG, Fève M, Zeniou M, Coelho PL, El-Habr E, Cadusseau J, Varlet P, Mitra SS, Devaux B, Kilhoffer MC, Cheshier SH, Moura-Neto V, Haiech J, Junier MP, Chneiweiss H: The anti-hypertensive drug prazosin inhibits glioblastoma growth via the PKC δ -dependent inhibition of the AKT pathway. *EMBO Mol Med* 8(5): 511-526, 2016. DOI: 10.15252/emmm.201505421
- 22 Langhans J, Schneele L, Trenkler N, von Bandemer H, Nonnenmacher L, Karpel-Massler G, Siegelin MD, Zhou S, Halatsch ME, Debatin KM, Westhoff MA: The effects of PI3K-mediated signalling on glioblastoma cell behaviour. *Oncogenesis* 6(11): 398, 2017. DOI: 10.1038/s41389-017-0004-8
- 23 Syková E, Vargová L: Extrasynaptic transmission and the diffusion parameters of the extracellular space. *Neurochem Int* 52(1-2): 5-13, 2008. DOI: 10.1016/j.neuint.2007.04.007
- 24 Pandey N, Anastasiadis P, Carney CP, Kanvinde PP, Woodworth GF, Winkles JA, Kim AJ: Nanotherapeutic treatment of the invasive glioblastoma tumor microenvironment. *Adv Drug Deliv Rev* 188: 114415, 2022. DOI: 10.1016/j.addr.2022.114415
- 25 Nance EA, Woodworth GF, Sailor KA, Shih TY, Xu Q, Swaminathan G, Xiang D, Eberhart C, Hanes J: A dense poly(ethylene glycol) coating improves penetration of large polymeric nanoparticles within brain tissue. *Sci Transl Med* 4(149): 149ra119, 2012. DOI: 10.1126/scitranslmed.3003594
- 26 Hood JL, San RS, Wickline SA: Exosomes released by melanoma cells prepare sentinel lymph nodes for tumor metastasis. *Cancer Res* 71(11): 3792-3801, 2011. DOI: 10.1158/0008-5472.CAN-10-4455

- 27 Graner MW, Alzate O, Dechkovskaia AM, Keene JD, Sampson JH, Mitchell DA, Bigner DD: Proteomic and immunologic analyses of brain tumor exosomes. *FASEB J* 23(5): 1541-1557, 2009. DOI: 10.1096/fj.08-122184
- 28 Verhaak RG, Hoadley KA, Purdom E, Wang V, Qi Y, Wilkerson MD, Miller CR, Ding L, Golub T, Mesirov JP, Alexe G, Lawrence M, O'Kelly M, Tamayo P, Weir BA, Gabriel S, Winckler W, Gupta S, Jakkula L, Feiler HS, Hodgson JG, James CD, Sarkaria JN, Brennan C, Kahn A, Spellman PT, Wilson RK, Speed TP, Gray JW, Meyerson M, Getz G, Perou CM, Hayes DN, Cancer Genome Atlas Research Network: Integrated genomic analysis identifies clinically relevant subtypes of glioblastoma characterized by abnormalities in PDGFRA, IDH1, EGFR, and NF1. *Cancer Cell* 17(1): 98-110, 2010. DOI: 10.1016/j.ccr.2009.12.020
- 29 Al-Nedawi K, Meehan B, Micallef J, Lhotak V, May L, Guha A, Rak J: Intercellular transfer of the oncogenic receptor EGFRvIII by microvesicles derived from tumour cells. *Nat Cell Biol* 10(5): 619-624, 2008. DOI: 10.1038/ncb1725
- 30 Skog J, Würdinger T, van Rijn S, Meijer DH, Gainche L, Sena-Esteves M, Curry WT Jr, Carter BS, Krichevsky AM, Breakefield XO: Glioblastoma microvesicles transport RNA and proteins that promote tumour growth and provide diagnostic biomarkers. *Nat Cell Biol* 10(12): 1470-1476, 2008. DOI: 10.1038/ncb1800
- 31 Balaj L, Lessard R, Dai L, Cho YJ, Pomeroy SL, Breakefield XO, Skog J: Tumour microvesicles contain retrotransposon elements and amplified oncogene sequences. *Nat Commun* 2: 180, 2011. DOI: 10.1038/ncomms1180
- 32 Barthel L, Hadamitzky M, Dammann P, Schedlowski M, Sure U, Thakur BK, Hetze S: Glioma: molecular signature and crossroads with tumor microenvironment. *Cancer Metastasis Rev* 41(1): 53-75, 2022. DOI: 10.1007/s10555-021-09997-9

Received November 8, 2024

Revised November 22, 2024

Accepted November 25, 2024