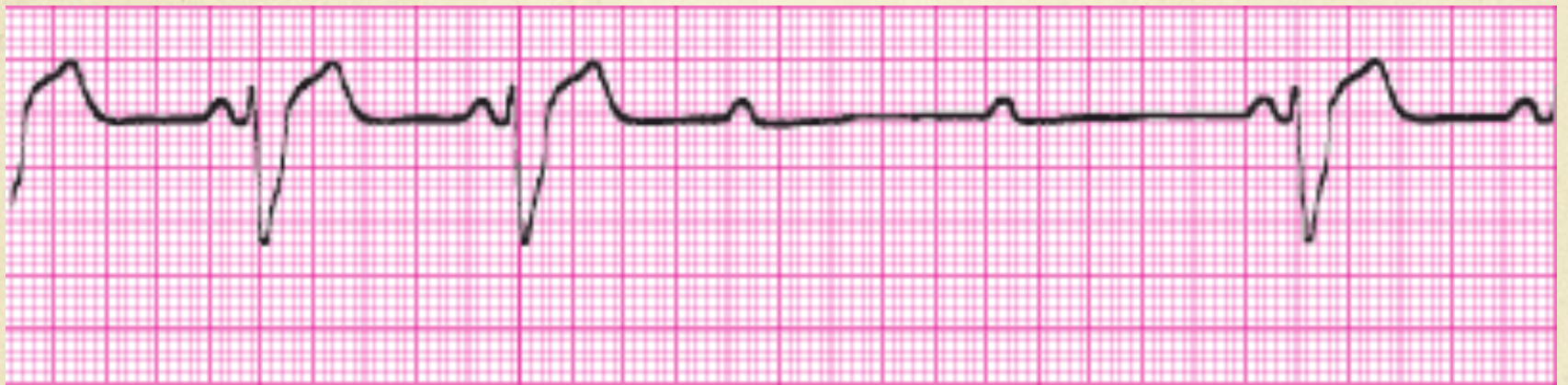


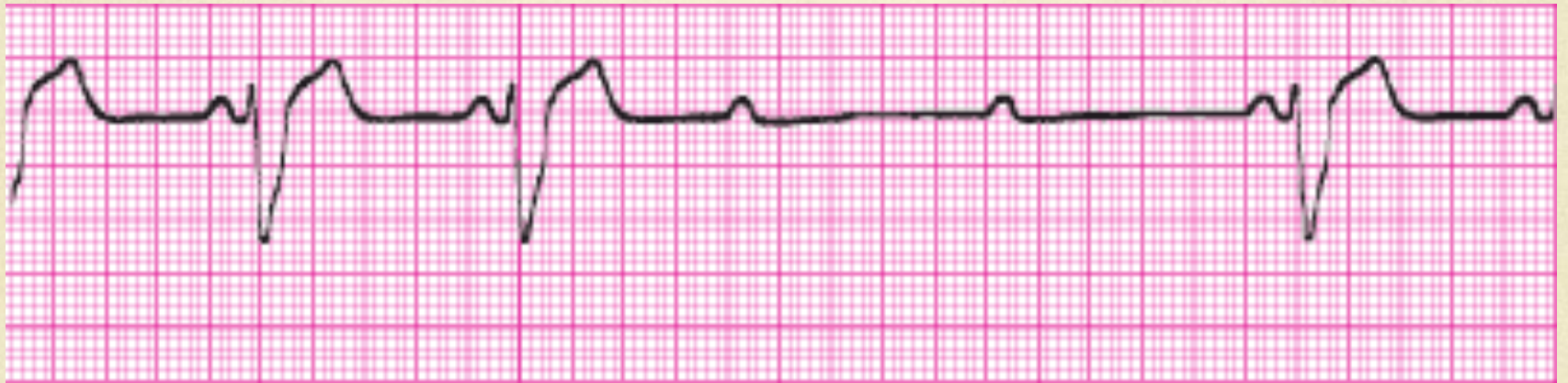# ECG Final Exam

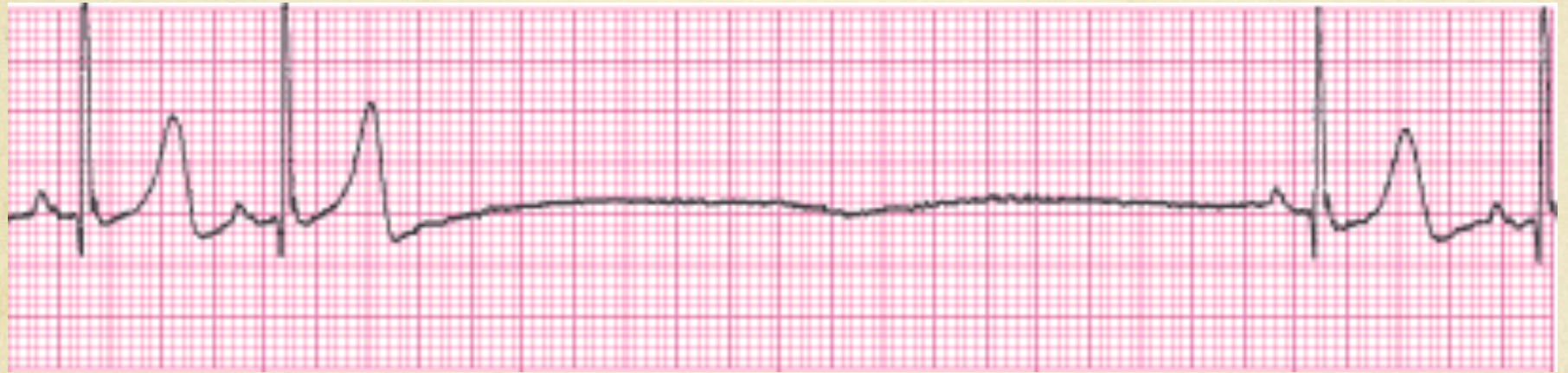
Practice Strips





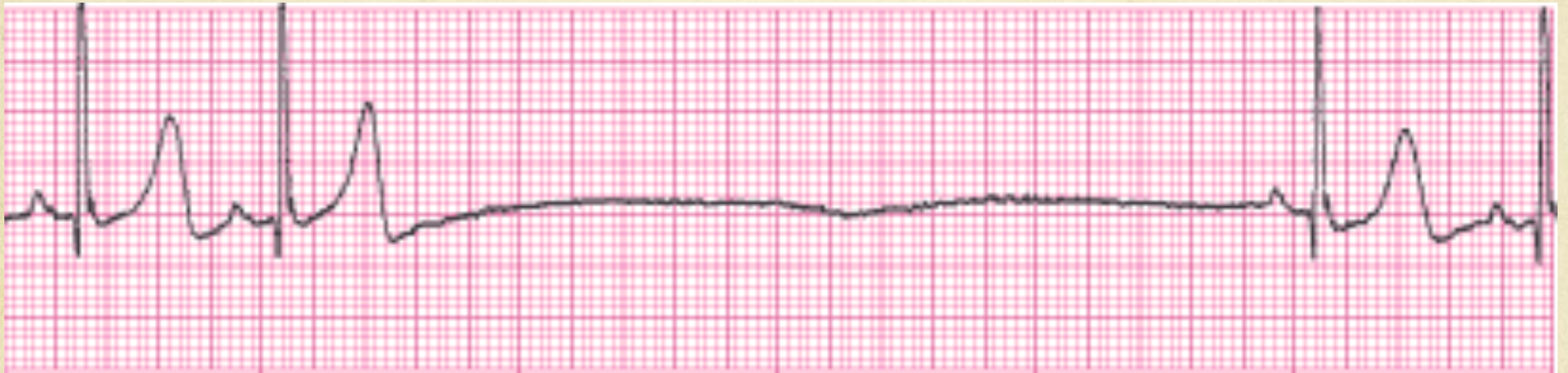
# Second Degree Type II (Mobitz)

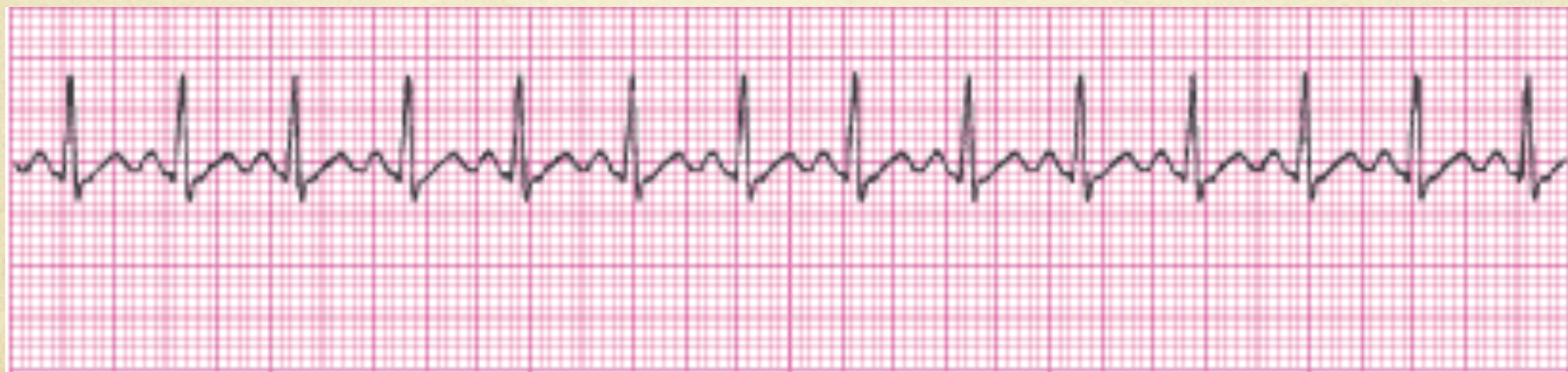





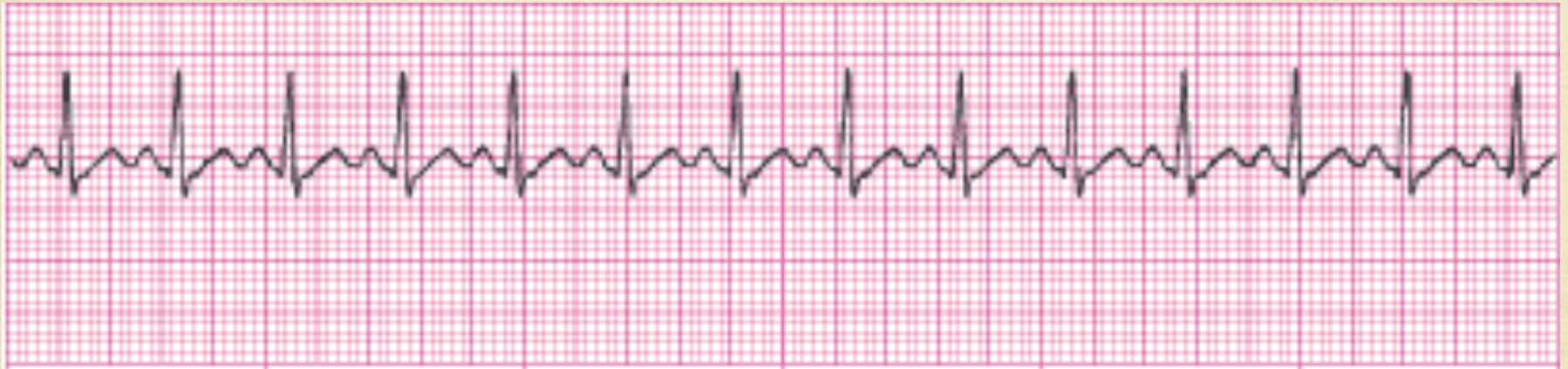# Sinus with an episode of sinus arrest

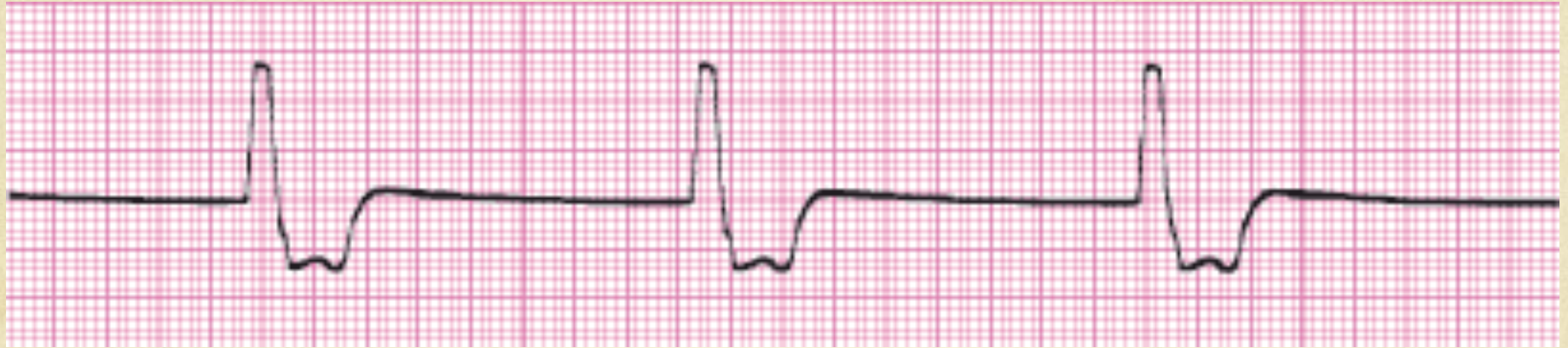





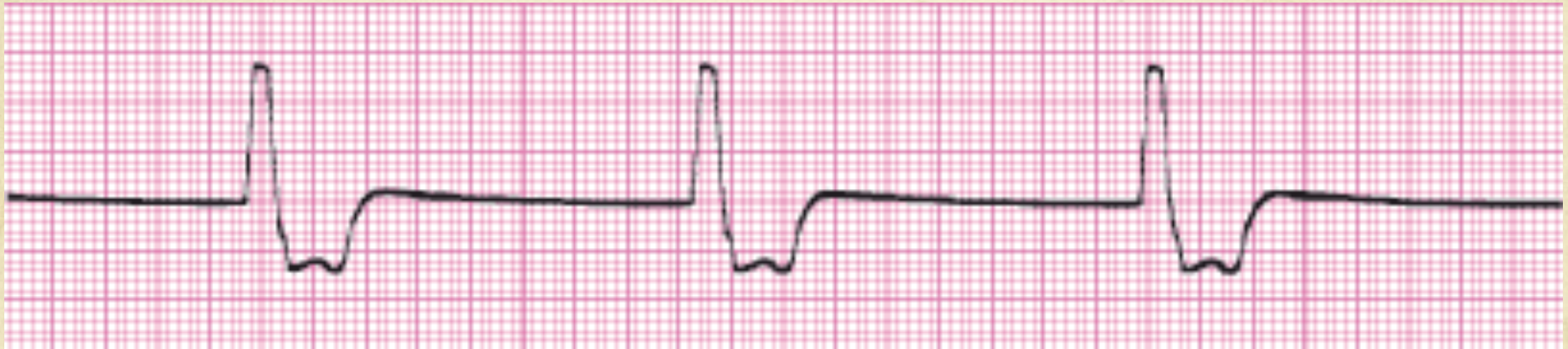# Sinus Tachycardia

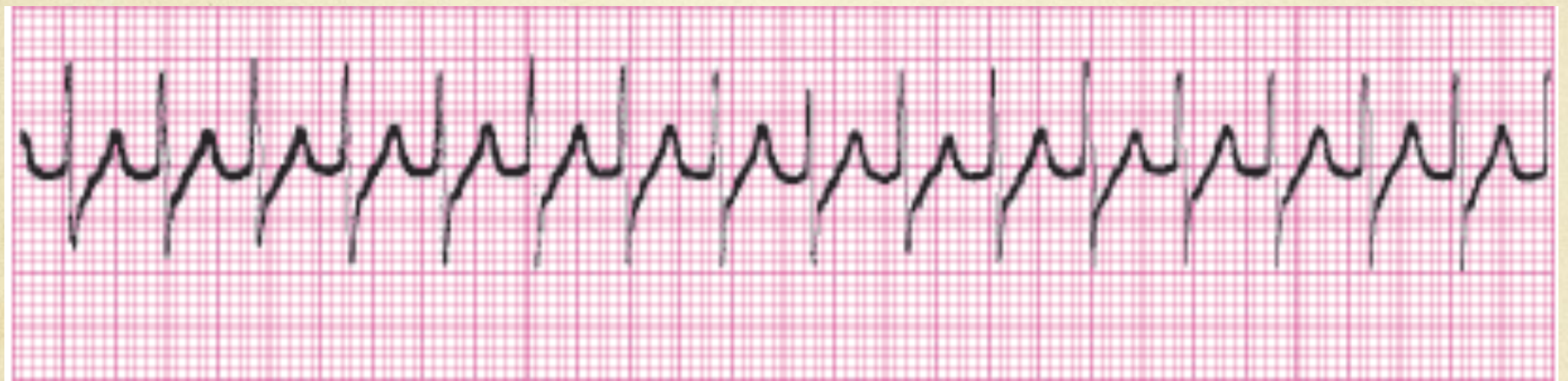





# Idioventricular

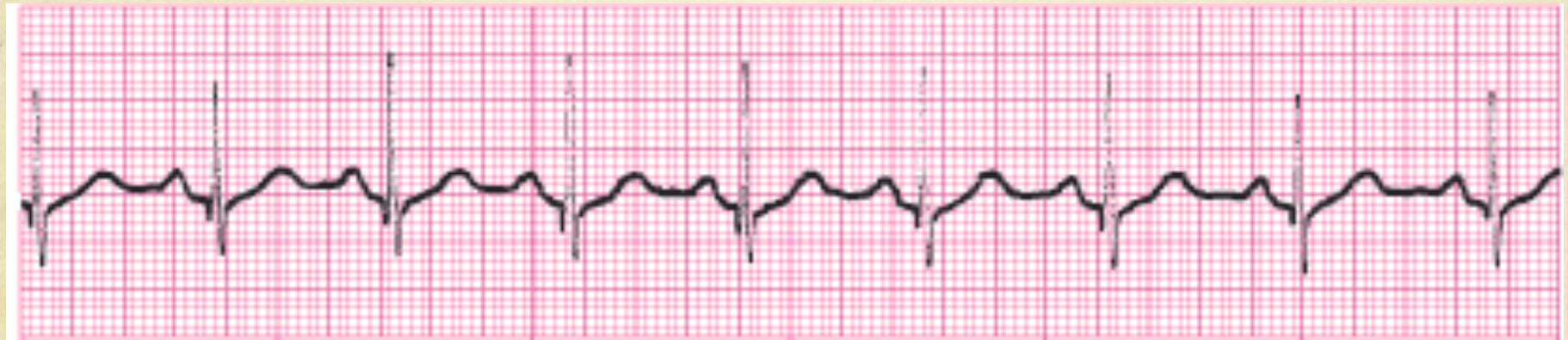





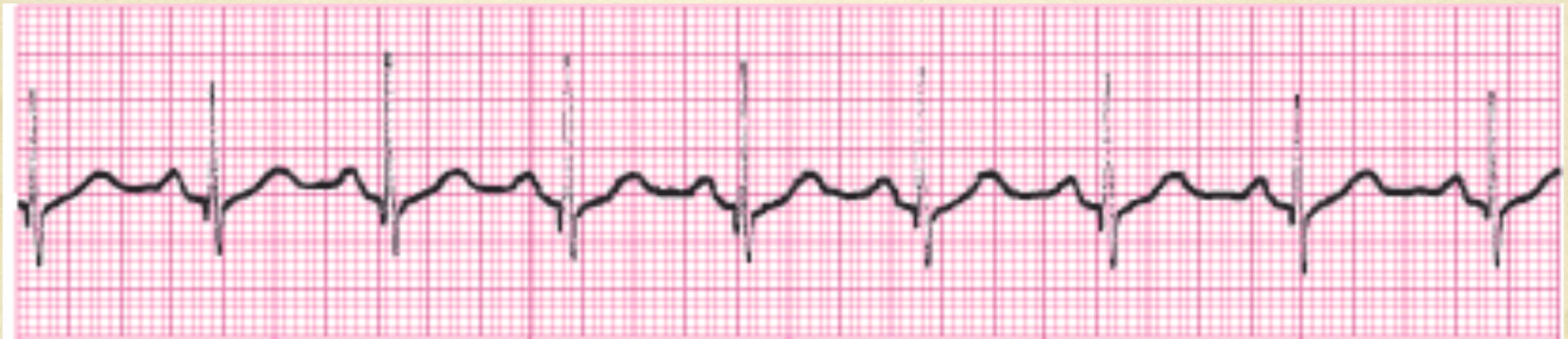# Supra Ventricular Tachycardia

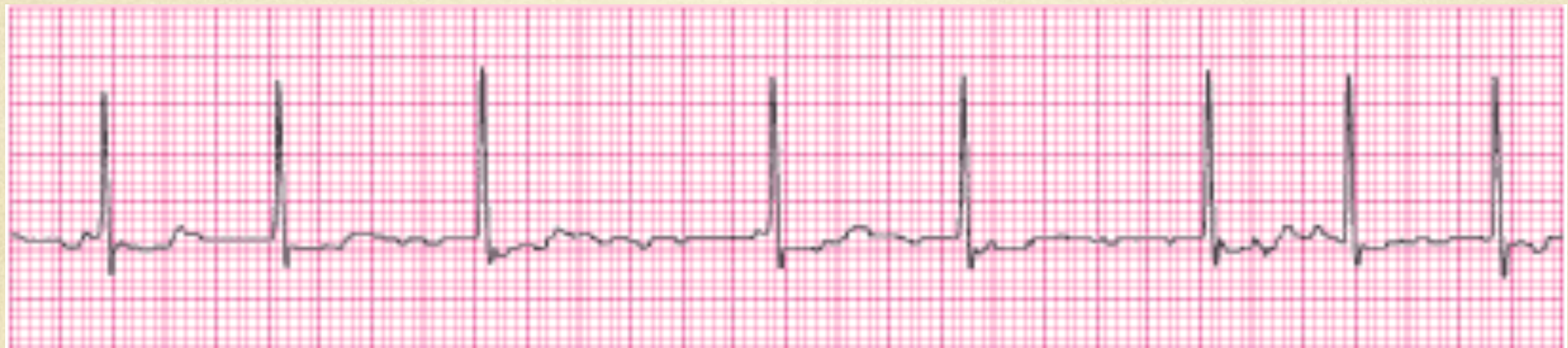





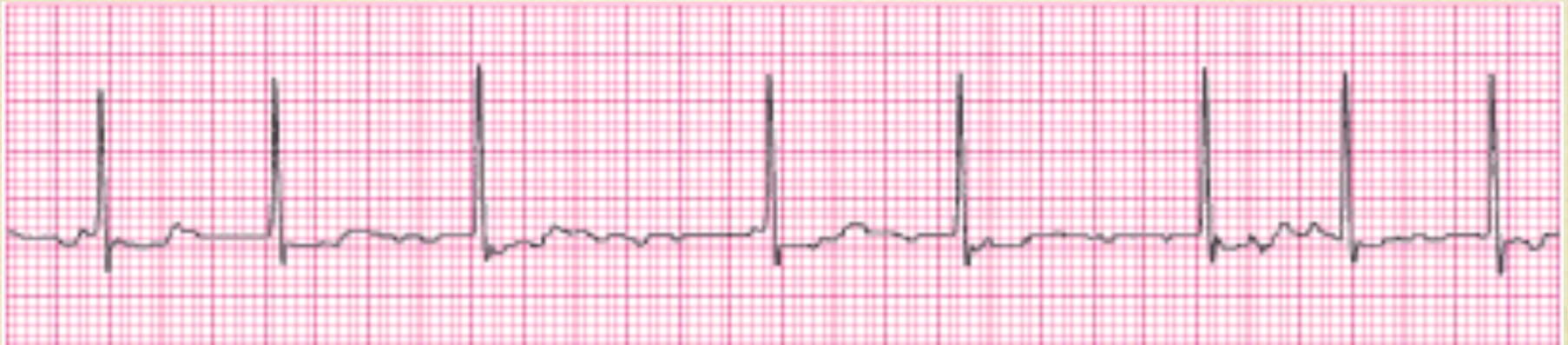# Normal Sinus Rhythm

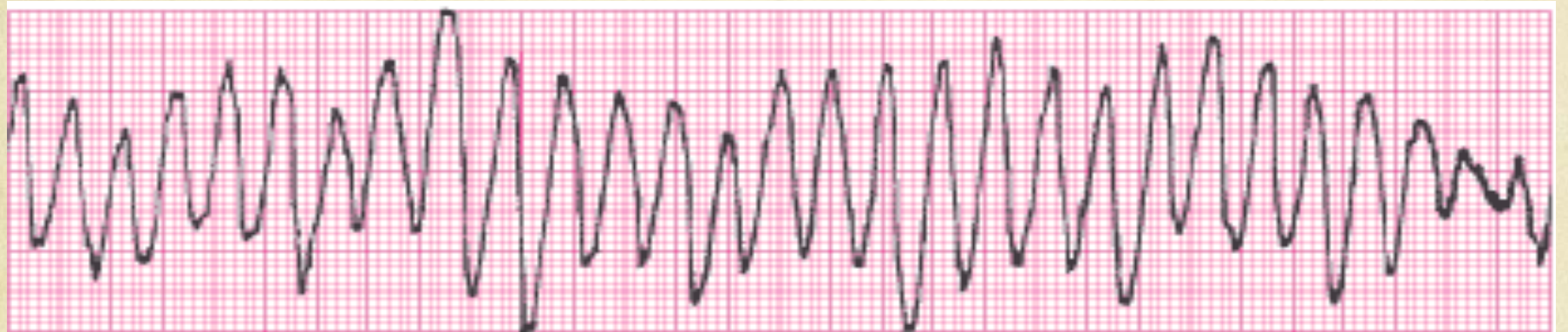





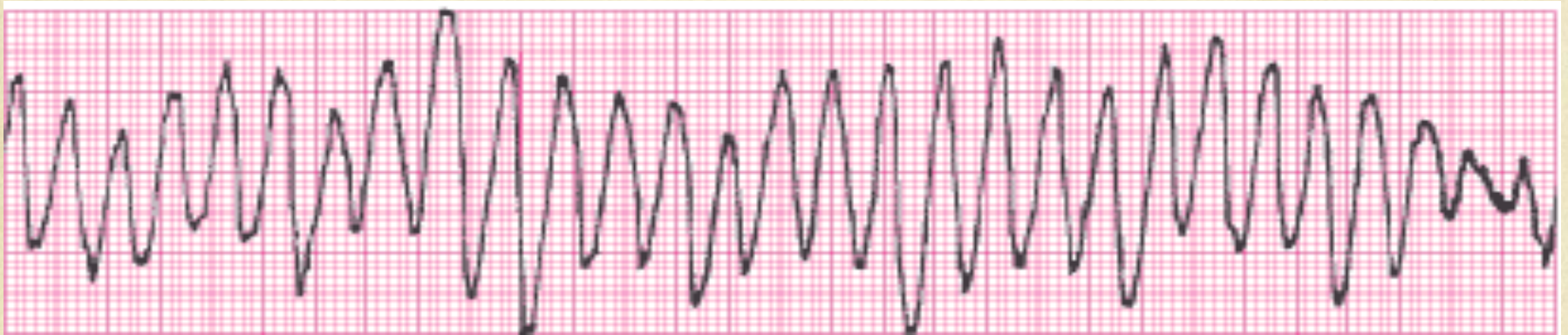# Atrial Fibrillation

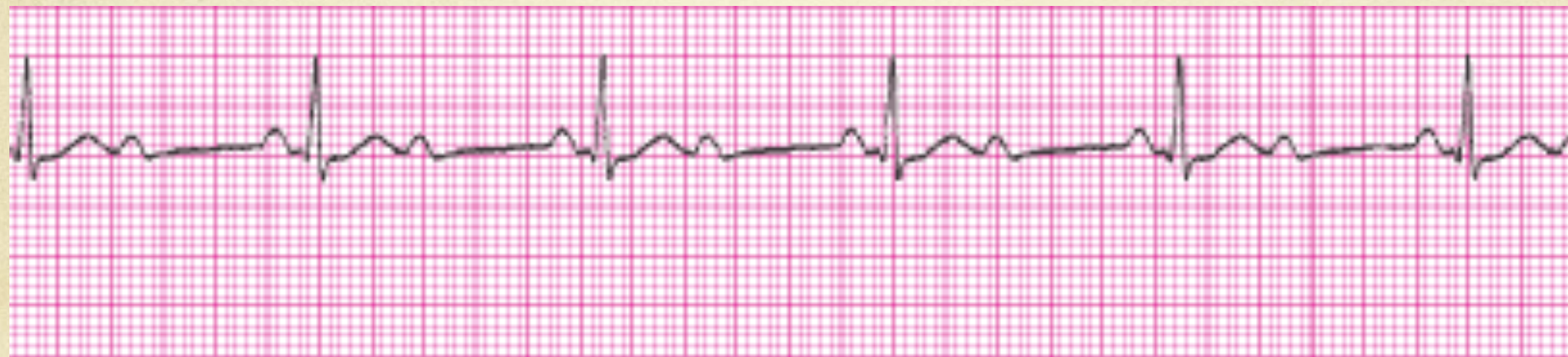





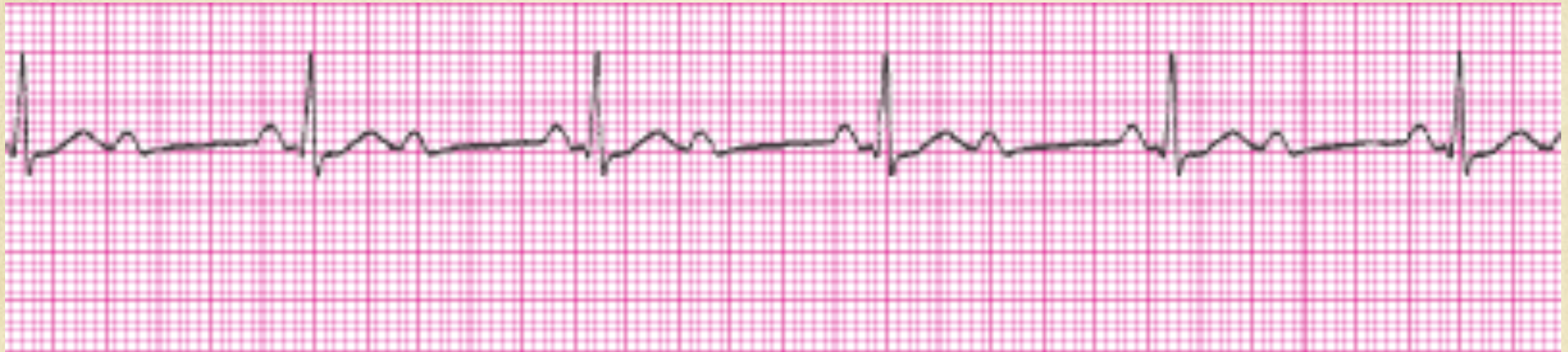# Polymorphic Ventricular Tachycardia

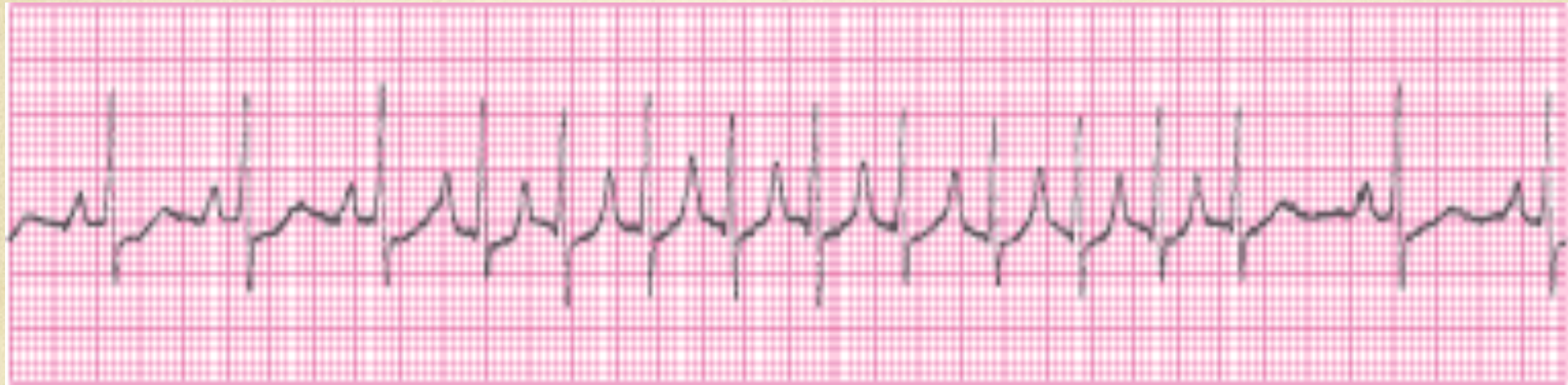





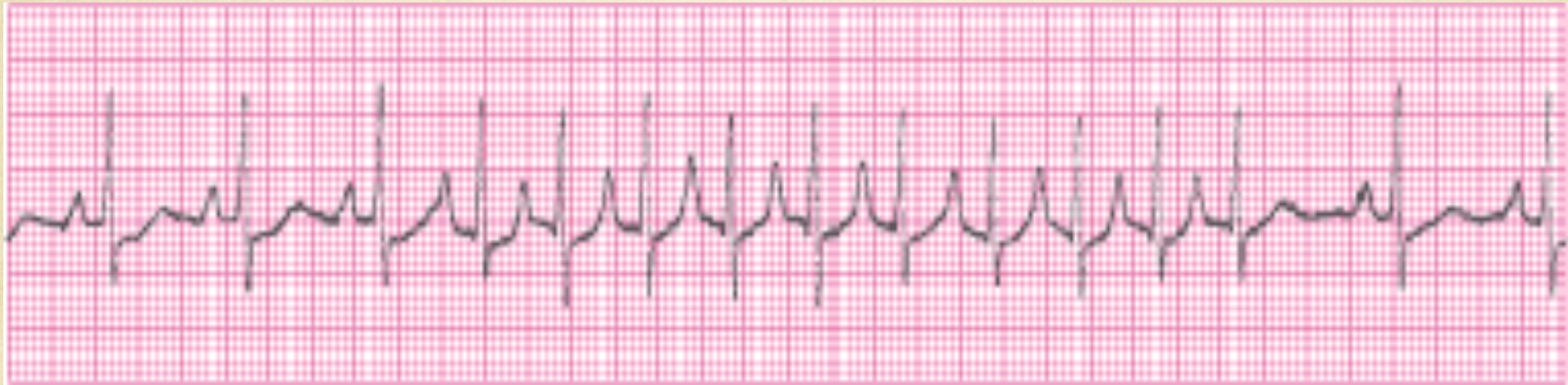# 2:1 Conductive AV Block Probably Type I

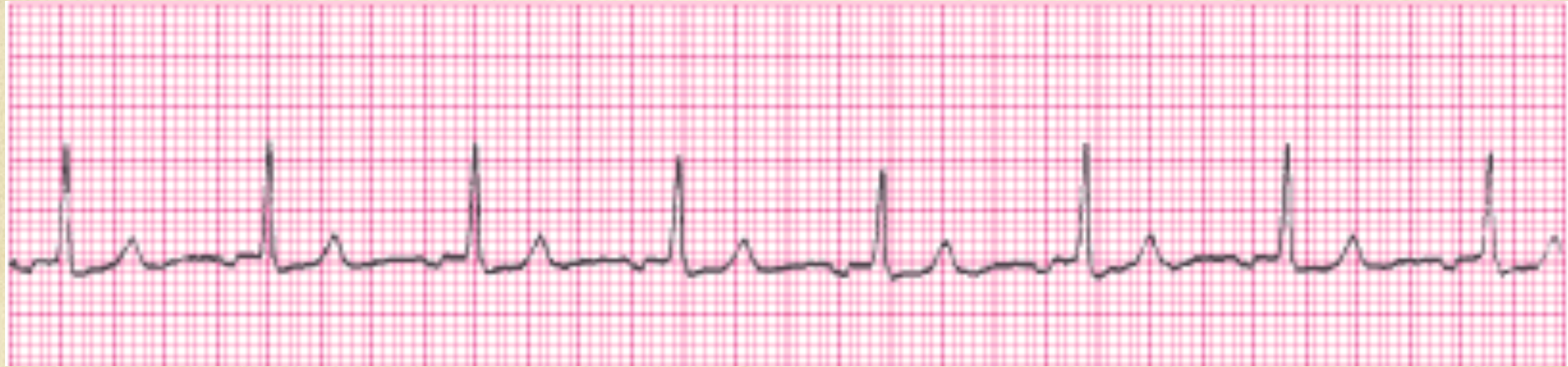





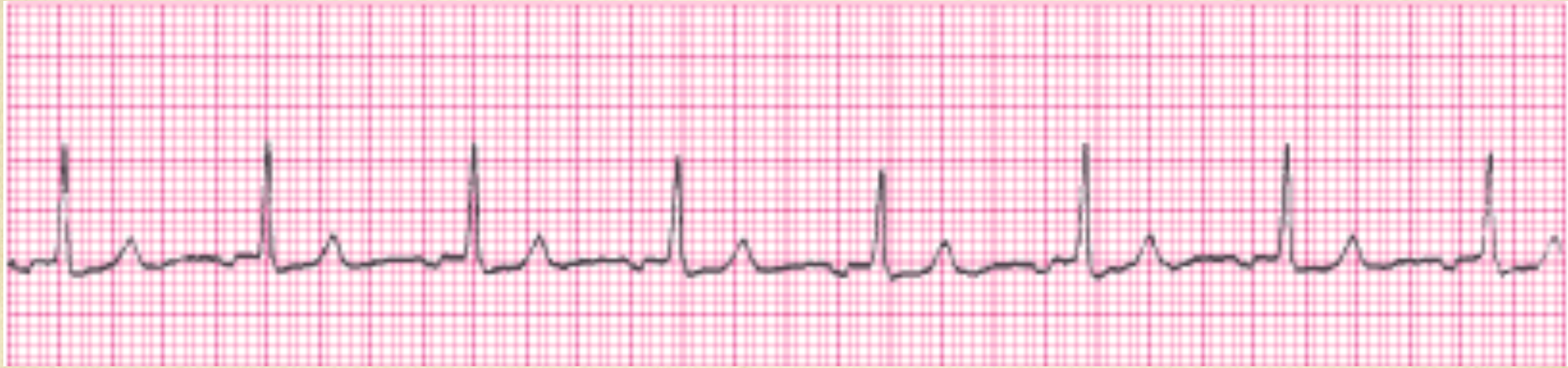# Paroxysmal Supra Ventricular Tachycardia

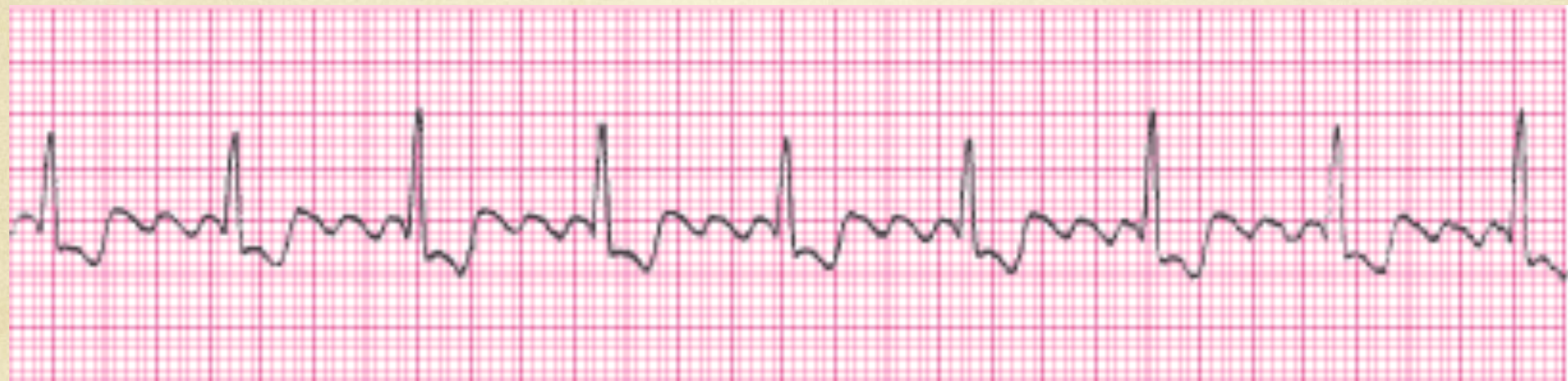





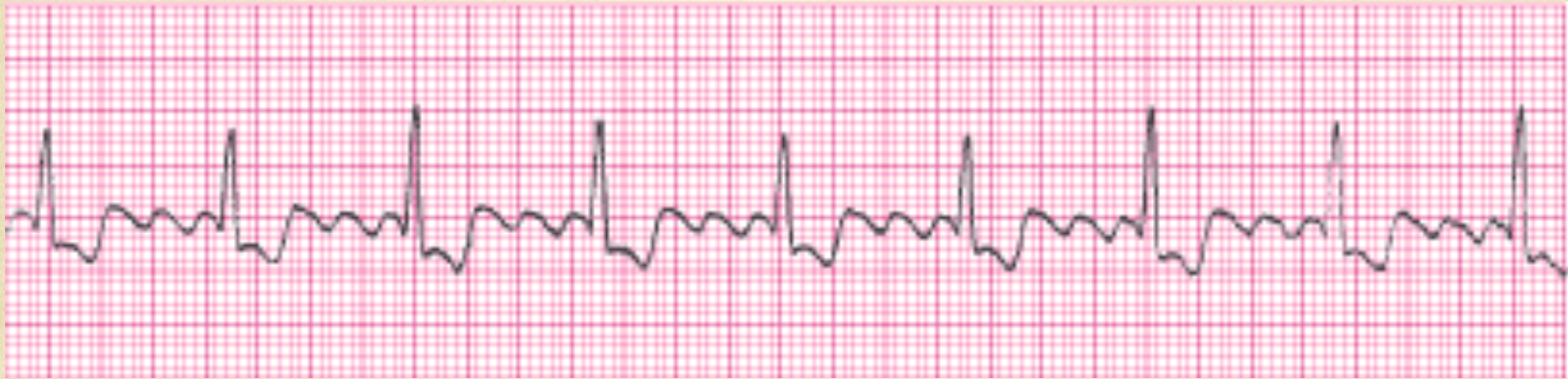# Accelerated Junctional rhythm

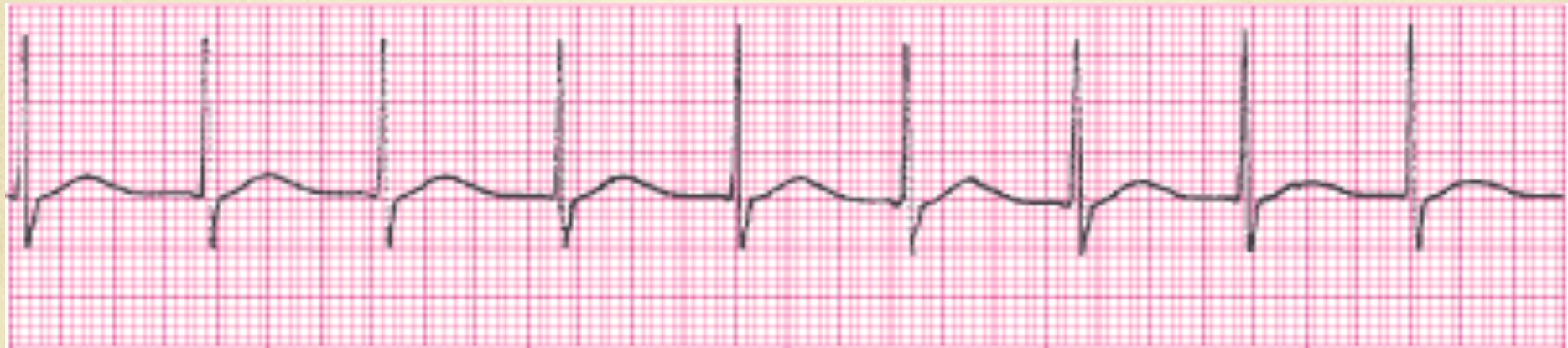





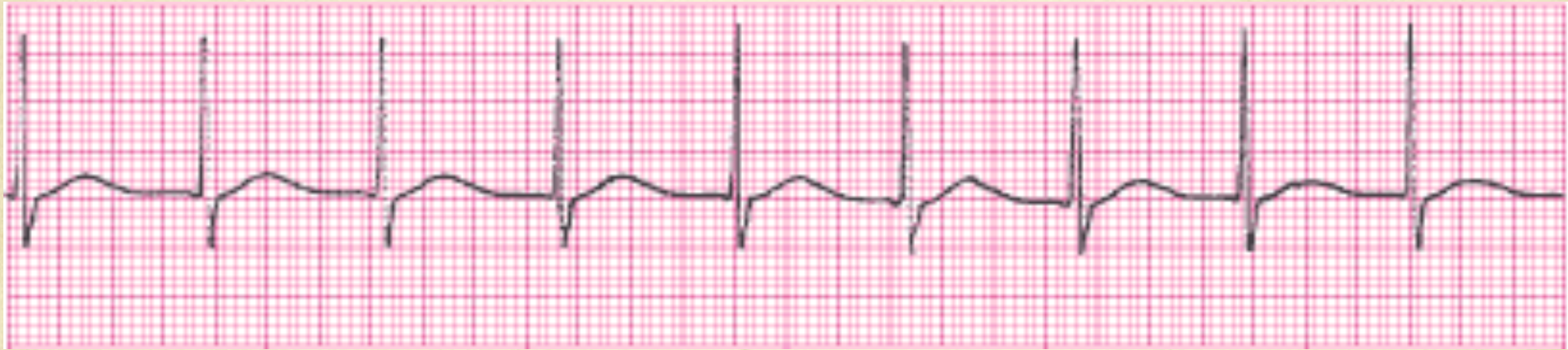# Atrial Flutter

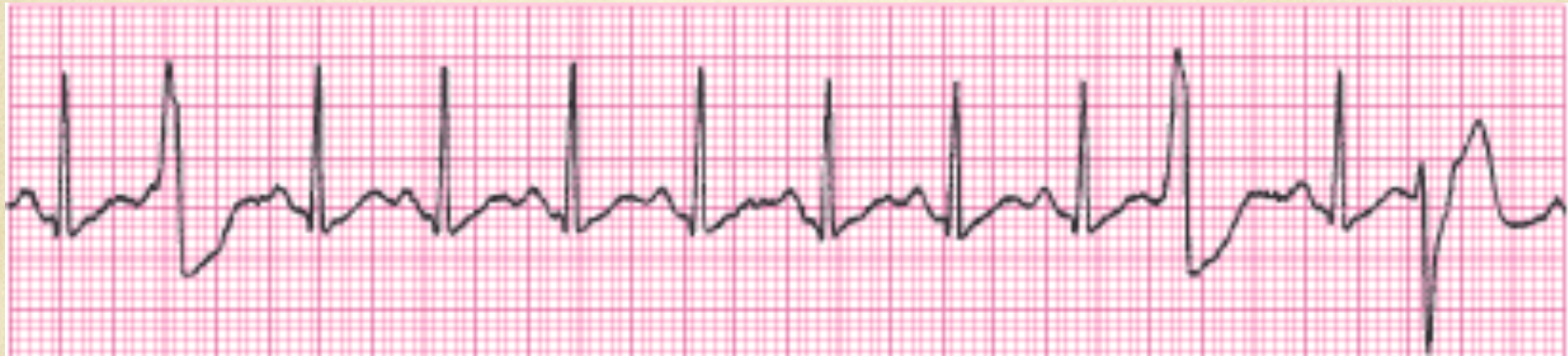





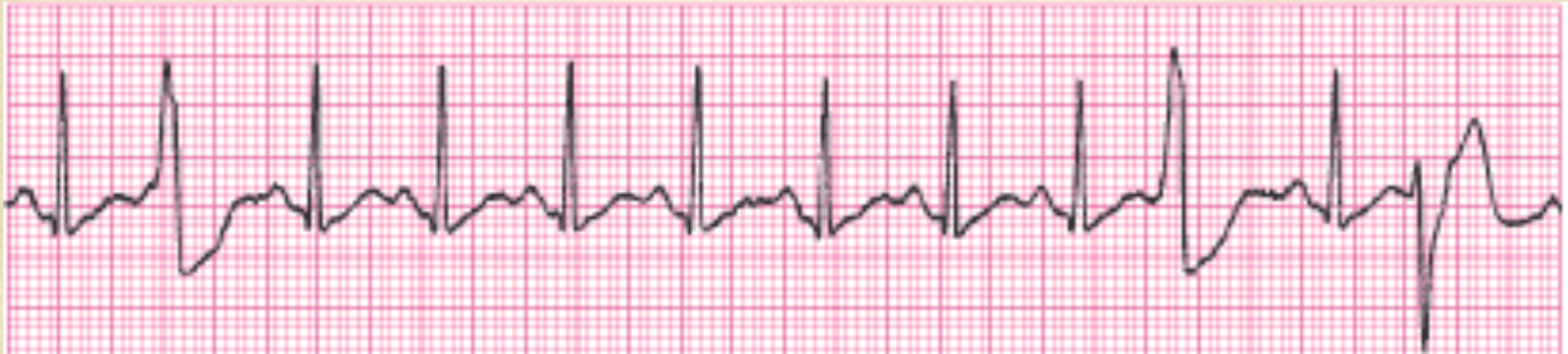# Borderline Junctional Tachycardia

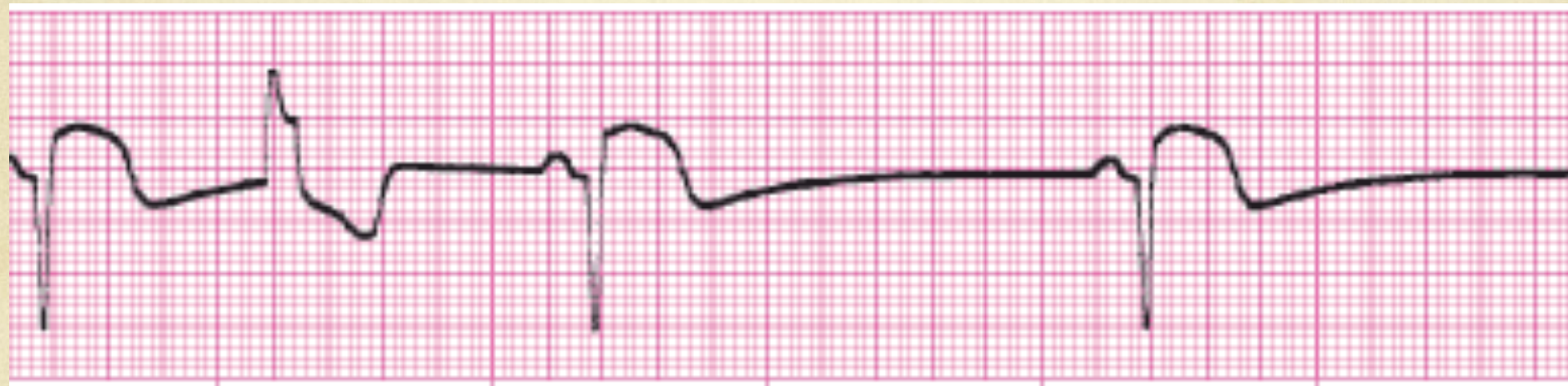






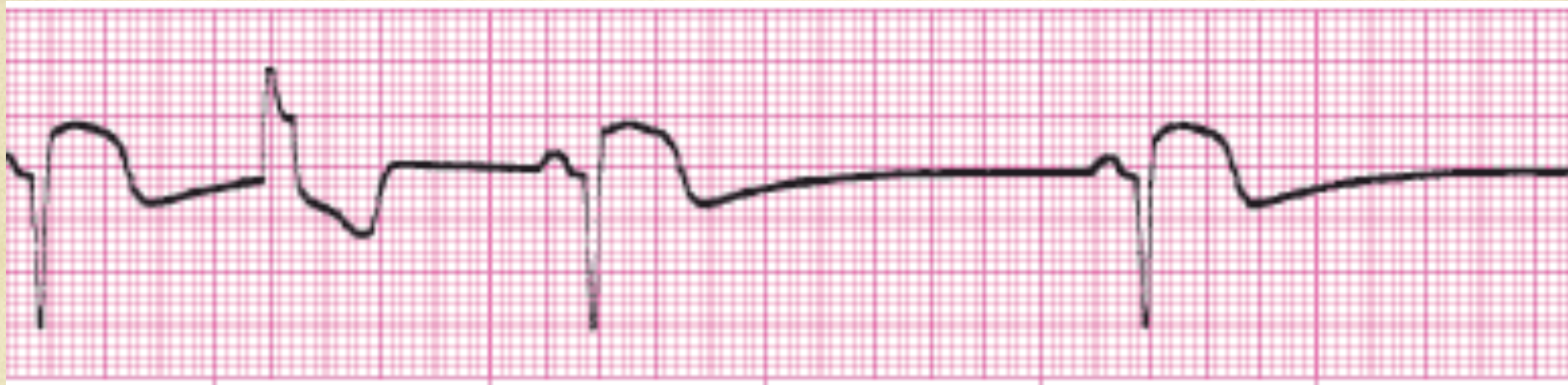
# Sinus Tachycardia with Multiform PVC's

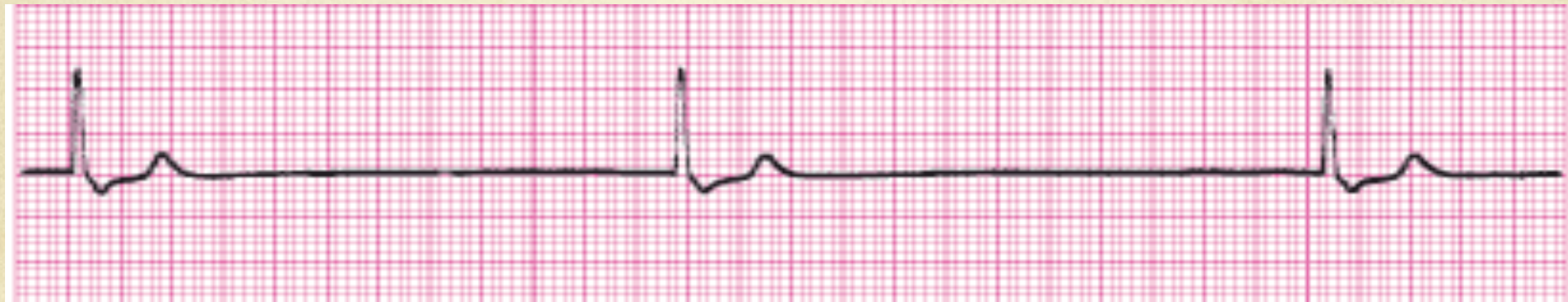





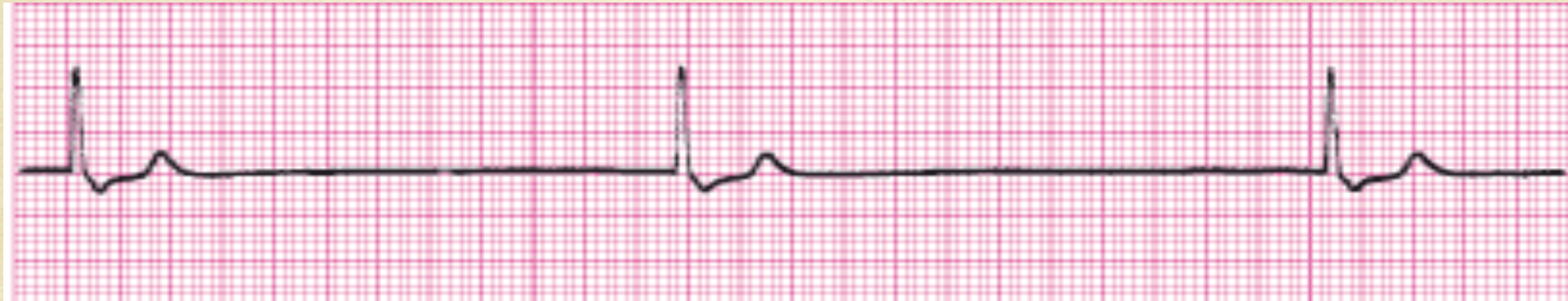# Sinus Bradycardia with Uniform PVC

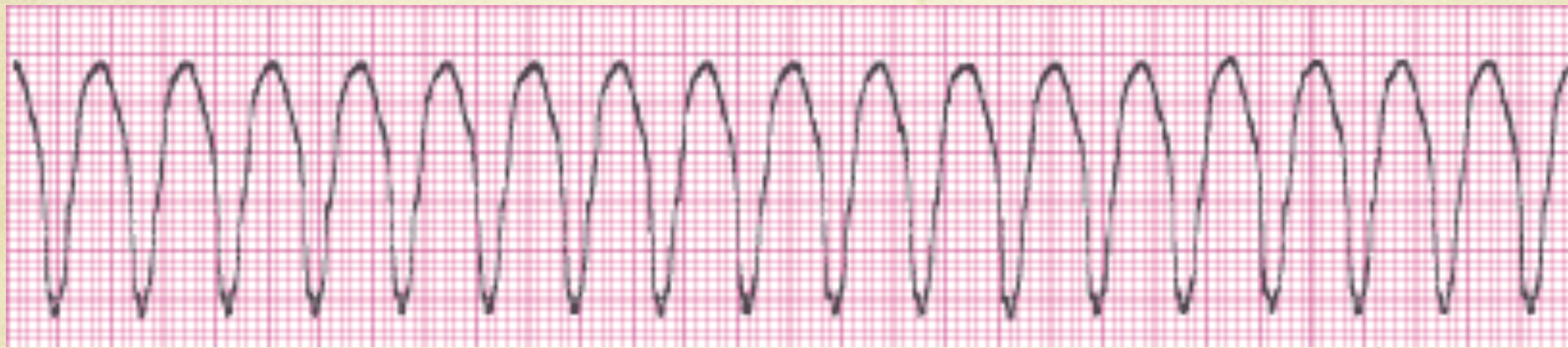





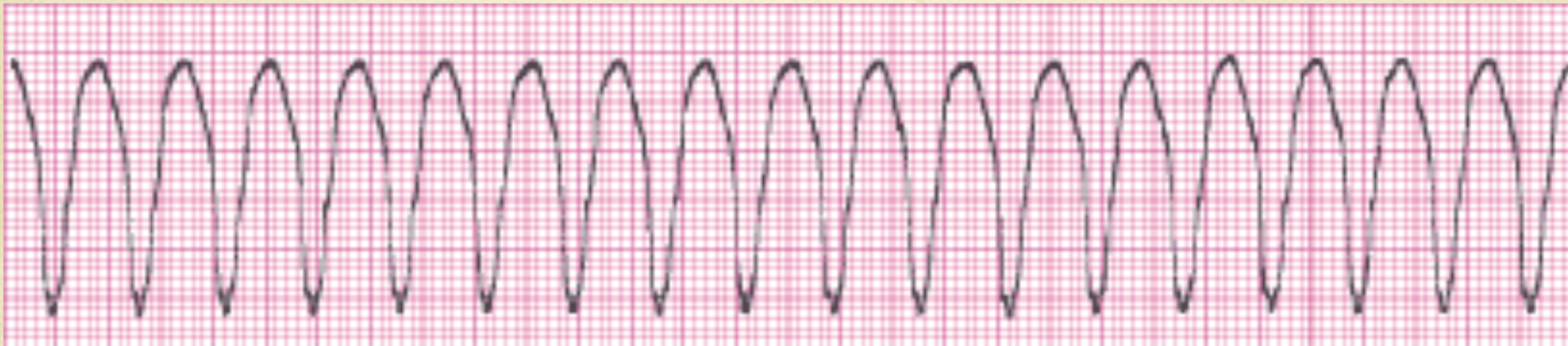# Junctional Escape Rhythm @ 30

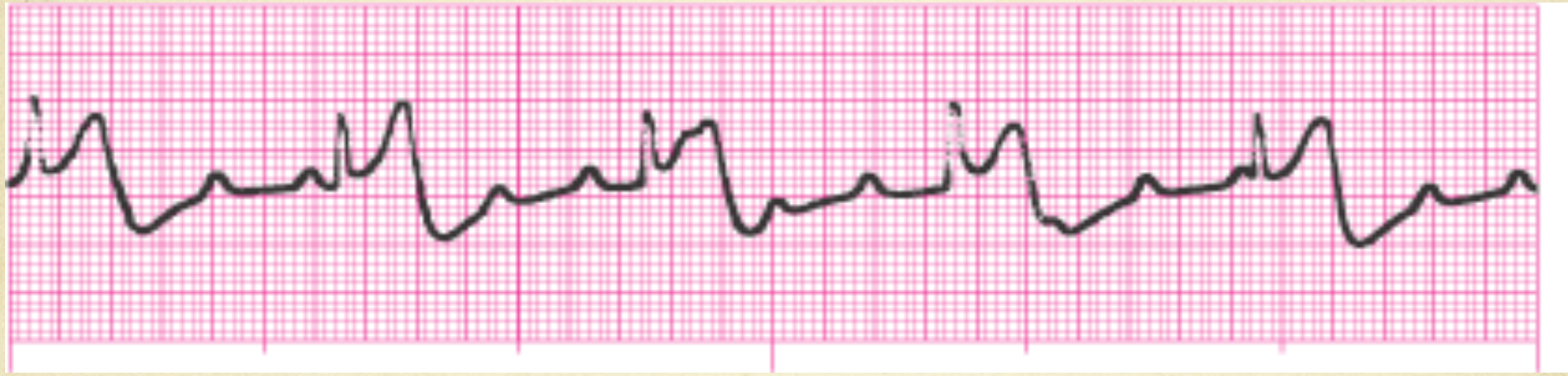





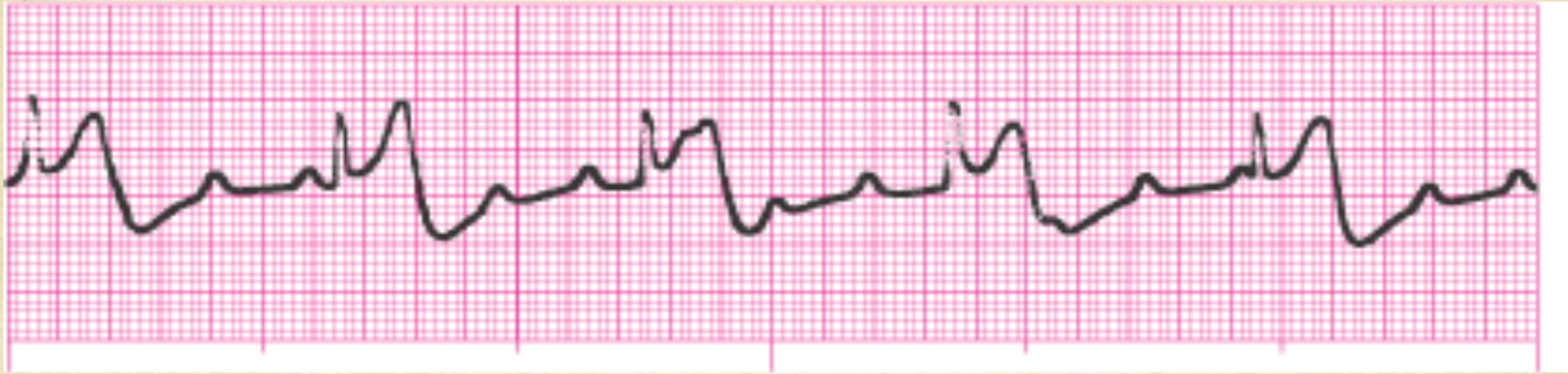# Monomorphic Ventricular Tachycardia

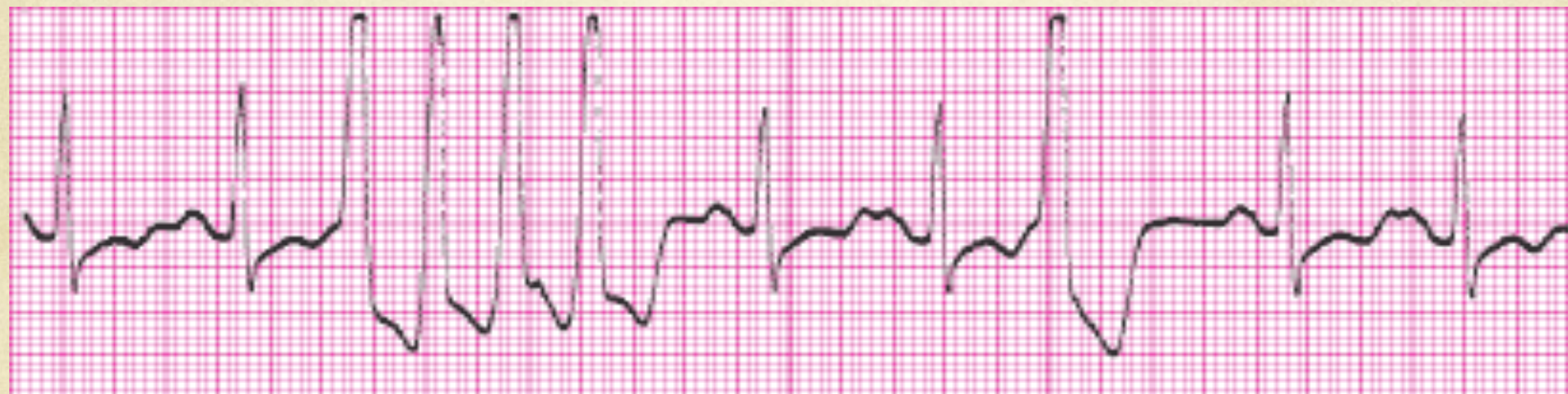





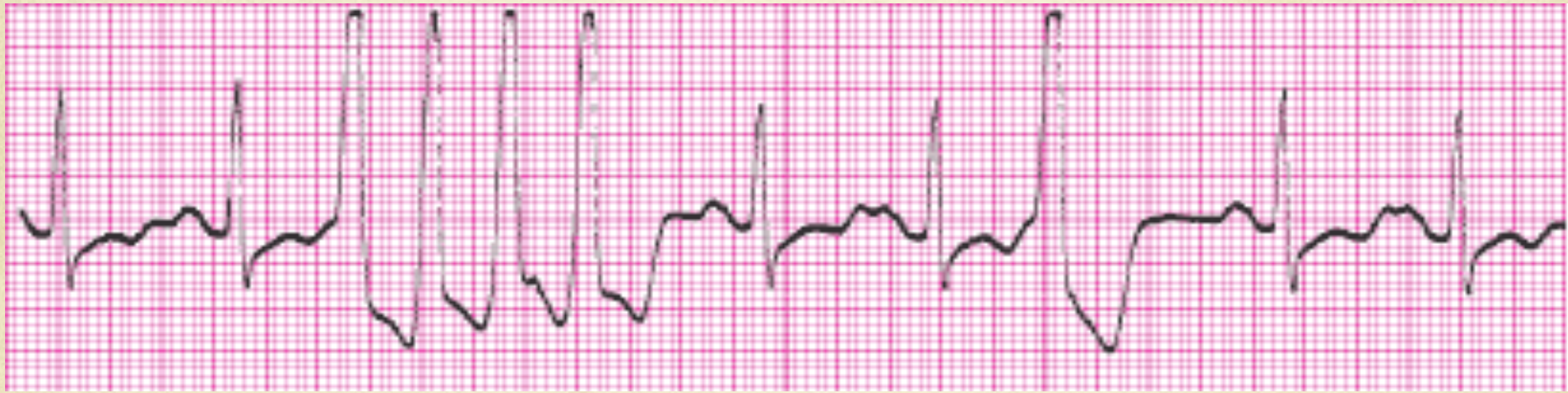# Complete third degree heart block

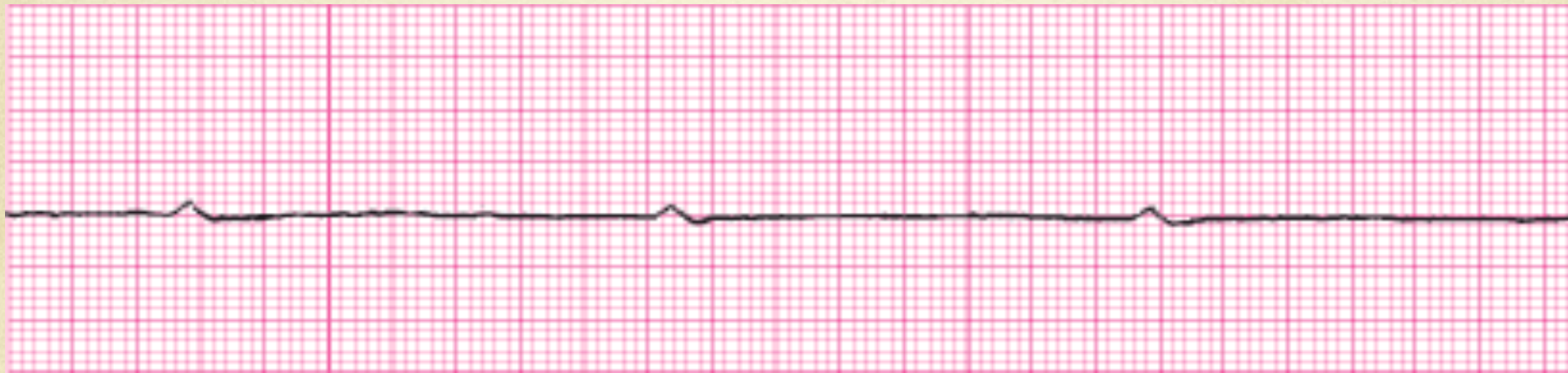





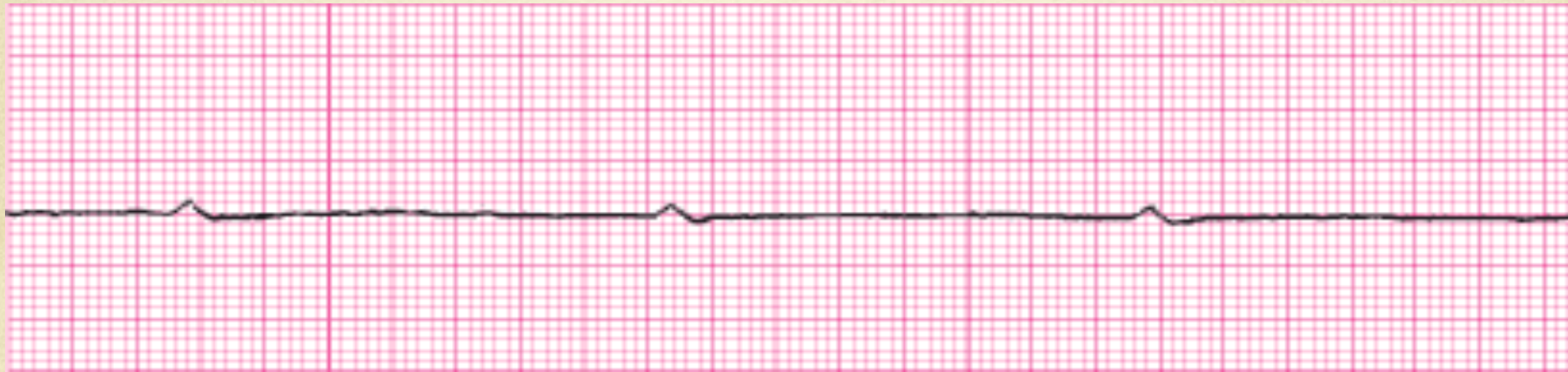# Sinus With a Run of V-Tach

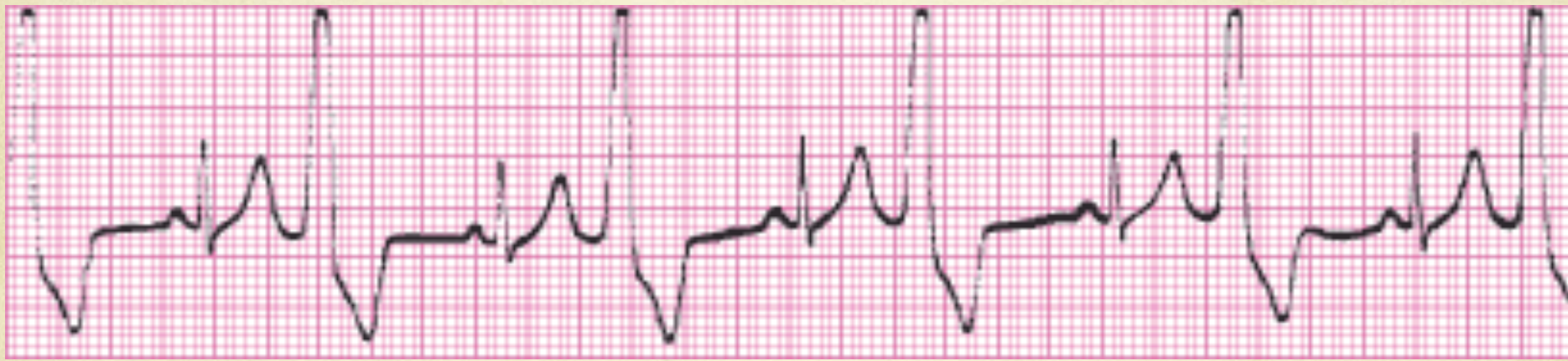





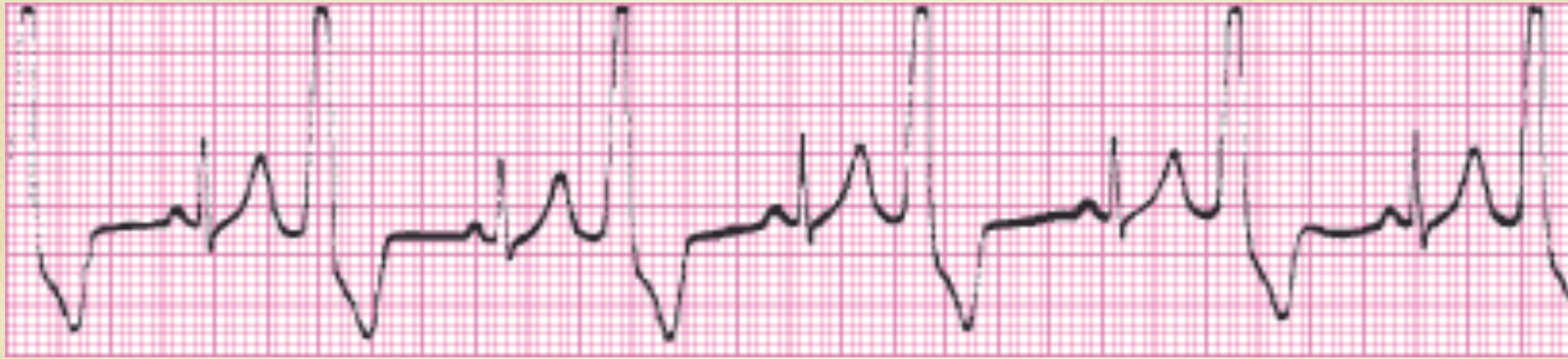# P Wave Asystole

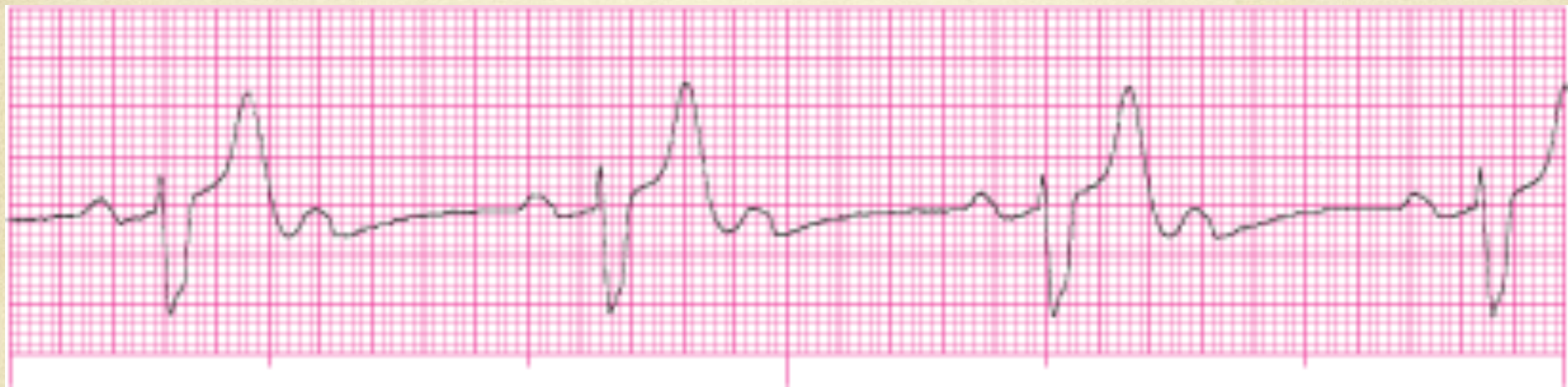





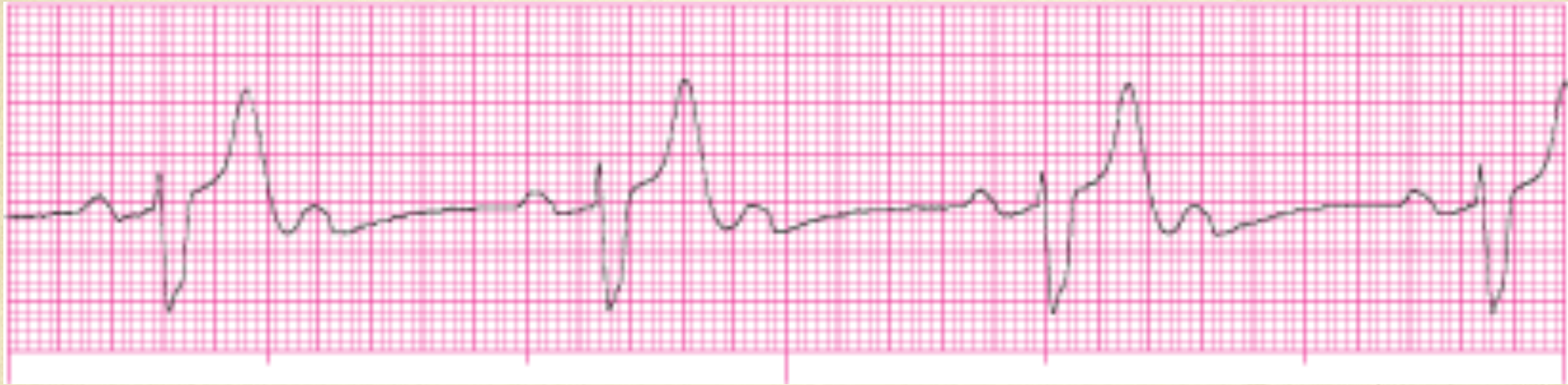# Sinus Bradycardia with Bigeminal PVC's

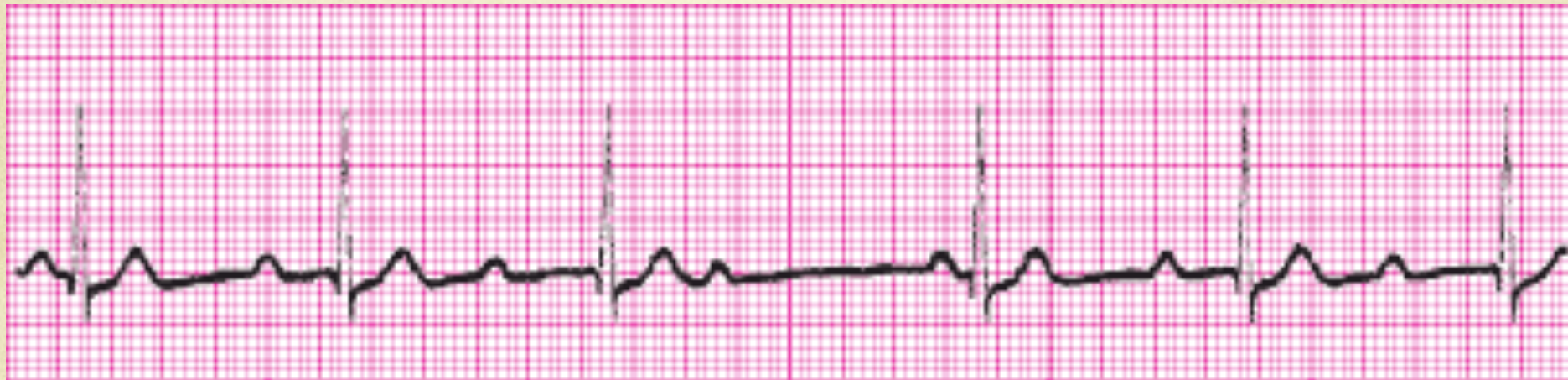






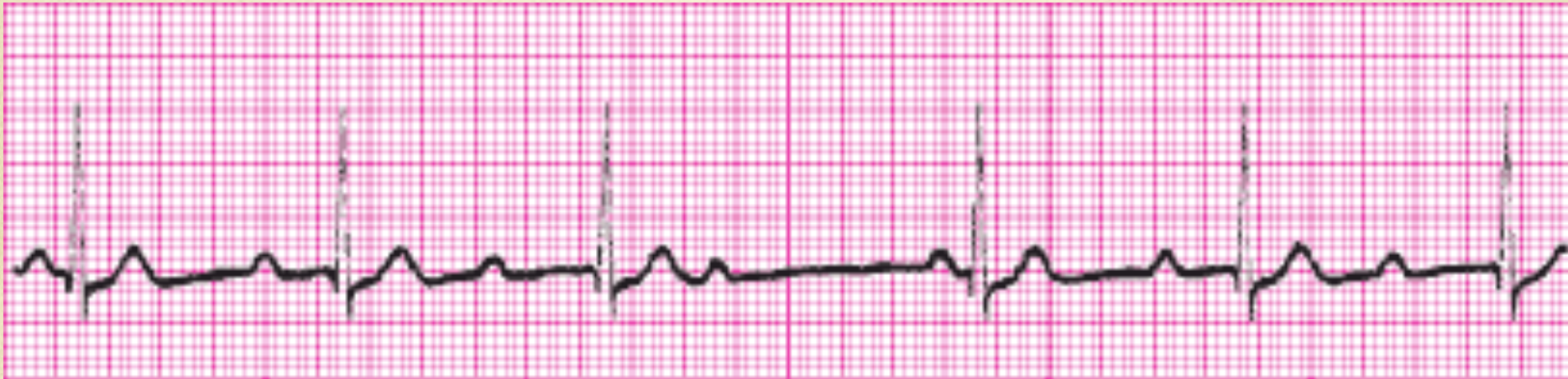
# Complete Third Degree Heart Block

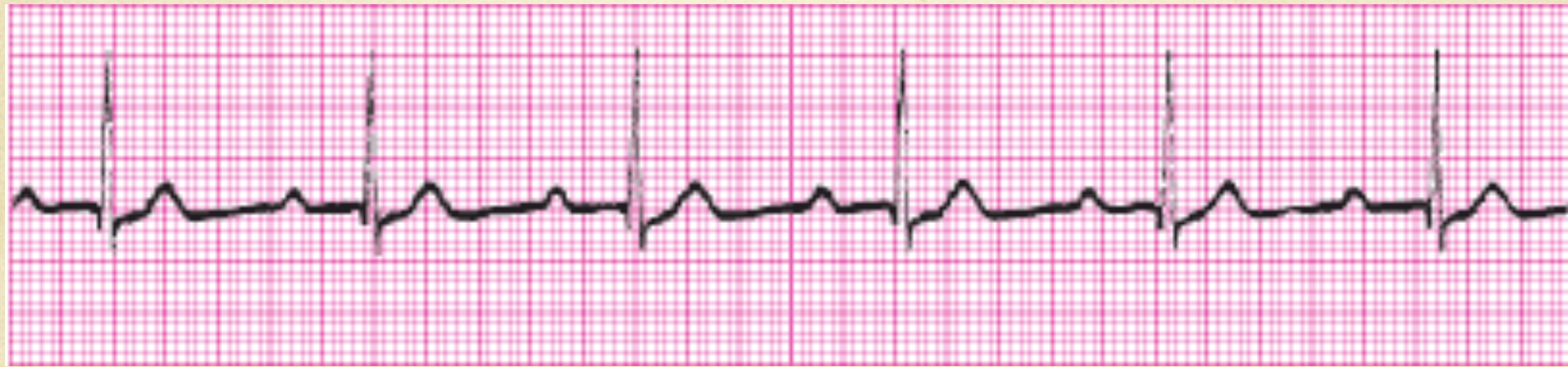





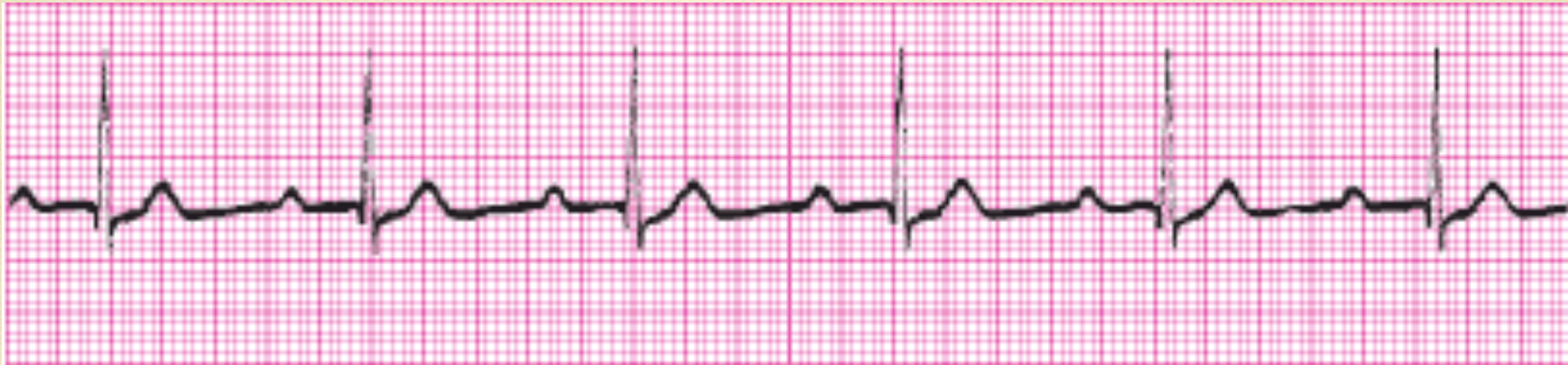# Second Degree Heart Block Type I (Wenkebach)

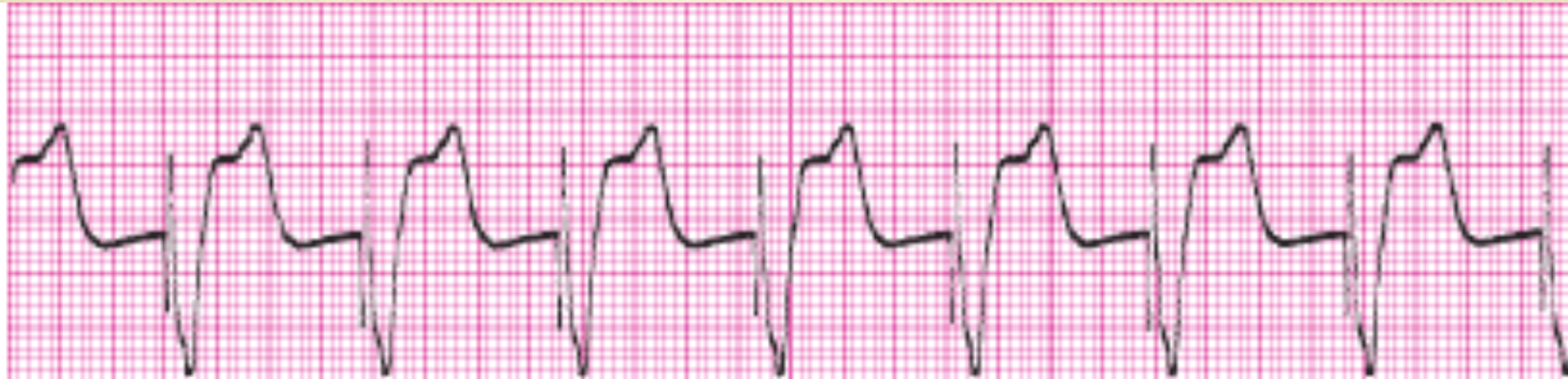





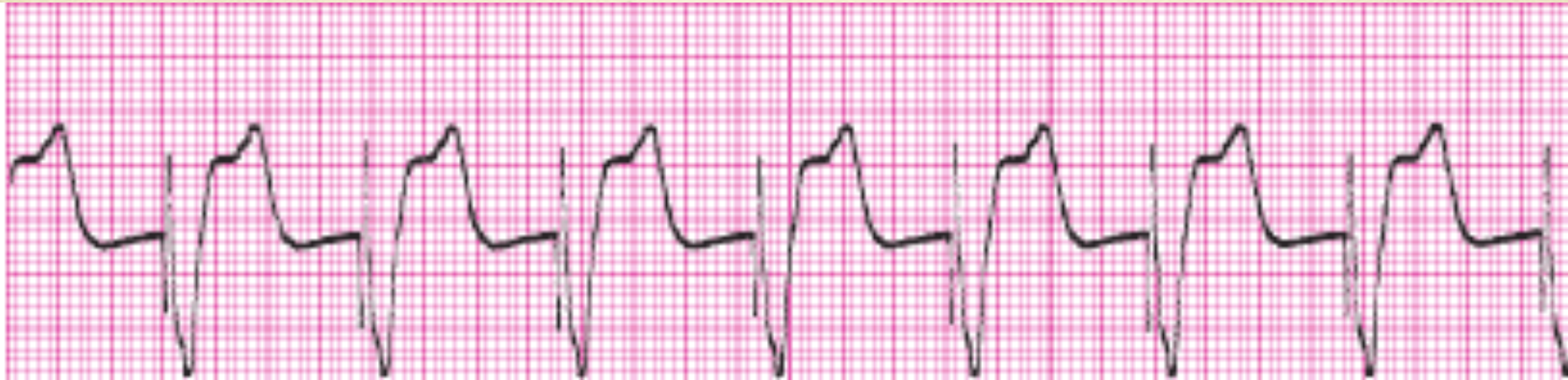# Sinus with a First Degree AV Block

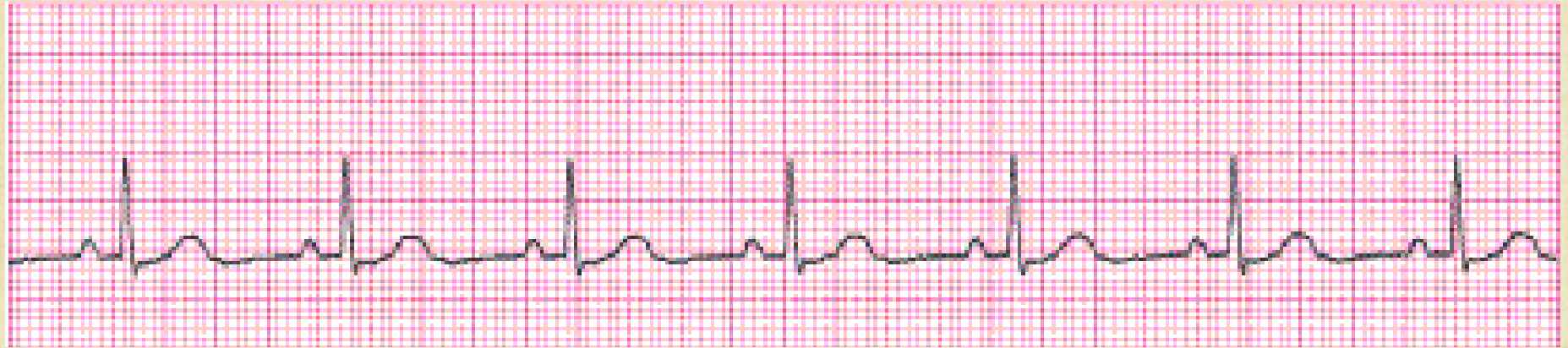





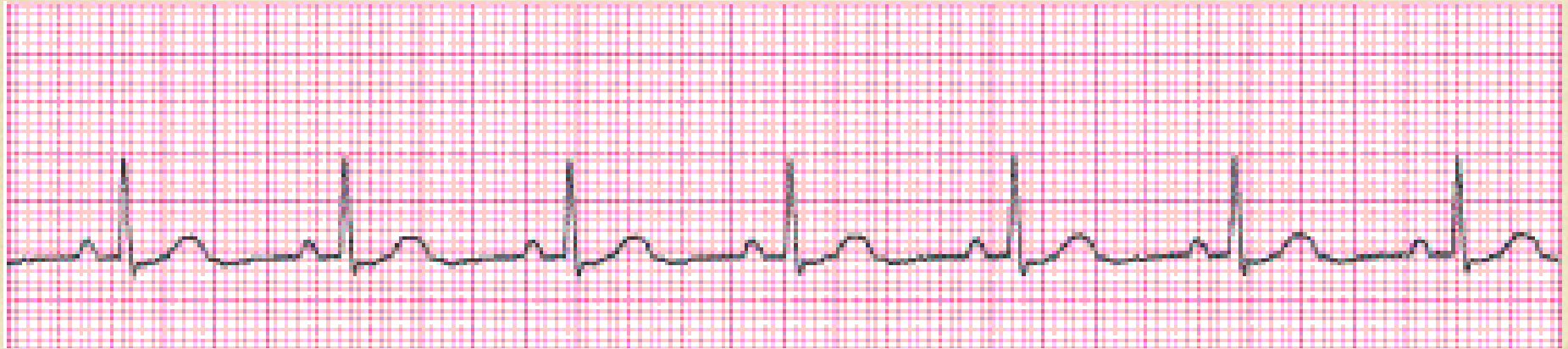# 100% Ventricular Paced Rhythm

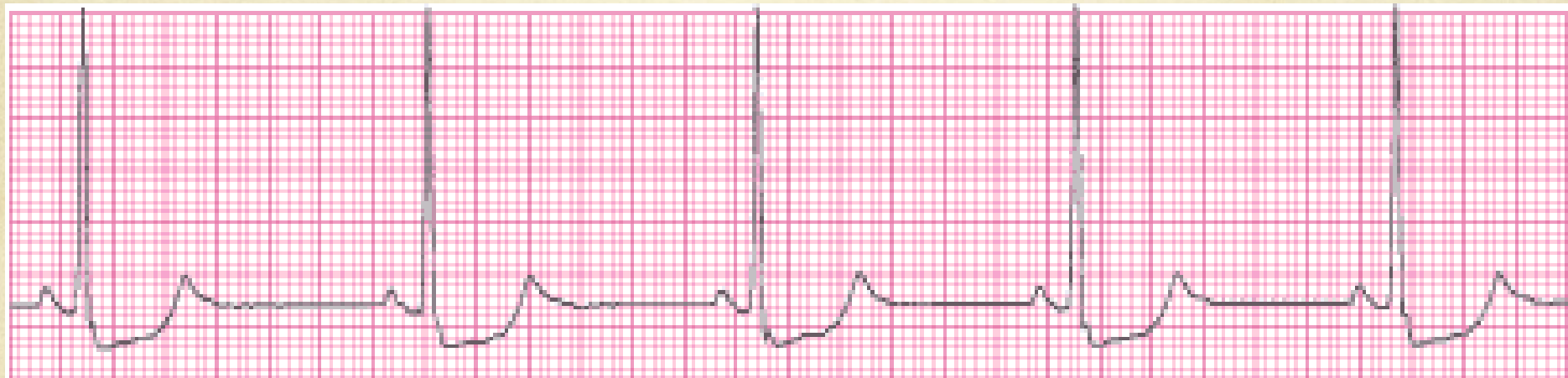




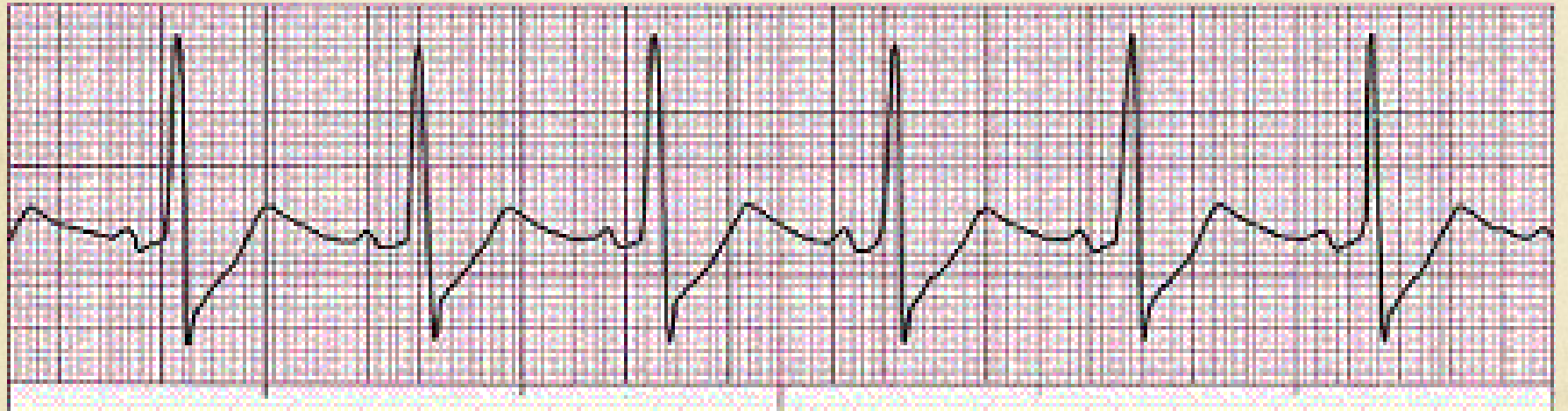
# Normal Sinus Rhythm

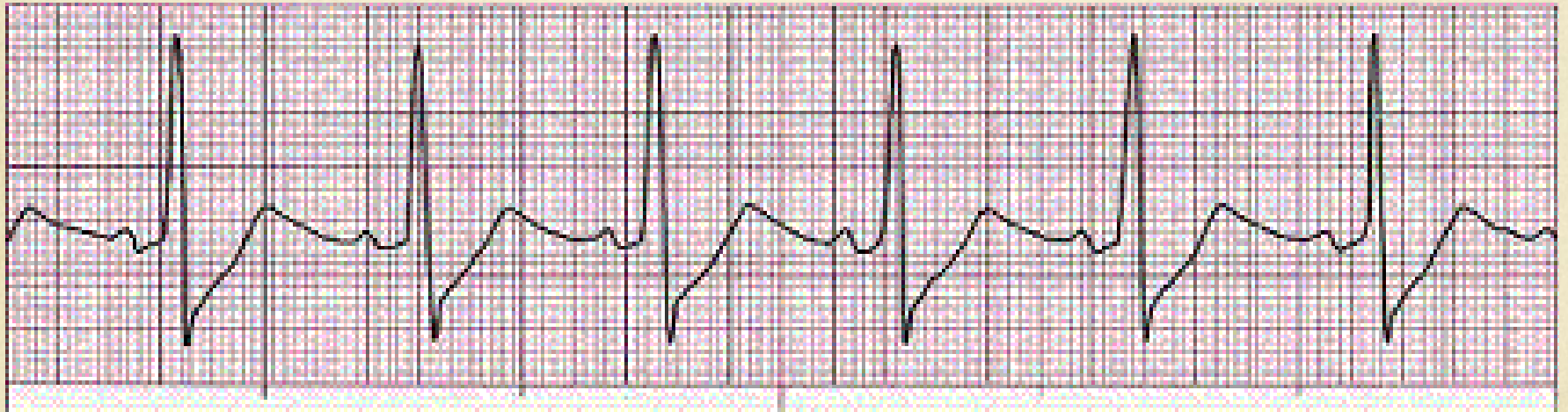



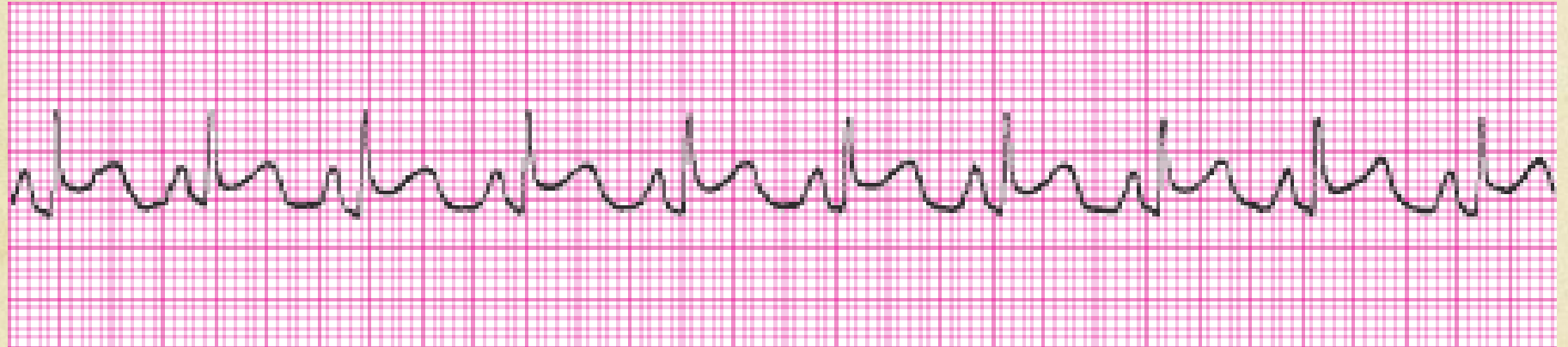




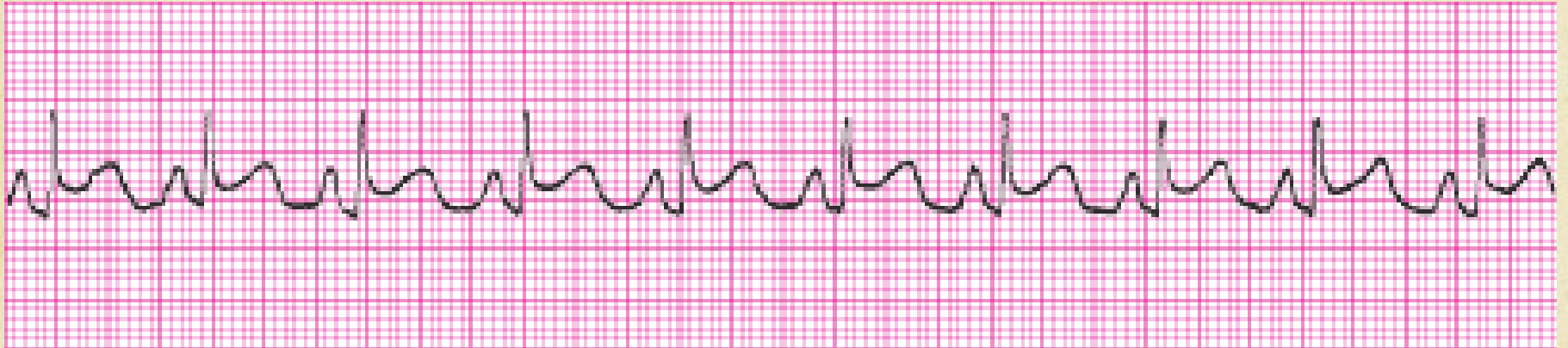
# Normal Sinus rhythm



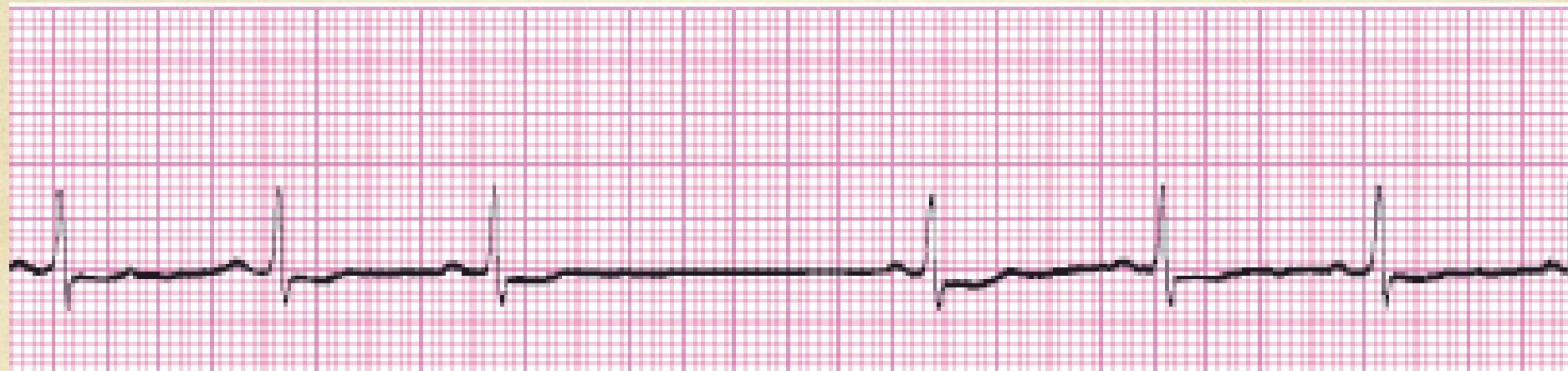



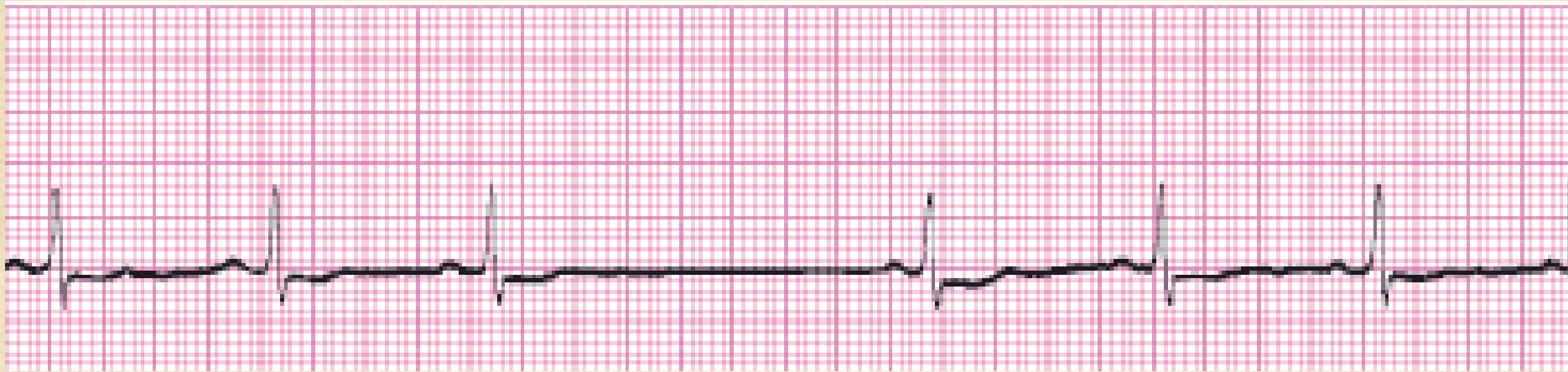# Borderline Sinus Tachycardia



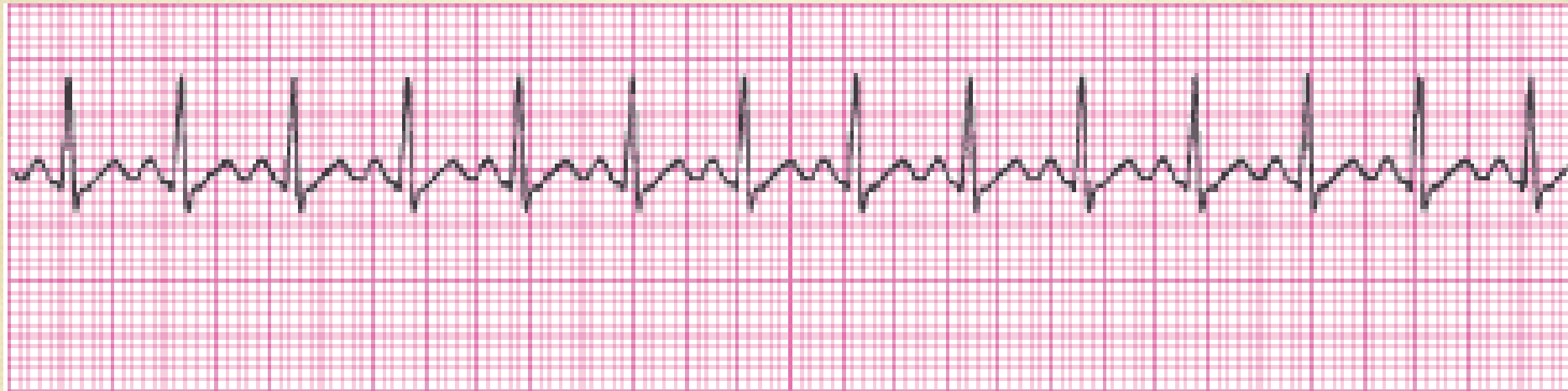



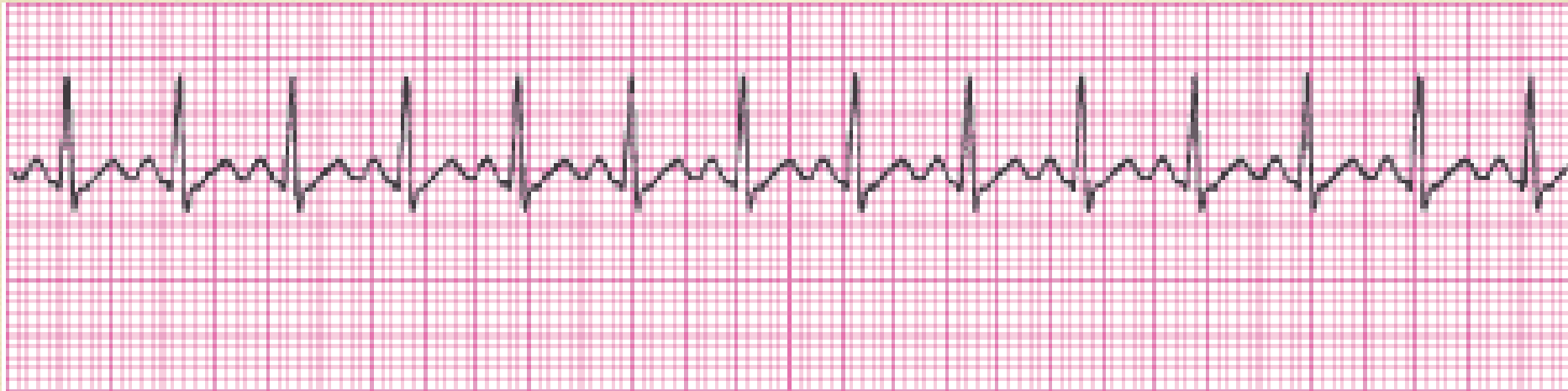# Sinus with an episode of sinus block



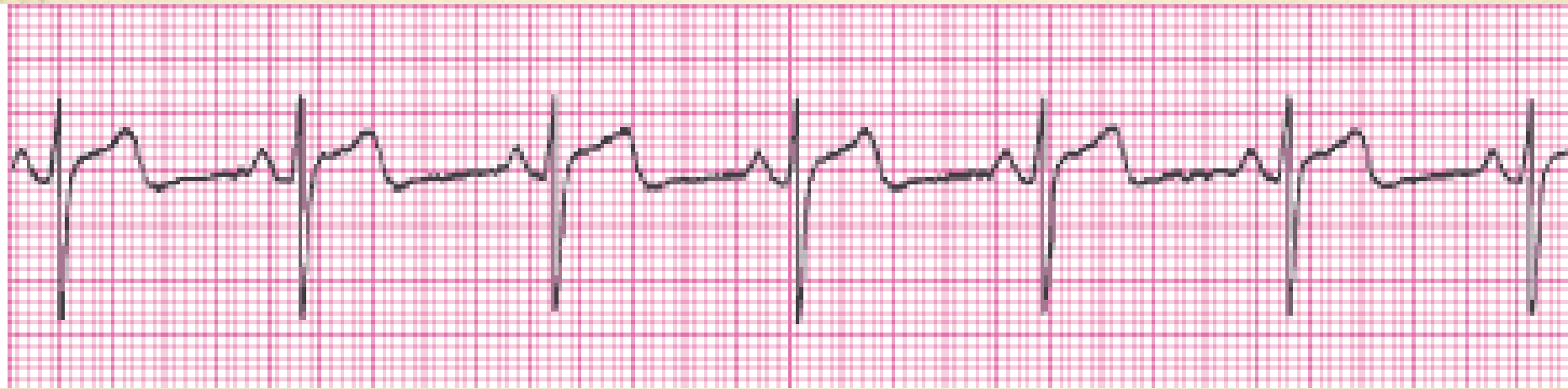



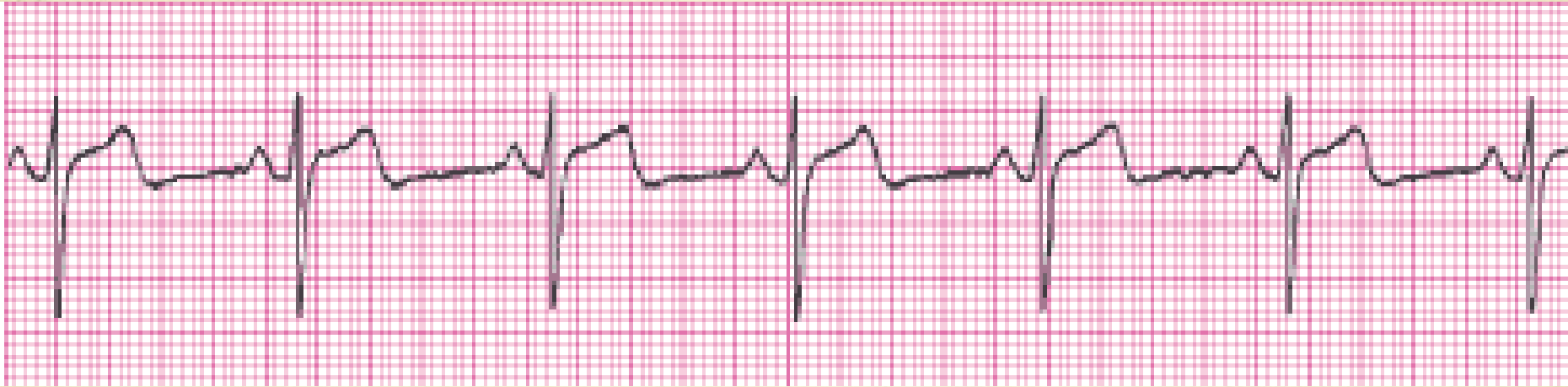# Sinus Tachycardia



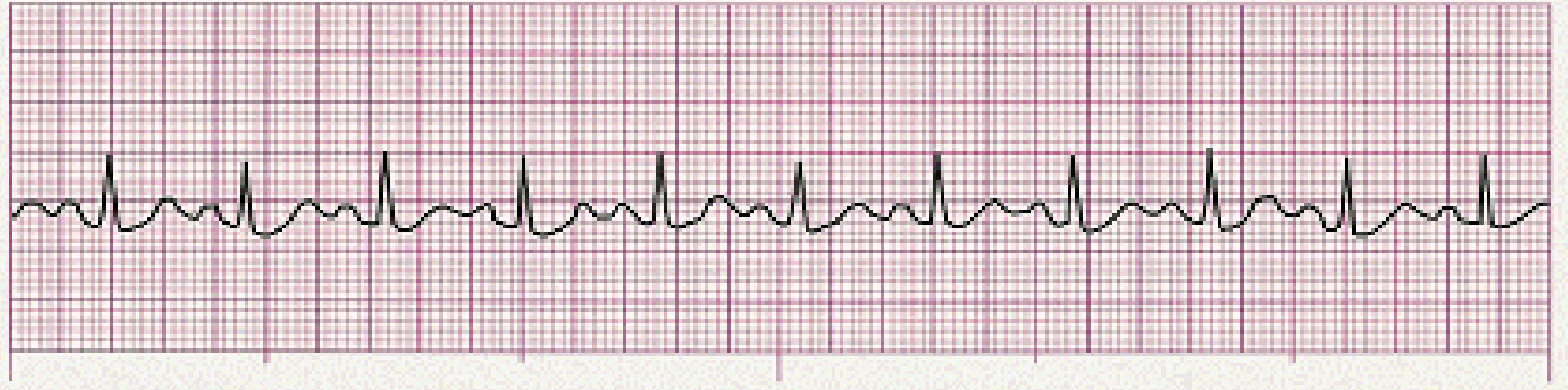



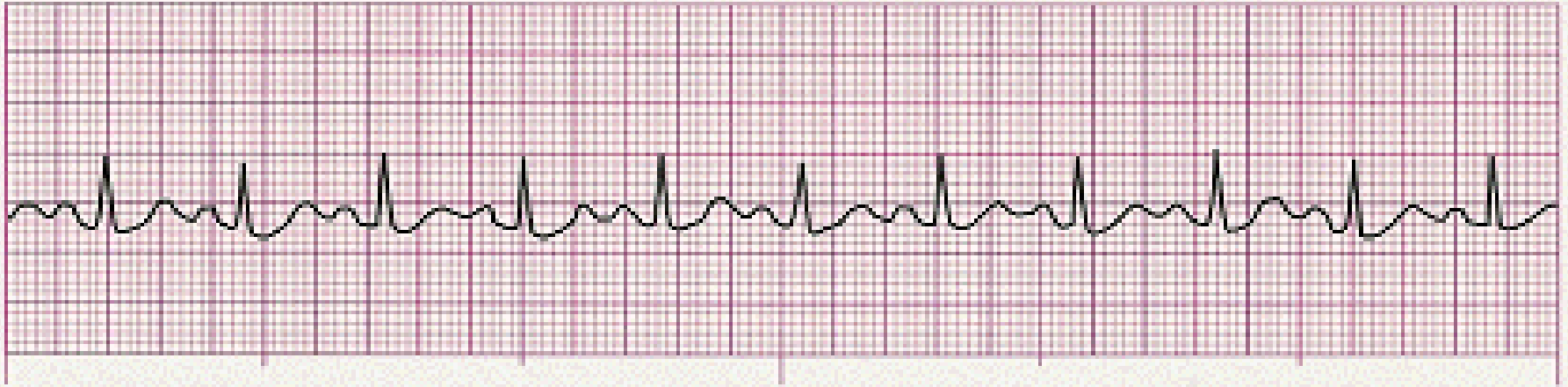# Normal Sinus Rhythm



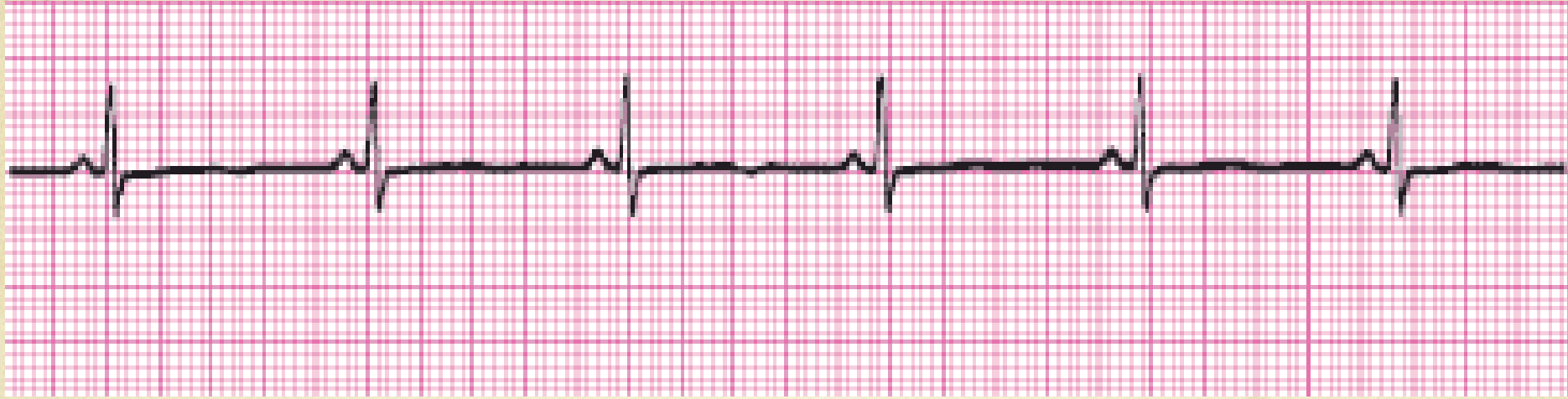




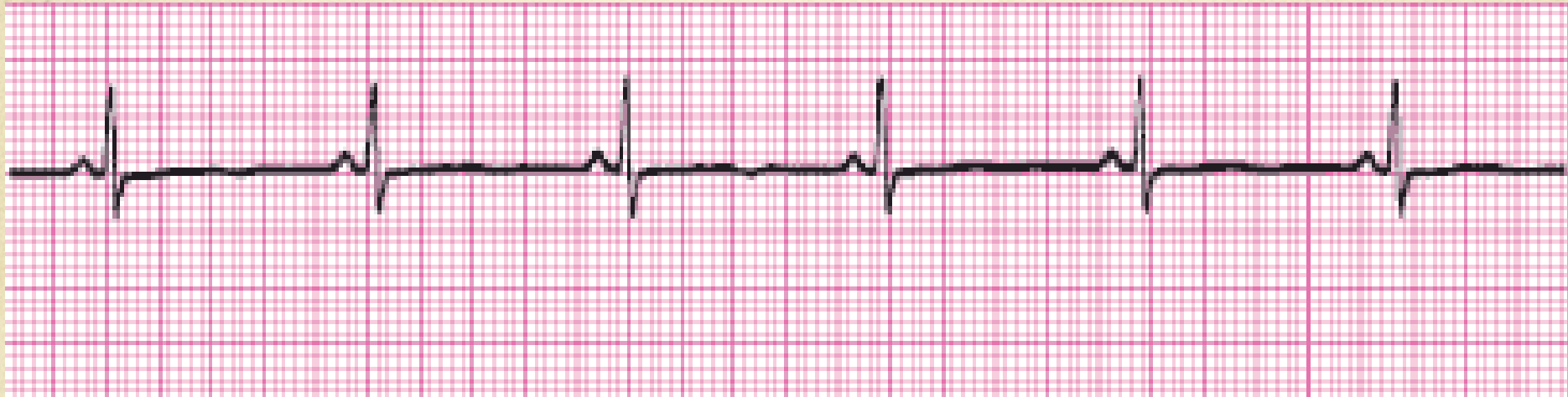
# Sinus Tachycardia

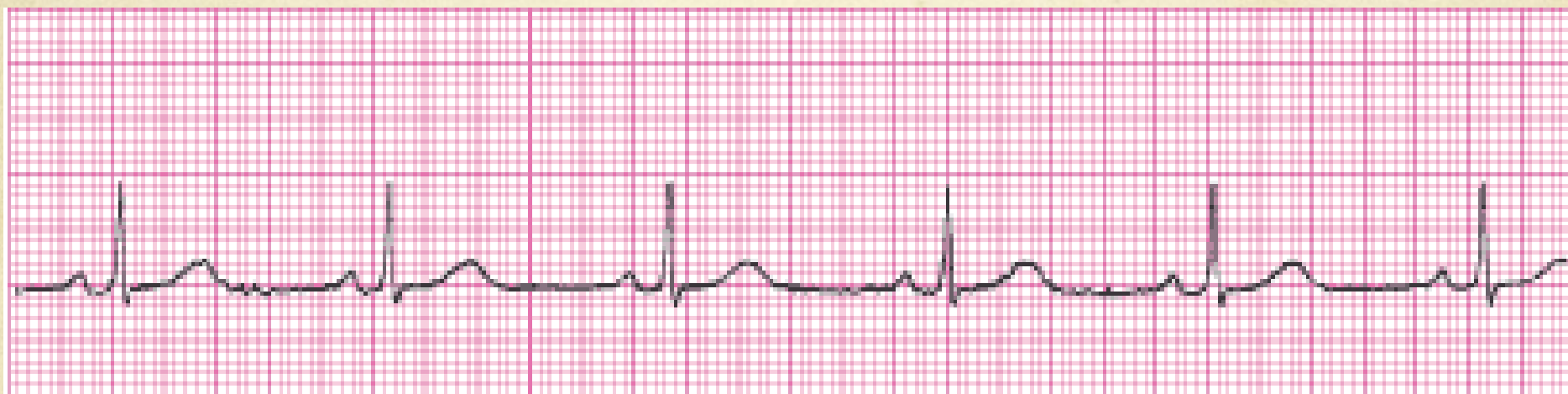





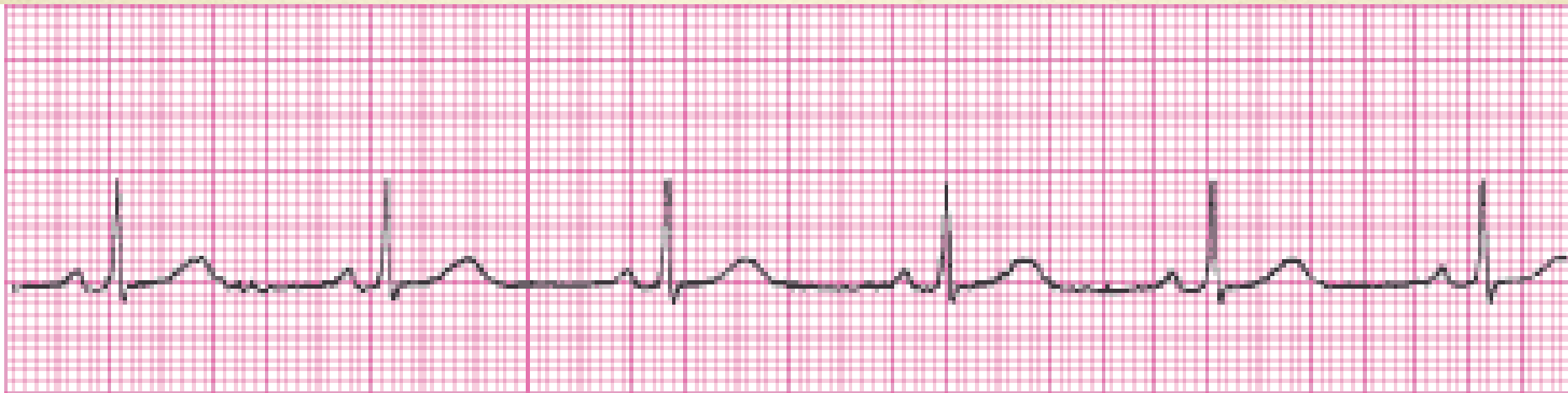# Normal Sinus Rhythm

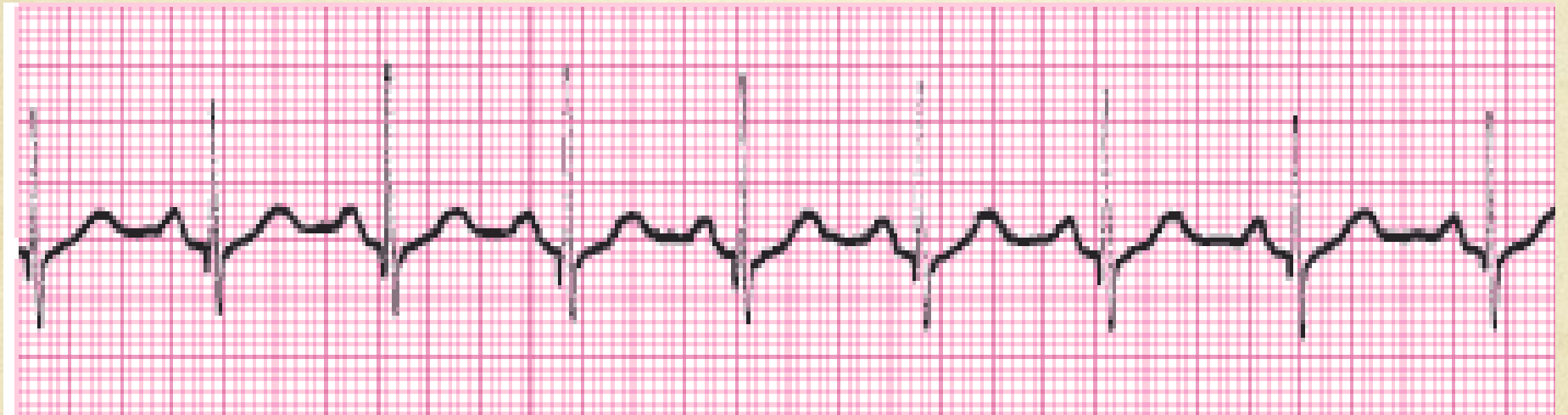




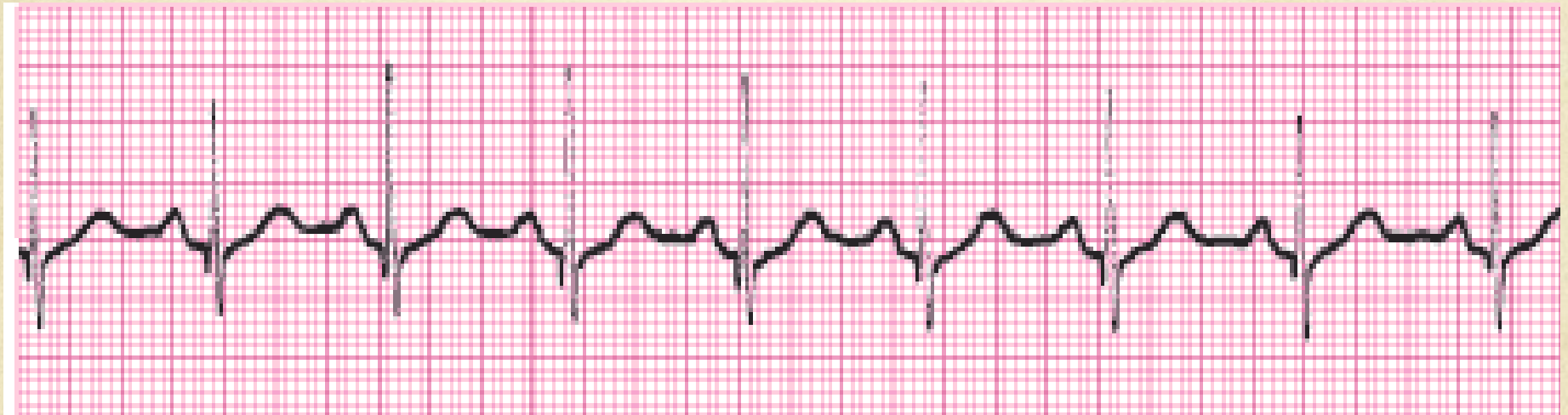
# Normal Sinus Rhythm

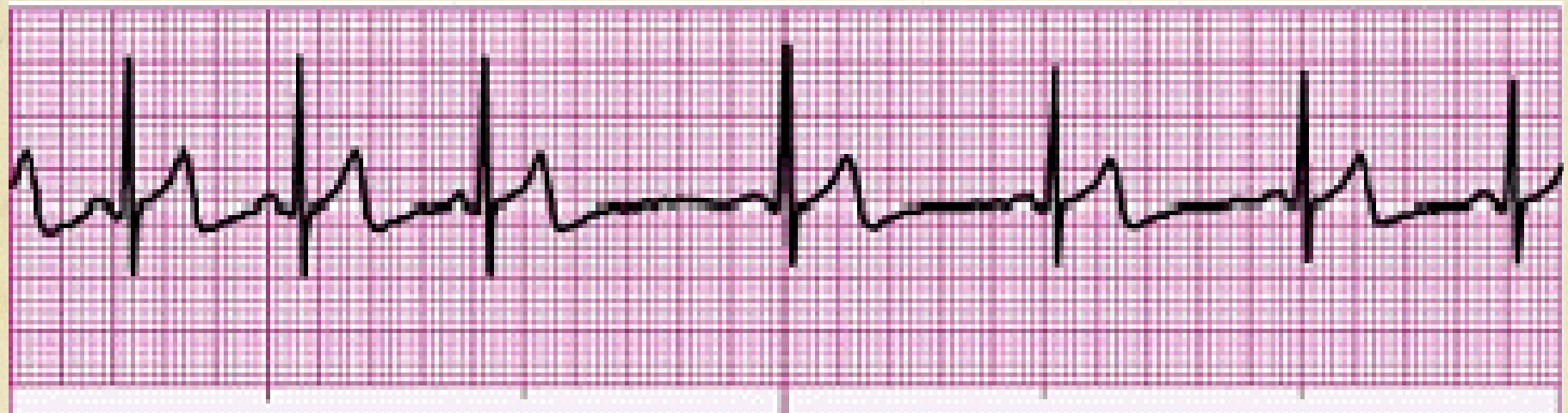



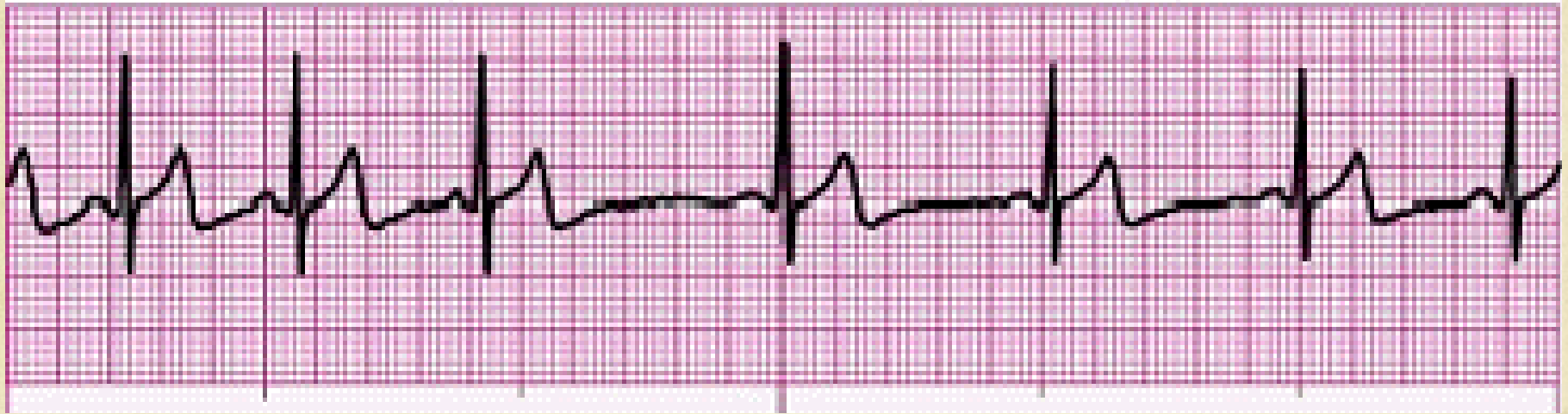# Normal Sinus Rhythm

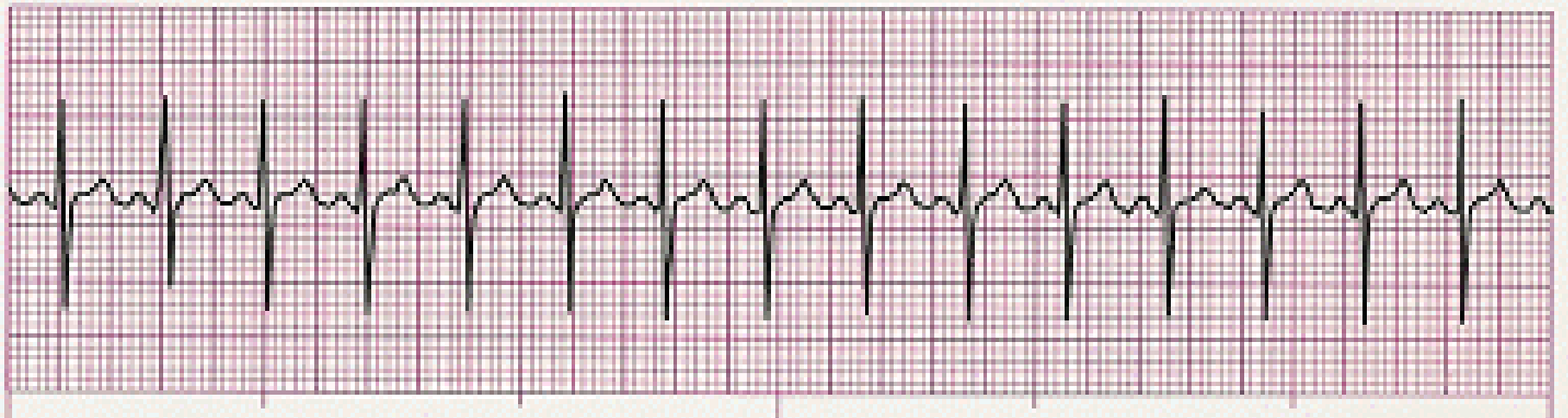





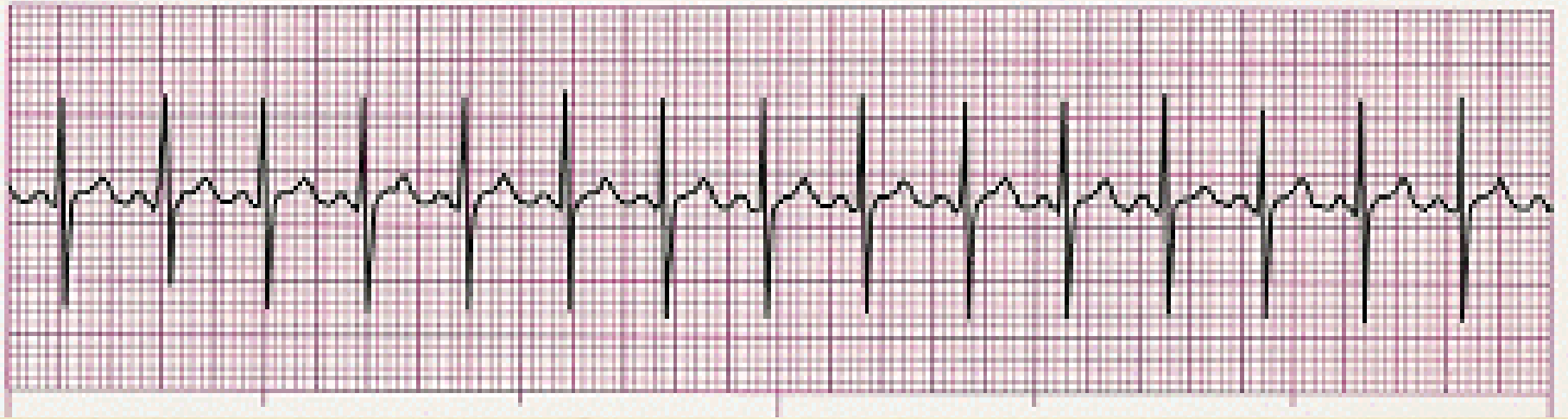# Sinus Arrhythmia

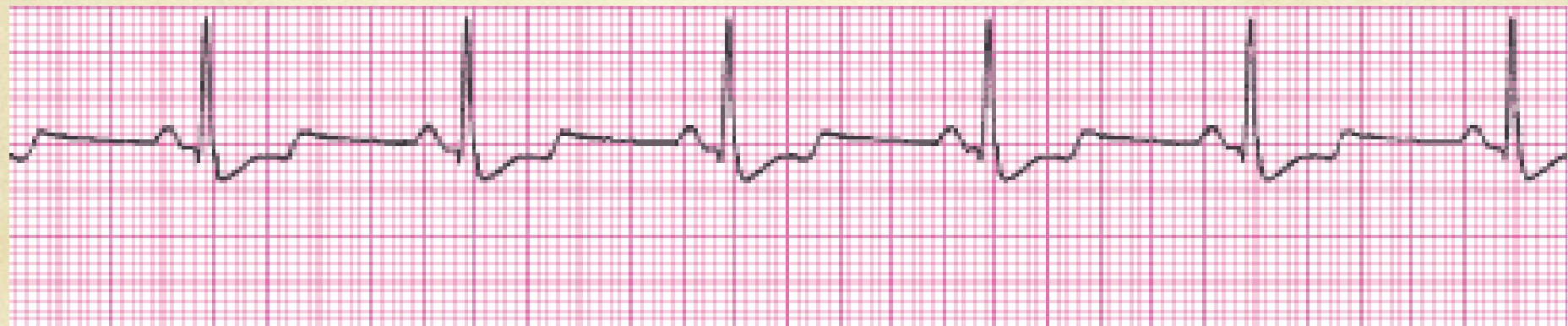




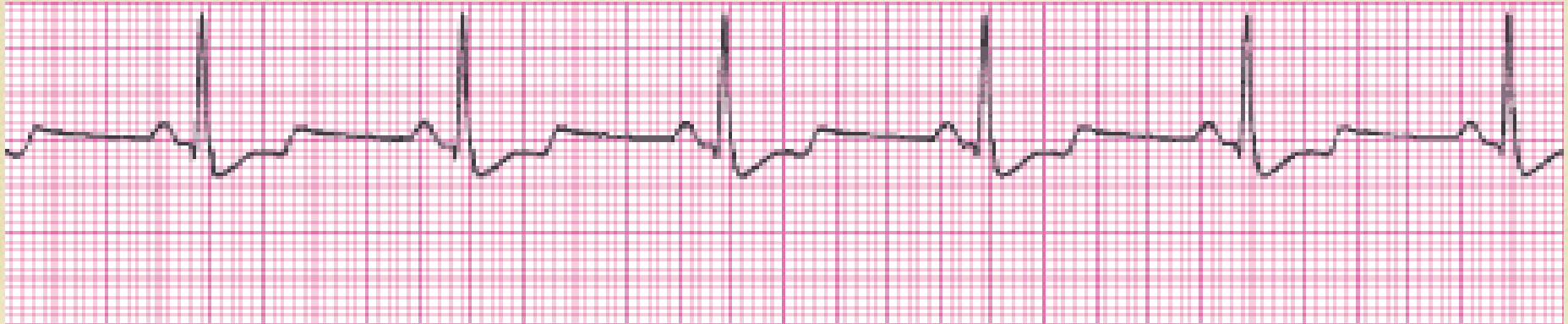
# Sinus Tachycardia

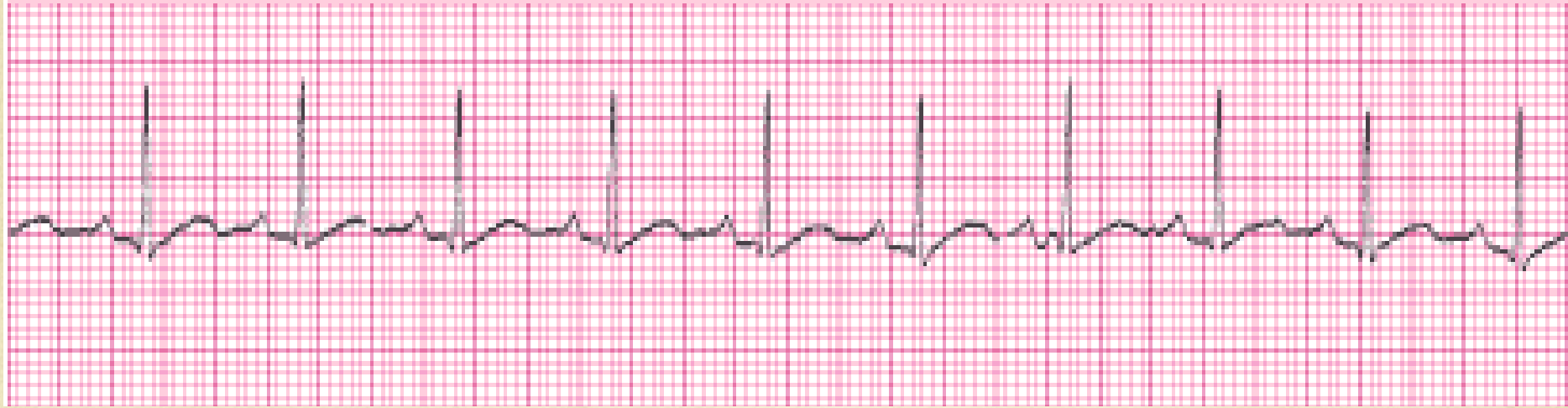



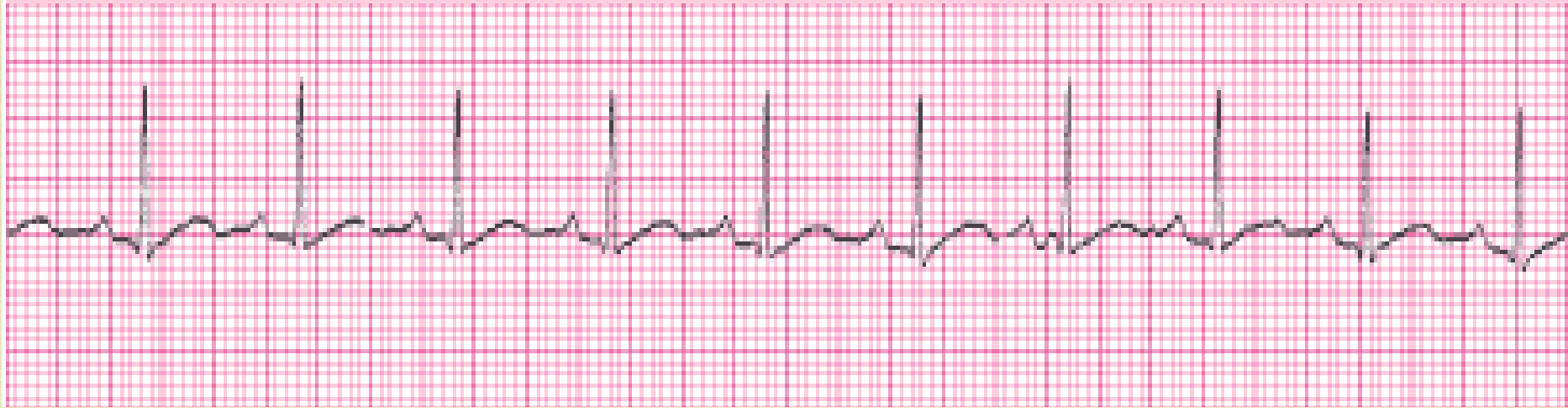# Normal Sinus Rhythm

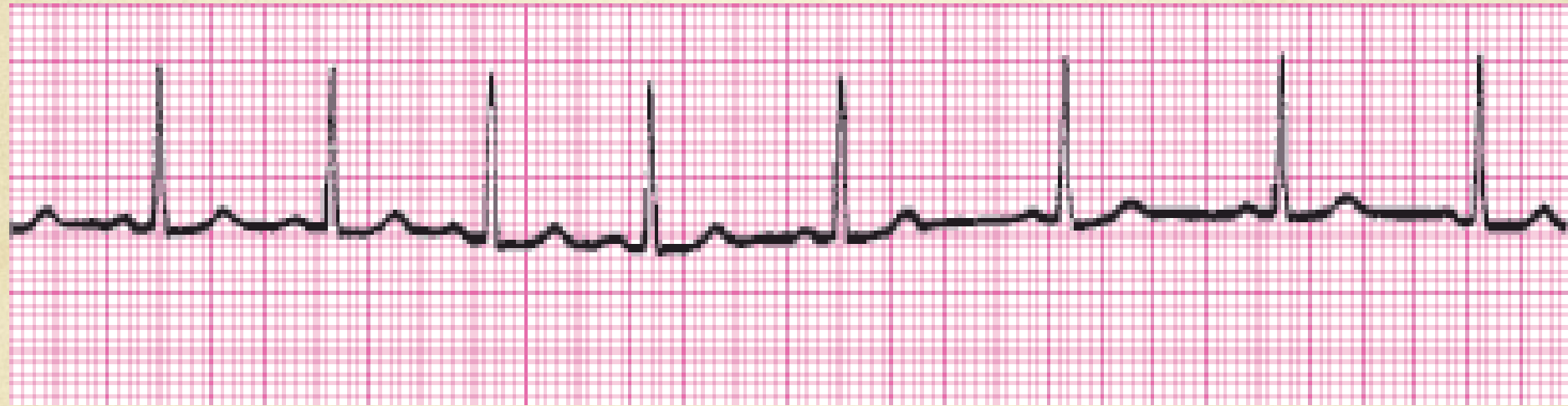





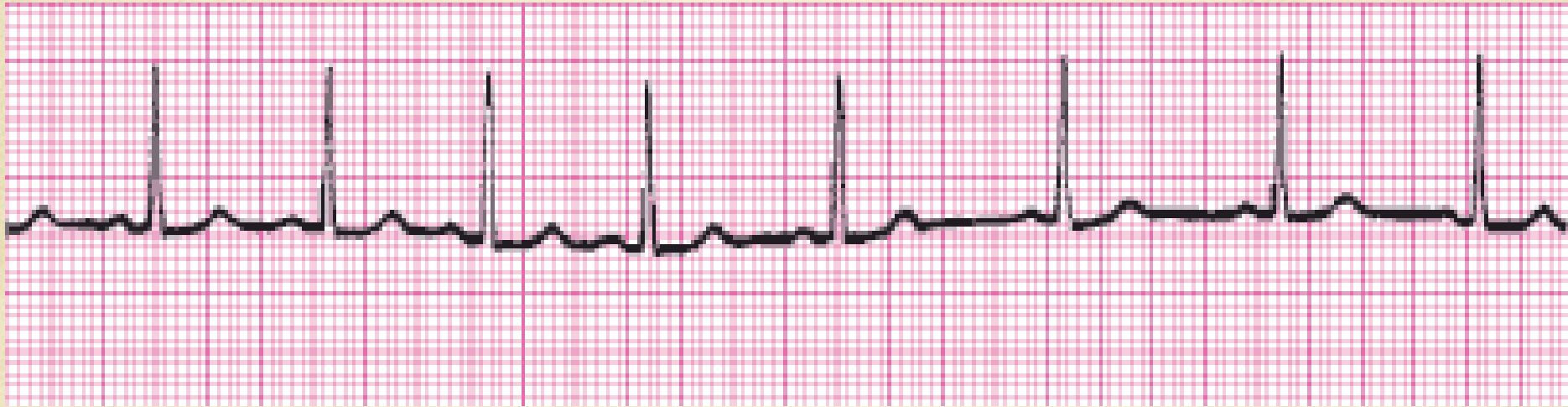# Borderline Sinus Tachycardia

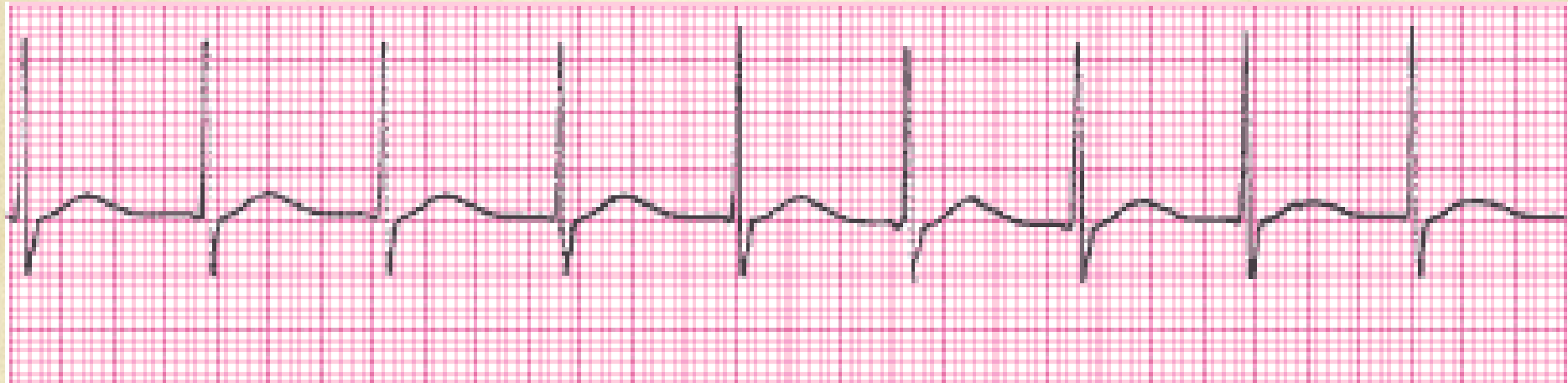




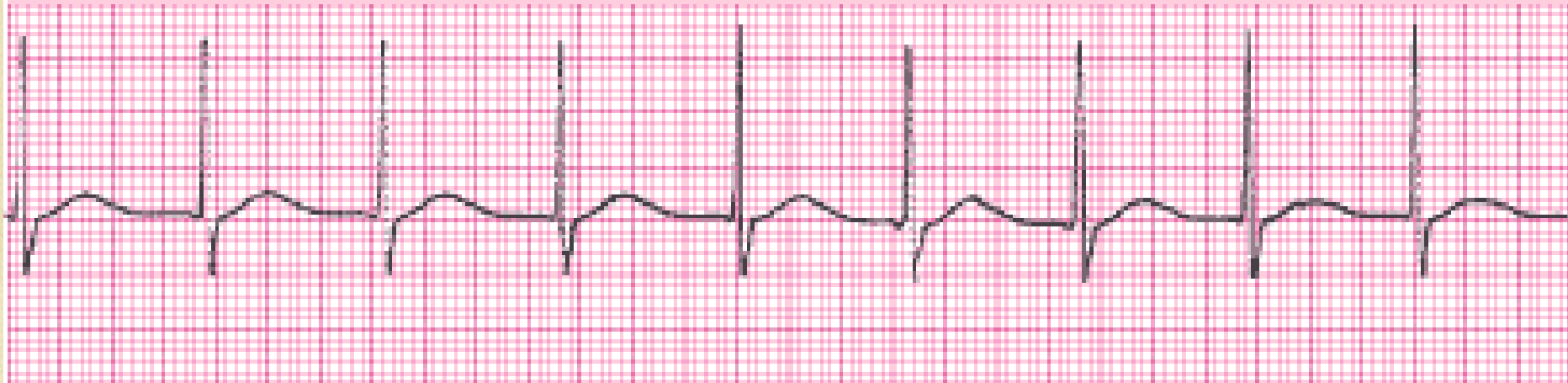


# Sinus Arrhythmia

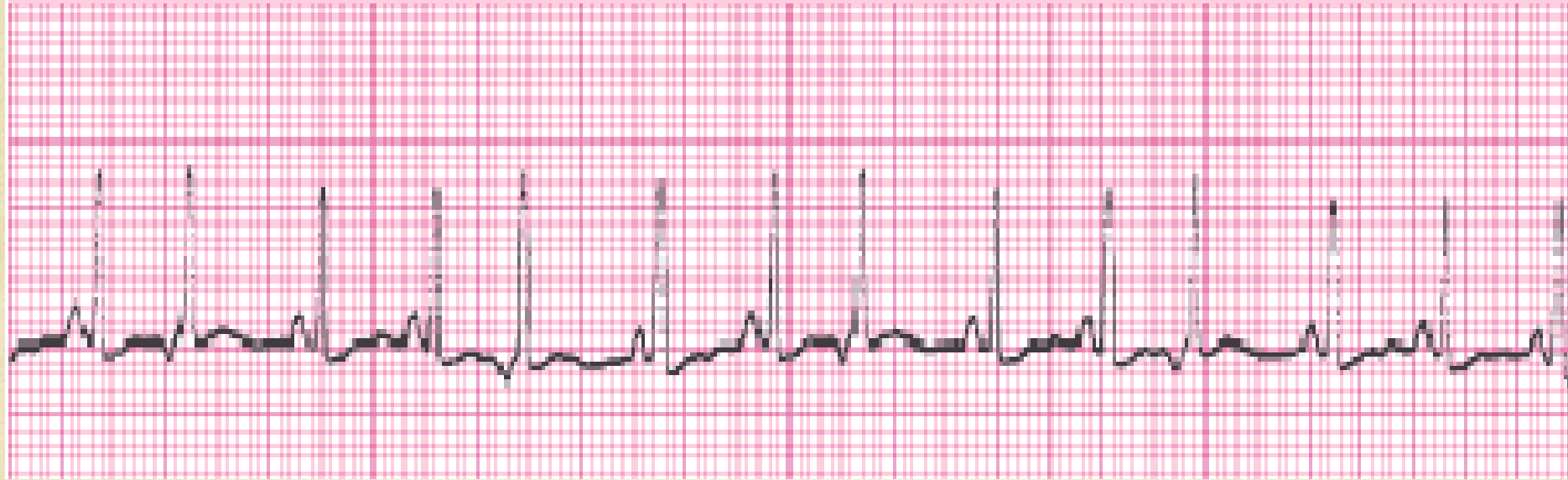




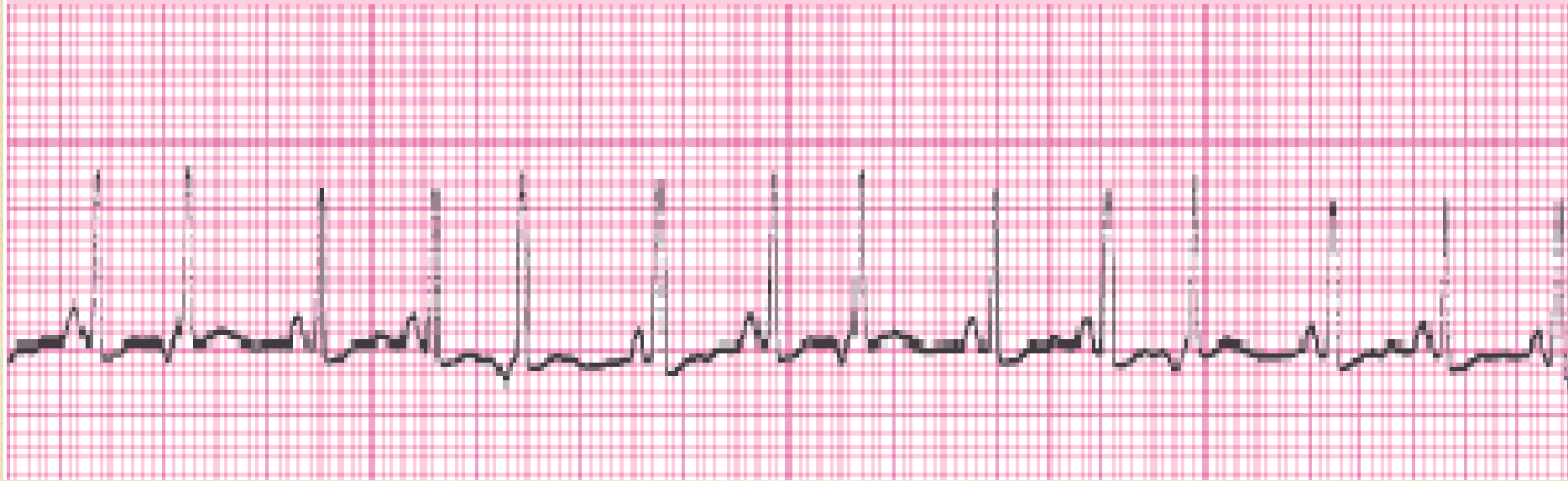
# Accelerated Junctional Rhythm

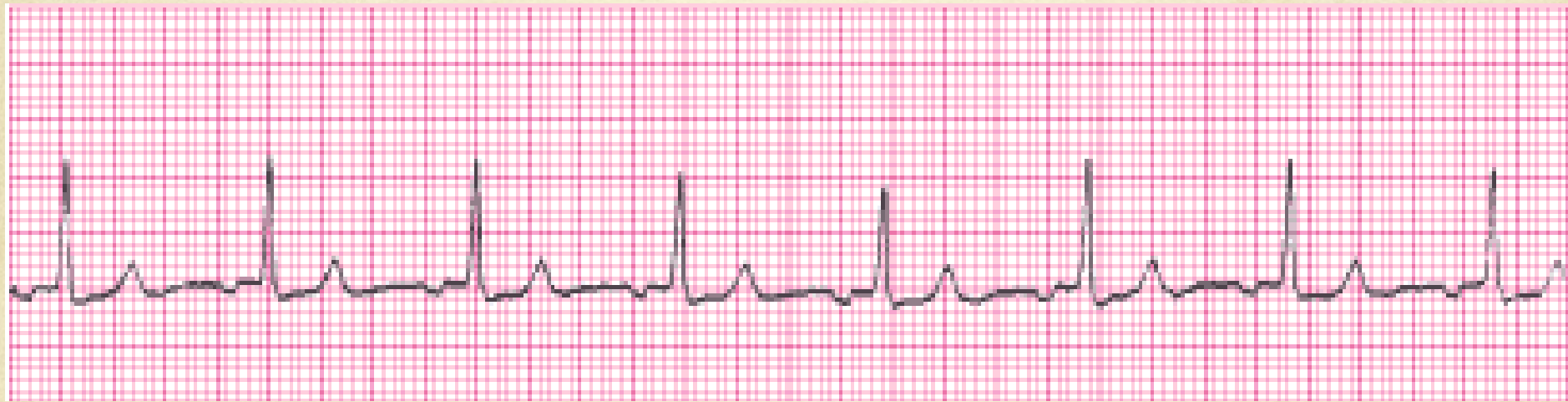





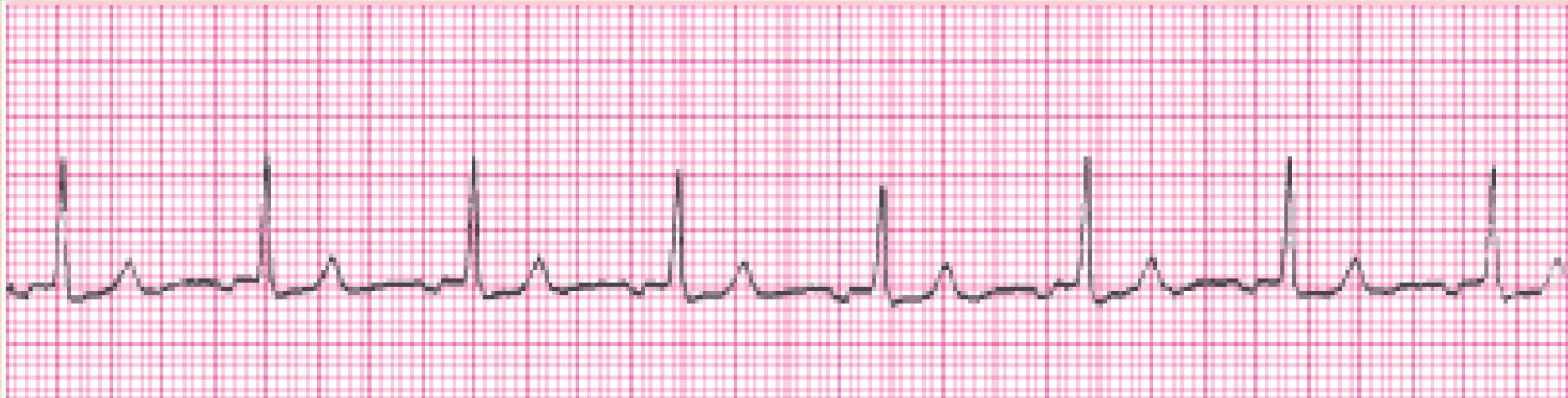# Sinus Tachycardia with Premature Junctional Complexes

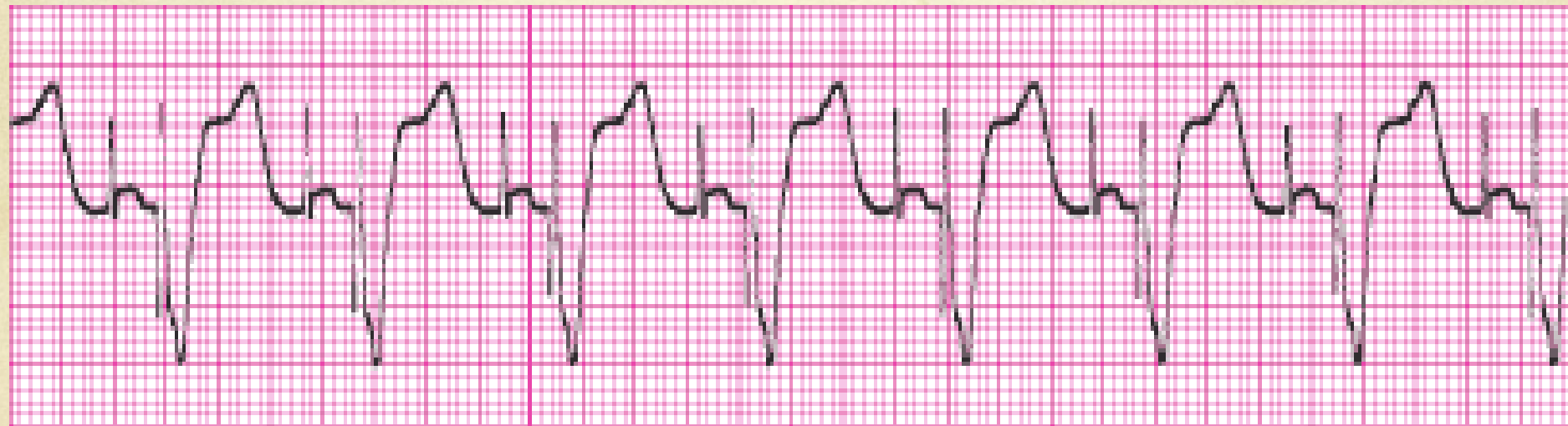




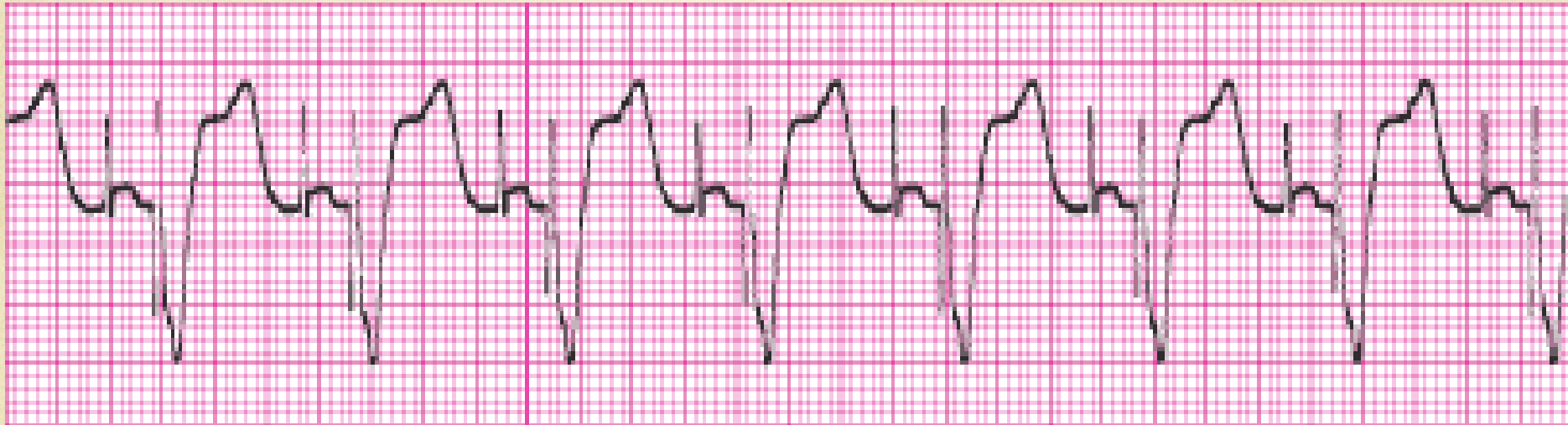


# Accelerated Junctional Rhythm

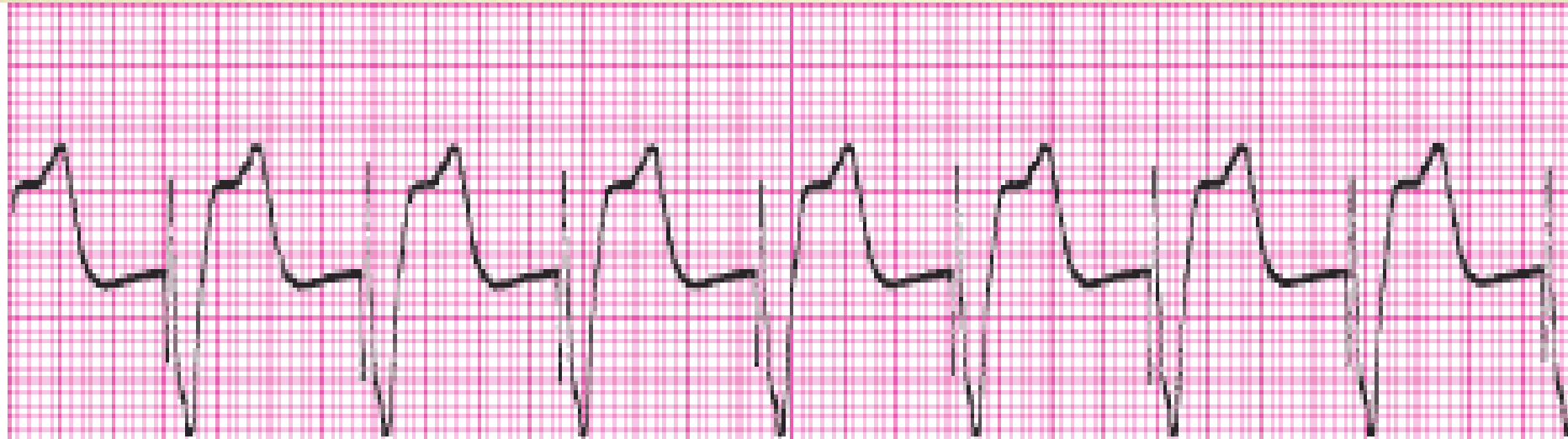



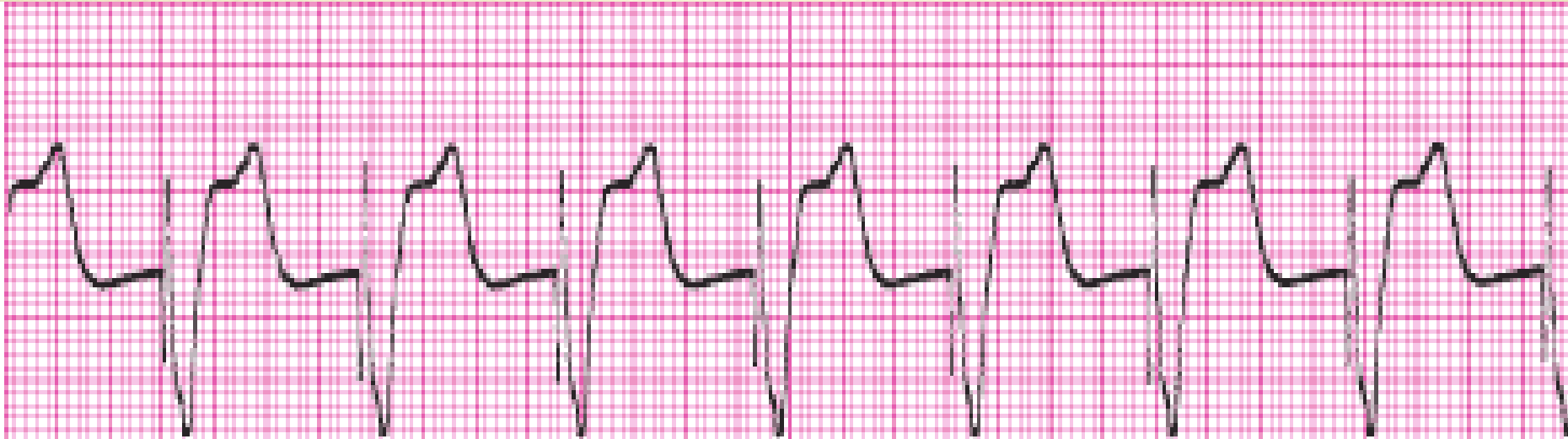# 100% Dual Chamber Pacemaker

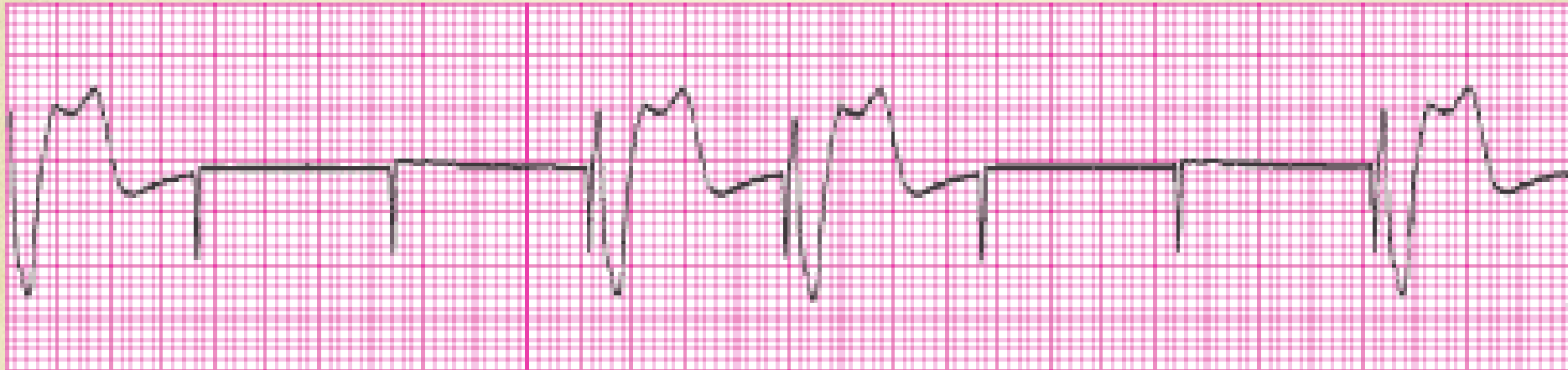





# 100% Ventricular Paced

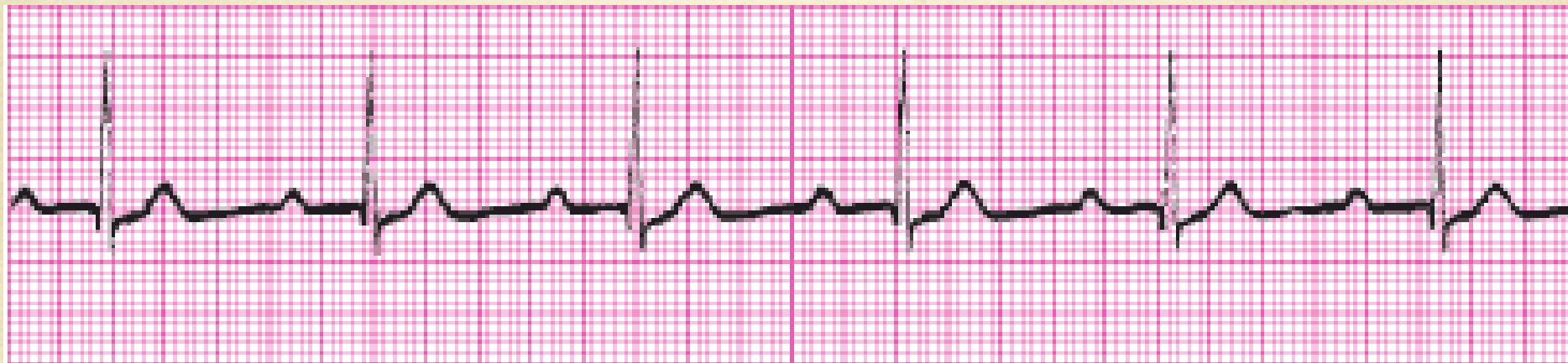




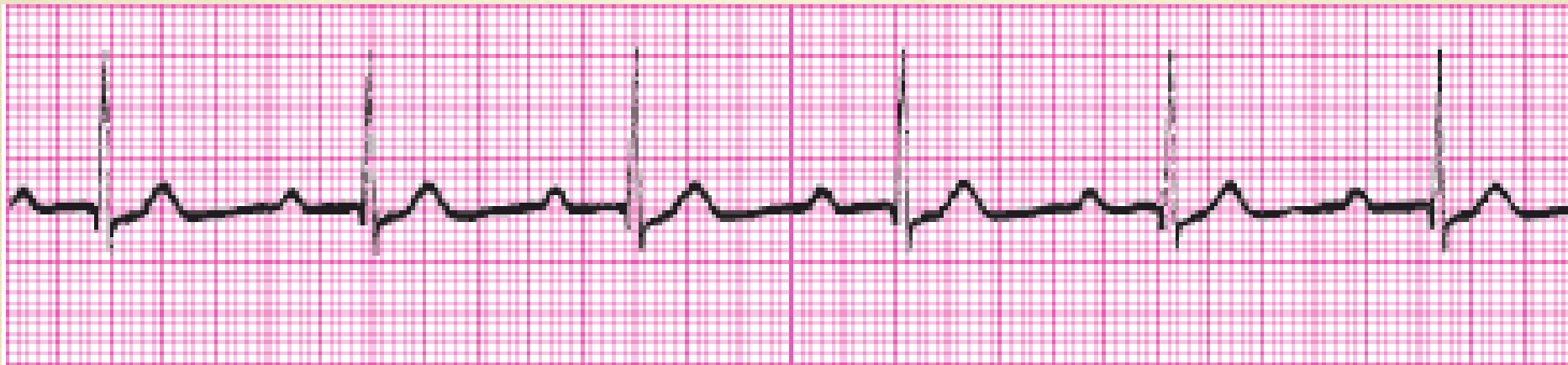
# 100% Ventricular Pacemaker without capture, failure to capture

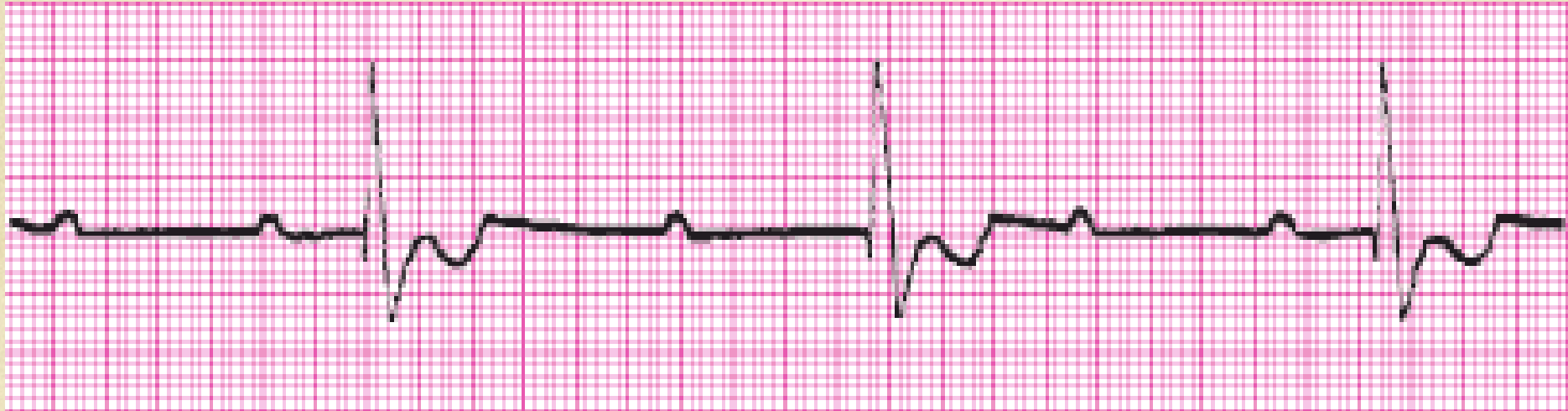



# Sinus with a first degree AV block

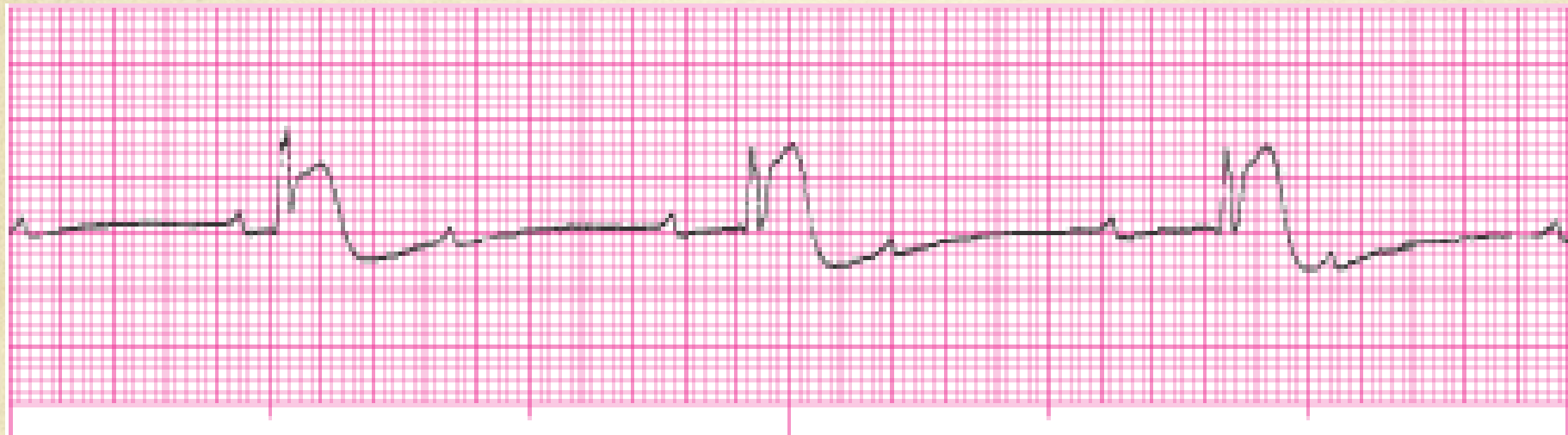





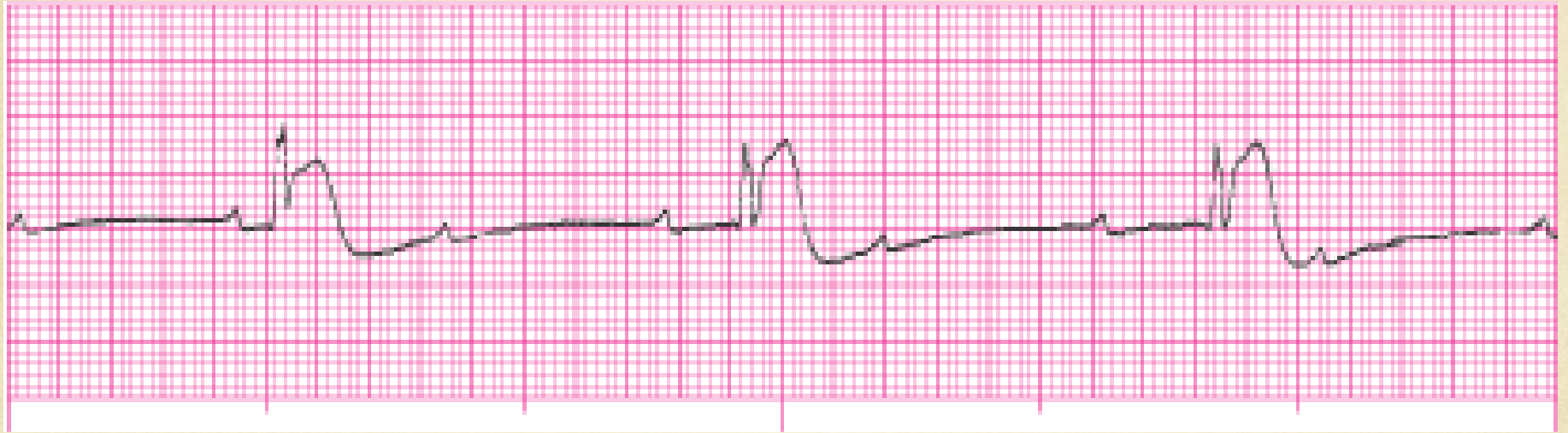# Third degree complete heart block

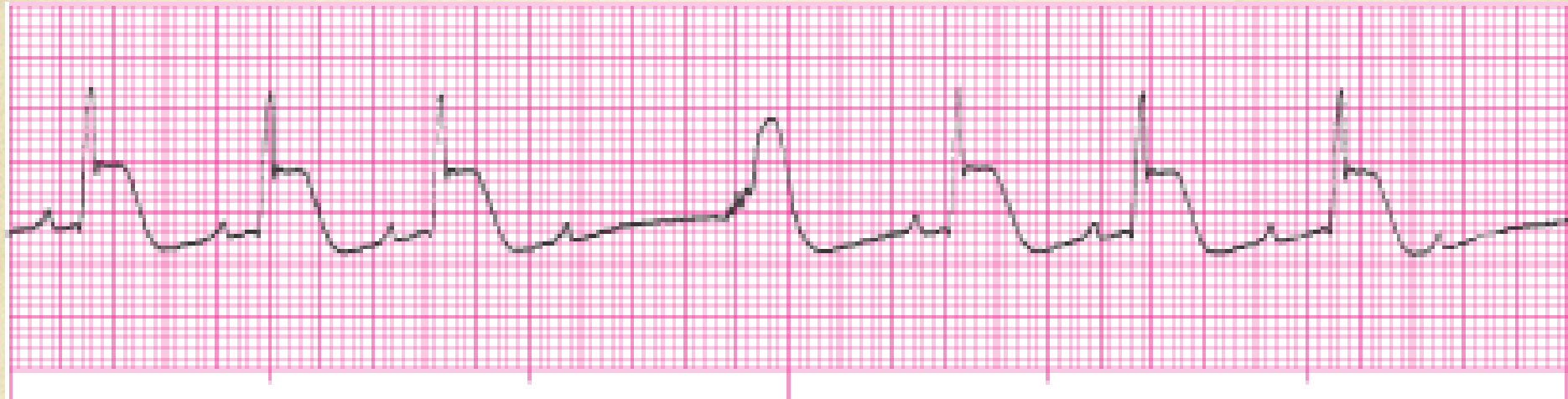




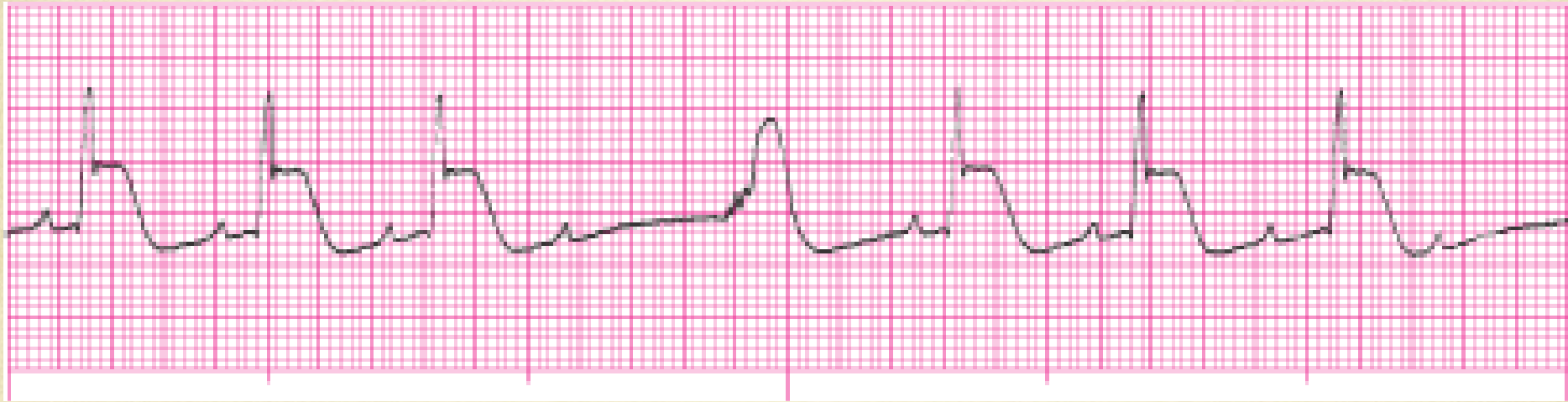
# Third degree complete heart block with ST elevation

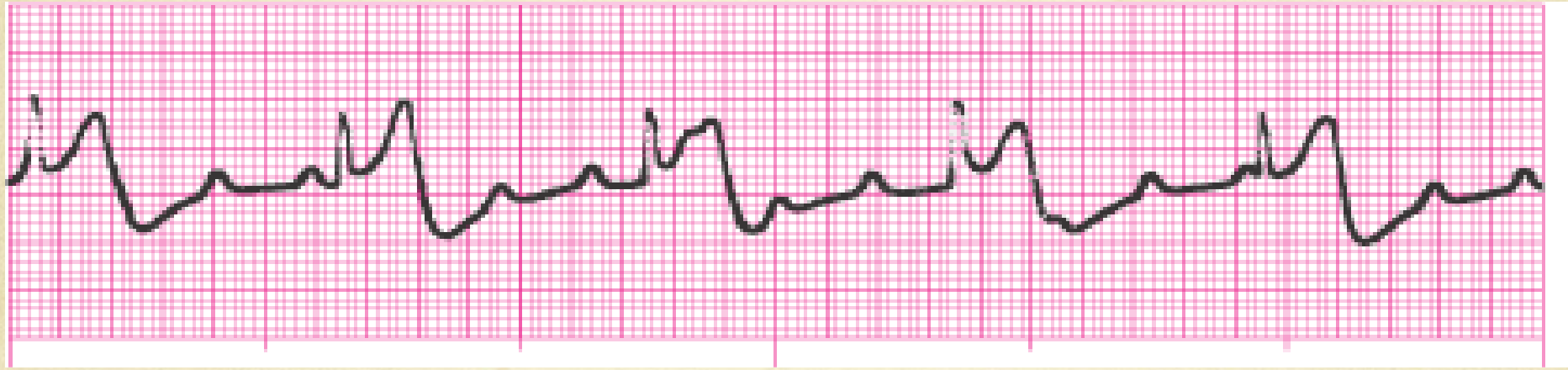


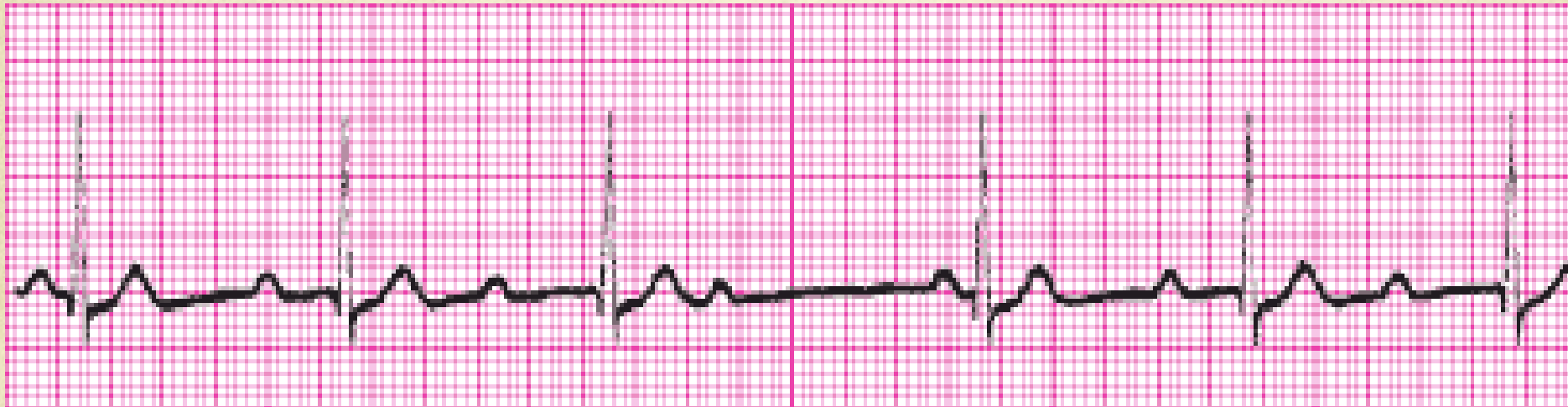
# Second degree type I (Wenkebach)

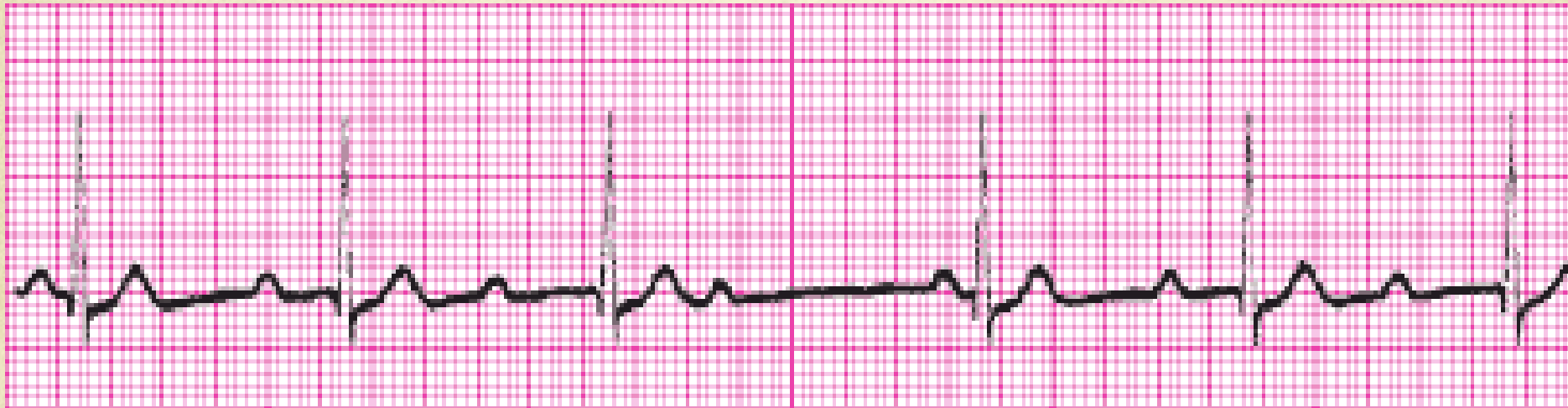




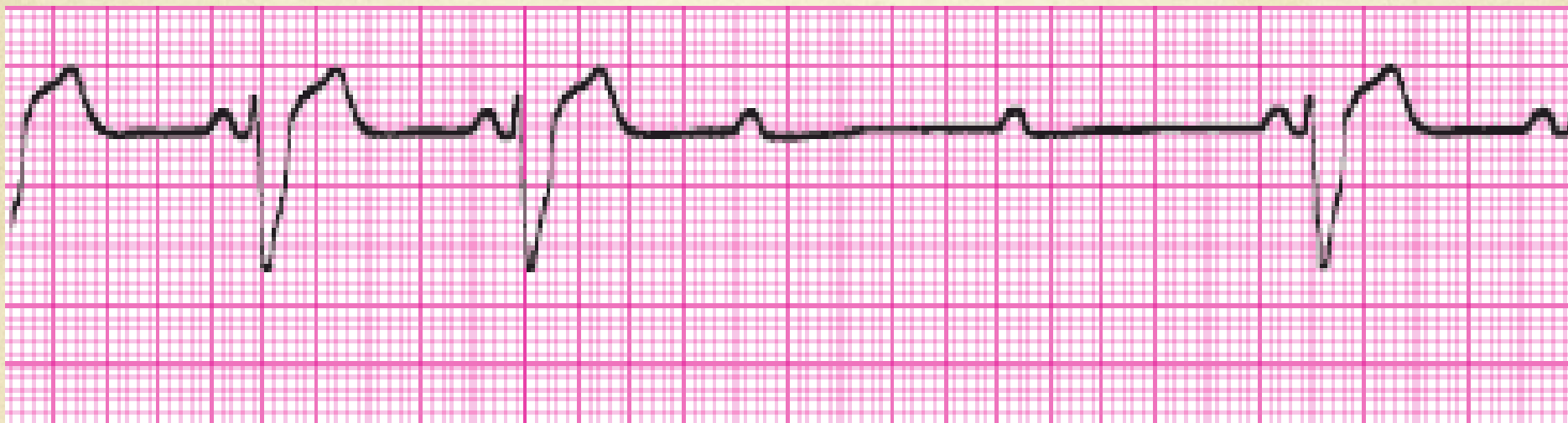


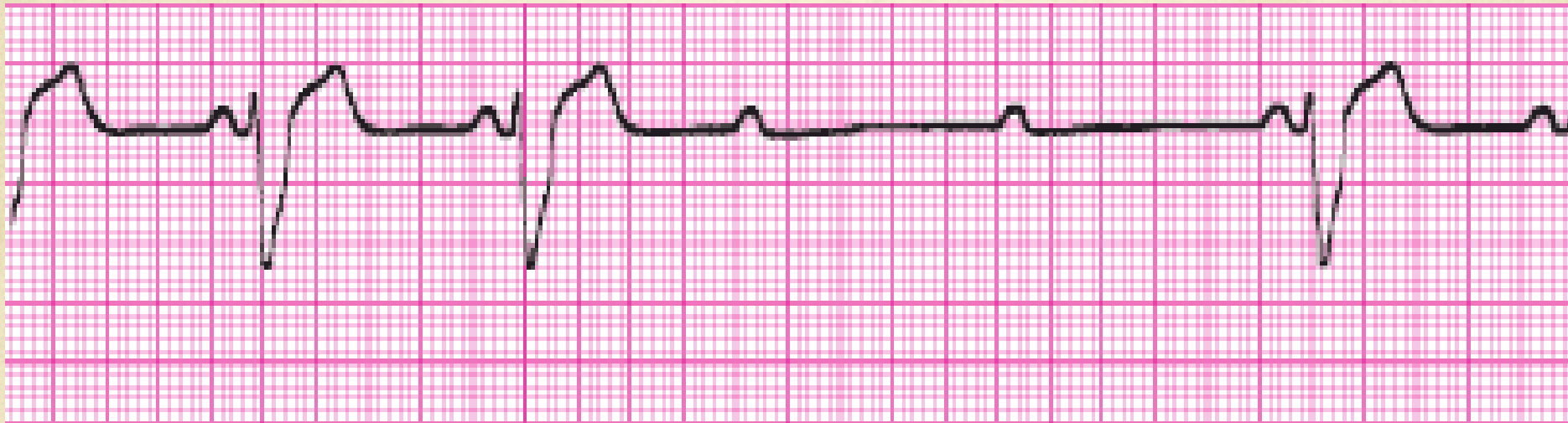# Second degree type I (Wenkebach)

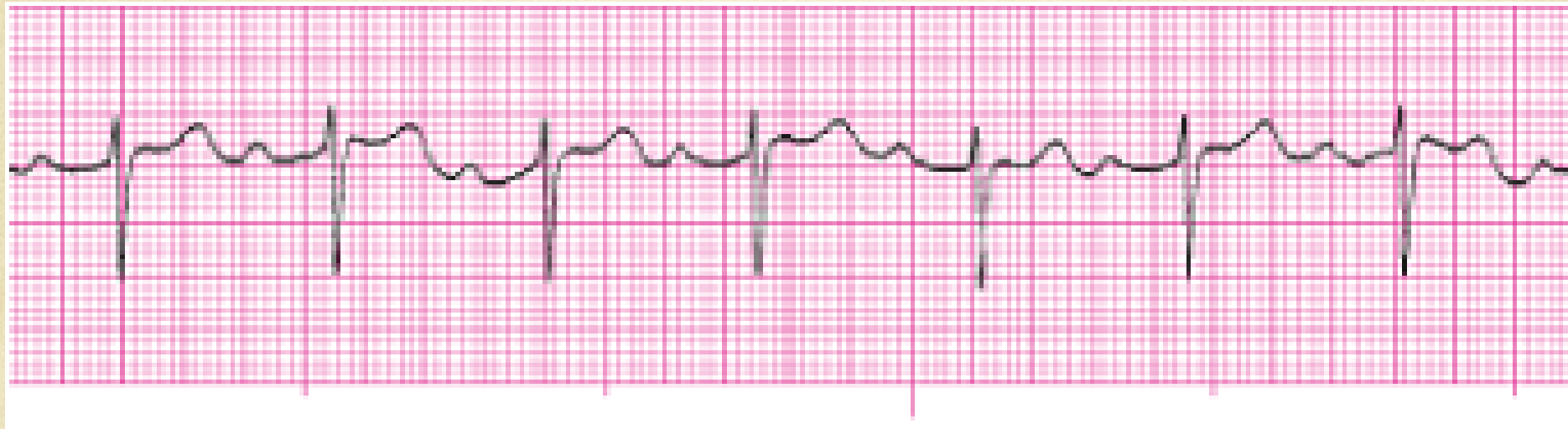





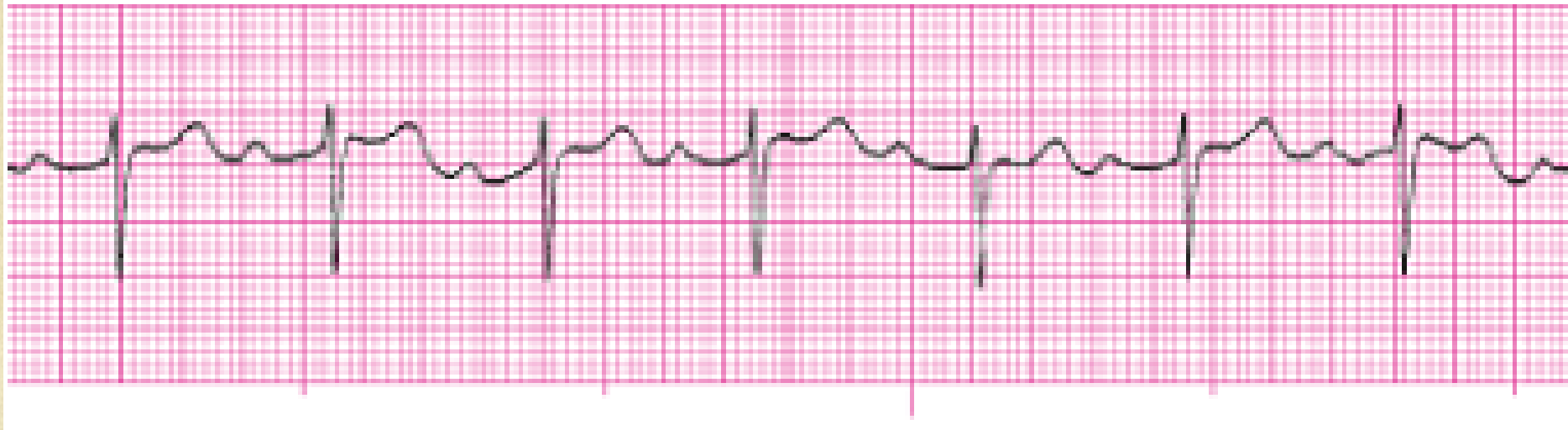# Second degree type II (Mobitz)

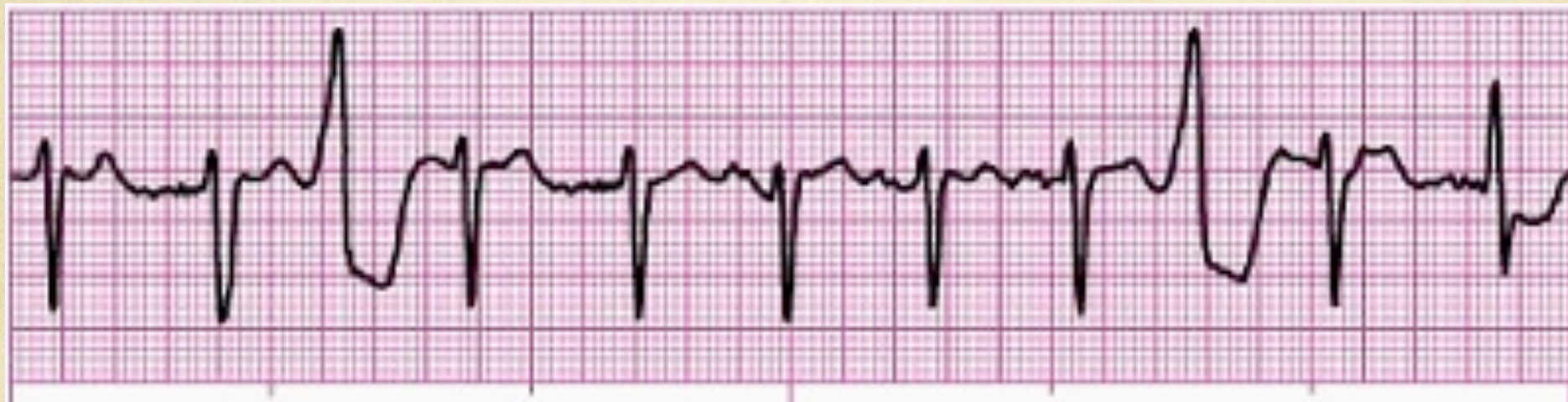





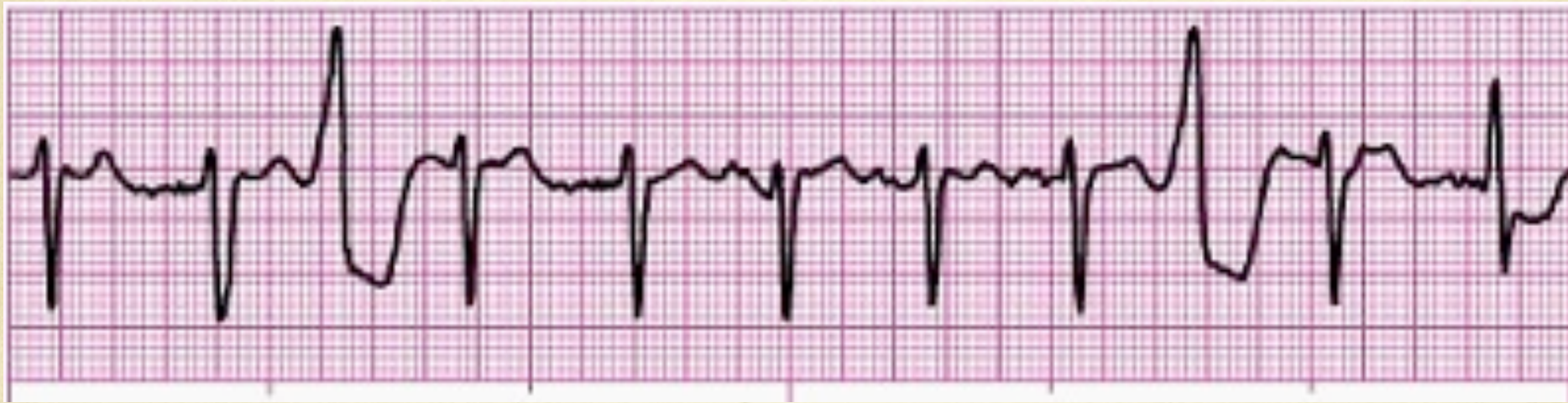# Sinus with a first degree AV block



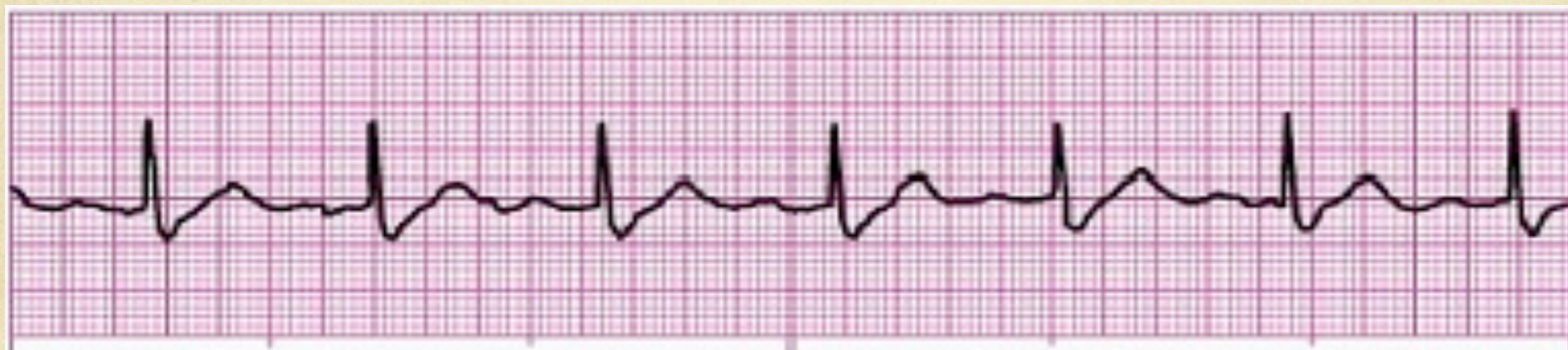



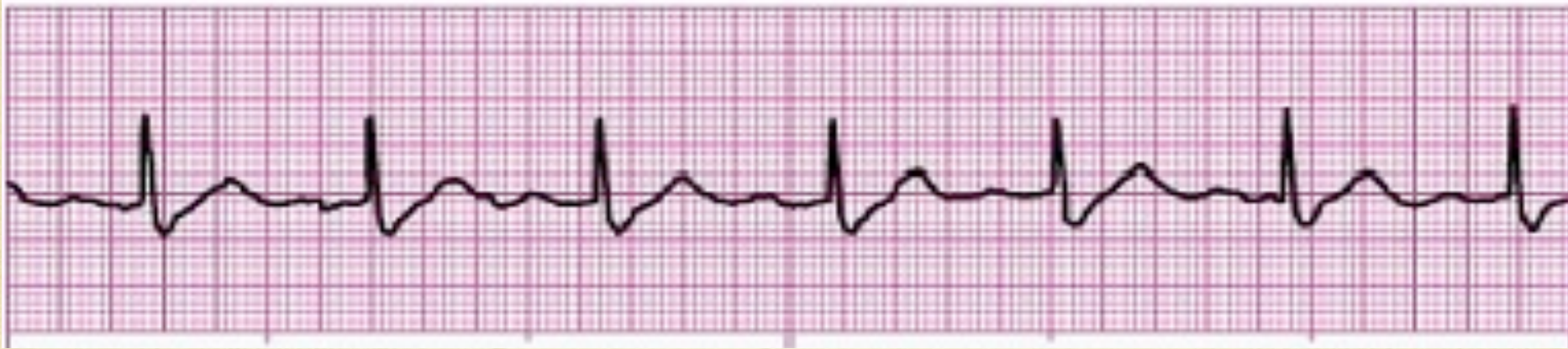Sinus @ 98 bpm with two PVC's



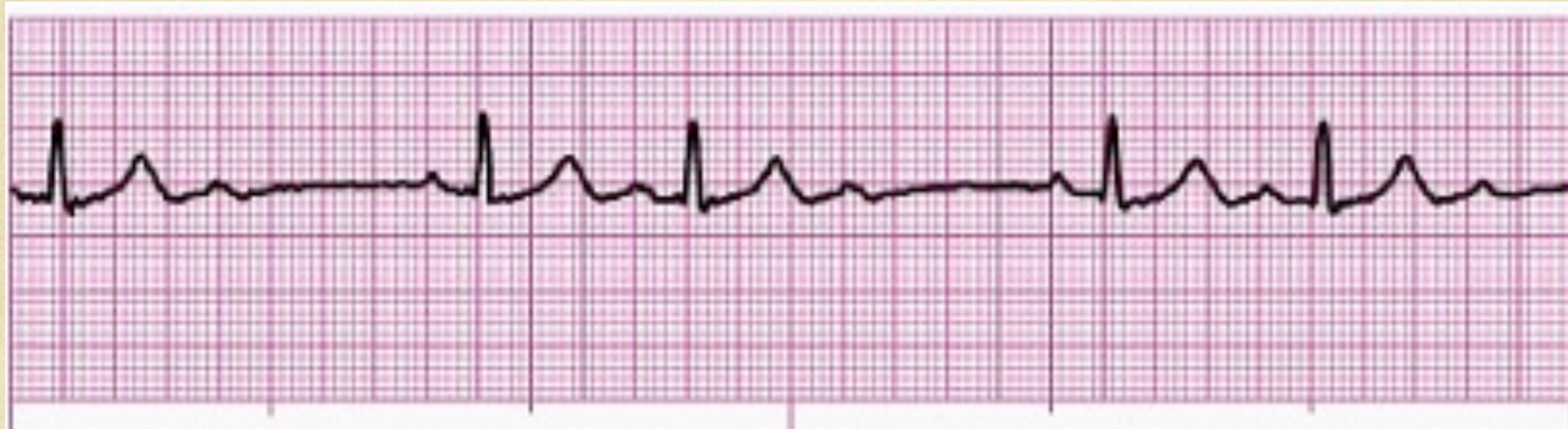



# Sinus with a first degree AV block

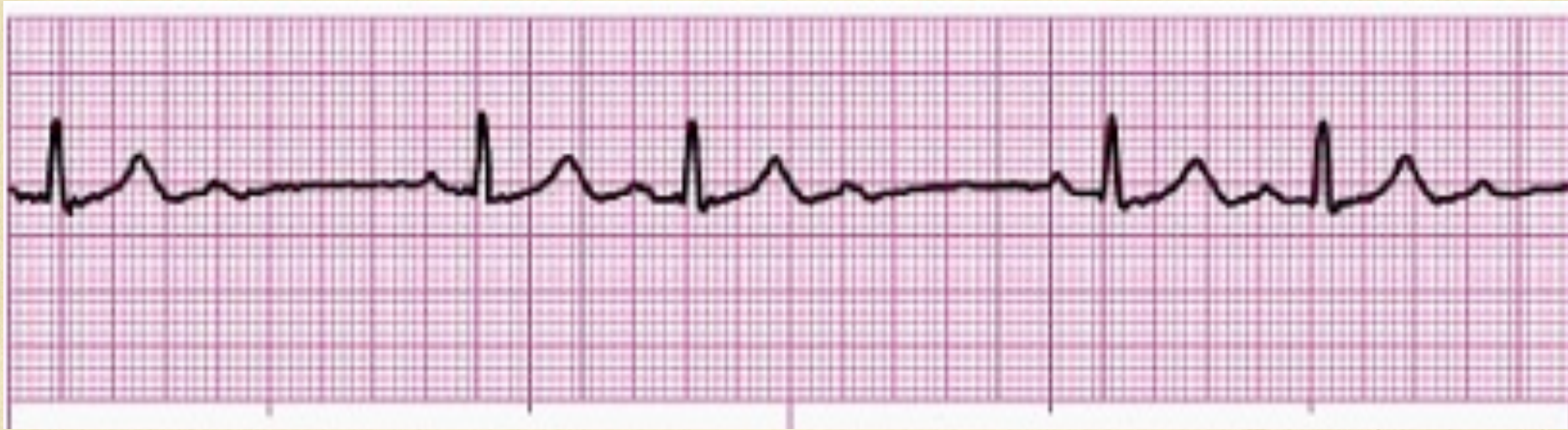


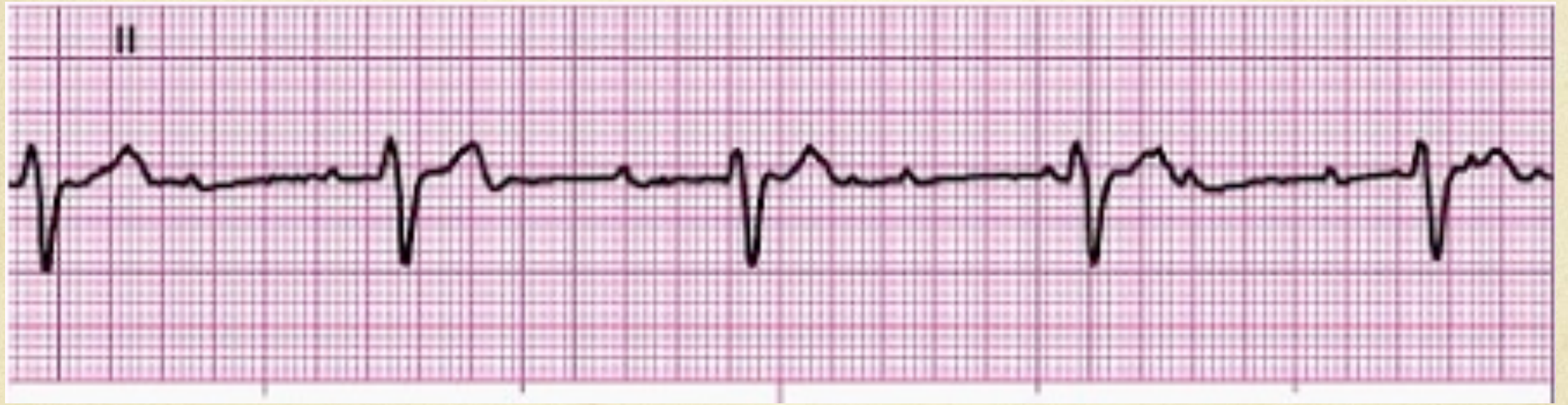




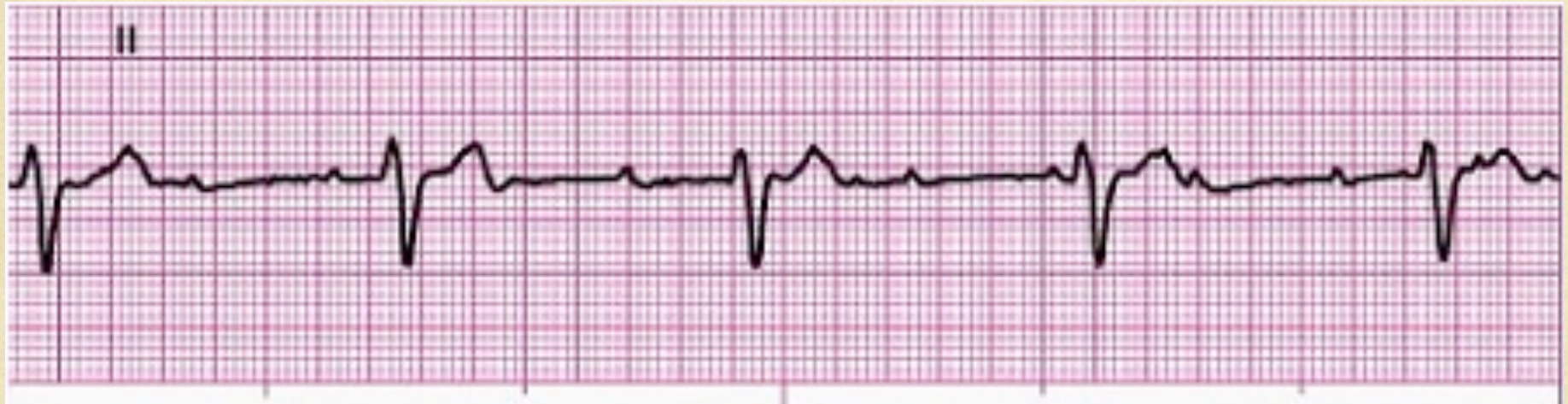# Second degree type I (Wenkebach)



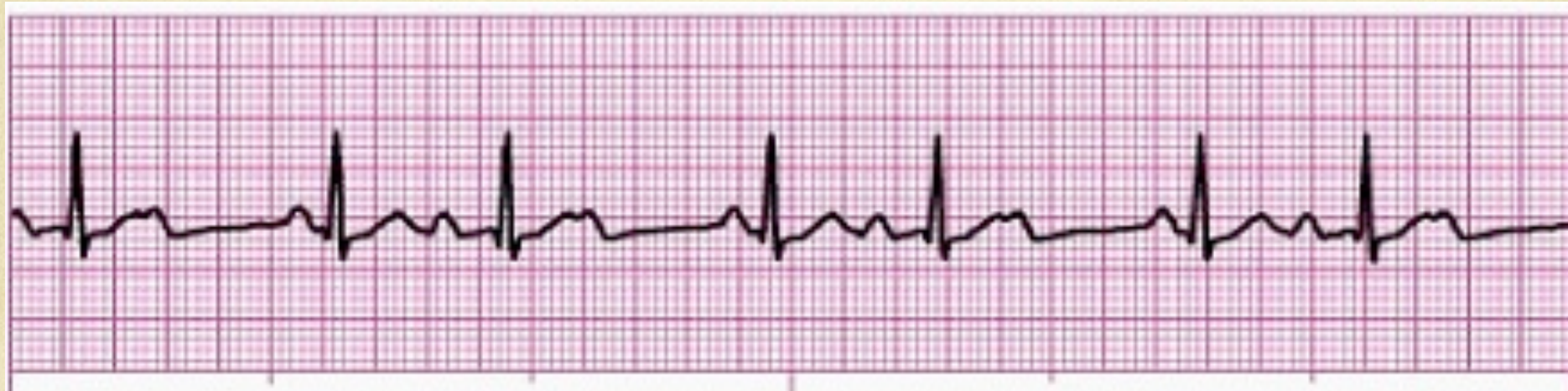



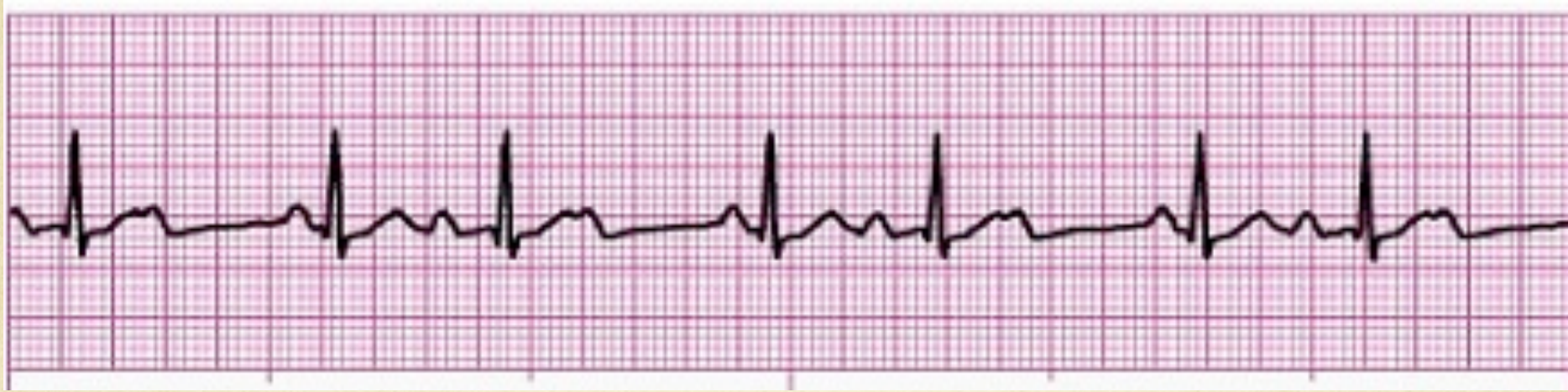# Third degree complete heart block



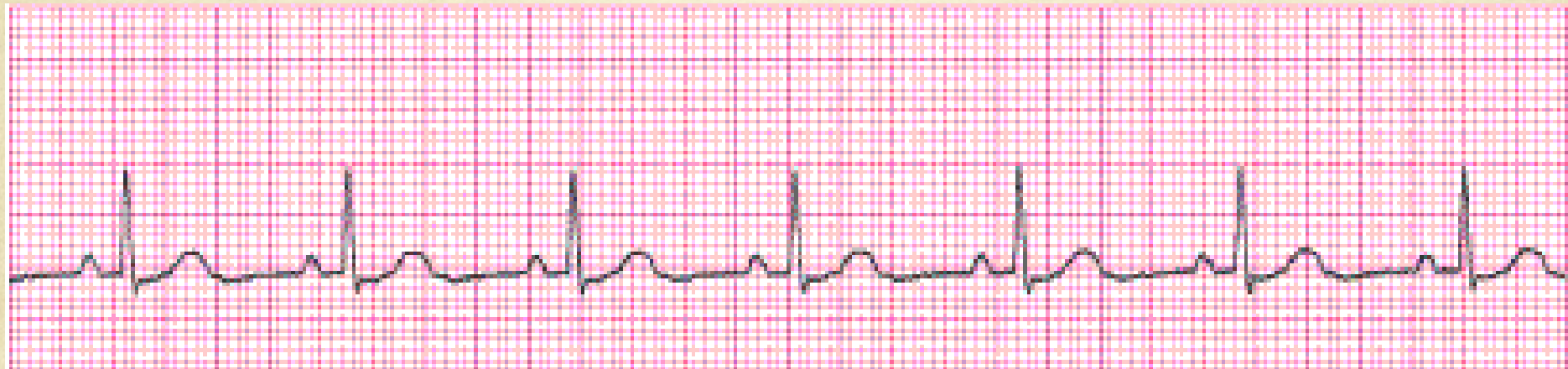



# Second degree type I (Wenkebach)

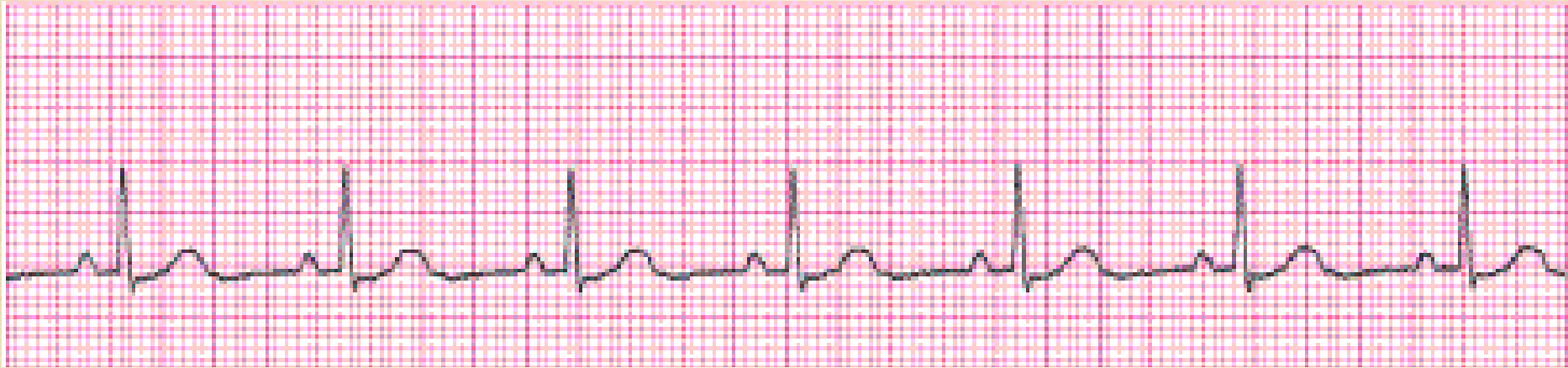


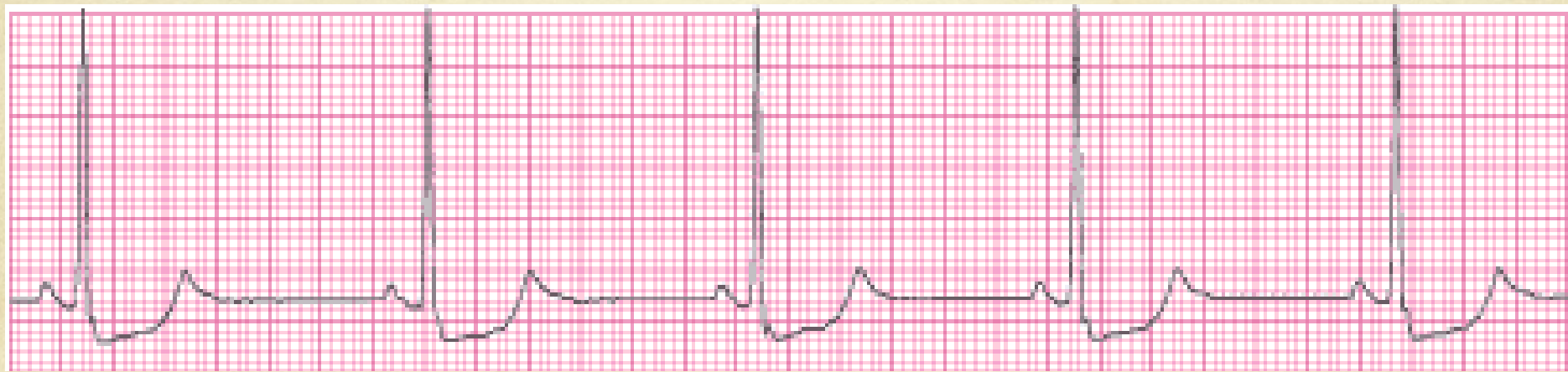


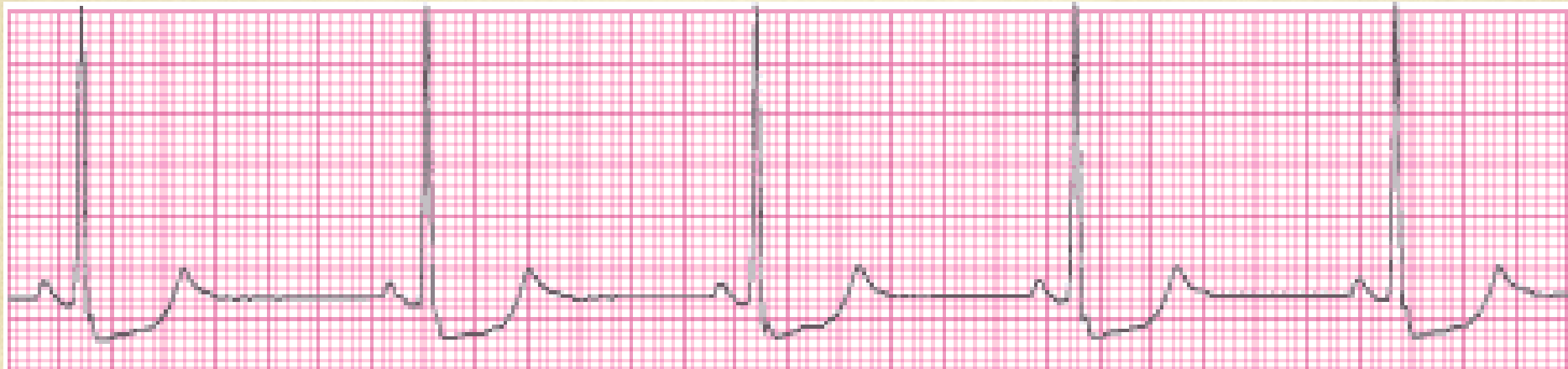


# Normal Sinus rhythm

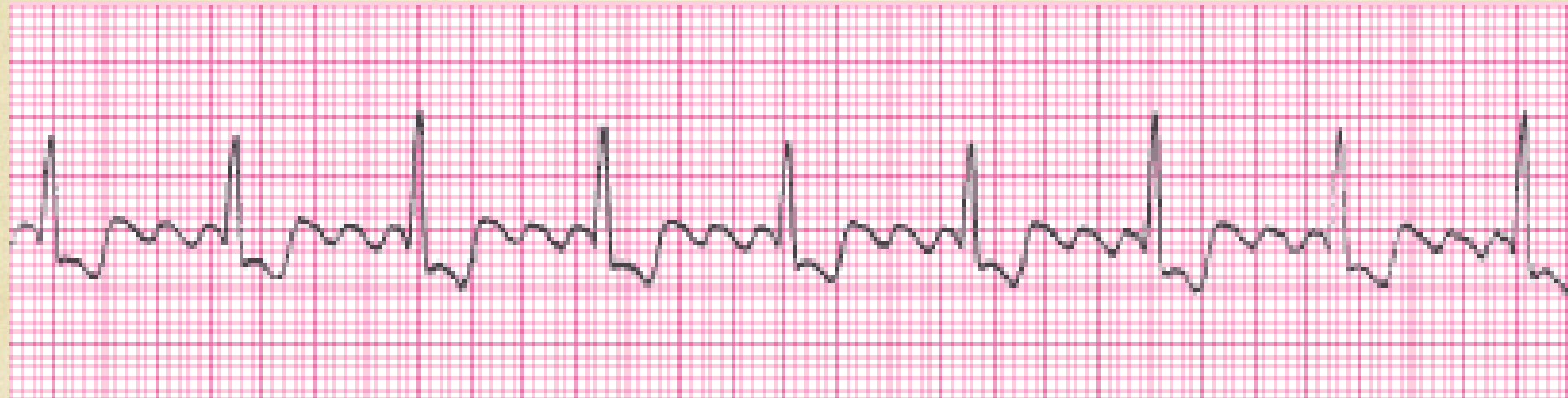



# Sinus Bradycardia







# Atrial Flutter

