



TAPPE'S EQUINE DENTISTRY

#587 Jan 14, 2025

979-251-2440
Tappesequinedental@yahoo.com



IAED CERTIFIED, LICENSED BY THE TEXAS BOARD OF VETERINARY MEDICINE

CLIENT Bailey Knepper MOB 1-330-243-5233
EMAIL bailey.knepper@gmail.com TEL
ADDRESS 8113 ST HWY 75 S, HUNTSVILLE TX 77340


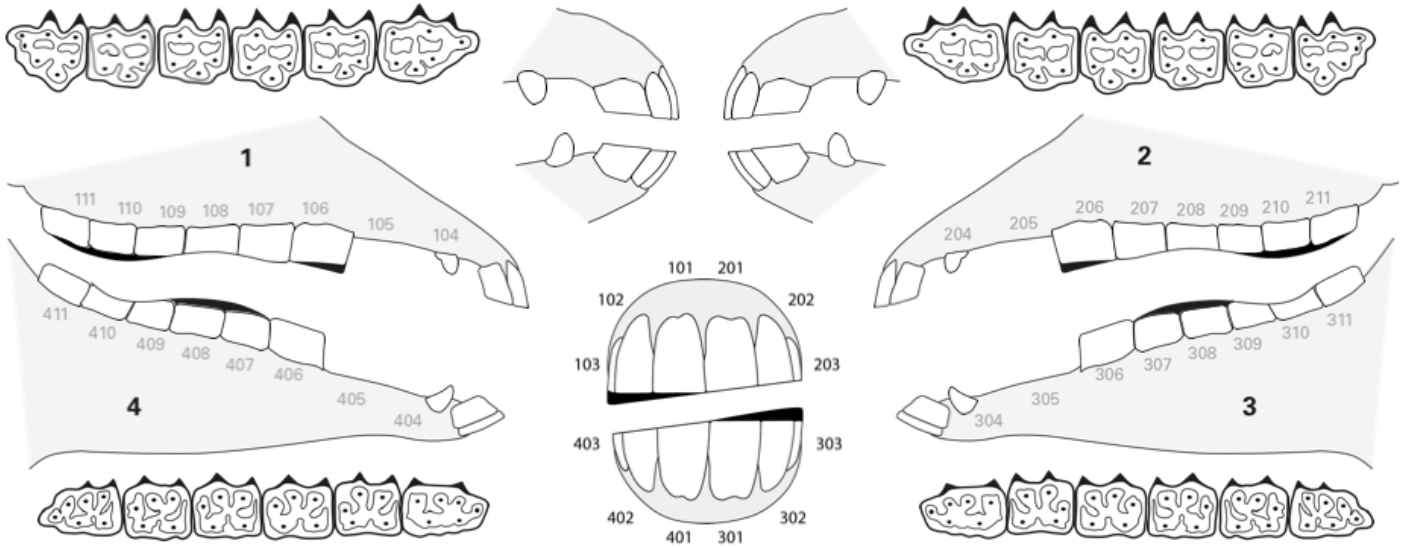
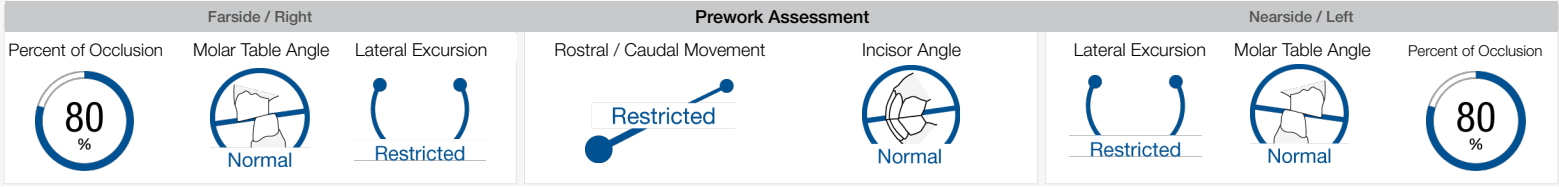
VET
PRACTICE
TIME SEDATION AMOUNT
Detomidine .6 ml

HORSE Dubs SEX Gelding
BREED American Quarter Horse (AQHA) AGE 14 YEAR 2011
HORSE NOTES COLOUR Gray HEIGHT

SEDATION NOTES CONDITION SCORE N/A

Clinical Notes

Last Treatment
N/A



- Incisors
 - Burred
 - Realignment
- Canines
 - Buff
 - Remove Tartar
- Wolf Teeth
 - None
- Premolars & Molars
 - Sharp Points
 - Ramps
 - ETR/ATR
 - Wave
 - Protuberant
- Other
 - Dental 1

NOTES

ATTACHMENTS

Appointment Due