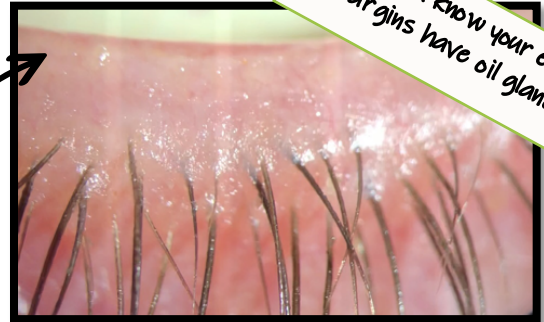

CONDITIONS THAT AFFECT THE EYELIDS

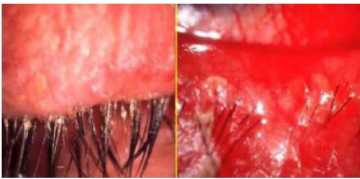
Did you know your eyelid margins have oil glands?

- Your **eyelashes** trap *allergens, dust, & debris* (this protects your eyes)
- *Oils, sweat, irritants, allergens, & bacteria* can build up on the **lid margin**
- This causes *eye irritation, redness, itching, burning, crusty lashes*
- Oil glands, called "**Meibomian Glands**", *open* at the base of the lashes
- "**Blinking**" helps the **oils** to be *secreted* from the oil glands
- This *produces* the outer **oily layer** of your tear film (if deficient, this causes dry eye)



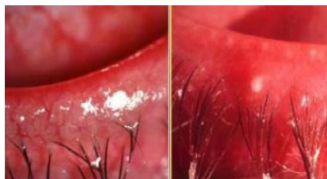
BLEPHARITIS is inflammation of the eyelid margins and blockage of the meibomian glands (oil glands in the lids). This can cause eye irritation, recurring eye infections/styes, loss of lashes, red/inflamed lids/eyes, and progression of dry eye disease.

Staphylococcal Blepharitis



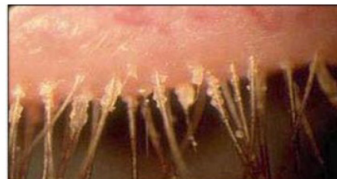Staph bacteria is present on the skin. If excess builds up on lids, the toxins cause redness/burning (worse in a.m.), crusting, infections.

Seborrheic Blepharitis



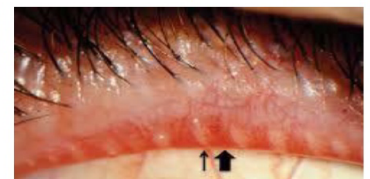Seborrhea is a skin condition causing dandruff on the scalp, eyebrows, eyelashes.

Anterior Blepharitis



Anterior blepharitis includes Staphylococcal and Seborrheic types. Both cause crusting of the lashes and red/inflamed lid margins.

Posterior Blepharitis (MGD)



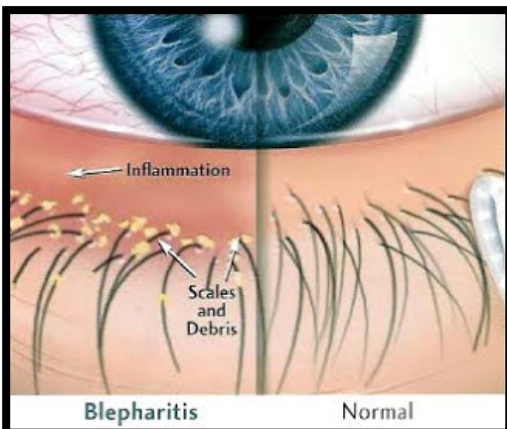
Posterior blepharitis is called Meibomian Gland Dysfunction (MGD) and affects the oil glands in the lid margin causing clogged glands similar to acne of the skin.

Types of BLEPHARITIS

- Seborrheic
- Anterior
- Posterior
- Bacterial
- Allergic
- Demodex (mites)

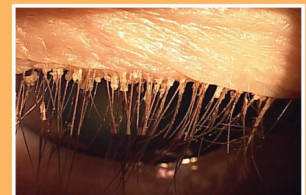
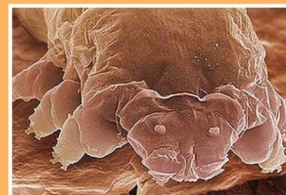Causes of BLEPHARITIS

- Seborrhea
- Dermatitis
- Rosacea
- Demodex
- Bacteria
- Allergies
- Cosmetics
- fake eyelashes



CREEPY, CRAWLY MITES

LIVE ON YOUR EYELIDS!



INFESTATION SIGNS AND SYMPTOMS

Red, irritated, itchy eyelids and the formation of cylindrical collarettes on the base of the lashes.

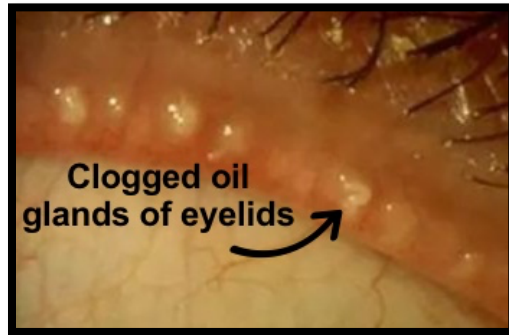
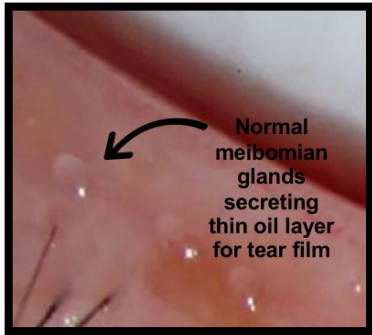
TAKE HOME RECOMMENDATION

Oust™ Demodex® Eyelid Cleansers

Did you know your eyelash follicles can become infected?

BLEPHARITIS = infected or inflamed lid margin or eyelash follicles

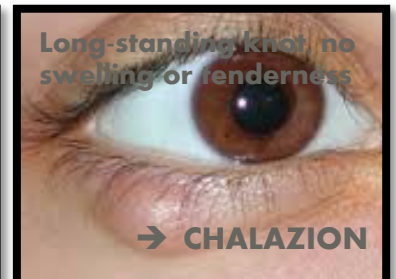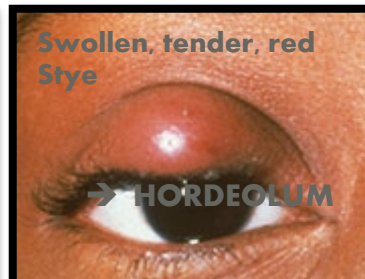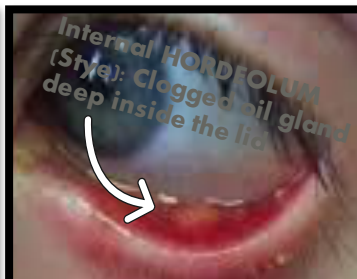
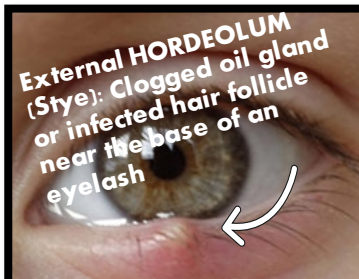MEIBOMIAN GLAND DYSFUNCTION (MGD) = Posterior Blepharitis



Causes: Oily skin, acne, aging, menopause, allergies, bacteria, oily based cosmetics, Rosacea

Symptoms: small bumps on lid margins, stringy mucus or crust in tear film, red eyes, burning sensation, can lead to styes and Evaporative Dry Eye

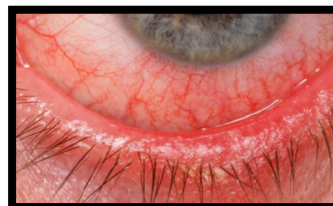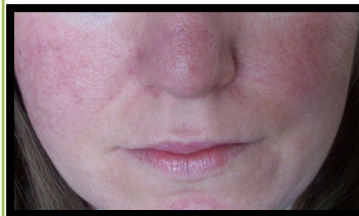STY– Infected, swollen, tender gland of eyelid (like a boil on the lid margin or a bump inside the lid)



CELLULITIS- Infection can spread to the skin if not treated (or if you try to *pop* it). This is a dangerous infection requiring treatment.

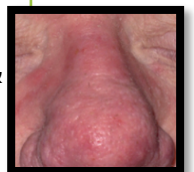OCULAR ROSACEA

- ❖ **Causes:** Rosacea, heredity
- ❖ **Triggers:** heat exposure, hormone changes, stress, caffeine, spicy foods, cosmetics, aging
- ❖ **Symptoms:** Blood vessels in the skin *dilate*, oil glands become *inflamed & clogged*, pores become *enlarged & bumpy*, eyelid margins & the white of the eye becomes red, irritated, & hot



TYPES OF ROSACEA

- ❖ **Acne Rosacea** - affects the face, dilated vessels, red cheeks, may mimic acne
- ❖ **Rhynophyma** - enlarged & bumpy nose
- ❖ **Ocular Rosacea** – dilated vessels at lid margins, blepharitis, MGD, red eyes, allergies, dry eyes, infections



Ocular rosacea is inflammation that causes redness, burning and itching of the eyes. It often develops in people who have rosacea, a chronic skin condition that affects the face.

You have been diagnosed with: