

See discussions, stats, and author profiles for this publication at: <https://www.researchgate.net/publication/233649845>

# Porcelain pornography

Article in *Faculty Dental Journal* · July 2011

DOI: 10.1308/204268511X13064036474003

---

CITATIONS

28

---

READS

9,777

1 author:



[Martin Kelleher](#)

King's College Hospital NHS Foundation Trust

106 PUBLICATIONS 1,953 CITATIONS

[SEE PROFILE](#)

## Porcelain pornography

*by Martin Kelleher*

I write to raise some issues involved in the blatant destruction of teeth, apparently being undertaken to cure patients affected by ‘porcelain deficiency disease’ (PDD). This is a newish disease, identified by some dentists who also seem to think that teeth suffer from ‘hyperenamelosis’ (an excess of enamel). It probably goes without saying that both of these conditions are imaginary yet it does appear to me, at times, that they are perceived to exist by some ‘cosmetic’ dentists. In this article I offer comments and case studies of patients who, arguably, have had unnecessarily aggressive treatment that was probably of more benefit to the profits of the dentists concerned than to the patients’ long-term dental health.

*Author:* Martin Kelleher, Consultant  
in Restorative Dentistry, King’s College  
Dental Institute, London SE5 9RS.

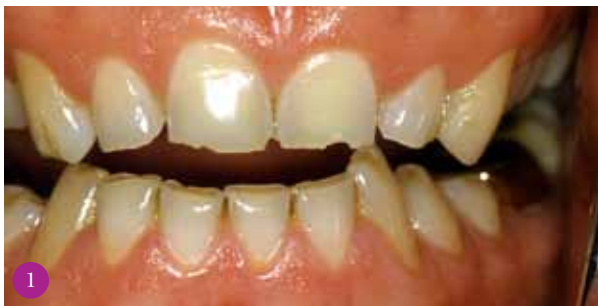*E:* martin.kelleher@virgin.net

*Keywords:* porcelain, veneer, cosmetic  
dentistry, bleaching, bonding

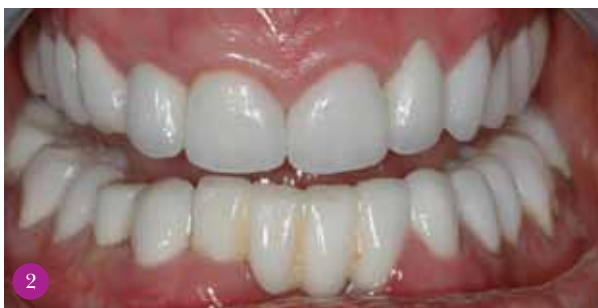Sadly, ‘remuner-ectomies’ do occur in healthcare. This is a term used to describe any operation done to remove something from a patient when the indications seem to be largely based on the remuneration that it produces for the operator, rather than on significant long-term benefits to the patient. The question at the heart of this article is this: when dealing with minor cosmetic dental problems, can the removal of sound enamel and dentine and their replacement with brittle porcelain bonded in various forms be the best treatment in terms of a patient’s long-term dental health?

In the recent past, various publications have included pictures of so much destruction and surgical violence being done to teeth that I think we now need a new term to describe ultra-white, over-contoured restorations being done unnecessarily on mainly intact teeth ([Figure 1](#)). I would propose the term ‘porcelain pornography’ to describe this phenomenon.

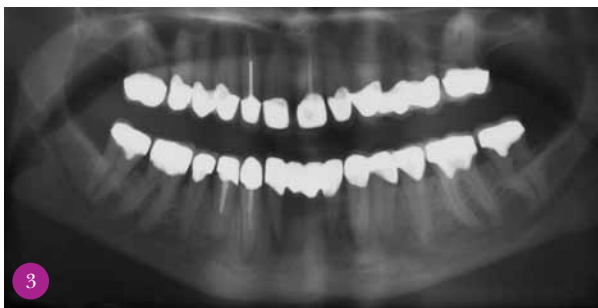



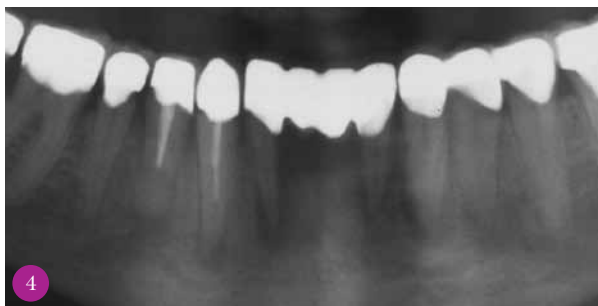**Fig 1** Teeth that are 'mainly intact', ie with mild wear that could be addressed through less aggressive treatment such as bleaching and bonding to achieve the 'nice smile' the patient desires.



**Fig 2** Patient as presented (apparently cured of PDD)



**Fig 3** Six dead teeth as a result of the treatment for hyperenamelosis by application of porcelain bonded to metal crowns and bridges.



**Fig 4** Section of the orthopantomogram showing areas of obvious periapical rarefaction.

One article, recently published in a journal purporting to describe what is best in modern 'cosmetic dentistry', showed some mildly eroded and worn teeth at the lower right canine, lateral incisor, central incisor and lower left central incisor. There was little evidence of significant wear of the lower left lateral incisor, canine or first or second premolars. There was also no sign of active periodontal disease around any of these lower teeth but there was some minor gingival recession that was probably of no real clinical significance. The upper anterior teeth appeared to have been previously crowned or veneered, and showed some associated minor gingival inflammation.

However, the treatment plan involved what can only be described as an unprovoked attack by an air rotor. The sound enamel and dentine of **all** the lower incisors and canines as well as **all** of the adjacent premolar and molar teeth were destroyed so that some ultra-white ('lavatorial' white?) crowns could be placed. The smooth margins as a result of this controlled destruction of intact teeth were nicely photographed but the graphic clinical pictures shown in this article made the residual cores of the prepared teeth look like they could have been auditioning for a part in an ultra-violence film.

The 'restorations' that were placed were jaw-dropping examples of over-contoured, ultra-white ceramic crowns. The nice photographs showed clear evidence of eviction of the interdental papillae and some obvious iatrogenic gingival inflammation around the upper and lower incisors. This could scarcely be considered a biologically beneficial or even neutral outcome, especially considering the amount of destruction that was clearly shown to have been performed on the sound structure of healthy teeth so they could end up looking remarkably similar to (cheap) dentures.

I believe that many experienced, ethical dentists are appalled by this sort of cavalier destruction of sound tooth tissue now frequently seen in this sort of elective cosmetic case. Innocent adjacent or opposing teeth are sometimes also attacked because they are part of a group, eg when one upper incisor might need treatment and it is deemed that it should be veneered or crowned (rather than bleached) a second incisor, or indeed three more incisors, will be given the same treatment (for little obvious health benefit) in order that the subsequently placed group of porcelain restorations will match. Sometimes canines or premolars are also included so that they too can match. This is clinically dubious: can you imagine having a knee replacement and the orthopaedic surgeon kindly volunteering to replace your other knee, which has no problems at that time, just so that they match?

Sadly, images of this kind of over-treatment are becoming increasingly commonplace in advertisement-strewn, usually un-refereed, dental journals that reach a very wide audience of dentists. Professionally, it is very worrying that some dentists seem to think it is sensible to imitate this style of 'destructodontics'. Sadly, these dentists seem to regard a gentle patient request for an improvement in

the 'attractiveness of their smile' as being sufficient justification for any amount of destructodontics. Recently an unfortunate woman was sent to me with six dead teeth following such practice (Figures 2–4). Most sensible and ethical dentists would not take a slightly worn, triangular-shaped lower incisor and inflict significant damage to it in order to place over-contoured, fragile porcelain on top of it. A paper by Edelhoff and Sorenson in 2002<sup>1</sup> showed clearly that somewhere between 62–73% of the structure of a tooth is removed by preparation for an anterior, all-ceramic full-coverage restoration. A veneer preparation was shown to remove between 3–30% of the tooth's structure.

More importantly, I wonder if the patient above completely understood that the result of such cosmetic treatment would result in the destruction of the integrity of her load-bearing, sound teeth along with a significant risk to the health of her dental pulps. Somehow, I doubt it.

#### Consent

Was information about such important issues as tooth structure and pulpal health accidentally or conveniently withheld from the above patient, so that she would have this lucrative treatment? If so, was this fair or reasonable, or does this possible omission invalidate her consent? If a patient is fully informed of the risks and still insists on the treatment, should we provide it? More importantly, assuming that a patient only cares about the outcome (eg, a nicer smile), could that have been provided through other, less aggressive (and less lucrative) treatment, such as bleaching and bonding? Ultimately, if a less destructive treatment can bring about the outcome desired by the patient, shouldn't the sensible, ethical dentist recommend it? Patients sometimes request extensive or irresponsible treatment for perceived cosmetic problems but they are not usually well informed of the potential problems that might occur in the future as a consequence of their request. Most dentists do inform patients in advance but it appears that others may not dwell on such negative aspects for financial or other reasons – or perhaps not even offer alternative treatments that would also give the desired result but for less expense. There is often a range of treatments available to address cosmetic problems – the good dentist should tend towards those that preserve the long-term dental health of the patient and make sure the patient is informed of all the treatments available and their consequences.

#### Pulpal issues in 'cosmetic dental makeovers'

When an air rotor assault is launched on virtually intact teeth, the innocent dental pulps are given no chance to retreat. Extensive preparation of intact teeth for ceramic-based crowns is very different to preparing teeth that have been previously attacked by dental caries. Caries is a slow process and often gives the pulp a chance to retreat and lay down secondary or reparative dentine. No such warning is available for the intact teeth undergoing preparation: the high pitched whine of an air rotor signals the imminent stripping of their invaluable enamel

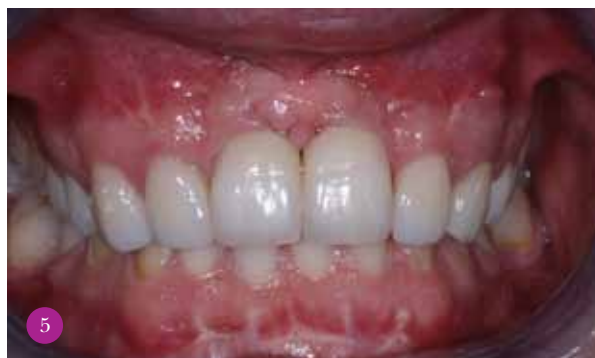

Fig 5 This patient apparently lost two front teeth (now replaced with implants) as well as the nerves of three teeth.

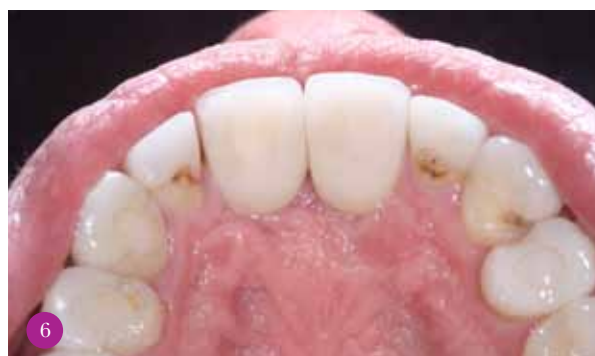
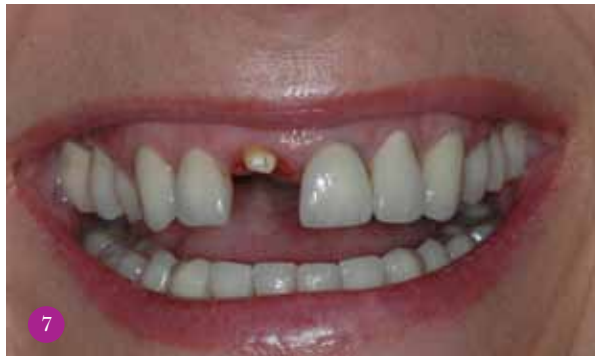
Fig 6 The upper right canine and both upper premolars had to be root filled following preparations for this porcelain pornography.

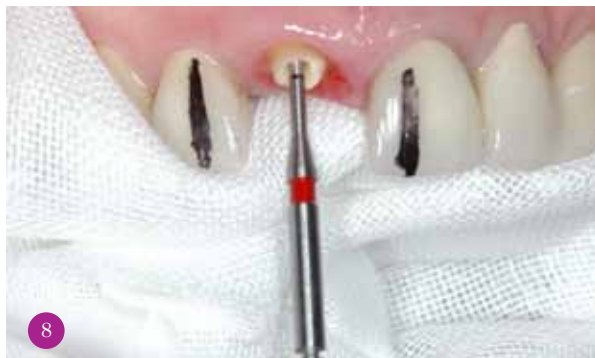'double mugging':  
these unfortunate  
patients are being  
robbed twice – first  
of their money and  
again of their enamel  
and dentine



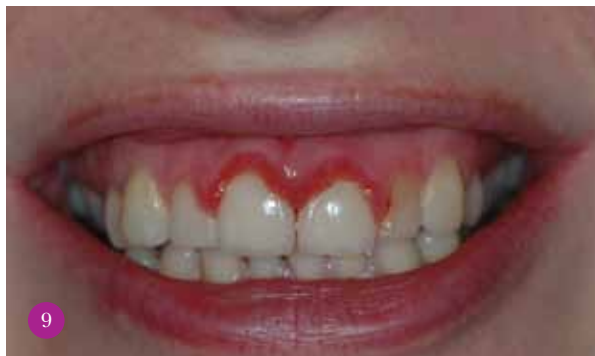**Fig 7** The core at the upper right central incisor broke off with the elective all-ceramic crown attached to it, following root filling for severe pulpal pain.



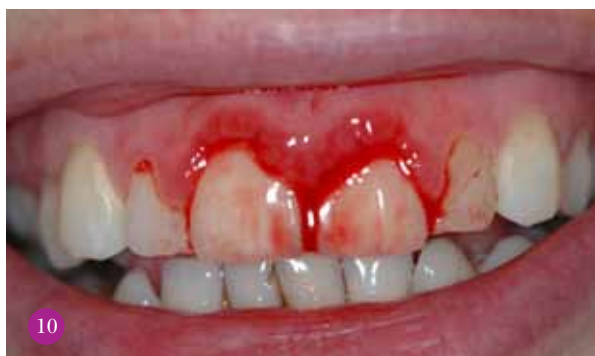**Fig 8** A post can deal (temporarily) with the problem in order to re-cement the pre-existing crown but it destroys even more sound tooth tissue



**Fig 9** Marked inflammation in pregnancy following two no-prep porcelain veneers. Note that the other teeth are minimally affected.



**Fig 10** 'Bleeding gingival' veneers. Is this a biologically neutral outcome for an elective aesthetic intervention? This is porcelain gloss at a biological loss.



and varying amounts of their precious and vulnerable dentine. Bearing in mind that this treatment is sometimes undertaken for relatively minor aesthetic problems of irregularity, colour or wear, it is difficult to see such destructive practices as being of predictable benefit to the patient's longer-term dental health.

Failing to temporise carefully these interventions on intact teeth is, sadly, a common clinical problem. It is during the couple of weeks (while the supposedly permanent crowns or extended veneers are being made) that many pulps develop severe inflammatory problems that may well cause them to die, either sooner or later (Figures 5 and 6). This is not surprising: sadly, many pulps succumb to the lethal combination of being rapidly shorn of their protective enamel overcoat and having their freshly opened tubules exposed to contamination by micro-leakage involving pathogenic oral bacteria.

#### Structural issues and reduction of strength by aggressive preparations

Teeth have evolved to be a certain shape and, in particular, incisors have evolved to act like chisels. Making already worn incisors appear, after preparation, as though they have been put in a pencil sharpener does little to improve the ability of these now grossly reduced (by 62–73%<sup>1</sup>) teeth to resist long-term loading. As a consequence of this, the core frequently breaks off with the crown attached (Figures 7 and 8), particularly if the tooth has had to be subsequently root filled through the ceramic restoration that was placed on the now much reduced residual dentine core.

#### Problems with 'no preparation' porcelain veneers

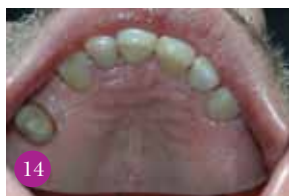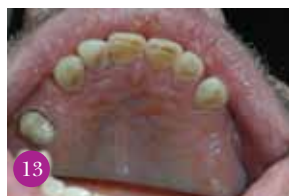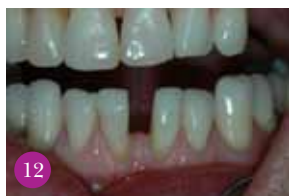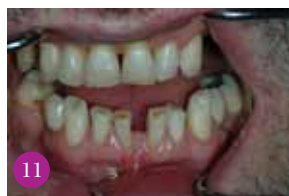Porcelain is a brittle material and it breaks if it is deformed by more than 0.1%. In an attempt to avoid pulpal or structural damage, very thin porcelain veneers of various types are sometimes touted as being biologically better and are promoted as being, superficially at least, minimally destructive while still having the gloss and low free surface energy of porcelain. However, over-contouring of teeth with 'no-prep' porcelain veneers can produce unpredictable periodontal, as opposed to pulpal, problems (Figures 9 and 10).

#### 'Bleaching and bonding' as an alternative to porcelain

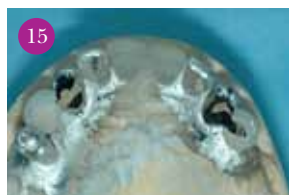Nightguard vital bleaching is a scientifically proven, safe and sensible way of managing discoloured teeth. Bleaching can be used on its own or can be combined with direct composite.

Adding directly bonded composite restorations carefully to the **outside** of worn incisors, and other teeth, can solve many clinical problems in a reasonable time for a moderate financial cost and with a fraction of the biological damage of porcelain restorations. I believe that most sensible, experienced, ethical dentists will testify to this. When managing worn teeth, if one considers pulp biology, the bio-engineering at work and the load-bearing

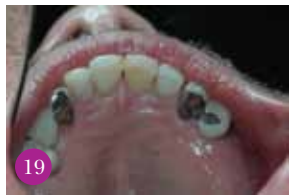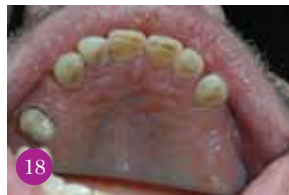## CASE STUDY



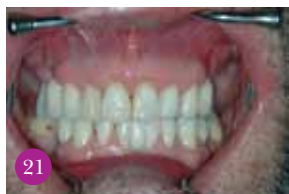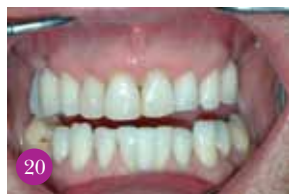Figs 11, 12, 13 and 14 Bleaching and bonding of the dark worn teeth with composite does not damage the pulps or the load bearing structure of the teeth.



Figs 15, 16 and 17 The patient refused to have dentures or implants. Three standard adhesive cantilever bridges reduced the visual problem of the gaps and increased the patients chewing function.



Figs 18 and 19 Bonding of the worn teeth at an increased anterior vertical dimension meant there was space created for the metal pads without removing any of the residual worn (but valuable) enamel.



Figs 20 and 21 Direct, free-hand composite bonded to the lingual enamel as well as the incisal enamel, provided it is placed in thick section, does well.<sup>2</sup>

strength of the teeth, then, in my view, *addition beats subtraction* when dealing with wear and many other cosmetic problems. In other words, it is more sensible to **add** to the worn or irregular teeth than to reduce the damaged teeth even further, both for reasons of strength and also for the preservation of residual pulpal health.

Minor chips or staining of composite on the **outside** of teeth do happen and are a price worth paying when compared with the gross biological cost of losing 62–73%<sup>1</sup> of the tooth structure merely because porcelain looks shinier than composite. As a consequence of porcelain being a fundamentally brittle and flawed material, its utilisation often requires extensive milling and destruction of sound tooth tissue. This seems a crazy philosophy, ie removing a proven, load-bearing, durable bio-material (sound tooth structure) in order to replace it with a newly fashionable but relatively unproven, indirectly fabricated ceramic material.

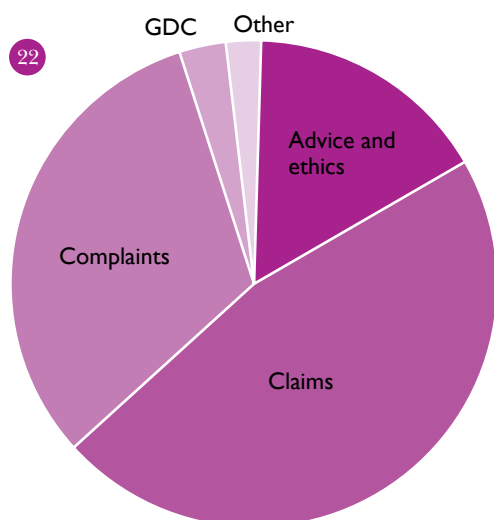
Many years ago most of us, when faced with the sad failure of our own and/or other dentists' restorations, realised we had gone astray and that, somehow, we now had the wrong focus for the outcome of our dentistry. It gradually dawned on most of us that rather than concentrating on the survival of our restorations, dentists should instead focus on the outcome for *the tooth and the patient* if, and when, the restoration failed. As a consequence, maintaining sound tooth structure and pulpal health then re-assumed their rightful positions as the more important priorities.

The **Case study** illustrates how the problems of missing, dark or worn teeth can be managed in order to improve their appearance and function, with minimal biologic damage, while still maintaining sensible fall-back positions for the patient's future life.

I am not sure how clinicians who continue to do this sort of extensive, elective porcelain veneer work have managed to avoid all the evidence, widely published over the past 10 years or so, that building up worn incisor teeth with direct composite when the wear is moderate-to-severe is a more successful approach. In a number of publications on this topic composite has been added successfully to worn teeth at an increased vertical dimension (Poyser *et al.*<sup>2</sup> Hemmings and Darbar<sup>3</sup>) and the results have been shown **not** to have long-term damaging effects on the treated teeth. This is of particular importance as patients will need their own sound teeth for very many more years than the traditional three-score-years-and-ten.

#### Why destroy sound tooth structure?

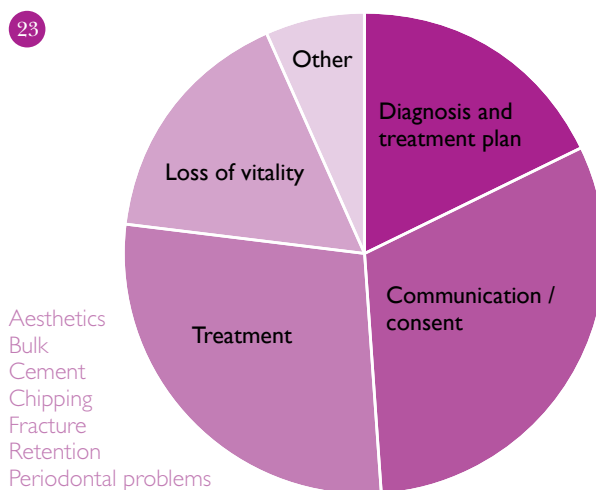
I am not certain where or when some dentists caught or developed this pathologic hatred of sound tooth tissue. Many of us were trained when the only option for restoring heavily damaged teeth was a crown, frequently involving relatively heavy tooth preparation. To the best of my memory, at that time, the key principles taught in the dental schools generally were, and probably still are, the 'preservation of sound tooth tissue' while developing



**Fig 22** Where dental veneer cases brought before Dental Protection Ltd 'finished up' 2005–2010.

There has been a significant rise in complaints and claims over the past five years. The claims significantly outnumber the complaints and claims usually start as complaints.

*Source: Personal communication from Kevin Lewis, Dental Protection Ltd, London, April 2011. Acknowledged with thanks.*



**Fig 23** Root cause analysis of dental veneer cases brought before Dental Protection Ltd 2005–2010.

The causes of complaint are often about consent, communication, the treatment itself, subsequent problems of teeth dying, veneers chipping, breaking or being lost, as well as periodontal problems around the veneers.

*Source: Personal communication from Kevin Lewis, Dental Protection Ltd, London, April 2011. Acknowledged with thanks*

retention and resistance form for the restorations. These key principles also extended to preparing teeth:

1. Only where there was a clear benefit to the patient in doing so.
2. Where the risk-to-reward ratio had been considered at length and only in those cases when the ratio involved was deemed to be favourable for the patient in the longer term.

Seriously destructive preparations of teeth with minor wear or with subjective aesthetic problems are a cause for grave professional concern. I doubt if patients genuinely realise that up to two thirds of their sound tooth structure will be removed in making their tooth ready to receive a crown and that they may well end up with restorations that have all the shapely attractiveness of a lavatory wall tile (Figure 2, for example).

Perhaps in 20 years, the sensible dentists (who will have to deal with the inevitable failures) will regard with sadness, anger or revulsion the unnecessary loss of the structure and strength of those patients' teeth, as well as the hazarding of the pulps. Certainly, all too frequently we now see illustrations and descriptions of how to turn somebody with very reasonable dental health, but with a bit of wear, minor discolouration or irregularity, into someone whose teeth match their bathroom fittings: this seems to me, at least, to be a very bad biological and financial deal.

In my view, many of these unfortunate patients are being robbed twice – first of their money and again of their

(even more precious) sound tooth structure. I call this 'double mugging'.

I recently published an article in *Dental Update* called 'The "daughter test" in elective aesthetic ("esthetic") dentistry'.<sup>4</sup> This test asks the question, whenever one is contemplating elective intervention that involves tooth destruction: 'Knowing what I know about dentistry and the effects of this elective treatment on the health and structure of the teeth in the long term, would I carry out this treatment on my own daughter?' I don't know of any sensible, experienced, ethical dentist who would elect to do invasive and destructive treatment on anyone they cared about if there were any reasonable alternatives available. The motivation for treatments that appear to be very aggressive seems frequently to be influenced by factors other than the longer-term health of the teeth and the well-being of the patient, many of whom will, quite reasonably, expect to live to a ripe old age and to still have their own teeth functioning.

This fashion for porcelain pornography is a real and present danger for the dental profession at large. This type of dentistry appears to be promoted by both individuals and some dental publications that have strong commercial interests. In so doing, younger colleagues could well be encouraged down a path leading to the unnecessary destruction of many sound teeth and, in the process, hazard not only their patients' long-term dental well-being but also their own professional status and safety.



### Complaints and claims about porcelain veneers

There are many sources of complaints and large claims involving porcelain veneers. These range from failure to satisfy patients' expectations or to obtain proper informed consent, through to technical issues of excessive bulk, chipping, fracture, loss of veneers and death of the treated teeth. Some cases have ended up as complaints to the General Dental Council.

Dental Protection Ltd has summarised the distribution of some of the problems in **Figures 22 and 23**.

### How did we find ourselves here?

Nobody is absolutely certain about when and where PDD started. It is thought that it originated in America, following the re-introduction of porcelain veneers by Calamia and Horn.<sup>5,6</sup> Originally, porcelain veneers were conservative treatment preparations. Kept in enamel, they proved to be very reliable and a useful addition to the armoury of a dentist. However, there is a limited market for porcelain veneers which have to be kept in enamel and the advent of dentine bonding agents persuaded some dentists to expand their repertoire to include cases which involved much more radical reduction of teeth, including dentine destruction. This was done in order to produce the very even, very white look popularised by Hollywood in the 1980s and 1990s.

This fashion then inexorably rolled across the Atlantic to the UK. Patients with a lot of disposable income were particularly vulnerable: the money a patient has available for treating PDD seems to be directly linked to the risk of the patient developing PDD, something which has confounded many dental pathologists. It has not been established that any UK dental school has ever taught that it is sensible, or reasonable, to destroy sound tooth tissue needlessly when the teeth have not been affected by the consequences of caries or other real dental pathology.

The rise of PDD was not only linked to disposable incomes and fashion but also to the development of various ceramic materials. A separate paper could be written on how appropriate or rigorous the clinical testing of these supposedly wonderful ceramic materials was before they were christened with a proprietary name and promoted with breathless enthusiasm to dentists. Suffice it to say, I would hope that long-term, properly designed clinical trials took place prior to their commercial release. Sadly, I have not seen good evidence in the literature on the long-term **benefits to teeth** in being treated this way. Many of the (very limited) studies that are reported are short-term and often tainted by commerce or other study problems. Irrespective of this, in real-life practice relatively sound tooth tissue often has to be damaged or removed in order to provide one path of insertion for these indirectly fabricated restorations.

Many of these restorations were, and are, cemented with composite resins. Curiously, the advocates for porcelain veneers and other more extensive restorations often pooch-pooch composite as being a poor quality material

and yet chose the very worst of composites, ie a poorly filled composite resin, to cement their superficially beautiful and supposedly 'permanent' restorations.

Incidentally, 'permanent' is considered by most people to be an absolute term. Lawyers, in particular, understand what the word 'permanent' means and to them, at least, it isn't a permanent restoration when nearly 50% are either no longer present or satisfactory after 10 years.<sup>7</sup>

The worst of this practice, the porcelain pornography, needs to be seen for what it is: willful and unnecessary violence being done to mainly healthy teeth, where clinical sense seems to be overridden by other, less virtuous (or short-sighted) motives. All clinicians should place the long-term health and safety of their patients first.

Many of these extensive porcelain 'veneer-ology' treatments seem to be designed in order to produce wealthier dentists but not healthier teeth. When will this madness end?

### References

1. Edelhoff D, Sorensen JA. Tooth structure removal associated with various preparation designs for anterior teeth. *J Prosthet Dent* 2002; **87**: 503–529.
2. Poyser NJ, Briggs PFA, Chana HS et al. The evaluation of direct composite restorations for the worn mandibular anterior dentition – clinical performance and patient satisfaction. *J Oral Rehabil* 2007; **34**: 361–76.
3. Hemmings KW, Darbar UR, Vaughan S. Tooth wear treated with direct composite restorations at an increased vertical dimension: Results at 30 months. *J Prosthet Dent* 2000; **83**: 287–293.
4. Kelleher MGD. The 'daughter test' in aesthetic ('esthetic') or cosmetic dentistry. *Dent Update* 2010; **37**: 5–11.
5. Calamia JR. Etched porcelain facial veneers: a new treatment modality based on scientific and clinical evidence. *NY J Dent* 1983; **53**: 255–259.
6. Horn HR. Porcelain laminate veneers bonded to etched enamel. *Dent Clin North Am* 1983; **27**: 671–684.
7. Burke FJ, Lucarotti PS. Ten-year outcome of crowns placed within the General Dental Services in England and Wales. *J Dent* 2008; **37**: 31–38.

bleaching and  
bonding solves  
many aesthetic  
dental problems  
at minimal  
biological cost  
and at reasonable  
financial cost