

# A case of profusely bleeding large nasal polypi cured with Homoeopathy

© Dr. Rajneesh Kumar Sharma

BSc, BHMS, MD (Homoeopathy), DI (Hom) London, hMD (UK) etc.

Homoeo Cure & Research Institute

NH 74, Moradabad Road, Kashipur (Uttaranchal)

INDIA, Pin- 244713 Ph. 05947- 260327, 9897618594

[drjneeshom@hotmail.com](mailto:drjneeshom@hotmail.com), [drjneeshom@yahoo.co.in](mailto:drjneeshom@yahoo.co.in)

[www.homeopathicreatment.org.in](http://www.homeopathicreatment.org.in), [www.treatmenthomeopathy.com](http://www.treatmenthomeopathy.com),

[www.homeopathyworldcommunity.com](http://www.homeopathyworldcommunity.com)



Mr. Sharma, a senior citizen, presented with heavy bleeding from both nostrils twice or thrice a week. Was seeking treatment in modern medicine and only option told to him was surgery. Was a one sided patient as no marked symptoms were there.

He was a lean thin, hot patient but thirstless, craving sweets, fats and warm food. No other symptoms were noted as he answered normal for every relevant questions.

Repertorization was done only for marked generals and the case responded quickly and almost cured within four months.

## Repertorization

**KPS M 68 Years R. No. 19222 / B/L Nasal Polypi**

**Small remedies + small rubrics - Small remedies + small rubrics - Intensity is considered**

| S. No. | Grade | Rubric  | No. of Remedies |
|--------|-------|---|-----------------|
| 1      | 2     | GENERALS - FOOD and DRINKS - fat - desire       | 76              |
| 2      | 2     | GENERALS - FOOD and DRINKS - sweets - desire    | 281             |
| 3      | 1     | GENERALS - FOOD and DRINKS - warm food - desire | 41              |
| 4      | 2     | GENERALS - LEAN people                          | 124             |
| 5      | 1     | NOSE - POLYPUS - bleeds easily                  | 4               |

|   | calc-p. | calc. | nat-ar. | phos. | tub. | nicc-s. | dys. | prot. | ars-met. | sanic. |
|---|---------|-------|---------|-------|------|---------|------|-------|----------|--------|
|   | 20      | 15    | 15      | 15    | 15   | 12      | 12   | 12    | 12       | 12     |
| 1 | 2       | 1     | 1       | 1     | 1    | 1       | 1    | 1     | 1        | 1      |
| 2 | 1       | 2     | 1       | 2     | 2    | 1       | 1    | 1     | -        | 1      |
| 3 | -       | 1     | 1       | -     | 1    | -       | -    | -     | 1        | -      |
| 4 | 3       | -     | 1       | 2     | 1    | 1       | 1    | 1     | 1        | 1      |
| 5 | 1       | 1     | -       | 2     | -    | -       | -    | -     | -        | -      |

## Prescription

Calcarea Phos 1 M one dose stat on 03-03-2014

Follow ups on 11-03-2014, 20-04-2014, 30-05-2014, 21-06-2014 and 17-07-2014.

No medicine required except placebos.

## Result

Symptoms disappeared within week. Bleeding occurs only once in first week but in small amounts. No symptoms were reported afterwards.

Again complete cure with the similimum. Reports attached.

## Rhinoscopy Report

**Name:** Krishna Pal Sharma

**Age:** M 68

**Referring Clinic Name:** HCRC

Type of Exam:

 Screening

 Diagnostic

Date of Exam: 03-03-2014

Left Nostril

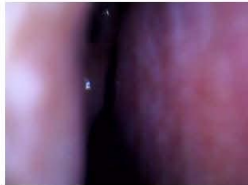


Image 1

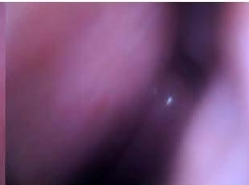

Image 2

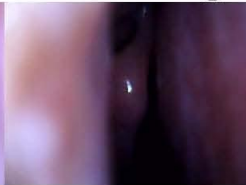

Image 3

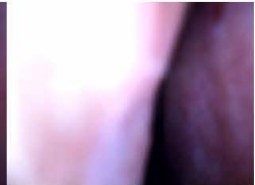


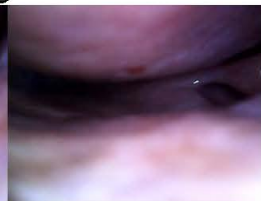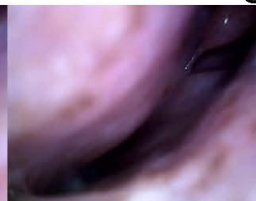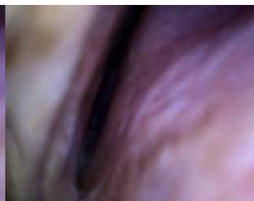Image 4

Right Nostril

Remarks: Polypi both nostrils.

Review Date:- 17-07-2014

Left Nostril



Right Nostril

Remarks: Marked regression of Polypi as compared to previous endoscopy.