

A Case of Huge Pleural Effusion Cured with Homoeopathy

© Dr. Rajneesh Kumar Sharma MD (Homoeopathy)

Homoeo Cure Research Institute
NH 74- Moradabad Road
Kashipur (UTTARANCHAL) - INDIA
Ph- 09897618594
E. mail- dr Rajneeshhom@hotmail.com
www.homeopathictreatment.org.in
www.treatmenthomeopathy.com
www.homeopathyworldcommunity.com



Definition

A PLEURAL EFFUSION is an abnormal, excessive collection of this fluid (Sycosis/ Pseudopsora). Excessive amounts of such fluid can impair breathing by limiting the expansion of the lungs during respiration.

Types of Effusions

1. TRANSUDATIVE PLEURAL EFFUSIONS

A fluid substance passed through a membrane or extruded from a tissue is of high fluidity and has a low content of protein, cells, or solid materials derived from cells is called transudative fluid. This effusion is caused by increased pressure (Psora), or low protein content in the blood vessels (Syphilis). A transudate is a clear fluid, similar to blood serum. It reflects a systemic disturbance of entire body. (Pseudopsora)

Causes of Transudates

- Atelectasis (Psora/ Syphilis)
- Early Cirrhosis (Psora/ Syphilis/ Sycosis)
- Congestive heart failure (Psora/ Sycosis)
- Hypoalbuminemia (Psora/ Syphilis)
- Nephrotic syndrome (Psora/ Sycosis/ Syphilis)
- Peritoneal dialysis (Causa occasionalis)

2. EXUDATIVE EFFUSIONS

A fluid rich in protein and cellular elements that oozes out of blood vessels due to inflammation is called exudative effusion (Pseudopsora/ Sycosis). It is caused by blocked blood vessels, inflammation, lung injury, and drug reactions (Psora/ Sycosis). It often is a cloudy fluid, containing cells and much protein, signifying underlying pleuropulmonary disease (Pseudopsora/ Sycosis).

Causes of Exudates

- Asbestos exposure (Causa occasionalis)

- Atelectasis (Psora/ Syphilis)
- Haemothorax Infection (bacteria, viruses, fungi, tuberculosis, or parasites) (Pseudopsora/ Sycosis).
- Pulmonary embolism (Causa occasionalis/ Psora/ Sycosis)
- Uremia (Psora/ Sycosis/ Syphilis)

Types of fluids

Four types of fluids can accumulate in the pleural space-

1. **Serous fluid (hydrothorax):** A hydrothorax is a condition that results from serous fluid accumulating in the pleural cavity. This specific condition can be related to cirrhosis with ascites in which ascitic fluid leaks into the pleural cavity. (Sycosis)
2. **Blood (haemothorax):** is a condition that results from blood accumulating in the pleural cavity. (Pseudopsora/ Sycosis)
3. **Chyle (chylothorax):** chyle is a milky bodily fluid consisting of lymph and emulsified fats, or free fatty acids (FFAs). It is formed in the small intestine during digestion of fatty foods. It results from lymphatic fluid (chyle) accumulating in the pleural cavity. (Psora)
4. **Pus (pyothorax or empyema):** is an accumulation of pus in the pleural cavity. (Pseudopsora/ Sycosis/ Syphilis)

Pathophysiology

It is explained by increased pleural fluid formation or decreased pleural fluid absorption (Psora/ Sycosis). Increased pleural fluid formation can result from elevation of hydrostatic pressure & decreased osmotic pressure (Psora/ Sycosis). It leads to increased capillary permeability and passage of fluid through openings in the diaphragm (Psora). Hence production increases and absorption decreases (Psora). Lymphatic obstruction may also cause effusion (Sycosis). Pleural effusions produce a restrictive ventilatory defect and also decrease the total lung capacity and vital capacity. (Psora)

CLINICAL MANIFESTATION

Pleuritic chest pain indicates inflammation of the parietal pleura (Psora/ Pseudopsora). Chest pain, usually a sharp pain, is worse with cough or deep breaths. Cough, fever, rapid breathing, shortness of breath etc. may accompany it (Psora).

DIAGNOSTIC EVALUATION

Physical examination can reveal the presence of an effusion by dull or flat note on percussion and diminished or absent breath sounds on auscultation.

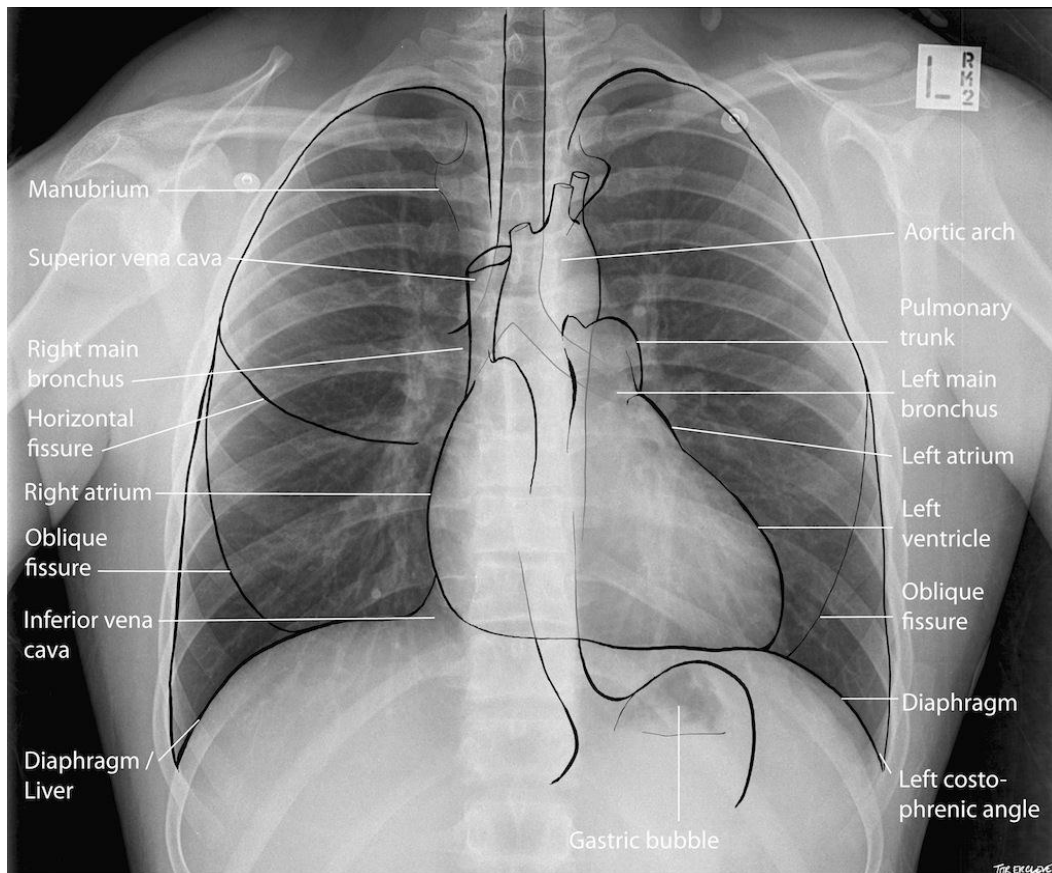
Pleural fluid analysis

Thoracentesis

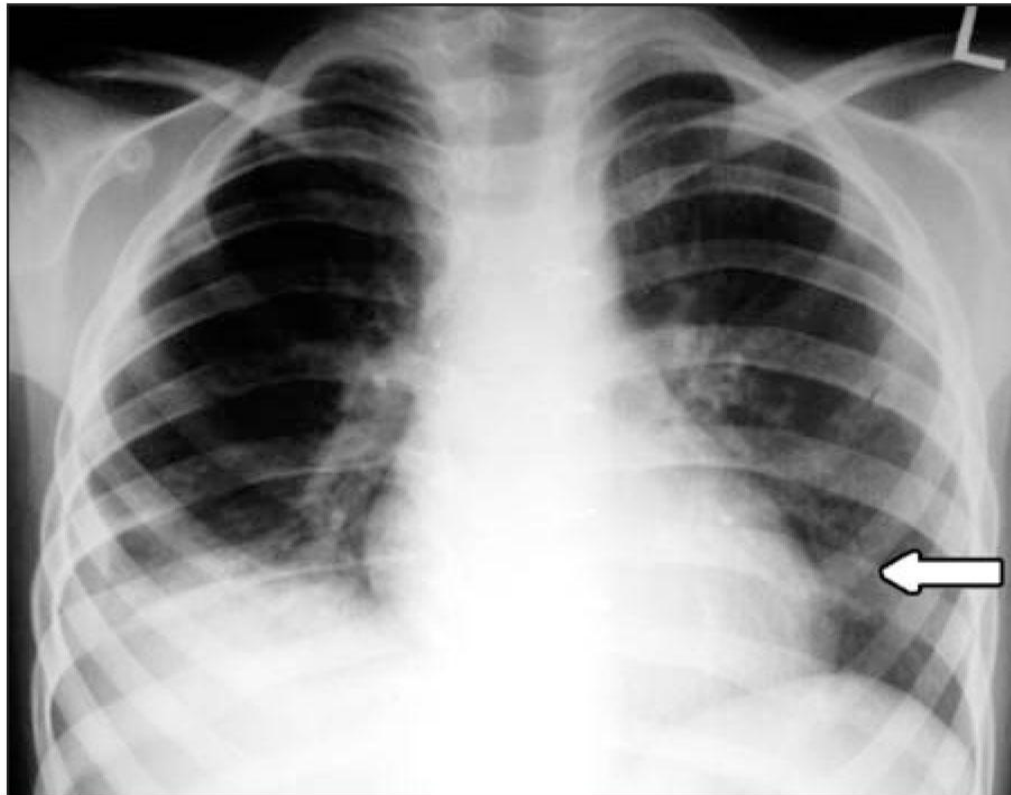
Chest Radiography: The posteroanterior and lateral chest radiographs are still the most important initial tools in diagnosing a pleural effusion.

Ultrasound is useful both as a diagnostic tool and as an aid in performing thoracentesis. It assist in identifying pleural fluid loculations.

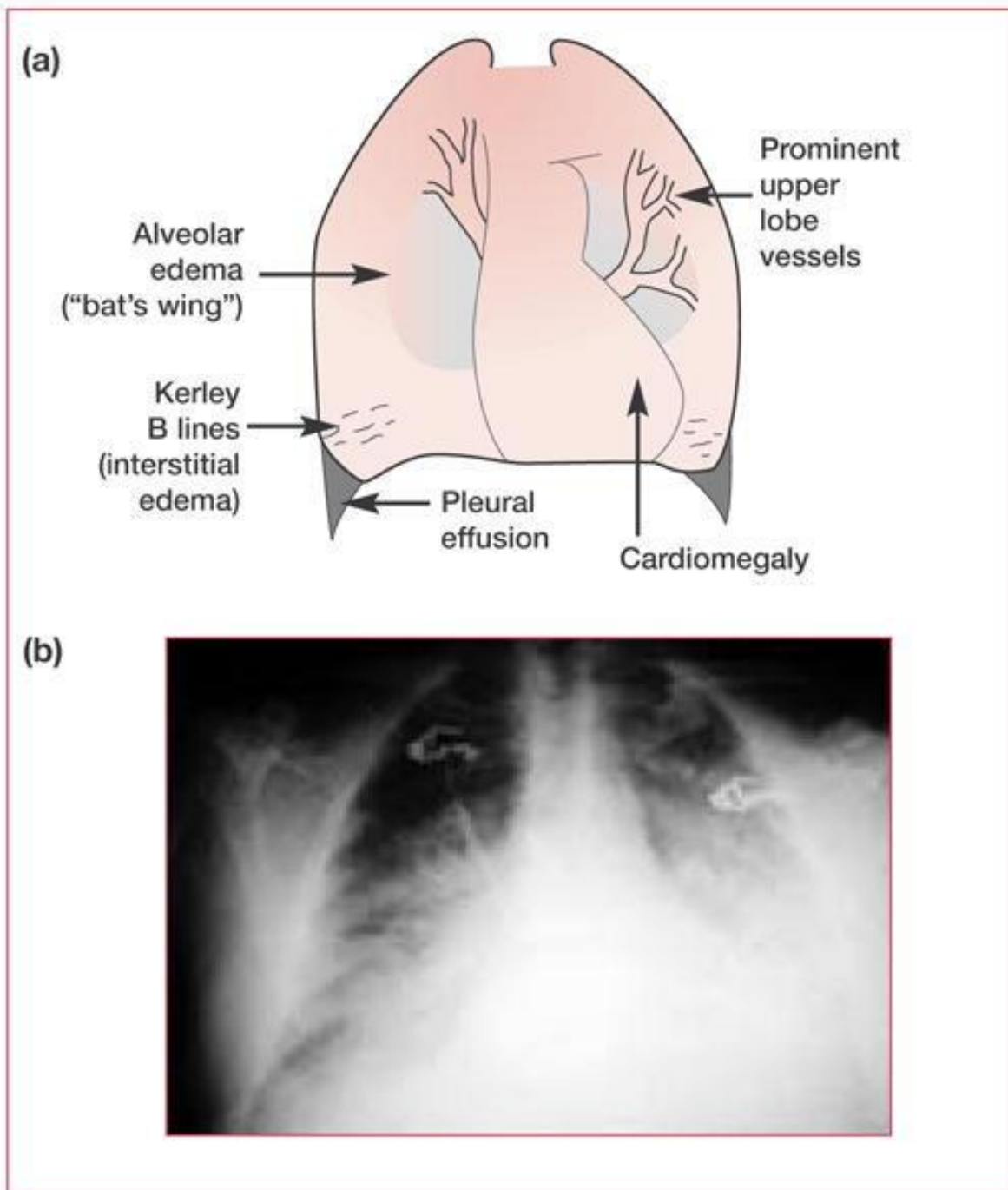
Computed Tomography: It helps distinguish anatomic compartments more clearly. This modality is useful as well in distinguishing empyema.



Normal Chest X Ray P A View



Chest X-ray show right side blunting of costophrenic angle (black arrow) due to pleural effusion



Treatment

Aims:

- To remove the fluid
- Prevent fluid from building up again
- Treating the cause of the fluid buildup

Therapeutic thoracentesis

It may be done if the fluid collection is large and causing chest pressure, shortness of breath, or other breathing problems, such as low oxygen levels. Removing the fluid allows the lung to expand, making breathing easier.

In some cases, Surgery may be needed.

Comfortable position

To maintain a comfortable position, usually elevated headboard is used.

Oxygen level

To supply oxygen.

Nutrition level

To maintain nutrition supply if intake less than body requirement related to inability to ingest adequate nutrients.

Body fluid level

To maintain body fluid volume lost due to drainage, by oral/ i. v. method.

Possible Complications

A lung that is surrounded by excess fluid for a long time may be damaged. Pleural fluid that becomes infected may turn into an abscess, called an empyema. Pneumothorax can be a complication of the thoracentesis procedure.


References




Chapter 22. Pleural Effusions, Excluding Hemothorax CURRENT Diagnosis & Treatment in Pulmonary Medicine



Chapter 117. Thoracentesis Principles and Practice of Hospital Medicine



The Chest: Chest Wall, Pulmonary, and Cardiovascular Systems; The Breasts > Dullness and diminished vibrations—pleural effusion or pleural thickening DeGowin's Diagnostic Examination, 10e



Chapter 263. Disorders of the Pleura and Mediastinum > Pleural Effusion Harrison's Online



Chapter 107. Basic Chest Radiography (CXR) > Pleural Effusion Principles and Practice of Hospital Medicine



Occupational Lung Diseases > BENIGN PLEURAL EFFUSIONS CURRENT Diagnosis & Treatment: Occupational & Environmental Medicine, 5e




Chapter 5. Postoperative Complications > Postoperative Pleural Effusion & Pneumothorax
CURRENT Diagnosis & Treatment: Surgery, 13e



Chapter 4. Radiology of the Chest > Exercise 4-13. Pleural Effusion Basic Radiology, 2e



Chapter 13. Pulmonary Pathology > Pleural Effusions Pathology: The Big Picture



Chest Wall, Lung, Mediastinum, and Pleura > Pleural Effusion Schwartz's Principles of Surgery

The Case study

Mrs. Ritu, F 42 developed shortness of breath, complete anorexia, cough and weakness for last one month. The symptoms grown worse and worse day by day and she became unable to lie down in bed for shortness of breath and cough which aggravated after midnight and she was so panic as in agony. The only comfortable position was to sit up. Usually, cough had two paroxysms. She was obliged to sit up in bed or keep herself in half sitting position. She developed extreme aversion to food, even smell of food causing her nausea.

On examination, she was found to be hypertensive, asthmatic, nondiabetic, pale, anemic and too weak even unable to walk.

Haemogram, LFT, KFT, Electrolytes, Lipid profile, CK MB etc. all were within normal range.

ECG revealed cardiomegaly with LVH.

Echocardiography revealed cardiac overload, reduced left ventricular efficiency with mild PR.

Chest X ray PA view showed marked cardiomegaly with pulmonary congestion with bilateral pleural effusion, more on right side.

HRCT Thorax revealed almost same findings as in chest x ray.

On further case taking, she revealed history of menorrhagia due to adenomyosis uteri for last 3 years, bleeding piles due to constipation and hard stools.

Mild albuminuria, borderline diabetes mellitus, hyper loaded kidneys with elevated blood creatinine level and anemia.

X Ray Chest PA View dated 03-01-2015

Jeevan Rekha M.R.I. & C.T. Scan Centre

Opp. Jaspur Bus Stand, Moradabad Road, Kashipur (U.S.Nagar) Uttarakhand
Mobile : 9319692514, 9837318884, 9837786185

Dr. D.N.Gangwar MBBS,MD(RADIO-DIAGNOSIS)		Dr. Nidhi Gupta MBBS,DNB(PATHOLOGY)	
Date	03/01/2015	Srl No.	11
Name	MRS. Ritu Sharma	Age	41 Yrs.
Ref. By	Dr. Rajneesh K.Sharma BHMS,MD.	Sex	F
Reporting Date		03/01/2015	

X-RAY CHEST PA VIEW

Soft tissues and bony cage under view are normal.

Lung fields are congested.

Bilateral hilar shadows are normal.

Mediastinum and domes are normal.

Costophrenic angles are clear.

Cardiac size is mildly enlarge.

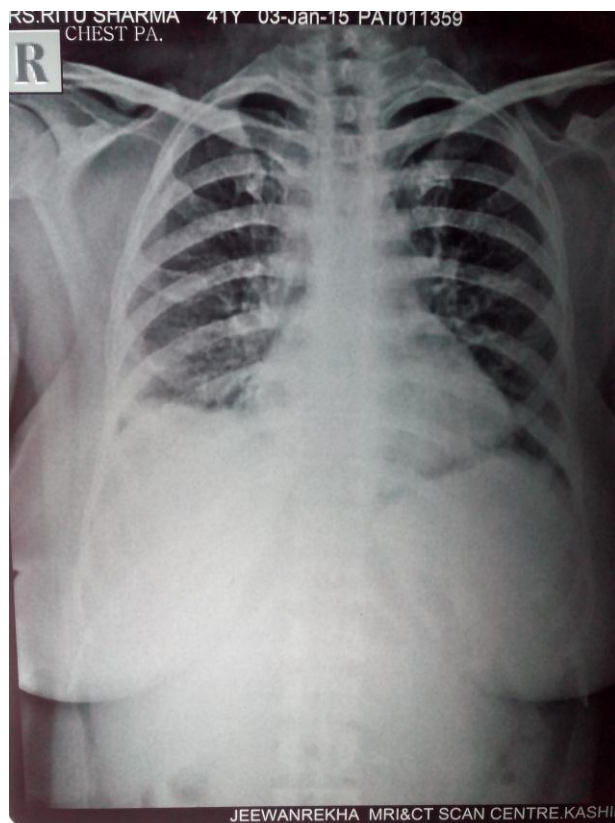
Adv. :- TLC,DLC,ESR & Sputum Examination.
Echo.

Please correlate clinically.

Dr. D. N. Gangwar
MBBS, MD (Radiodiagnosis)
Consultant Radiologist

Discrepancies due to technical or typing errors should be reported for correction with seven days
No compensation liability stands.

M.R.I., Spiral C.T., Mammography, Digital X-ray, Ultrasound, Colour Doppler, OPG & Pathology
Not For Medicolegal Purpose



X Ray Chest PA View dated 20-01-2015

Jeevan Rekha M.R.I. & C.T. Scan Centre

Opp. Jaspur Bus Stand, Moradabad Road, Kashipur (U.S.Nagar) Uttarakhand
Mobile : 9319692514, 9837318884, 9837786185

Dr. D.N.Gangwar MBBS,MD(RADIO-DIAGNOSIS)		Dr. Nidhi Gupta MBBS,DNB(PATHOLOGY)	
Date	20/01/2015	Srl No.	52
Name	MRS. Ritu Sharma	Age	41 Yrs.
Ref. By	Dr. Rajneesh K.Sharma BHMS,MD.	Sex	F
Reporting Date		20/01/2015	

X-RAY CHEST PA VIEW

Soft tissues and bony cage under view are normal.

Lung fields are congested.

Bilateral hilar shadows are normal.

Mediastinum and domes are normal.

Right CP angle is blunt. Left costophrenic angle is clear.

Cardiac size is mildly enlarge.

IMPRESSION :- Congested lung field with mild cardiomegaly.

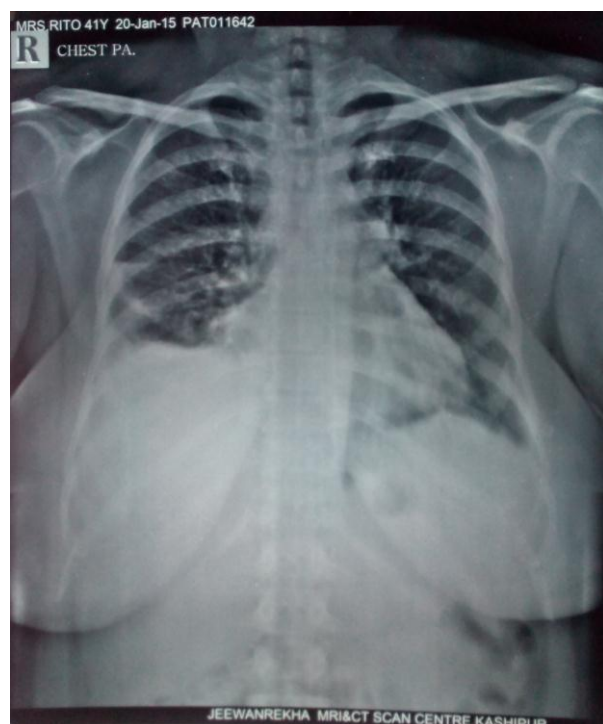
Adv. :- TLC,DLC,ESR & Echo.

Please correlate clinically

Dr. D. N. Gangwar
MBBS, MD (Radiodiagnosis)
Consultant Radiologist

Discrepancies due to technical or typing errors should be reported for correction with seven days
No compensation liability stands.

M.R.I., Spiral C.T., Mammography, Digital X-ray, Ultrasound, Colour Doppler, OPG & Pathology
Not For Medicolegal Purpose



HRCT Thorax dated 21-01-2015

Jeevan Rekha M.R.I. & C.T. Scan Centre

Opp. Jaspur Bus Stand, Moradabad Road, Kashipur (U.S.Nagar) Uttarakhand
Mobile : 9319692514, 9837318884, 9837786185

Name of patient	MRS. RITU SHARMA	Age / Sex — 41/F	No. of films
Referred by	DR. RAJNEESH KUMAR SHARMA, MD	January 21, 2015	2

CT Scan of Thorax

Plain axial scans were taken in the region of interest. Intravenous contrast enhanced axial scans were taken from the thoracic inlet to the lung bases. Study reveals:

- **Trachea & bronchi:** Trachea is normal in diameter, shape, position & bifurcation. No evidence of any narrowing or intraluminal mass lesion. Right and left main bronchi are normal in size & diameter.
- **Lungs and pleura:** Moderate right pleural effusion is seen with small effusion in horizontal fissure on right side with no evidence of pleural thickening or calcification. Focal small area of atelectasis is seen in anterior segment left upper lobe. Rest of lung parenchyma is normal in attenuation. No evidence of interstitial thickening. No lung mass or nodule is seen.
- **Mediastinum:** Heart & major mediastinal vessels are normal. Few enlarged right paratracheal and paratracheal lymph node is seen. No mass lesion is seen. No evidence of pericardial effusion.
- **Chest wall & axillae:** Chest wall musculature is normal. Bony thorax is normal. Bilateral axillae are normal. No evidence of axillary lymphadenopathy.

Impression: Focal small atelectasis in anterior segment left upper lobe and moderate right pleural effusion with minimal left side pleural effusion with few enlarged mediastinal lymph nodes likely infective.

Adv: TLC, DLC, ESR, Mx test and pleural fluid examination.

DR. P. K. SINGH
MD (Radiodiagnosis)

DR. D. N. GANGWAR
MD (Radiodiagnosis)

Dr S K Gupta
MD (Radiodiagnosis)

M.R.I., Spiral C.T., Mammography, Digital X-ray, Ultrasound, Colour Doppler, UPG & Pathology
Not For Medicolegal Purpose

X Ray Chest PA View dated 19-02-2015

Jeevan Rekha M.R.I. & C.T. Scan Centre

Opp. Jaspur Bus Stand, Moradabad Road, Kashipur (U.S.Nagar) Uttarakhand
Mobile : 9319692514, 9837318884, 9837786185

Dr. D.N. Gangwar MBBS, MD (RADIO-DIAGNOSIS)	Dr. Nidhi Gupta MBBS, DNB (PATHOLOGY)
Date 19/02/2015	Ref No. 62
Name MRS. Reetu Sharma	Age 40 Yrs.
Ref. By Dr. Rajneesh K. Sharma BHMS, MD.	Sex F

X-RAY CHEST PA VIEW

Soft tissues and bony cage under view are normal.

Lung fields are normal.

Bilateral hilar shadows are normal.

Mediastinum and domes are normal.

Costophrenic angles are clear.

Cardiac size and shape is normal.

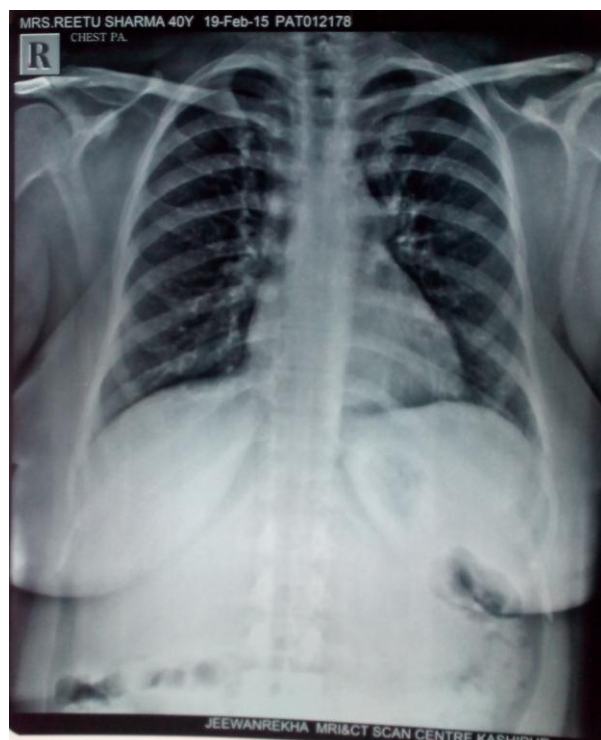Adv. :- TLC, DLC, ESR.

Please correlate clinically

Dr. D. N. Gangwar
MBBS, MD (Radiodiagnosis)
Consultant Radiologist

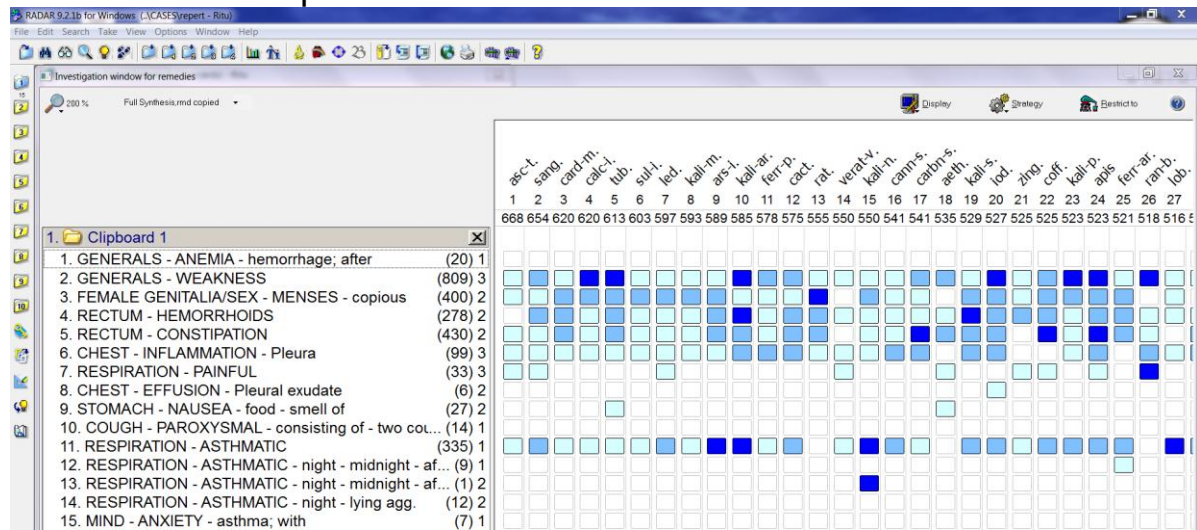
Discrepancies due to technical or typing errors should be reported for correction with seven days
No compensation liability stands.

M.R.I., Spiral C.T., Mammography, Digital X-ray, Ultrasound, Colour Doppler, OPG & Pathology
Not For Medicolegal Purpose



Complete resolution of effusion and restoration of normal cardiac size with normal findings in blood and urine exams.

Evaluation and repertorization



Prescription

On looking at a glance, Asclp. Tub seems to be similimum, but modalities were so marked Kali nitricum was found to be most suitable.

RESPIRATION - ASTHMATIC - night - midnight - after - sitting up in bed - must sit up

KALI-N.

A single dose of Kali nitricum was given on 03rd January 2015 in morning. There was mild aggravation that night.

Since second night, improvement in general condition started but dyspnea and cough was increased. Surprisingly, there was sense of wellbeing along with aggravation in particulars.

X ray and HRCT scan were done on 20 and 21 January respectively. Both were showing slight worsening in conditions at pathological levels. The only supporting symptom was a feeling of better health all the time. Night agony was also better in spite of dyspnea and cough. Appetite was much better now.

By the end of 20th day, she was miraculously better and all the symptoms gone except some weakness.

The last scan was done on 03rd January 2015 and there was no sign of disease. No fluid, no cardiomegaly and no pulmonary congestion.

A complete cure of gross pathological changes with a single dose of the similimum remedy!