

A Case of Alopecia areata Cured with Homoeopathy

© Dr. Rajneesh Kumar Sharma M.D. (Homoeopathy)

Dr. Swati Vishnoi B.H.M.S.

Homoeo Cure & Research Institute

NH 74, Moradabad Road, Kashipur (Uttaranchal) INDIA

Pin- 244713 Ph. 05947- 260327, 9897618594

E. mail- drrajneeshom@hotmail.com

www.treatmenthomoeopathy.com

www.homeopathicreatment.org.in

www.homeopathyworldcommunity.com



Etymology

Greek- Alopecia- fox disease, on account of foxes changing their fur twice a year.

Areata- occurring in patches or circumscribed areas.

DEFINITION

Alopecia areata is chronic non-scarring autoimmune disorder (Psora/ Syphilis/ Pseudopsora) affecting the hair follicle, presented by a sudden onset of solitary or multiple circular or oval bald areas, usually affecting the scalp, and may affect any hair-bearing area.

The affected scalp is usually normal in colour but may be erythematous (Psora/ Pseudopsora). Hairs at the edge of the patch may be easily removed with gentle traction. Spontaneous regrowth frequently occurs, but the areas may spread peripherally and may eventually involve the whole scalp, called alopecia totalis and even facial and body hair called alopecia universalis. As well as hair, alopecia areata can affect the nails. (Psora/ Pseudopsora/ Sycosis)

Incidence

It happens in all races and either sex equally and may present at any age, with the highest incidence between 10 and 30 years.

Pathophysiology

Sometimes, the immune system mistakenly targets the body instead of harmful antigen. In alopecia areata, the immune system attacks the hair follicles leading to hair loss (Psora/ Syphilis). When white blood cells attack the cells in hair follicles, they shrink and dramatically slow down hair production. The exact cause is still unknown.

Causes

- Family history of alopecia areata (Pseudopsora)
- Family history of other autoimmune disorders, such as Down syndrome or atopy. (Syphilis)
- Stress (Psora)
- Alopecia areata often develops suddenly, over the course of just a few days.

Signs and symptoms

Patchy hair loss

Coin-sized patches of hair begin to fall out, mainly from the scalp, but any hair-bearing site such as the beard and eyelashes can also experience the hair loss.

Sudden hair loss

The loss of hair can be sudden, developing in just a few days. The hair follicles are not destroyed and so hair can re-grow if the inflammation of the follicles subsides. People who experience just a few patches of hair loss, often have a spontaneous full recovery without any form of treatment.

Other than hair loss

Alopecia areata can also affect the fingernails and toenails, and sometimes these changes can be the first sign that alopecia areata is developing. Nails may show-

- Pinpoint dents
- White spots and lines
- Roughness
- Loss of shine
- Thinning and splitting

Case Study

A Case of Alopecia

Km Aanchal, F 12 years, suddenly lost her hair.

Mentals

Tremendously timid, shy, fear of darkness.

Physical built

Has lean thin and dark complexion. Hot patient.

Present Complaints

No complaint except her baldness.

Past History

Has had tonsillitis in childhood.

Additional Complaints

Pain in throat. Cough, coryza.

Generals

Thirst – Decreased

Appetite – Low

Stool – Normal

Desire – Sweet, salt

Aversion – Non veg

Sleep - Normal

Case Analysis

- GENERALS - FOOD and DRINKS - sweets - desire
- GENERALS - LEAN people
- GENERALS - FOOD and DRINKS - salt - desire
- MIND - TIMIDITY

- MIND - FEAR - dark; of
- HEAD - HAIR - falling - spots, in
- HEAD - HAIR - baldness - patches
- STOMACH - THIRSTLESS

Repertorization

	phos.	tub.	calc.	lyc.	nat.m.	ars.	graph.	sepp.	calc-p.	arg.n.	chin.	silph.	tryp.	caust.	kali-s.	merc.	kali-p.	poli.	carb-v.	plb.	sil.	arg.met.	lac-c.	nat.	
1																									
8																									
18																									
1																									
2																									
3																									
4																									
5																									
6																									
7																									
8																									
9																									
10																									
11																									
12																									
13																									
14																									
15																									
16																									
17																									
18																									
19																									
20																									
21																									
22																									
23																									
24																									

Phosphorus, Tuberculinum

Potential Differential Field


History of tonsils confirms TUBERCULINUM and current picture PHOSPHORUS.

Rx.

01-04-2013.

Tuberculinum 1 M a single dose.

Phosphorus 30 tds.



02-07-2013

Marked improvement. Hair developed.

Phosphorus 30 tds.



28-04-2014


More improvement.

Sac lac.

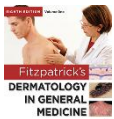


Complete cure. Hair fully developed.


Bibliography




Skin > Clinical Findings CURRENT Diagnosis & Treatment: Pediatrics, 22e




Chapter 107. Neonatal, Pediatric, and Adolescent Dermatology > Alopecia Areata Fitzpatrick's Dermatology in General Medicine, 8e



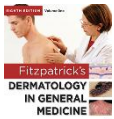
Chapter 187. Alopecia Areata The Color Atlas of Family Medicine, 2e



Chapter 88. Hair Growth Disorders > Alopecia Areata Fitzpatrick's Dermatology in General Medicine, 8e




Chapter 88. Hair Growth Disorders > Etiology and Pathogenesis Fitzpatrick's Dermatology in General Medicine, 8e




Chapter 88. Hair Growth Disorders > Treatment Fitzpatrick's Dermatology in General Medicine, 8e



Encyclopedia Homoeopathica




Section 31. Disorders of Hair Follicles and Related Disorders > Alopecia Areata Fitzpatrick's Color Atlas and Synopsis of Clinical Dermatology, 7e



Section 32. Disorders of the Nail Apparatus > Alopecia Areata (AA) Fitzpatrick's Color Atlas and Synopsis of Clinical Dermatology, 7e



Skin > 1. Alopecia Areata CURRENT Diagnosis & Treatment: Pediatrics, 22e



The Skin and Nails > Alopecia areata DeGowin's Diagnostic Examination, 10e



Radar 10