



# CENTRAL SEROUS CHORIORETINOPATHY (CSR) AND HOMOEOPATHY

DR. RAJNEESH KUMAR SHARMA MD (HOMOEOPATHY)  
DR. SWATI VISHNOI BHMS

# CENTRAL SEROUS CHORIORETINOPATHY (CSR) AND HOMOEOPATHY

© Dr. Rajneesh Kumar Sharma M.D. (Homoeopathy)  
Dr. Swati Vishnoi B.H.M.S.  
Homoeo Cure & Research Institute  
NH 74, Moradabad Road, Kashipur (Uttaranchal) INDIA  
Pin- 244713 Ph. 05947- 260327, 9897618594  
E. mail- [drrajneeshhom@hotmail.com](mailto:drrajneeshhom@hotmail.com)  
[www.treatmenthomoeopathy.com](http://www.treatmenthomoeopathy.com)  
[www.homeopathictreatment.org.in](http://www.homeopathictreatment.org.in)  
[www.homeopathyworldcommunity.com](http://www.homeopathyworldcommunity.com)



## Contents

Synonyms .....	2
Definition.....	2
History of the disease .....	2
Incidence .....	2
Race .....	2
Age.....	3
Sex .....	3
Causes .....	3
Risk Factors .....	3
Pathogenesis .....	4
RPE dysfunction theory.....	4
Choroid dysfunction theory .....	4
Symptoms.....	5
Stages of CSR.....	6
Acute.....	6
Sub-acute .....	6
Chronic.....	6
Inactive .....	6
Late complications .....	6
Diagnosis.....	6
Distance & Near Visual Acuity testing.....	6
Procedure of distance visual acuity testing .....	6
Procedure of near visual acuity testing .....	6
Retinoscopy.....	6
Procedure of Retinoscopy.....	7
Amsler Grid .....	7
Procedures of Amsler Grid testing .....	7
Photostress Recovery testing.....	7
Clinical procedure for photostress recovery testing .....	7
Ophthalmoscopy .....	7
Special Investigations .....	8

Fundus Fluorescein Angiography (FFA) .....	8
Indo-Cyanine-Green Angiography (ICGA).....	8
Optical Coherence Tomography (OCT).....	8
Prognosis.....	8
Treatment .....	8
Observation.....	8
Photodynamic therapy (PDT).....	8
Photodynamic Therapy (Visudyne) .....	8
Laser photocoagulation.....	8
Laser Treatment .....	8
Prevention of CSR .....	9
Homoeopathic treatment .....	9
Naphthalinum .....	9
Gelsemium sempervirens.....	10
Digitalis purpurea.....	10
Jaborandi .....	10
Ruta graveolens .....	10
Aurum metallicum.....	10
Bibliography .....	11

## Synonyms

Central Serous Chorio-retinopathy, Central Serous retinopathy, CSC, CSCR

## Definition

It is characterized by a usually self-limiting, spontaneous serous detachment of neurosensory retina in the macular region, with or without retinal pigment epithelium detachment with retinal elevation leading to hypermetropia. (Psora/ Syphilis/ Sycosis)

## History of the disease

- 👁 1866 - Von Graefe-first described the disease as recurrent serous retinitis.
- 👁 1916 - Fuch worked appreciably on this disease.
- 👁 1927 - Horniker – named disease as “Central Angiospastic Retinitis”.
- 👁 1930 - Walsh & Sloane - “Idiopathic flat detachment of macula”.
- 👁 1930 - Gifford and Marquardt - Theory on Angioneurotic diathesis.
- 👁 1950 - Bennett & Maumenee - spectrum of macular disciform degeneration.
- 👁 1953 - Klien - Theory on autonomic nervous system dysfunction.
- 👁 1955 - Bennett - “Central Serous Retinopathy”.
- 👁 1960 - Maumenee and Gass – Fluorescein Angiography appearance of CSC.
- 👁 1967 - Gass - “Central Serous Choroidopathy”.

## Incidence

### Race

It commonly affects Caucasians, Hispanics and Asians and rarely the African-Americans.

## Age

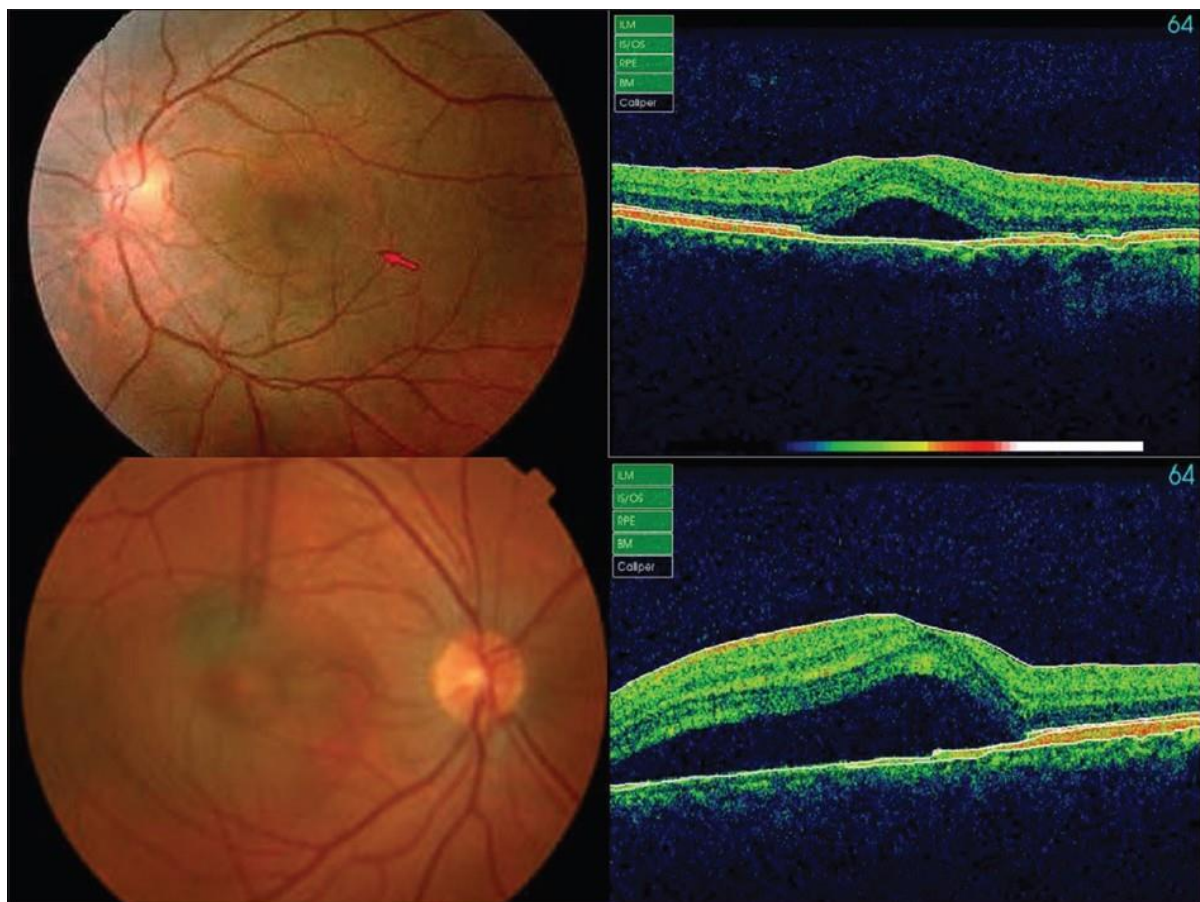
It typically affects males between 20 to 50 years of age especially personality type A, who are rigidly organized, high status, conscious, sensitive, truthful, impatient and always trying to help others. (Psora/ Pseudopsora)

## Sex

Male to female ratio is 8:1 to 10:1.

## Causes

The actual cause of central serous retinopathy is not well understood. Stress and sleeplessness may be the main causes (Psora). Exposure to any steroid medication (nasal spray, cortisone cream, joint injection, etc.) have also been associated. (Causa occasionalis)



## Risk Factors

- 👁 Refractive error changes (increases hyperopia due to retinal elevation) (Psora)
- 👁 Pregnancy (Causa occasionalis)
- 👁 Local or systemic steroids (Causa occasionalis)
- 👁 Hypertension (Psora/ Sycosis)
- 👁 Emotional stress (Psora/ Causa occasionalis)
- 👁 Persons who are type A personality- Sensitive, truthful, impatient, always trying to help others (Psora/ Pseudopsora)
- 👁 Allergic respiratory disease (Psora/ Pseudopsora)

## Pathogenesis

The source of sub-retinal fluid is the choroid, where a focal defect in the retinal pigment epithelium (RPE) allows serous fluid to accumulate under the retina resulting in a localized separation of the retina from the retinal pigment epithelium (Psora/ Syphilis/ Sycosis).

There are two theories-

### RPE dysfunction theory


- ☞ The intact retinal pigment epithelium creates a barrier between the neurosensory retina and choroid. (Psora)
- ☞ In areas of chorioretinal scar tissue, occurring after inflammation or photocoagulation, the pigment epithelial diffusion barrier is permanently destroyed. (Sycosis/ Syphilis)
- ☞ Choroidal capillaries exert suction on the surrounding fluid. (Psora)
- ☞ The intact RPE absorbs fluid in a retinochoroidal direction. (Psora)
- ☞ Under certain conditions, the function of the RPE is reversed and it secretes in a chorioretinal direction. (Psora)

### Choroid dysfunction theory

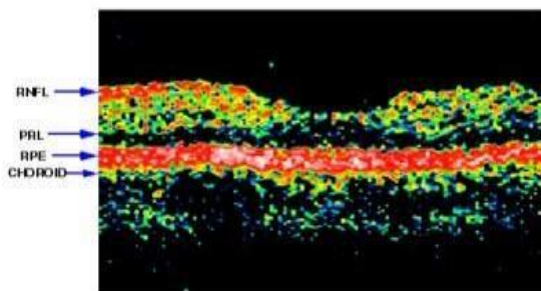
- ☞ Psychogeny, pregnancy, transplantation, personality type A, raised cortisol levels causes a disturbance in the auto regulation of choriocapillaries blood flow. (Psora/ Causa occasionalis)
- ☞ Circulatory disturbance in the micro circulation of the choriocapillaries leads to increase fluid leakage in the sub-RPE space. (Psora/ Sycosis)
- ☞ In the beginning, the RPE cells are able to maintain their integrity and function and pump in a retina-choroid direction and keep the sub-RPE space dry.
- ☞ The prolonged excessive stress on the RPE cells ultimately causes a generalized damage to the cells themselves and also loss of function. (Syphilis/ Causa occasionalis)
- ☞ The loss of function of the contiguous RPE cells allows the fluid to accumulate in the sub-retinal spaces cause a serous-retinal detachment or neurosensory detachment. (Psora/ Sycosis/ Syphilis)

CSR presents with fluid spontaneously leaking into the sub-retinal space from the choroid (Psora). The retina lies on top of the choroid, a large layer of tissue packed with blood vessels and capillaries. The choroid is functionally separated from the retina by a membrane called Bruch's Membrane and a single layer of cells called the retinal pigment epithelium (RPE). This layer works like a barrier aiding nutrients to flow into the retina from the underlying vessels. It also allows retinal wastes to leave for removal by the choroidal vessels. The RPE layer prevents free flow of fluid. In CSR, this seal breaks down, and fluid leaks into the sub-retinal space (Psora/ Syphilis/ Causa occasionalis). This can occur in both eyes but usually presents in one at a time. After a few months, the condition may resolve on its own. There is up to a 50% chance of having a recurrent episode in either eye. Recurrent episodes in the same location or a persistent leak in a single location can cause permanent damage to vision (Syphilis). The rare but serious complication happens if scar tissue and blood vessels from the choroid occupy the space under the retina (Sycosis). This tissue, if not stopped, can continue to grow and destroy the central retina or macula (Psora/ Syphilis/ Sycosis). This occurs more commonly in older patients with recurrences.

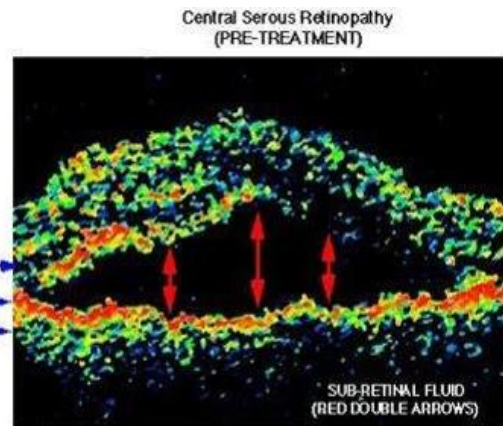




NORMAL FOVEA

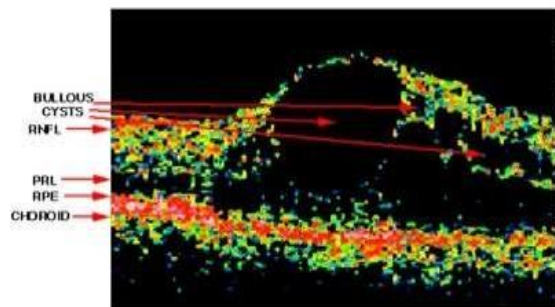


NYEEL, Ocular Imaging Center

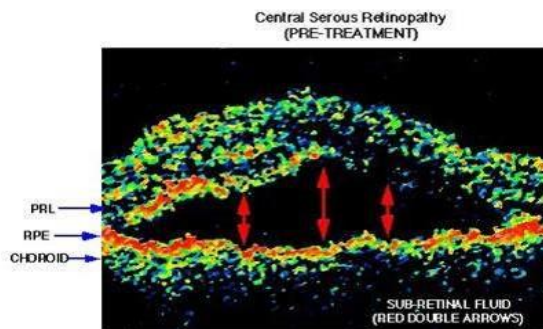


Central Serous Retinopathy (PRE-TREATMENT)

CYSTOID MACULAR EDEMA

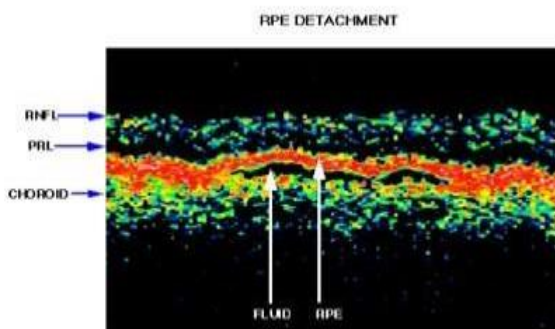


NYEEL, Ocular Imaging Center



Central Serous Retinopathy (PRE-TREATMENT)

NYEEL, Ocular Imaging Center



RPE DETACHMENT

NYEEL, Ocular Imaging Center

## Symptoms

Symptoms are usually unilateral-

- 👁 Blurring, distortion, minification of objects and a dark patch at fixation (Psora/ Syphilis)
- 👁 Blurred vision (Psora)
- 👁 Hypermetropia- Difficulty in near work, like reading a newspaper (Psora/ Sycosis)
- 👁 A relative central scotoma (Psora/ Syphilis)
- 👁 Slow recovery from bright light (Psora)
- 👁 Metamorphopsia (image distortion) (Psora)
- 👁 Macropsia (object looks larger than they appear) (Psora)
- 👁 Micropsia (object looks smaller than they appear) (Psora)
- 👁 Photophobia (Psora)
- 👁 Hyperopic shift in refraction (due to elevation of sensory retina) (Psora/ Sycosis)
- 👁 Reduced contrast sensitivity (Psora)
- 👁 Impaired depth perception (Psora)

## Stages of CSR

### Acute

Patients are asymptomatic as there is no break in diffusion barrier.

### Sub-acute

As the acute stage of the disease progresses some patients develop focal breaks in the tight junction of the RPE cells. (Psora/ Syphosis)

### Chronic

The leaking through the break of tight junction becomes chronic; a field defect will develop which often involves fovea resulting marked decrease in visual acuity. (Psora/ Syphilis)

### Inactive

Most of the patients in this stage have no history of previous eye problem. They had asymptomatic stage and spontaneously improve.

### Late complications

Sub-retinal neo-vascularization develops which is seen 5 to 10 years after the first diagnosis of CSR. Sub-retinal neo-vascularization are of two types on fluorescein angiography-

- 👁 Typical (one or two leaking areas are seen on FFA (Fundus fluorescein angiography)).
- 👁 Atypical (Multiple leaks are seen on FFA).

## Diagnosis

### Distance & Near Visual Acuity testing

Visual acuity can measure 6/60 to 6/6. 6/6 is 100% visual acuity.

#### Procedure of distance visual acuity testing

- 👁 Distance visual acuity chart is kept at 6 meter.
- 👁 Left eye is covered.
- 👁 Patient is asked to read the chart from top to bottom. Up to which smallest line patient can read that is his visual acuity in that eye. Normal distance visual acuity is 6/6 or 20/20.
- 👁 The test for other eye is repeated.

#### Procedure of near visual acuity testing

- 👁 The near vision chart is hold at 33 cm.
- 👁 Left eye is covered.
- 👁 Then patient is asked to read which smallest line he can read that is the near visual acuity in his that eye. Normal near visual acuity is N6.
- 👁 The test for other eye is repeated.

In CSR involved eye distance visual acuity reduces 6/18 to 6/9 and often correctable to 6/6 with the addition of a plus or convex lens. Some disparity is always seen between the subjective and objective refraction of the eye. But near vision may not improve to N6, if improves to N6 with strongest plus lens then also patient is not become satisfy, if he compares the vision with other eye. But this acuity frequently changes with time.

### Retinoscopy

It is an objective method to determine the refractive error of the eye.

## Procedure of Retinoscopy

- ☞ This test is performed in a dark room.
- ☞ Patient should fixate on a distant non accommodative target that is 6/60 or 20/200 letter.
- ☞ Observer performs retinoscopy at a fixed distance that is 1 meter. In CSR involved eye retinoscopic examination reveals hypermetropia up to +1 D due to swelling in the central retina as CSR shortens the visual axis.

## Amsler Grid

### Procedures of Amsler Grid testing

- ☞ The Amsler chart is hold at 33 cm away from the eye with patient wearing reading glasses.
- ☞ The left eye is covered to perform the test for the right eye.
- ☞ Patient is asked to look at the central dot of the chart at all the time.
- ☞ Patient is instructed to draw on the chart if he notices any missing and distorted areas.
- ☞ In CSR cases central vision become blurred due to fluid accumulation in the Macula. So in Amsler Grid testing we get central scotoma (non-seeing area) along with distorted line or wavy line.
- ☞ The procedure is repeated for left eye.

## Photostress Recovery testing

Photostress recovery testing is also referred to as dazzling time and re-adaptation time. It is the period required for the macula to return to a normal level of function after being exposed to an intense light source.

### Clinical procedure for photostress recovery testing

- ☞ Firstly, the best corrected visual acuity for each eye is determined.
- ☞ Left eye of the patient is occluded.
- ☞ Patient is asked to fixate with right eye on the centre of the light source (Ophthalmoscope or Torch light) while it is positioned approximately 2.5 cm (Some practitioner maintain 10 cm) from the eye.
- ☞ The duration of viewing is 10 to 30 seconds.
- ☞ Remove the light source and immediately patient is asked to read the line above best corrected visual acuity. If Patients pre-test visual acuity is 6/9 then patient is asked to read 6/12 line.
- ☞ The time (in seconds) required for the patient to read at least one-half of the line is measured. If the line has five letters then patient should read at least 3 letters. The time takes for the normal eye is 30 seconds or less. But in CSR patient the time takes more than the normal.
- ☞ The procedure for left eye is repeated and the result is compared. The difference between normal eyes average 5 to 6 seconds. But in CSR patient the difference increases.

## Ophthalmoscopy

The following points are noteworthy-

- ☞ Elevation of Macular area.
- ☞ A circular ring-reflex on the retina.
- ☞ A round or ovoid blister like sensory retinal detachment of various sizes.
- ☞ Foveal reflex absent or distorted.
- ☞ After a few weeks of onset of the disease, tiny irregular white or yellow precipitates become deposited on the retina.
- ☞ Atrophic RPE changes as evidence of previous episodes.
- ☞ In chronic cases, a fine brown and white pigment epithelial scar is seen.
- ☞ Extra Macular RPE tracts.



## Special Investigations

### Fundus Fluorescein Angiography (FFA)

Fluorescein dye is injected intravenously and simultaneously serial photos of the retina with a fundus camera are taken. In CSR, the defective area is so small (in the level of RPE), only a tiny leakage point is visible during the earliest phase of FFA. Subsequently, there is rapid increase in fluorescein stained liquid in the sub-retinal blister during the following stages of angiography.

### Indo-Cyanine-Green Angiography (ICGA)

After the ICG is injected intravenously, the dye is seen within the choroidal vessels. Within a few minutes, hyper-fluorescent patches appear within the choroid.

### Optical Coherence Tomography (OCT)

OCT is an excellent non-invasive diagnostic test which clearly demonstrates the serous detachment, especially when the serous detachment is shallow.

## Prognosis

- 👁 About 80% of patients with CSR, Spontaneous resolution of sub-retinal fluid and visual acuity improves to 6/9 or better within 4 months.
- 👁 The remaining 20% last longer than 6 months, but resolve within 12 months.
- 👁 Even if visual acuity returns to normal, some degree of subjective visual impairment such as micropsia can persist.
- 👁 Recurrences of the disease may occur 30 to 50% of patients.
- 👁 In chronic CSR, progressive RPE changes associated with a permanent impairment of visual function.

## Treatment

### Observation

Observation is often used in the first month or two to see whether central serous retinopathy might clear on its own. Routine exercise and 8 hours per day sleep seems to help.

### Photodynamic therapy (PDT)

It is still experimental.

### Photodynamic Therapy (Visudyne)

This treatment seems to be quite effective in some cases of central serous retinopathy and does not leave the same scarring that laser can.

### Laser photocoagulation

Laser photocoagulation can be done at the point where leakage seen on fluorescein angiography.

### Laser Treatment

Laser treatment for central serous retinopathy has been one of the mainstays of active therapy. The idea is that with a slight amount of thermal laser stimulation, the RPE cells may scar, and the fluid leak stop.

## Prevention of CSR

- 👁️ Avoidance of unnecessary stress
- 👁️ Meditation
- 👁️ Yoga
- 👁️ Alcohol restriction
- 👁️ Corticosteroid restriction
- 👁️ Avoidance of excessive exercise
- 👁️ Avoidance of crash diets
- 👁️ Good sleep
- 👁️ Improvement of lifestyle
- 👁️ Avoidance of caffeine containing drinks- caffeine stimulates the pituitary gland and increases the cortisol level.

## Homoeopathic treatment

### Naphthalinum

(naphtin.) (Boericke)

(A chemical compound from Coal-tar; Tar Camphor)

Coryza, hay-fever, phthisis pulmonalis, also gonorrhoea have been influenced favorably by this drug. Pyelonephritis. Irritation of the periphery of the urinary apparatus. Whooping-cough.

Head.-Lying as if stupefied by a narcotic. Restless. Face pale yellowish hue.

Eyes.-Marked affinity for the eye. It produces detachment of the retina; papillo-retinal infiltration; deposits in patches upon the retina; amblyopia and consecutive amaurosis; sparkling synchysis; soft cataract.. Exudation in the retina, choroid and ciliary body. Cataract. Opacity of the cornea.

Urine.-Irresistible desire. Meatus red, swollen, and oedema of prepuce. Black urine. Cutting pain down penis. Pain in bladder. Terribly offensive odor of decomposing ammoniacal urine.

Respiratory.-Sneezing; eyes inflamed; painful; head hot. Hay-fever. Spasmodic asthma; better in open air. Soreness in chest and stomach; must loosen clothing. Dyspnoea and sighing inspiration. Emphysema in the aged with asthma. Whooping-cough, long and continued paroxysms of coughing, unable to get a respiration. Acute laryngo-tracheitis. Bronchitis when the spasmodic element is associated with tenacious

expectoration and oppression. (Cartier).

Skin.-Dermatitis; itching infiltration. Eruptions at corners of mouth and pigmentation around nails.

Non-Homoeopathic Uses-For worms, and especially pin- worms, one-gramme dose. Externally in skin diseases, five percent. ointment.

Relationship.-Compare : Dros.; Corall.; Coccus.Terpin. hydrat. (Whooping-cough, hay asthma and bronchial affections. 1-2 grain doses).

Dose.-Third trituration.

Other Homoeopathic medicines of repute in Retinal detachment:

## Gelsemium sempervirens

FARRINGTON – Eyes, affections of – Paralysis of the eye-lids and ocular muscles; diplopia, double vision, ptosis; eye-balls oscillating laterally when using them; cannot tell which side of the street he is on; complete blindness coming on suddenly.

Glaucoma; intra-ocular inflammations with serous exudations, intense pain over the right eye, double vision and vertigo.

Serous Iritis, Choroiditis, with gradual impairment of vision and heavy lids : detachment of the retina; strabismus from weakness of the muscles or following Diphtheria.

CLARKE – Clinical – Retina, detachment of. Rheumatism. Sexual excess

HERING – Therap., p.86; Detachment of retina, Boynton, see Norton's Opth.

Ptosis, Gallinger, Raue's Rec., 1870, p.100; Infra-orbital neuralgia, Cushing, Raue's Rec., 1874, p.260; Deafness and loss of speech, Hawke, Raue's Rec., 1870, p.119; Prosopalgia, Hendricks, Allg. – Detachment of retina dependent upon an injury, with diffuse haziness of vitreous and serous inflammation of choroid and retina.

Sight and Eyes- Right vision 20 with difficulty; left vision, counted fingers at 20 feet; serous inflammation of iris and choroid, deposits on membrane of Descemet, aqueous and vitreous hazy in both eyes, left pupil dilated and sluggish; sensation of pressure over both eyes and headache in temples.

Detachment of retina from myopia; severe attacks of neuralgia.

## Digitalis purpurea

BOERICKE – Eyes- Blueness of eyelids, Dark bodies, like flies, before eyes. Change in acuteness of perception of shades of green. Objects, appear green and yellow. Mydriasis; lid margins red, swollen, agglutinated in morning. Detachment of retina. Dim vision, irregular pupils, diplopia.

HERING – Sight and Eyes- || Detachment of retina; wavering, everything appears green or yellow. Superficial inflammation of eye and its appendages; blepharoadenitis.

Therap., p.86; Irido-choroiditis (2 cases), see Norton's Opth.

## Jaborandi

CLARKE – Characteristics – Sandesberg (B. J. H., xl. 201) noticed that the internal use of Jaborandi and Pilocarpin in cases of detachment of retina and choroiditis seemed to occasion opacity of the crystalline lens. He treated a horse for irido-choroiditis and large opacities of the vitreous with infusion of Jab. leaves and injections of Pilo..

## Ruta graveolens

CLARKE – Symptoms. – Eye – Tendency to stare. Contraction of pupil (Aitken). (Detachment of retina.)

Asthenopia. Astigmatism (?). On using eyes, sensation of violent heat in them.

## Aurum metallicum

HERING – Sight and Eyes – Central portion of retinal vessels strongly pulsating. Chorio-retinitis chronica, with an accumulation of fluid beneath retina, which settled to lower portion of left eye,

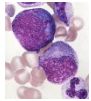
causing a large detachment of retina. Hemiopia. Large black subchoroidal tumor behind lens in fundus, growing from inner side. Pupils not very active; generally contracted.

There is marked improvement in all the patients with retinal detachment as well as macular holes and degeneration. I can now say homoeopathy is as good in this disorder as surgery does up to 90%.

## Bibliography



Encyclopedia Homoeopathica




A. External Manifestations > 106. Retinopathy of Acute Leukemia Lichtman's Atlas of Hematology ... XI.A.106 Retinopathy of acute leukemia. Fifteen-year-old girl with first relapse of poor...




Chapter 10. Retina > Central Serous Chorioretinopathy Vaughan & Asbury's General Ophthalmology, 18e .... Figure 10-24. Late fluorescein angiogram showing accumulation of dye in the serous detachment of CSR...



Chapter 13. Disturbances of Vision > Other Diseases of the Retina Adams & Victor's Principles of Neurology, 10e ...- Kornzweig disease, Batten-Mayou disease, and others (see Chap. 37 ). Serous retinopathy , a cause...



Chapter 13. Sensory Impairment > Diabetic Retinopathy Essentials of Clinical Geriatrics, 7e ... of microvascular disease, including retinopathy in type 2 diabetes (see Chapter 12 ). Panretinal and focal retinal...



Chapter 14. The History, Physical Examination, and Cardiac Auscultation > Vascular Occlusion Hurst's The Heart, 13e ... in the drained area. As collateral drainage, the edema and hemorrhagic retinopathy subside, leaving white-walled...



Chapter 15. Ocular Disorders Associated with Systemic Diseases > Diabetic Retinopathy ( Figures 15–18 , 15–19 , 15–20 and 15–21 ) Vaughan & Asbury's General Ophthalmology, 18e ... Figure 15-18. Diabetic retinopathy stage I. Trypsin-digested whole mount showing...



Chapter 23. Lasers in Ophthalmology > Central Retinal Vein Occlusion Vaughan & Asbury's General Ophthalmology, 18e ... retinopathy—preferably with the krypton red or diode infrared laser to avoid preretinal fibrosis caused...




Chapter 43. Assessment and Rehabilitation of Older Adults with Low Vision > Diabetic Retinopathy Hazzard's Geriatric Medicine and Gerontology, 6e ... The progression of diabetic retinopathy includes macular edema that may cause blurred vision...




Chapter 67. Ocular Inflammatory Diseases for Rheumatologists > Ophthalmic Disease Due to Medications Used to Treat Rheumatic Disease CURRENT Diagnosis & Treatment: Rheumatology, 3e ... subcapsular cataracts, central serous retinopathy, or glaucoma from glucocorticoids; iritis or scleritis from...



Chapter 9. Glucocorticoids and Adrenal Androgens > Miscellaneous Effects Greenspan's Basic & Clinical Endocrinology, 9e .... Central serous chorioretinopathy, an accumulation of subretinal detachment, may also complicate endogenous...



Diabetes Mellitus > Diabetic Retinopathy Williams Obstetrics, 24e ... retinopathy, or macular edema. A fourth of these women developed progression of retinopathy in at least one...



Disorders of the Eye > Central Serous Chorioretinopathy Harrison's Principles of Internal Medicine ... This primarily affects males between the ages of 20 and 50 years. Leakage of serous fluid from...



Eye > Clinical Findings CURRENT Diagnosis & Treatment: Pediatrics, 22e ..., episcleritis, and sterile corneal infiltrates. Posterior segment findings may include central serous...



Managing Vision Impairment in Older Adults > Complications Current Diagnosis & Treatment: Geriatrics ... Vision loss caused by diabetic retinopathy is caused mainly by macular edema and proliferative...



Neurologic & Muscular Disorders > CENTRAL NERVOUS SYSTEM DEGENERATIVE DISORDERS OF INFANCY & CHILDHOOD CURRENT Diagnosis & Treatment: Pediatrics, 22e ... enteropathy Strabismus Retinopathy Dysmorphic facies Prominent fat pads Inverted nipples...



Neurologic Paraneoplastic Syndromes > PNDs of the Central Nervous System and Dorsal Root Ganglia Harrison's Manual of Medicine, 18e ... retinopathies involve cone and rod dysfunction characterized by photosensitivity, progressive loss of vision...




Paraneoplastic Neurologic Syndromes and Autoimmune Encephalitis > PARANEOPLASTIC VISUAL SYNDROMES Harrison's Principles of Internal Medicine .... The term cancer-associated retinopathy is used to describe paraneoplastic cone and rod dysfunction...




The Eye & Ocular Adnexa > 2. Exudative ("Wet") Macular Degeneration CURRENT Diagnosis & Treatment: Surgery, 14e ... neovascular membrane that leaks fluid and blood. This causes a serous detachment of the central fovea that can...



The Eye & Ocular Adnexa > Treatment CURRENT Diagnosis & Treatment: Surgery, 14e ... of diabetic retinopathy. Recent epidemiologic studies show that many diabetics fail to have recommended yearly...



The Head and Neck > Diabetic retinopathy DeGowin's Diagnostic Examination, 10e ... Plate 24 Diabetic Retinopathy: Non-Proliferative Retinopathy. This right eye shows...



Use of the Hand-Held Ophthalmoscope > RETINAL DETACHMENT Harrison's Principles of Internal Medicine ... main types: (1) serous/exudative, (2) tractional, and (3) rhegmatogenous retinal detachment...



Radar 10