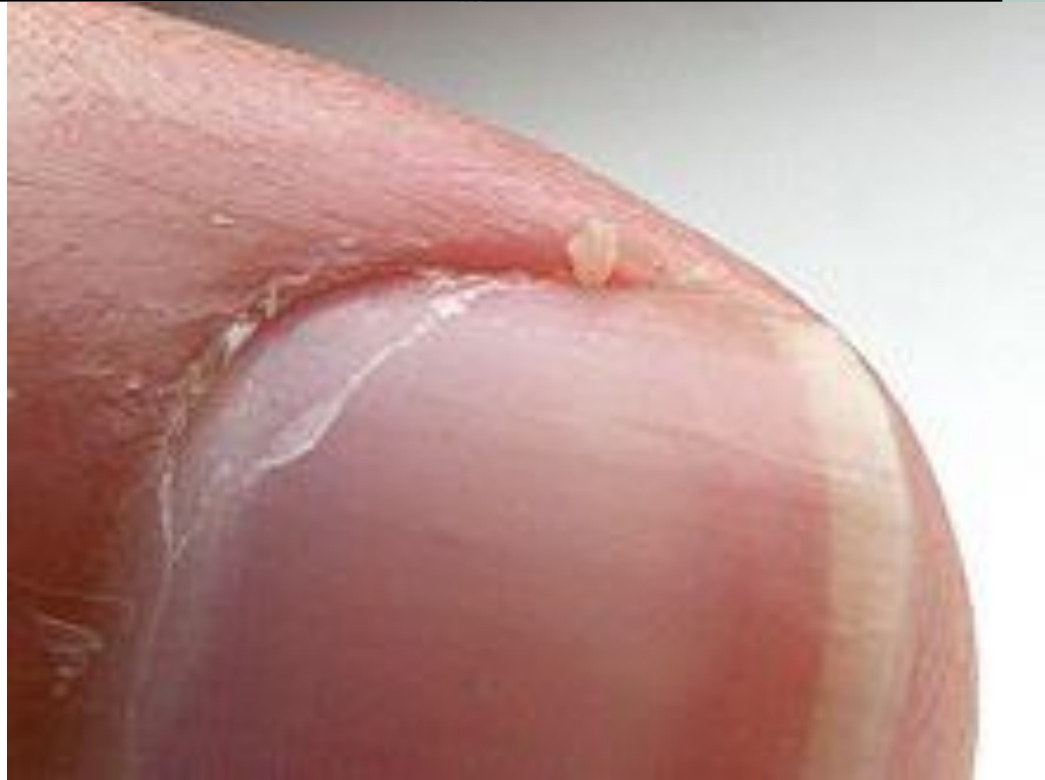

Hangnails and Homoeopathy



Dr. Rajneesh Kumar Sharma MD (Homoeopathy)

Dr. Swati Vishnoi BHMS

Hangnails and Homoeopathy

© Dr. Rajneesh Kumar Sharma M.D. (Homoeopathy)
Dr. Swati Vishnoi B.H.M.S.
Homoeo Cure & Research Institute
NH 74, Moradabad Road, Kashipur (Uttaranchal) INDIA
Pin- 244713 Ph. 05947- 260327, 9897618594
E. mail- drrajneeshom@hotmail.com
www.treatmenthomeopathy.com
www.homeopathyworldcommunity.com



Contents

Definition	1
Causes.....	2
Pathophysiology	2
Nail anatomy	2
Nail plate (actual nail).....	2
Lateral nail folds	2
Proximal nail fold (posterior nail fold).....	2
Cuticle (eponychium)	2
Nail matrix (nail root)	2
Lunula (half-moon).....	2
Nail bed (ventral matrix, sterile matrix)	3
Onychocorneal band	3
Hyponychium (contains the solenhorn).....	3
Distal groove (limiting furrow)	3
Functions of the nails	3
Symptoms.....	4
Diagnosis	4
Homoeopathic Treatment.....	5
Bibliography.....	5

Definition

A hangnail is the long or triangular strip of the skin that separates from the side of the cuticle in the form of tiny spicule that tends to be painful and annoying.

Causes

- Winter months because of dryness
- Exposed to excessive moisture (working in water for a long time)
- Harsh chemicals like the ones present in detergents
- Nail biting (due to damage to the cuticles)
- Nail clipping can lead to hangnails if the nail is trimmed along the lateral aspect of the nail
- Bad manicures when the nails are cut along the edge of the cuticles. At times, manicurists push back the cuticles too aggressively, thereby leading to hangnails.
- Protein deficiency
- Increased folic acid need
- Zinc deficiency
- Vitamin C deficiency

Pathophysiology

To understand hangnail formation, one must be acquainted with nail anatomy and their functions.

Nail anatomy

Nail plate (actual nail)

Durable keratinized structure on the dorsal distal segment of the digit that continues growing throughout life.

Lateral nail folds

The cutaneous folded structures providing the lateral borders to the nail.

Proximal nail fold (posterior nail fold)

Cutaneous folded structure providing the visible proximal border of the nail, continuous with the cuticle.

Cuticle (eponychium)

The layer of epidermis extending from the proximal nail fold and adhering to the dorsal aspect of the nail plate.

Nail matrix (nail root)

Traditionally, this can be divided into three parts-

1. The dorsal matrix which is synonymous with the ventral aspect of the proximal nail fold
2. The intermediate matrix (germinative matrix), which is the epithelial structure starting at the point at which the dorsal matrix folds back on itself to underlie the proximal nail
3. The ventral matrix, which is synonymous with the nail bed and starts at the border of the lunula, where the intermediate matrix stops, and is limited distally by the hyponychium.

Lunula (half-moon)

The convex margin of the intermediate matrix seen through the nail. It is paler than the adjacent nail bed. It is most commonly visible on the thumbs and great toes. It may be concealed by the proximal nail fold.

Nail bed (ventral matrix, sterile matrix)

The vascular bed upon which the nail rests, extending from the lunula to the hyponychium. This is the major territory seen through the nail plate.

Onychocorneal band

The distal margin of the nail bed, which has a contrasting hue in comparison with the rest of the nail bed. Normally, this is a transverse band of 1 to 1.5 mm of a deeper pink or brown, followed by a relatively avascular pale band.

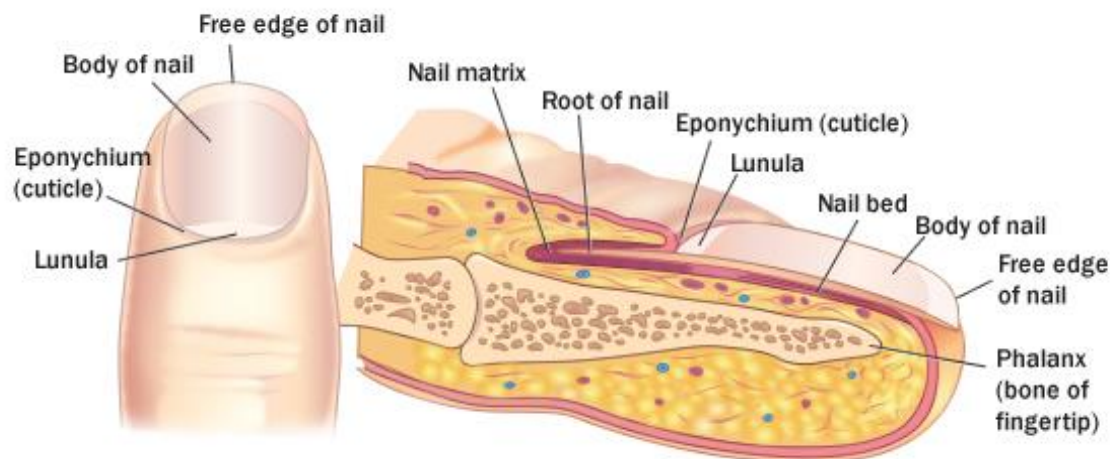
Its color, or presence, may vary with disease or with compression, which influences the vascular supply.

Hyponychium (contains the solenhorn)

The cutaneous margin underlying free nail, bordered distally by the distal groove.

Distal groove (limiting furrow)

A cutaneous ridge demarcating the border between subungual structures and the finger pulp.



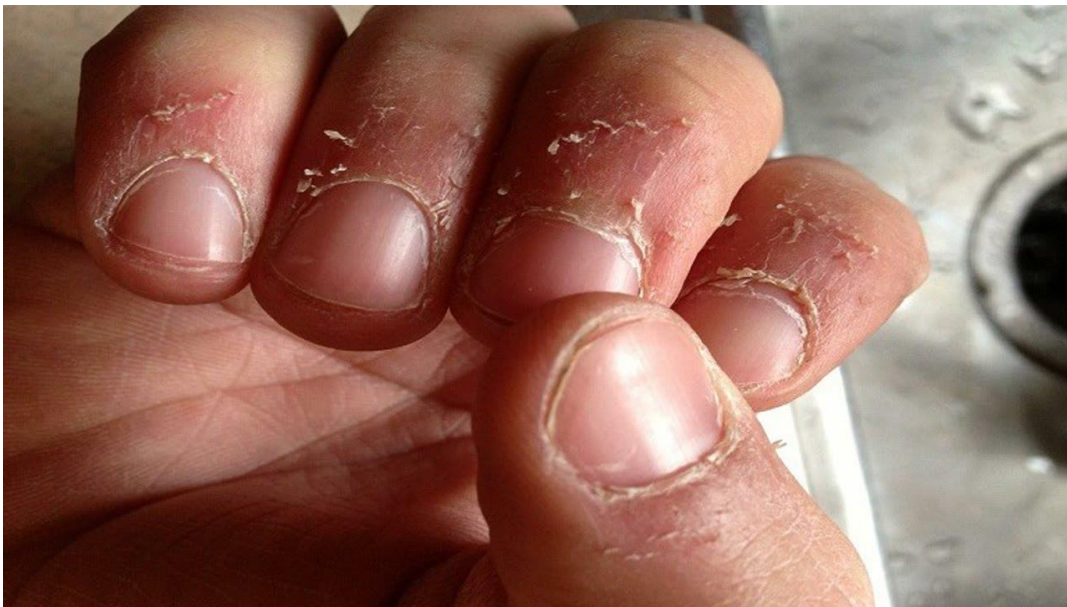Functions of the nails

- The biological function of the human fingernail is to be a tool for grasping and manipulating objects.
- The cutting property of the sharp end of the nail allows peeling of fruits and removal of undesired parts of foodstuff as well as serving defensively.
- The nail plate intensifies sensory discrimination in the handling of minute objects and to a certain extent protects the fingertips from traumatic impacts.
- From a sociological point of view, nails can serve as signals of social class.
- Nail color and shape is often indicative of systemic diseases.

The main cause of hangnails relates to the dryness of the cuticles. When this area becomes dry, the cuticles depart partially from the nail region and become troublesome. The nails being most distal structures in body, the metabolized proteins and other essential substances reach there in last, causing relative deprivation. Hence the nail troubles are healed slowly.

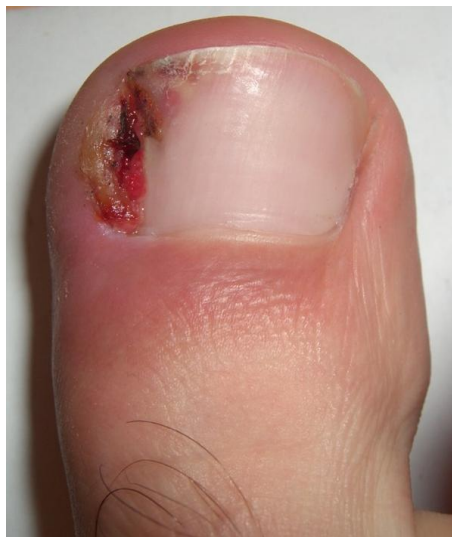Symptoms

- Often, hangnails may be asymptomatic.
- When the loose skin catches on clothing or other items, the tear can be pulled quite harshly. This can further tear the skin and make the condition worse resulting in pain.
- Hangnail may act as the site for infections. Infected hangnail looks very red or is filled with pus and is severely painful.
- The condition may be very painful or associated with a fever and a lot of swelling. Without treatment, the infection could spread underneath the nail and damage it.
- Hangnails are cosmetically annoying.



Diagnosis

The only way to diagnose hangnails is a keen clinical examination. Other systemic diseases like diabetes or disorders causing dry skin must be ruled out e.g. Sjogren syndrome, hypothyroidism, xeroderma, psoriasis, hyperkeratosis, ichthyosis, dyshidrotic eczema etc.



Homoeopathic Treatment

Hangnails- common remedies- [bros-gau](#). [Calc. carc.](#) [kali-chl.](#) [lyc.](#) [Merc.](#) [NAT-M.](#) [nat-s.](#) [plut-n.](#) [positr.](#) [pyncnop-sa.](#) [Rhus-t.](#) [sabad.](#) [sanic.](#) [sel. sep.](#) [Sil.](#) [Stann.](#) [SULPH.](#) [Thuji.](#) [upa.](#) [wye.](#)

EXTREMITIES - FELON - hangnails, from [lyc.](#) [Nat-m.](#) [sulph.](#)

EXTREMITIES - NAILS; complaints of - hangnails - Fingers - Third – right [wye.](#)

EXTREMITIES - NAILS; complaints of - hangnails – Fingers [calc.](#) [lyc.](#) [Merc.](#) [Nat-m.](#) [Rhus-t.](#) [sabad.](#) [Stann.](#) [Sulph.](#)

EXTREMITIES - NAILS; complaints of - hangnails – inflamed [kali-chl.](#) [lyc.](#) [nat-m.](#) [upa.](#)

EXTREMITIES - NAILS; complaints of - hangnails – painful [lyc.](#) [nat-m.](#) [sel.](#) [stann.](#) [upa.](#)


EXTREMITIES - NAILS; complaints of - hangnails – painless [plut-n.](#)

EXTREMITIES - NAILS; complaints of - hangnails - Thumbs - Root of nail [bros-gau.](#)

Bibliography



Chapter 176. Superficial Cutaneous Infections and Pyodermas > Staphylococcal Paronychia; Fitzpatrick's Dermatology in General Medicine, 8e ..., usually around the fingernails, often originating from a break in the skin, such as a hangnail. Clinically, skin and soft tissue of the proximal and lateral nail fold are red, hot, and tender, and, if not treated, can progress to abscess formation (Fig. 176-12). Management of paronychia caused by S...



Chapter 194. Paronychia > Prevention; The Color Atlas of Family Medicine, 2e ... Trim hangnails to a semilunar smooth edge with a clean sharp nail plate trimmer. Trim toenails flush with the toe tip. Do not bite the nail plate or lateral nailfolds. Avoid prolonged hand exposure to moisture. If hand washing must be frequent, use antibacterial soap, thoroughly dry hands...




Chronic Venous Insufficiency & Lymphedema > General Considerations; Current Diagnosis & Treatment: Geriatrics ... there are extensive hyperkeratotic or papillomatous changes. Patient should see a podiatrist for nail care. Avoid trimming the cuticles or hangnails. Gloves are recommended for gardening, housework, and dishwashing. Early treatment of minor trauma or insect bites is recommended. Patients should be advised to use...



Dermatologic Disorders > Clinical Findings; Current Medical Diagnosis & Treatment 2016 ... illumination. Periungual warts may be dry, fissured, and hyperkeratotic and may resemble hangnails. Plantar warts resemble plantar corns or calluses. ...



Encyclopedia Homoeopathica



Nontraumatic Disorders of the Hand > PARONYCHIA; Tintinalli's Emergency Medicine: A Comprehensive Study Guide, 8e ... then be gently probed with a small clamp to ensure drainage. Paronychia is an infection of the lateral nail fold or perionychium, occasionally extending to the cuticle or eponychium. It is usually caused by minor trauma such as nail-biting, manicures, or embedded lateral nails ("hangnails...



Radar 10