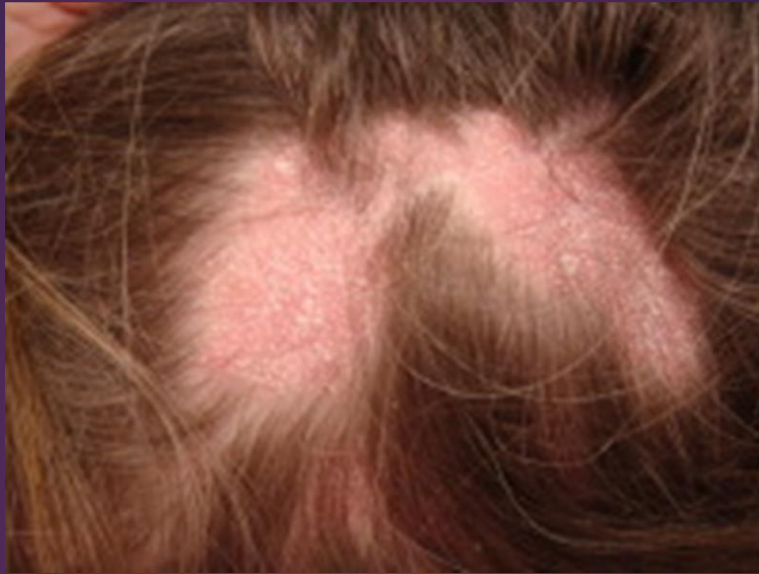



LICHEN PLANOPILARIS AND HOMOEOPATHY

DR. RAJNEESH KUMAR SHARMA MD (HOMOEOPATHY)

DR. SWATI VISHNOI BHMS

DR. PREETIKA LAKHERA BHMS

DR. MOHAMMAD TAYYAB DAUD BHMS

DR. MOHAMMAD TAYYAB AMIR BHMS

LICHEN PLANOPILARIS AND HOMOEOPATHY

© Dr. Rajneesh Kumar Sharma MD (Homoeopathy)

Dr. Swati Vishnoi BHMS

Dr. Preetika Lakhera BHMS

Dr. Mohammad Tayyab Daud BHMS

Dr. Mohammad Tayyab Amir BHMS

Homoeo Cure Research Institute

NH 74- Moradabad Road

Kashipur (UTTARANCHAL) - INDIA

Ph- 09897618594

E. mail- drrajneeshhom@hotmail.com

www.treatmenthomeopathy.com

www.homeopathyworldcommunity.com

Contents

Definition	1
Etymology	2
Epidemiology	2
Causes.....	2
Pathology	2
Types.....	3
Classic LPP.....	3
Frontal fibrosing alopecia	3
Lassueur Graham-Little Piccardi syndrome.....	4
Signs and Symptoms	4
Diagnosis.....	5
Differential Diagnosis.....	5
Treatment	5
Homoeopathic treatment.....	6
Common remedies for Lichen planopilaris	6
Short repertory of Lichen planopilaris	6
Bibliography.....	8

Definition

Lichen planopilaris is a rare inflammatory condition of skin resulting in patchy progressive permanent hair loss primarily on the scalp. Although lichen planopilaris is rare, it is one of the common causes of scarring hair loss of the scalp. (Psora/ Sycosis/ Syphilis)

Etymology

Follicular lichen planus, Frontal fibrosing alopecia (subtype), Kossard disease, Lichen planopilaris classic type, LPP, Lichen planus follicularis, Lichen follicularis

Epidemiology

Lichen planopilaris usually affects young adult women, although the age range is wide and it also affects men. It commonly develops in association with lichen planus affecting the skin, mucosa and nails.

Causes

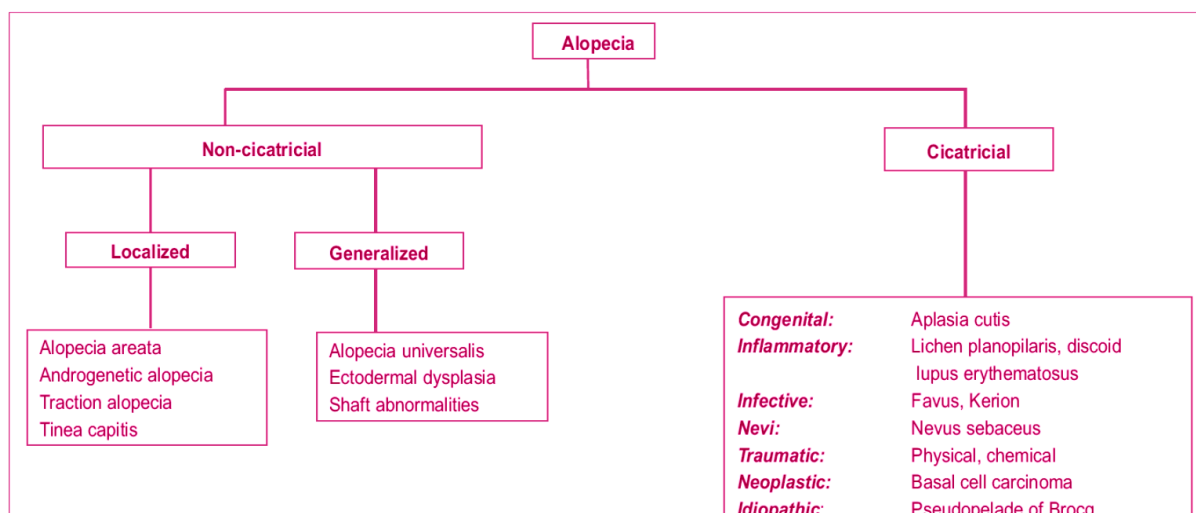
The exact cause of this disorder is unknown but it is assumed to be an autoimmune disorder. T-lymphocytes are known to be involved, however, the trigger is not yet known. The hair loses its protection from the immune system. The immune system then starts to attack the hair follicle. Its activating factors may include-

- Pharmacologic agents (Causa occasionalis)
- Contact sensitizers (Causa occasionalis)
- Infectious agents (Psora/ Syphilis/ Causa occasionalis)

Pathology

Lichen planopilaris affects hairy areas of skin. It is an example of a primary lymphocytic folliculitis. Lichen planopilaris destroys the hair follicle and then replaces it with scarring. Histology reveals the following characteristic features-

- Absence of errector pili muscles (Syphilis)
- Absence of sebaceous glands (Syphilis)
- Perivascular and perifollicular lymphocytic infiltrate in the reticular dermis (Syphilis/ Sycosis)
- Mucinous perifollicular fibroplasia within the upper dermis with absence of interfollicular mucin (Syphilis/ Sycosis)
- Superficial perifollicular wedge-shaped scarring (Psora/ Sycosis/ Syphilis)



Follicular lesions occurring in the scalp are accompanied by some scaling and are likely to lead to a scarring alopecia (Psora/ Sycosis/ Syphilis). Very rarely, the scalp alone is involved.

Graham Little–Piccardi–Lassueur syndrome comprises the triad of multifocal scalp cicatricial alopecia (Psora/ Sycosis/ Syphilis), non-scarring alopecia of the axillae and/or groin (Psora/ Syphilis), and keratotic lichenoid follicular papules (Psora/ Sycosis/ Syphilis). The clinical, histological and IMF overlap between this syndrome and LP with follicular involvement (lichen planopilaris) suggest that both are variants of LP.

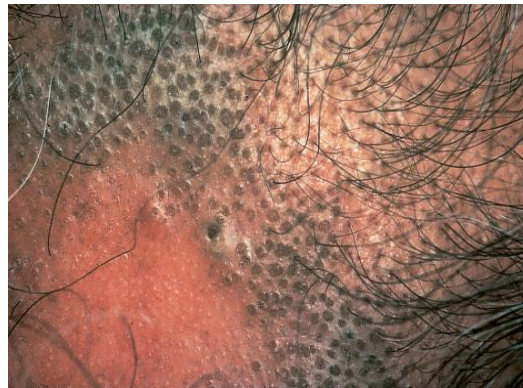
Progressive frontal fibrosing alopecia is a clinically distinct variant of lichen planopilaris and is certainly associated with mucocutaneous lichen planus. (Psora/ Sycosis/ Syphilis)

Types

Lichen planopilaris may be of three types-

Classic LPP

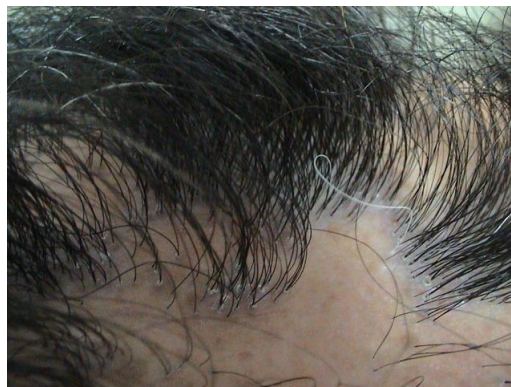It is also known as follicular lichen planus.



Lichen planopilaris-Hyperpigmented follicular 'plugged' lesions in frontal scalp hairline

FRONTAL FIBROSING ALOPECIA

It is characterized by characteristic gradual progressive alopecia (Psora/ Syphilis) and scarring (Psora/ Sycosis) on the scalp near the forehead including eyebrows, eye lashes and/or other parts of the body in some cases.

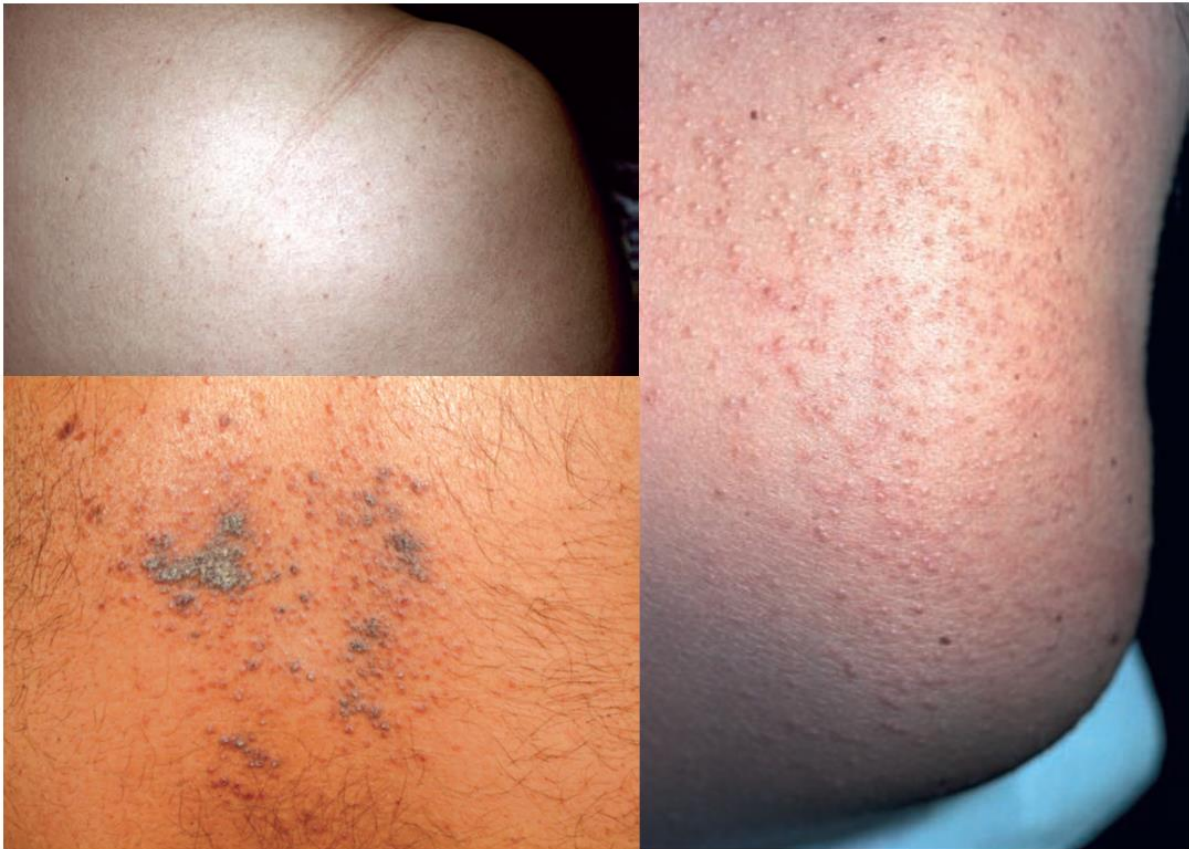

Frontal fibrosing alopecia

LASSUEUR GRAHAM-LITTLE PICCARDI SYNDROME

It is a triad of multifocal cicatricial alopecia (Psora/ Syphilis) of the scalp, noncicatricial alopecia of the axilla and groin and a follicular lichen planus eruption (Psora/ Sycosis) on the body, scalp, or both.

Tiny red papules (Psora) appear around a cluster of hairs. Rarely, blistering (Psora) occurs in the lesions. The disease affects mostly the hair follicles, although lesions may also be found on the skin and mucous membranes. Its common signs and symptoms are increased hair shedding (Psora), itching (Psora), scaling (Psora/ Sycosis), burning (Psora), and tenderness (Psora). Hair loss may be permanent if the disease causes permanent scarring as cicatricial alopecia. (Psora/ Sycosis/ Syphilis)



Graham–Little syndrome; lichen planopilaris, follicular pattern

Signs and Symptoms

Lichen planopilaris typically presents as smooth white patches of scalp hair loss (Psora/ Syphilis). No hair follicle openings can be seen in the areas of hair loss (Syphilis). At the edges of these patches there may be scale and redness around each hair follicle (Psora/ Sycosis). Hair can be easily pulled out. As it is multifocal, small patches may merge to form larger irregular areas. Lichen planopilaris is usually slowly progressive. Diffuse hair loss is uncommon. Common sites of involvement are the sides, front and lower back of the scalp. Symptoms are often absent but they may include-

- Itching (Psora)
- Pain (Psora)

- Tenderness (Psora)
- Discomfort (Psora)
- Burning (Psora)
- Alopecia (Psora/ Syphilis)
- Hyperkeratosis (Sycosis)
- Lichenification (Sycosis)
- Abnormality of the fingernails (Psora/ Sycosis/ Syphilis)
- Aplasia/Hypoplasia of the skin (Psora/ Syphilis)
- Skin ulcer (Syphilis)
- Abnormal blistering of the skin (Psora)
- Abnormality of the intestine (Psora)
- Abnormality of the liver (Psora)
- Hypopigmented skin patches (Psora/ Syphilis)
- Neoplasm of the oral cavity (Psora/ Sycosis/ Syphilis)
- Onycholysis (Syphilis)
- Pterygium (Psora/ Sycosis)
- Vaginal neoplasm (Psora/ Sycosis/ Syphilis)

Diagnosis

Lichen planopilaris is suspected on the keen clinical examination of the mouth, nails and skin for evidence of lichen planus elsewhere.

Trichoscopy reveals absent follicles, white dots, tubular perifollicular scale and perifollicular erythema. The diagnosis may be confirmed on a scalp biopsy that includes hairs with surrounding redness and scale at the edge of an area of hair loss.

Differential Diagnosis

Follicular LP must be distinguished by biopsy from-

- Keratosis pilaris
- Darier's disease
- Follicular mucinosis
- Lichen scrofulosorum
- Lupus erythematosus

Treatment

Treatment is required early as no treatment recovers hairs that have been lost and replaced by scarring. The objective of treatment is to slow progression of the disease and relieve symptoms. Hair loss may continue, but at a slower rate. Response to treatment is variable.

Since this is a constitutional disorder rather than a local one, holistic treatment is the only option to cure it by roots.

Surgery such as scalp reduction and hair transplantation has been used for end stage disease with large areas of scarring, but is not always successful.

Homoeopathic treatment

From overall study of Lichen planopilaris, it becomes clear that it is not simply a disorder of local factors, but whole genetics and constitutional disharmony is there. The person as a whole is affected by the factors causing LPP; and later on, by the effects of established disease in that individual, physically as well as mentally. Thus, whole person needs treatment rather than a local dermal system.

Well selected constitutional remedy almost always cures the condition permanently if applied as per laws of similia.

Common remedies for Lichen planopilaris

acetan. acon-ac. **Acon.** aeth. **Agar.** agn. ail. allox. aloe alum-p. alum-sil. **Alum.** **Am-c.** am-m. ambr. **Anac.** anag. **Anan.** ang. **ANT-C.** **Ant-t.** anthraci. anthraco. **Apis** aran. arg-met. **Arg-n.** **Arn.** ars-h. **Ars-i.** ars-s-f. **ARS.** arum-d. arum-t. **Asaf.** asim. aster. aur-ar. aur-m-n. aur-m. **Aur.** bac. bad. bamb-a. bar-c. **Bar-m.** bar-s. **BELL.** benz-ac. berb. beryl. borx. bov. brom. **Bry.** bufo cadm-s. **Calad.** calc-n. **Calc-p.** **Calc-s.** calc-sil. **Calc.** **Canth.** caps. carb-ac. **Carb-an.** **Carb-v.** **Carbn-s.** carc. carl. castn-v. caul. **CAUST.** **Cham.** chel. chin. chinin-ar. chinin-s. chir-fl. chlf. **Chlol.** chord-umb. **Cic.** cemic. cina **Cist.** **CLEM.** coc-c. **Cocc.** cod. colch. coli. **Com.** **Con.** **Cop.** cor-r. cortiso. crot-h. **Crot-t.** cub. cund. cupr. **CUR.** cycl. dig. dros. **Dulc.** eug. euph-l. euph. euphr. fago. falco-pe. ferr-ar. ferr-i. ferr. fl-ac. fuli. galeoc-c-h. **Gamb.** gast. gels. gink-b. goss. granit-m. **GRAPH.** **Grin.** guaj. guare. hell. helodr-cal. **Hep.** hippoc-k. hippoz. hydr-ac. hydr. **Hydr.** **Hyos.** hyper. **Ign.** ina-i. indg. **Iod.** iodof. ip. **Iris** jab. **Jug-c.** **Jug-r.** **Kali-act.** **Kali-ar.** **Kali-bi.** **Kali-br.** **KALI-C.** kali-chl. **KALI-H.** kali-m. kali-n. kali-p. **Kali-s.** kali-sil. kalm. keros. ketogl-ac. **Kreos.** lac-d. lac-e. **LACH.** lachn. lat-m. **Laur.** **Led.** lipp. **Lith-c.** loxo-lae. loxo-recl. **LUNA** **LYC.** m-ambo. m-arct. m-aust. **Mag-c.** mag-m. mang. meny. meph. **Merc-c.** merc-i-r. **MERC.** **MEZ.** moni. morb. morg-p. morg. mosch. **Mur-ac.** musa myos-a. myric. nabal. narc-ps. nat-ar. **Nat-c.** nat-f. nat-hsulo. **NAT-M.** **Nat-p.** **Nat-s.** **NIT-AC.** **NUX-V.** **Olnd.** op. ox-ac. ozone pall. **Par.** petr-ra. **Petr.** **PH-AC.** **PHOS.** **Phyt.** pic-ac. pieri-b. pip-n. pitu-gl. pix plac-s. **Plan.** **Plb.** positr. pot-e. **PSOR.** **PULS.** querc-r. **Ran-b.** ran-s. rat. rhus-g. **RHUS-T.** **Rumx.** ruta sabad. sabin. sacch-a. **Sars.** sec. **Sel.** **Seneg.** **SEP.** **Sil.** sinus. **Spect.** spig. spong. **Squil.** stann. **STAPH.** **Stram.** stront-c. suis-hep. **SUL-AC.** sul-i. sulfa. sulfon. **SULPH.** **Syph.** tab. tarax. tarent. tell. tere-la. teucr. thiop. **Thuj.** **Til.** toxi. toxo-g. trios. tritic-vg. trom. tub-m. tub. **Urin.** **Vac.** valer. vanil. verat. verb. vero-o. vinc. **Viol-t.** vip. x-ray zinc-p. **ZINC.**

Short repertory of Lichen planopilaris

CHEST - ERUPTIONS - pimples - red - lichen simplex; like ant-t.

FEMALE GENITALIA/SEX - ERUPTIONS - Vagina; in – lichen moni.

FEMALE GENITALIA/SEX - KRAUROSIS VULVAE moni.

MOUTH - ULCERS - Cheeks - Inside - lichen planus borx. fl-ac. merc. nit-ac.

SKIN - DISCOLORATION - brown - liver spots am-c. am-m. **Ant-c.** ant-t. **Arg-n.** **arn.** ars-i. ars-s-f. **Ars.** aur-ar. **Aur.** bad. borx. bry. cadm-s. calc-p. calc-s. calc-sil. calc. canth. **Carb-v.** **Carbn-s.** carc. caul. caust. chel. **Con.** cop. cor-r. crot-h. **CUR.** dros. **Dulc.** ferr-ar. ferr-i. ferr. graph. **Hyos.** **Iod.** kali-ar. kali-bi. kali-c. kali-p. kali-s. kali-sil. **LACH.** **Laur.** led.

LYC. Merc-c. merc-i-r. MERC. Mez. moni. musa nat-ar. Nat-c. nat-hsulo. nat-m. nat-p. NIT-AC. Nux-v. ozone petr. Phos. Plb. psor. puls. ruta sabad. SEP. sil. stann. sul-ac. sul-i. SULPH. tarent. Thuj. trios. Tub.

SKIN - DISCOLORATION - spots - dark spots - old people; in ars. aur. bar-c. Carb-an. Con. Lach. Lyc. op. Sec.

SKIN - ERUPTIONS – flat Am-c. ang. ant-c. ant-t. Ars. Asaf. BELL. carb-an. euph. LACH. Lyc. merc. Nat-c. nit-ac. petr. Ph-ac. phos. puls. Ran-b. Sel. Sep. Sil. staph. sulph. thuj.

SKIN - ERUPTIONS - itching - warm - bed - agg. aeth. Alum. anac. ant-c. caust. Clem. cocc. Kali-act. kreos. mag-m. merc. mur-ac. PSOR. Puls. Rhus-t. sars. staph. SULPH. Til. verat.

SKIN - ERUPTIONS – itching acon. aeth. Agar. agn. allox. alum-p. alum-sil. Alum. Am-c. am-m. ambr. Anac. anag. Ant-c. Ant-t. anthraci. Apis arg-met. Arn. Ars-i. ars-s-f. ARS. asaf. aur-m-n. bamb-a. bar-c. bar-s. bell. borx. bov. Bry. bufo Calad. Calc-p. Calc-s. calc-sil. Calc. Canth. caps. carb-an. carb-v. carbn-s. carl. CAUST. Cham. chel. chinin-s. cic. cemic. cina CLEM. cocc. cod. colch. Com. con. Cop. cortiso. Crot-t. cupr. dig. dros. dulc. fago. ferr. fl-ac. fuli. gast. gink-b. goss. GRAPH. guaj. guare. Hep. hippoc-k. Ign. iod. ip. iris Jug-c. Jug-r. Kali-ar. kali-bi. kali-br. Kali-c. Kali-i. kali-n. kali-p. Kali-s. kali-sil. kalm. Kreos. lac-d. lac-e. Lach. lat-m. laur. Led. Lyc. m-ambo. m-arct. m-aust. mag-c. mag-m. mang. Merc. MEZ. morg-p. morg. myos-a. nat-ar. nat-c. nat-f. NAT-M. NIT-AC. NUX-V. Olnd. ox-ac. Par. Petr. ph-ac. Phos. Phyt. pic-ac. pitu-gl. pix plac-s. plb. positr. pot-e. Psor. Puls. Ran-b. ran-s. RHUS-T. ruta sabad. sabin. sacch-a. Sars. Sel. SEP. Sil. Spect. spig. spong. Squil. stann. STAPH. stram. stront-c. sul-ac. SULPH. tarax. tarent. teucr. thuj. til. tritic-vg. tub-m. Vac. valer. verat. vero-o. vinc. Viol-t. zinc-p. zinc.

SKIN - ERUPTIONS – lichen acon. agar. alum. am-m. Anan. Ant-c. anthraco. Apis Ars-i. Ars. Bell. bov. bry. Calad. castn-v. Cic. cocc. dulc. jug-c. kali-ar. Kreos. Led. Lyc. mang. merc. mur-ac. nabal. nat-c. nat-m. phyt. Plan. Rumx. sep. sul-i. Sulph. til.

SKIN - ERUPTIONS - lichen planus agar. anac. Ant-c. apis Ars-i. Ars. chinin-ar. iod. Jug-c. Kali-bi. kali-i. led. merc. sars. staph. sul-i. sulph. syph.

SKIN - ERUPTIONS – patches acon-ac. agar. ail. apis ars. berb. Calc. Carb-v. coli. Graph. ina-i. Iris jug-c. Kali-bi. Kali-c. Lith-c. mang. petr. phos. pot-e. Puls. Sars. sec. Sep. sinus. thuj. tritic-vg. Viol-t.

SKIN - ERUPTIONS – pimples acetan. Acon. Agar. aloe alum-p. alum. am-c. am-m. ambr. anac. ANT-C. Ant-t. aran. arg-met. arg-n. arn. ars-h. ars-i. ARS. arum-d. arum-t. aster. aur-ar. aur-m. Aur. bar-c. Bar-m. bar-s. Bell. benz-ac. berb. borx. bov. brom. Bry. bufo Calad. Calc-p. Calc-s. calc-sil. calc. Canth. caps. carb-ac. Carb-an. carb-v. Carbn-s. CAUST. Cham. chel. chin. chinin-ar. chlf. chlol. chord-umb. cemic. cina Cist. clem. coc-c. Cocc. coli. Con. cop. crot-h. crot-t. cub. cund. cupr. cycl. dig. dros. Dulc. eug. euph-l. euphr. falco-pe. Fl-ac. Gamb. gels. gink-b. granit-m. Graph. guaj. hell. helodr-cal. Hep. hippoc-k. hydr-ac. hydr. hyos. hyper. ina-i. indg. iod. iodof. jab. Kali-ar. kali-bi. kali-br. Kali-c. kali-chl. kali-m. kali-n. kali-p. kali-s. Kreos. lac-e. Lach. lachn. Led. LUNA Lyc. m-ambo. mag-c. mag-m. mang. meny. meph. Merc-c. MERC. Mez. mosch. Mur-ac. myric. nat-ar. Nat-c. NAT-M. Nat-p. Nat-s. NIT-AC. Nux-v. op. pall. par. petr. PH-AC. PHOS. pieri-b. pip-n. pix plb. psor. PULS. querc-r. rat. rhus-g. RHUS-T. ruta

sabad. sabin. Sars. sel. Seneg. SEP. Sil. spig. Spong. Squil. stann. Staph. stram. stront-c. suis-hep. sul-ac. sul-i. sulfon. SULPH. tab. tarax. tarent. tell. Thuj. Til. toxi. tritic-vg. trom. Urin. vac. valer. vanil. verat. viol-t. ZINC.

SKIN - ERUPTIONS – popular Acon. allox. anthraco. aur. bac. beryl. Bry. Calc. caps. Caust. cham. cycl. Dulc. galeoc-c-h. gels. Grin. hippoz. Hydr. lod. Kali-bi. Kali-c. KALI-I. kali-s. keros. lat-m. loxo-lae. loxo-recl. lyc. Merc. morb. narc-ps. nat-f. petr-ra. Petr. phos. pic-ac. psor. Sep. sil. suis-hep. sulfa. Sulph. Syph. tere-la. thiop. toxo-g. x-ray zinc.

SKIN - ERUPTIONS – red acon. Agar. AM-C. anac. Anan. ant-c. ant-t. apis Arn. Ars. asim. aur-ar. aur. bell. berb. bry. calad. calc-n. Calc. caust. cham. chel. chinin-s. chir-fl. Chlol. cic. cina Clem. cocc. Com. con. cop. crot-t. cycl. Dulc. fl-ac. goss. Graph. ina-i. Kali-bi. KALI-C. kali-s. ketogl-ac. lach. Led. lipp. lyc. m-ambo. Mag-c. MERC. Mez. Nit-ac. op. ox-ac. petr. ph-ac. PHOS. plb. psor. ran-b. Rhus-t. sabad. sars. sep. sil. spig. squil. staph. Stram. SUL-AC. SULPH. tab. thuj. til. tritic-vg. tub. valer. vanil. verat. verb. vero-o. vip.

SKIN - ERUPTIONS - tubercles – umbilicated Kali-bi. Kali-br.

Bibliography



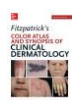Chapter 30. Commonly Encountered Genital Dermatoses > Lichen Planus
CURRENT Diagnosis & Treatment of Sexually Transmitted Diseases



Chapter 88. Hair Growth Disorders > Lichen Planopilaris Fitzpatrick's Dermatology in General Medicine, 8e... LPP is a follicular variant of lichen planus. Together with DLE, this is the most common cause of primary cicatricial alopecia. LPP can be divided in classic LPP, frontal fibrosing alopecia (FFA), and Graham–Little syndrome. The typical age of onset of classic LPP is around the fifth decade...



Dermatologic Disorders > LICHEN PLANUS Current Medical Diagnosis & Treatment 2017



Disorders of Hair Follicles and Related Disorders > Lichen Planopilaris (LPP) Fitzpatrick's Color Atlas and Synopsis of Clinical Dermatology, 7e... Figure 31-16. Scarring alopecia of scalp: pseudopelade of Brocq caused by lichen planus The scalp is smooth, shiny, devoid of hair and hair follicles in many areas; some of the remaining follicles are inflamed with perifollicular erythema and scale. Several hairs are seen emerging from...



Eczema, Psoriasis, Cutaneous Infections, Acne, and Other Common Skin Disorders > LICHEN PLANUS Harrison's Principles of Internal Medicine ... inhibitor Oral


Twice daily Renal dysfunction, hypertension, hyperkalemia, hyperuricemia, hypomagnesemia, hyperlipidemia, increased risk of malignancies FIGURE 71-5 Lichen planus . An example of lichen planus showing multiple flat-topped, violaceous papules and plaques. Nail dystrophy...



Encyclopedia Homoeopathica



Radar 10



Skin Disorders: Trunk > LICHEN PLANUS Tintinalli's Emergency Medicine: A Comprehensive Study Guide, 8e ... Lichenoid drug eruptions can be identical to lichen planus, except they tend to be more generalized and photodistributed and there is a history of drug ingestion. The latent period can be months to years, with an average of 12 months, and it may take years to resolve after withdrawal...



The Skin and Nails > Lichen planus DeGowin's Diagnostic Examination, 10e... Purple, flat-topped, sharply demarcated pruritic papules appear on the wrists, ankles, eyelids, and shins. Other forms exist, including hypertrophic and bullous lichen planus. Mucous membrane involvement is common, appearing as white linear lesions in the mouth or genital mucosa (Wickham...