

# Oral Lesions and Homoeopathy

© Dr. Rajneesh Kumar Sharma MD (Homoeopathy)

Dr. (Km) Ruchi Rajput BHMS

Homoeo Cure Research Centre P. Ltd.

NH 74- Moradabad Road

Kashipur (UTTARANCHAL) - INDIA

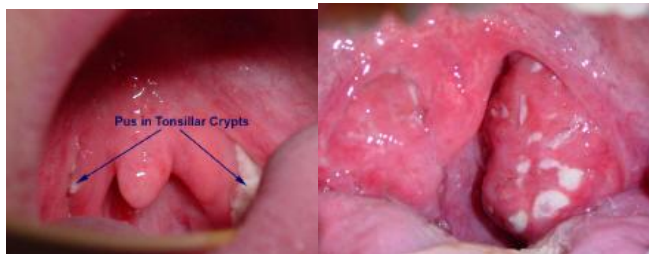
Ph- 09897618594

## Introduction

There are certain conditions of oral cavity which can easily be seen, diagnosed and cause headache to a physician treating it due to their complicated nature or under running a serious disease. It becomes a matter of great deal to the physician to understand these lesions and their nature especially while treating them homoeopathically. Here we are discussing about some very common oral lesions in terms of Homoeopathy.

## Acute Tonsillitis

This is a common condition which is usually caused by gram positive bacteria. If the organism is Streptococcal pyrogenesis, there is a risk of developing Rheumatic Fever (Psora/ Sycosis/ Syphilis). Often multiple different bacteria exist in the tonsillar crypts, which can be difficult to culture.



The picture above right shows the appearance of acute tonsillitis due to Infectious Mononucleosis (Psora/ Syphilis).

## Rubrics related with Tonsillitis in various repertories-

S. No.	Rubric	No. of remedies
1	Clarke J. H., Clinical Repertory (English) - Clinical - T - tonsillitis	11
2	EARS - Tickling - tonsils, from	2
3	EARS - Hearing - deafness - tonsils, from swelled	4
4	EARS - Aggravation - tonsils, from enlarged	4
5	MOUTH - Palate - Adheres to tonsil, uvula	1
6	MOUTH - Throat (and gullet) - abscess of tonsils	21
7	MOUTH - Throat (and gullet) - burning - tonsils	1
8	MOUTH - Throat (and gullet) - dry - tonsils	1
9	MOUTH - Throat (and gullet) - indurated tonsils	7
10	MOUTH - Throat (and gullet) - inflamed - tonsils	44
11	MOUTH - Throat (and gullet) - itching in - tonsils	3
12	MOUTH - Throat (and gullet) - nodular tonsils	1

13	MOUTH - Throat (and gullet) - painful - tonsils	10
14	MOUTH - Throat (and gullet) - plug, lump, etc. - tonsils, in	5
15	MOUTH - Throat (and gullet) - red - purple tonsils	2
16	MOUTH - Throat (and gullet) - red - tonsils	9
17	MOUTH - Throat (and gullet) - sore throat - tonsils	1
18	MOUTH - Throat (and gullet) - sticking, stitches, etc. - tonsils, in	4
19	MOUTH - Throat (and gullet) - swollen, as if - tonsils	3
20	MOUTH - Throat (and gullet) - throbbing, beating - tonsils, in	3
21	MOUTH - Throat (and gullet) - ulcers - tonsils, on	8
22	MOUTH - Throat (and gullet) - uvula - sticking in - to tonsil	1
23	RESPIRATION - Impeded by - tonsils, swelled	1
24	COUGH - Excited or aggravated by - tonsils, irritation in	3
25	C - Cough - tonsils, enlarged	2
26	H - Hearing - bad, deafness, impaired - enlarged tonsils from	5
27	R - Rheumatism - tonsillitis, after	4
28	S - Speaking, talking agg - nasal - tonsils, enlarged, with	1
29	T - Tonsils	20
30	EARS - Deafness, hardness of hearing - Cause - Adenoids and hypertrophied tonsils	7
31	THROAT - Tonsils - Deposits on - Creamy, extends over tonsils, uvula, soft palate	1
32	THROAT - Tonsils - Deposits on - Grayish - dirty, like macerated skin, covering tonsils, uvula, pharynx	1
33	THROAT - Tonsils - Deposits on - Grayish - patch on Tonsils	1
34	THROAT - Tonsils - Deposits on - Patchy on right tonsil and inflamed fauces, easily detached	1
35	THROAT - Tonsils - Deposits on - Thick, brownish-yellow like wash leather - firm, fibrinous, pearly, extends over tonsils, soft palate	1
36	THROAT - Tonsils - Deposits on - Thin - false; on yellowish red tonsils and fauces	1
37	RESPIRATORY SYSTEM - Cough - Aggravation - Tonsils, enlarged	2
38	MOUTH AND THROAT - Tonsils	9
39	MOUTH AND THROAT - Diphtheria, tonsillitis, etc.	13
40	EAR - COMPLAINTS of ears - accompanied by - Tonsils; enlarged	4
41	EAR - ELONGATION; from - Tonsils; of	4
42	HEARING - LOST - tonsillectomy; after	1
43	HEARING - LOST - tonsils; from swelling of	4
44	THROAT - ADHESION - Uvula - Tonsil; to	2
45	THROAT - ANXIETY and apprehension in throat - oppression; with - Tonsils; in	1
46	THROAT - APHTHAE - Tonsils, on	4
47	THROAT - BLOOD - oozing - Tonsils	5
48	THROAT - CASEOUS deposits in tonsils	10
49	THROAT - COATED - Tonsils	1
50	THROAT - DISCOLORATION - bluish - Tonsils	1
51	THROAT - DISCOLORATION - gray - Tonsils	2

52	THROAT - DISCOLORATION - purple - Tonsils	4
53	THROAT - DISCOLORATION - redness - bright - Tonsils	3
54	THROAT - DISCOLORATION - redness - dark red - Tonsils	4
55	THROAT - DISCOLORATION - redness - Tonsils	24
56	THROAT - DISCOLORATION - white - Tonsils	1
57	THROAT - DISCOLORATION - yellow - Tonsils	1
58	THROAT - DRYNESS - Tonsils	1
59	THROAT - ELONGATED - Tonsils	1
60	THROAT - ERUPTIONS - vesicles - Tonsils	3
61	THROAT - GLAZED appearance - Tonsils	2
62	THROAT - INDURATION - Tonsils; of	38
63	THROAT - INFLAMMATION - Tonsils	142
64	THROAT - ITCHING - Tonsils	3
65	THROAT - LUMP; sensation of a - Tonsils	5
66	THROAT - MEMBRANE - Tonsils	21
67	THROAT - MENSES; during - Tonsils	1
68	THROAT - MUCOUS patches - gray - Tonsils	1
69	THROAT - MUCOUS patches - Tonsils	1
70	THROAT - MUCUS - false membrane, like - Tonsils and fauces; on yellowish-red	1
71	THROAT - MUCUS - tenacious - thick yellowish-brown like wash leather, pearly - extending to tonsils and soft palate	1
72	THROAT - MUCUS - thick - dark gray or brownish-black - Tonsils	1
73	THROAT - NODOSITIES - Tonsils	1
74	THROAT - OBSTRUCTION - Tonsils; from swelling of	1
75	THROAT - PAIN - Tonsils	65
76	THROAT - PULSATING - Tonsils	6
77	THROAT - PUSTULES - Tonsils, on	2
78	THROAT - SENSITIVE - Tonsils	1
79	THROAT - SUPPURATION - Tonsils	55
80	THROAT - SWELLING - sensation of - Tonsils	4
81	THROAT - SWELLING - Tonsils	149
82	THROAT - SWELLING - Tonsils - accompanied by - swelling - Blood vessels on tonsils; of	1
83	THROAT - TONSILS; complaints of	31
84	THROAT - ULCERS - Tonsils	36
85	THROAT - VARICOSE - Tonsils	6
86	LARYNX AND TRACHEA - VOICE - nasal - tonsils; with enlarged	1
87	RESPIRATION - DIFFICULT - lying - agg. - enlargement of tonsils; from	1
88	RESPIRATION - IMPEDED, obstructed - pulsation; from - Tonsils; of	1
89	RESPIRATION - IMPEDED, obstructed - swelling; from - Tonsils; of	1
90	COUGH - IRRITATION; from - Tonsils; in	3
91	COUGH - TICKLING - Tonsils; below	1
92	COUGH - TOUCHED; from being - tonsils	1
93	GENERALS - ELONGATION - Tonsils agg.; of	1
94	GENERALS - HISTORY; personal - abscesses; of recurrent - Tonsils; on	5

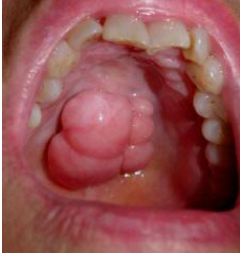95	GENERALS - HISTORY; personal - tonsillitis; of recurrent	28
----	--	----

**Repertorization-**

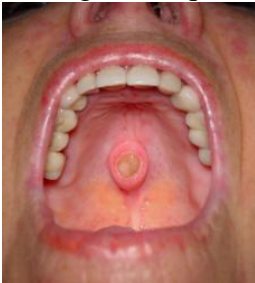merc.	lach.	nit-ac.	staph.	bell.	phyt.	bar-c.	aur.	kali-bi.	hep.
4100	4045	3440	3410	3360	2990	2910	2270	2125	1970

**Torus palatinus**

It is a hard bony growth (Sycosis/ Syphilis) in the center of the roof of the mouth (palate). It is not a tumor or neoplasm but by a benign bony growth called an exostosis (Sycosis). This growth commonly occurs in females over the age of 30 and rarely needs treatment. Occasionally it is removed for the proper fitting of dentures.



The torus below has a chronic non-healing ulceration (Sycosis/ Syphilis). This is a rare finding and required surgical excision of the torus.



**Rubrics related with Torus Palatinus in various repertories-**

1	Clarke J. H., Clinical Repertory (English) - Clinical - P - palate, affections of	1
2	Choudhury H., Hints for Treatment of Cancer - CANCER OF - palate	9
3	MOUTH - Palate - Hard palate	64
4	MOUTH - Palate - Soft palate	48
5	MOUTH - Palate - brown, turning - soft palate	1
6	MOUTH - Palate - burning, heat, etc. - hard palate	5
7	MOUTH - Palate - burning, heat, etc. - soft palate	3
8	MOUTH - Palate - burnt feeling - hard palate	4
9	MOUTH - Palate - dry - soft palate	3
10	MOUTH - Palate - excoriated raw feeling - soft palate	1
11	MOUTH - Palate - inflamed - hard palate	6
12	MOUTH - Palate - itching - hard palate	5
13	MOUTH - Palate - itching - soft palate	5
14	MOUTH - Palate - necrosis - hard palate	6
15	MOUTH - Palate - oedema - soft palate	6
16	MOUTH - Palate - pain, simple - hard palate	4
17	MOUTH - Palate - pain, simple - soft palate	4
18	MOUTH - Palate - pinching - hard palate	2

19	MOUTH - Palate - pressure - hard palate	6
20	MOUTH - Palate - pressure - soft palate	8
21	MOUTH - Palate - pricking - hard palate	2
22	MOUTH - Palate - pricking - soft palate	2
23	MOUTH - Palate - rawness - soft palate	1
24	MOUTH - Palate - red - soft palate	5
25	MOUTH - Palate - rough - soft palate	8
26	MOUTH - Palate - scratching - hard palate	12
27	MOUTH - Palate - scratching - soft palate	11
28	MOUTH - Palate - sticking, stitches, stinging, etc. - hard palate	21
29	MOUTH - Palate - sticking, stitches, stinging, etc. - soft palate	9
30	MOUTH - Palate - swelled - hard palate	15
31	MOUTH - Palate - swelled - soft palate	17
32	MOUTH - Palate - swelled - sensation - hard palate	1
33	MOUTH - Palate - tearing or shooting in - soft palate	1
34	MOUTH - Palate - tickling - hard palate	3
35	MOUTH - Palate - tickling - soft palate	2
36	MOUTH - Palate - ulcers - hard palate	8
37	MOUTH - Palate - ulcers - soft palate	11
38	MOUTH - Palate - vesicles on - hard palate	8
39	MOUTH - Palate - vesicles on - soft palate	3
40	MOUTH - Tongue - sticks to palate	2
41	HEAT AND FEVER IN GENERAL - Partial heat - partial heat - on palate	40
42	P - Palate	6
43	T - Tongue - palate, sticks to	4
44	THROAT - Tonsils - Deposits on - Creamy, extends over tonsils, uvula, soft palate	1
45	THROAT - Tonsils - Deposits on - Thick, brownish-yellow like wash leather - firm, fibrinous, pearly, extends over tonsils, soft palate	1
46	MOUTH AND THROAT - Paralysis, noisy swallowing, etc. - palate	1
47	MOUTH - ABSCESS - Palate	1
48	MOUTH - ABSCESS - Palate - Hard palate	1
49	MOUTH - APHTHAE - Palate	17
50	MOUTH - APHTHAE - Palate - Hard palate	3
51	MOUTH - BLEEDING - Palate	3
52	MOUTH - BLEEDING - Palate - Hard palate	1
53	MOUTH - BLOTCHES - Palate	4
54	MOUTH - CANCER - Palate	2
55	MOUTH - CARIES - Palate	7
56	MOUTH - CHEWING agg. - Palate	1
57	MOUTH - COLDNESS - sensation of coldness - Palate	3
58	MOUTH - COMPLAINTS of mouth - Palate	6
59	MOUTH - CONDYLOMATA - Palate	1
60	MOUTH - CONSTRICTION - Palate	4
61	MOUTH - CONTRACTION - Palate	3
62	MOUTH - CRAWLING - Palate	15

63	MOUTH - DISAGREEABLE sensation - Palate	1
64	MOUTH - DISCOLORATION - Palate - brown - Soft palate	1
65	MOUTH - DISCOLORATION - Palate - red - Soft palate	5
66	MOUTH - DRAWN - down - Palate; soft	1
67	MOUTH - DRAWN - up - Palate; soft	1
68	MOUTH - DRYNESS - Palate	75
69	MOUTH - ELONGATION; sensation of - Palate	1
70	MOUTH - ERUPTIONS - pimples - Palate	9
71	MOUTH - ERUPTIONS - vesicles - Palate	15
72	MOUTH - ERUPTIONS - vesicles - Palate - Hard palate	14
73	MOUTH - ERUPTIONS - vesicles - Palate - Soft palate	4
74	MOUTH - ERUPTIONS - Palate	4
75	MOUTH - FOREIGN body - sensation of a - Palate	1
76	MOUTH - GANGRENOUS - Palate	1
77	MOUTH - GLAZED - Palate	4
78	MOUTH - GREASY sensation - Palate	5
79	MOUTH - HAIR; sensation of a - Palate; on	2
80	MOUTH - HARD - body at palate; sensation of a	1
81	MOUTH - HARD - Palate	7
82	MOUTH - HEAT - Palate	17
83	MOUTH - HEAT - Palate - Hard palate	5
84	MOUTH - HEAT - Palate - Soft palate	40
85	MOUTH - HEAVINESS - Palate	1
86	MOUTH - INDURATION - Palate	3
87	MOUTH - INFLAMMATION - Palate	28
88	MOUTH - INFLAMMATION - Palate - Hard palate	8
89	MOUTH - INFLAMMATION - Palate - Soft palate	3
90	MOUTH - INSENSIBLE - Palate	2
91	MOUTH - ITCHING - Palate	42
92	MOUTH - ITCHING - Palate - Hard palate	7
93	MOUTH - ITCHING - Palate - Soft palate	7
94	MOUTH - MEMBRANE - Palate covered with a false	13
95	MOUTH - MUCOUS MEMBRANE - excoriation - scaling off - Palate	6
96	MOUTH - MUCOUS MEMBRANE - excoriation - scaling off - Palate - Hard palate	1
97	MOUTH - MUCOUS MEMBRANE - excoriation - Palate	26
98	MOUTH - MUCOUS MEMBRANE - excoriation - Palate - sensation as if - Palate; hard	1
99	MOUTH - MUCOUS MEMBRANE - excoriation - Palate - Soft palate	2
100	MOUTH - NECROSIS - Palate; hard	6
101	MOUTH - NODOSITIES - Palate	4
102	MOUTH - NUMBNESS - Palate	6
103	MOUTH - PAIN - Palate	146
104	MOUTH - PAIN - Palate - Hard palate	55
105	MOUTH - PAIN - Palate - Soft palate	28
106	MOUTH - PAIN - Tongue - extending to - Palate	2

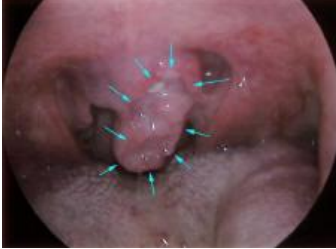107	MOUTH - PALATE; complaints of - Hard palate	65
108	MOUTH - PALATE; complaints of - Soft palate	48
109	MOUTH - PARALYSIS - Palate	5
110	MOUTH - PRICKLING - Palate	8
111	MOUTH - PRICKLING - Palate - Hard palate	2
112	MOUTH - PRICKLING - Palate - Soft palate	2
113	MOUTH - PUCKERED sensation - Palate	1
114	MOUTH - PULSATION - Palate	2
115	MOUTH - PUSTULES - Palate	4
116	MOUTH - RELAXED palate	1
117	MOUTH - ROUGHNESS - Palate	31
118	MOUTH - ROUGHNESS - Palate - Soft palate	9
119	MOUTH - SALIVA - dries on palate and lips, becomes tough	1
120	MOUTH - SCRAPING - Palate	19
121	MOUTH - SCRATCHING - Palate	11
122	MOUTH - SCRATCHING - Palate - Hard palate	14
123	MOUTH - SCRATCHING - Palate - Soft palate	11
124	MOUTH - SENSITIVE - Palate	5
125	MOUTH - SHRIVELLED - Palate	5
126	MOUTH - SKIN; sensation of a new - Palate	2
127	MOUTH - SOFT - Palate	2
128	MOUTH - SPASMS - Palate	1
129	MOUTH - STIFF - Palate	3
130	MOUTH - SWELLING - edematous - Palate; soft	6
131	MOUTH - SWELLING - Palate	43
132	MOUTH - SWELLING - Palate - Hard palate	19
133	MOUTH - SWELLING - Palate - Soft palate	19
134	MOUTH - TASTE - bitter - Palate; in back of	1
135	MOUTH - ULCERS - malignant - Palate; hard	1
136	MOUTH - ULCERS - Palate	40
137	MOUTH - ULCERS - Palate - Hard palate	13
138	MOUTH - ULCERS - Palate - Soft palate	12
139	MOUTH - WARTS - Palate	3
140	MOUTH - WRINKLED - Palate	2
141	THROAT - MUCUS - creamy - Tonsils - extending to - Uvula and soft palate	1
142	THROAT - MUCUS - tenacious - thick yellowish-brown like wash leather, pearly - extending to tonsils and soft palate	1
143	THROAT - SWELLING - Palate; soft	2
144	STOMACH - NAUSEA - Palate; in	5
145	STOMACH - PAIN - extending to - Palate	1
146	COUGH - DRYNESS, from - Palate	1
147	COUGH - ELONGATED Palate; from	2
148	COUGH - IRRITATION; from - Palate; in	4
149	COUGH - ROUGHNESS; from - Palate; in	1
150	COUGH - TICKLING - Palate; in	6

## Repertorization-

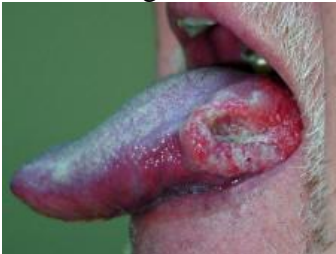phos.	merc.	bell.	nux-v.	lach.	aur.	nit-ac.	calc.	canth.	par.
5690	5574	5454	4545	4365	4334	3150	3105	2714	2625

## Oral Cancer

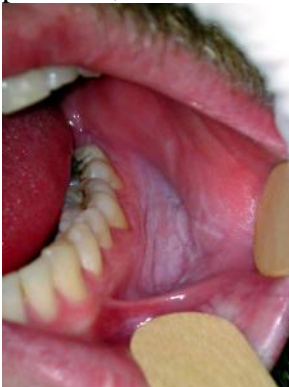This patient is a 57 year old, with a 75 pack year history of smoking and alcohol intake. He has a uvular carcinoma (Psora/ Sycosis/ Syphilis) which has also spread onto the nasopharynx surface of the soft palate. He was also found to have a carcinoma in the upper portion of his right lung.



Below is shown a cancer on the tongue in a 45 year old male who was a non-smoker. The most common cause of oral tumors is Human Papilloma Virus which is found in 70% of oral tumors. This virus most commonly causes tumors on the tonsil and base of tongue.

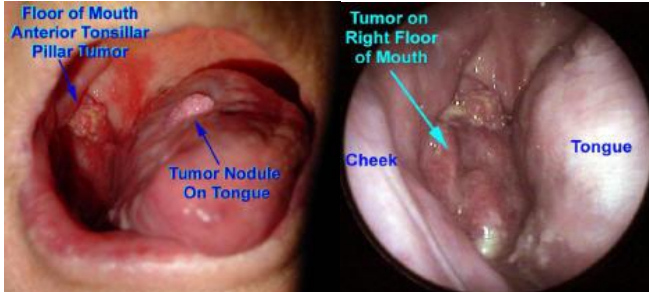


The following picture is from a 22 year old male who has used over one can of snuff for the past 15 years. He has high blood pressure (Sycosis) from the vasoconstrictive (contraction of blood vessels) (Psora) effect of nicotine and gastroesophageal reflux disease (stomach acid coming up from the stomach towards the mouth) which is also made worse from using tobacco products. The picture below shows extensive leukoplakia (Psora/ Sycosis/ Syphilis) forming between his gums and lips. This is a pre-cancerous condition and if it does not resolve with his cessation of using tobacco products, it will need to be surgically removed.

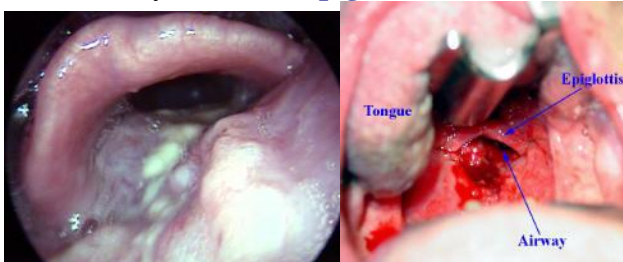



This patient is 87 year old who used to smoke 1 pack per day many years ago she was not sure how long she smoked. This patient has a tumor (Psora/ Sycosis/ Syphilis) on both her tongue and right floor of the mouth. The tumor is over her alveolus and extends onto the anterior tonsillar pillar. These types of tumors are often treated with a commando operation which consists of resection of the mandible, floor of mouth and tongue; along with a radical neck dissection which removes the muscles and lymph nodes in the neck.



This patient is a 70 year old who smoked 1 pack per day for 50 years he also drank alcohol heavily (Syphilis). He presented with severe **dysphagia** (trouble swallowing) (Psora) and on examination was found to have a very small airway (Syphilis). The pictures below show a large oral tumor (Psora/ Sycosis) in the **hypopharynx** with a very small airway under the **epiglottis**.



#### Rubrics related with Oral Cancer in various repertories-

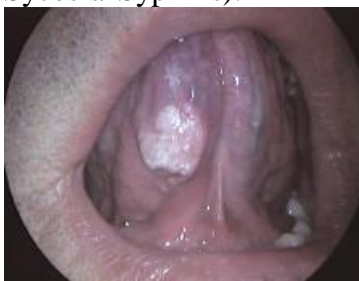1	Choudhury H., Hints for Treatment of Cancer - CANCER OF - mouth	3
2	MOUTH - Tongue - aphthae (cancer)	6
3	MOUTH - Tongue - cancer	10
4	MOUTH - CANCER	6
5	MOUTH - ODOR - offensive - accompanied by - cancer	4

#### Repertorization-

sulph.	aur-m.	merc-c.	sil.	merc.	agar.	ars.	aur.	borx.	carc.
600	500	200	179	150	100	100	100	100	100

#### Carcinoma of the Tongue

This patient has a T1 (2 cm or less) squamous cell carcinoma of the tongue (Psora/ Sycosis/ Syphilis).



**Rubrics related with Carcinoma of tongue in various repertories-**

1	Clarke J. H., Clinical Repertory (English) - Clinical - T - tongue - cancer of	3
2	Choudhury H., Hints for Treatment of Cancer - CANCER OF - tongue	34
3	MOUTH - Tongue - aphthae (cancer)	6
4	MOUTH - Tongue - cancer	10
5	T - Tongue - cancer	2
6	TONGUE - Eruptions, growths - Cancer	14
7	MOUTH - CANCER - Tongue	44
8	MOUTH - CANCER - Tongue - accompanied by - atrophy of tongue	2
9	MOUTH - CANCER - Tongue - accompanied by - atrophy of tongue and speaking with a thick hoarse voice	1
10	GENERALS - CANCEROUS affections - epithelioma - accompanied by - Tongue - indented tongue	1
11	GENERALS - CANCEROUS affections - epithelioma - accompanied by - Tongue - purple discoloration of the tongue	1

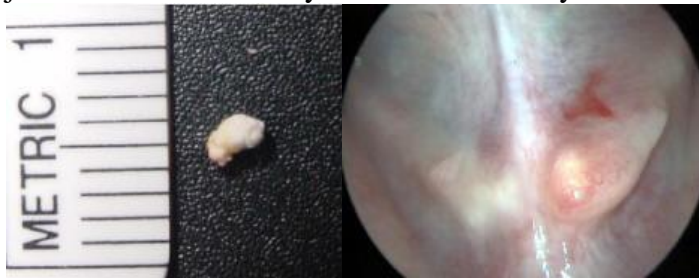**Repertorization-**

mur-ac.	kali-m.	kali-cy.	sulph.	ars.	crot-h.	aur.	thuj.	sil.	kali-chl.
1469	1000	930	800	550	500	469	430	419	400

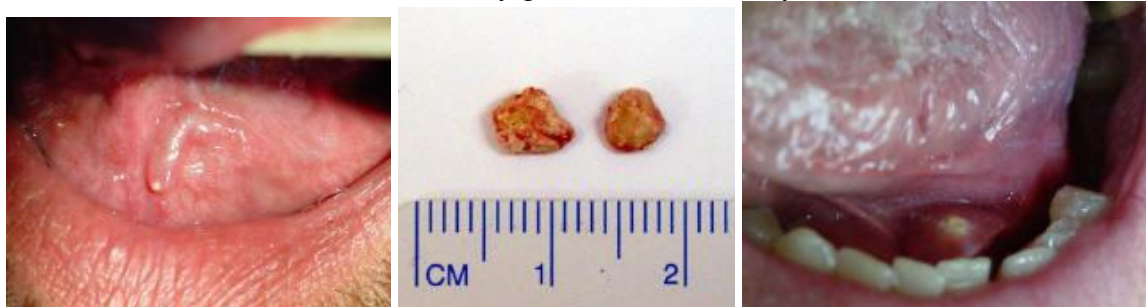**Salivary Gland Stone**

This patient had a stone (Psora/ Sycosis) which formed in the Submandibular (Submaxillary) Gland Duct.

The picture below shows the duct's papilla in the floor of the mouth, underneath the patient's tongue. This duct drains uphill, is wide and has a mucoid or viscous secretion (Psora/ Sycosis). Thus, when salivary gland stones occur, they usually occur in this duct. Prevention is with hydration, gland massage and using a few drop of sour lemon juice several times a day to increase salivary flow.



The following picture on left is from a patient who has a small salivary gland stone in its duct. Note the dilatation of the salivary gland duct (Psora/ Sycosis).

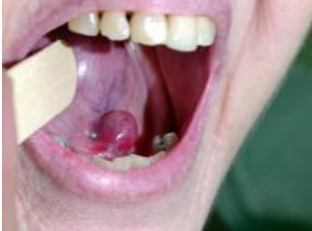

The pictures above on middle and right show a patient with severe sialolithiasis (salivary

gland stones) (Psora/ Sycosis). One of the stones has eroded through the floor of the mouth. Two stones were recovered with a third still in the duct. This patient had a long history of recurrent salivary gland swelling and infection.

### Sialocele

A sialocele arises from the blockage of a salivary gland duct. The duct enlarges and forms a sac of saliva (Psora/ Sycosis).



### Rubrics related with Salivary Gland Lesions in various repertories-

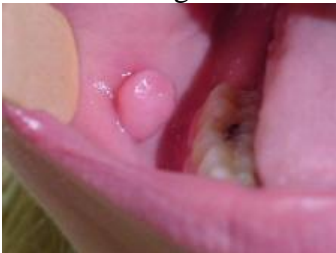1	MOUTH - Glands, salivary	31
2	MOUTH - Swelled - salivary glands	2
3	MOUTH - Throat (and gullet) - contracted - salivary glands	1
4	S - Salivary glands	7
5	MOUTH - Inner mouth - Glands, salivary cellular tissue inflamed	5
6	FACE - COMPLAINTS of face - Salivary glands	1
7	FACE - INFLAMMATION - Parotid glands - mumps - accompanied by - salivation	3
8	FACE - SWELLING - Submaxillary glands - salivation; with	1
9	MOUTH - COMPLAINTS of mouth - Salivary glands	33
10	MOUTH - CONTRACTION - Salivary glands	2
11	MOUTH - INFLAMMATION - Salivary glands	7
12	MOUTH - PAIN - Salivary glands	3
13	MOUTH - SWELLING - Salivary glands	5
14	MOUTH - ULCERS - yellow - Orifice of salivary glands, at	3
15	MOUTH - ULCERS - Salivary glands	1

### Repertorization-

merc.	iris	acon.	thuj.	brom.	mur-ac.	calc-f.	cham.	iod.	phyt.
1925	500	400	400	350	350	325	325	325	325

### Oral Fibroma

This is a benign lesion in a young patient (Psora/ Sycosis).



### Rubrics related with Oral fibroma in various repertories-

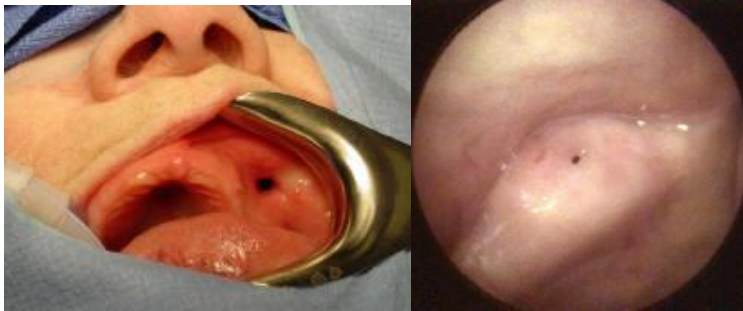1	Clarke J. H., Clinical Repertory (English) - Clinical - F - fibroma	14
2	SKIN - Fibroma	7

### Repertorization-

sec.	lyc.	con.	iod.	hydrinin- m.	kali-i.	sil.	calc-ar.	kali-br.	lap-a.
225	200	150	150	125	125	125	100	100	100

### Oral-Maxillary Fistula

In this condition, a hole (fistula) (Psora/ Syphilis) develops between the mouth and the large sinus cavity above the palate (roof of the mouth). This condition can be caused by dental infections or a complication of surgery.



The patient shown above right has a small hole in the middle of a tooth socket. A tooth had been pulled and a hole was made into the maxillary sinus. The hole did not fully heal and a small fistula was left in the middle of the upper alveolar ridge.

### Rubrics related with Oral Fistula in various repertories-

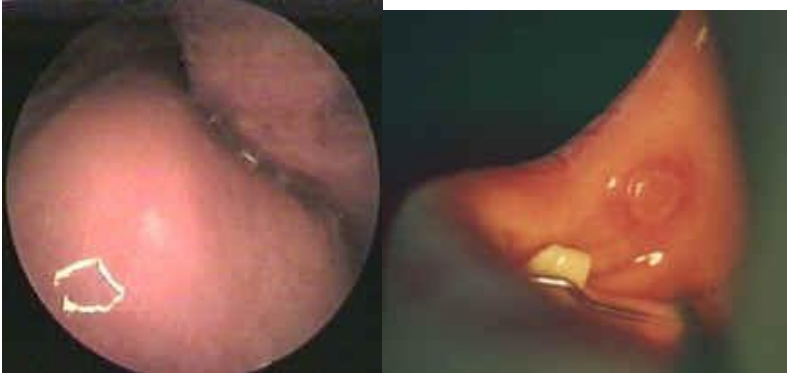1	MOOUTH - FISTULA - salivary fistula	1
2	GENERALS - FISTULAE - abscess; fistulous	2
3	GENERALS - FISTULAE	53
4	SKIN - ULCERS - fistulous	60
5	FACE - INFLAMMATION - Parotid glands - fistula; with	1
6	GENERALITIES - Fistulae	11
7	F - FISTULAE	11
8	T - Teeth - fistula	4
9	O - Operations, surgical; after - fistula; after	1
10	F - Fistula	20
11	BONES - Fistula, as of	5
12	TEETH - Gums - fistula	13
13	Clarke J. H., Clinical Repertory (English) - Causation - operations - for fistula xxx	1
14	Clarke J. H., Clinical Repertory (English) - Causation - fistula, operation for	1
15	Clarke J. H., Clinical Repertory (English) - Clinical - F - fistulous abscess	1
16	Clarke J. H., Clinical Repertory (English) - Clinical - F - fistula	26
17	Clarke J. H., Clinical Repertory (English) - Clinical - D - dental fistula	3

### Repertorization-

sil.	caust.	calc.	nit-ac.	sulph.	calc-s.	phos.	fl-ac.	calc-f.	lyc.
1720	1239	1155	1039	1005	1000	965	950	850	805

## Aphthosis Ulcers

Aphthosis ulcers are shallow small painful ulcers (Psora/ Syphilis) which appear on mobile mucosa in the oral cavity. They are often found in individuals that are under stress. The cause of these ulcers is unknown.



### Rubrics related with Aphthous ulcers in various repertories-

1	MOUTH AND THROAT - Ulcers, aphthae, etc.	12
2	MOUTH - APHTHAE - Tongue - ulcers; forming	1
3	MOUTH - STOMATITIS, ulcerative - accompanied by - Tongue - aphthae on	1
4	Clarke J. H., Clinical Repertory (English) - Clinical - A - aphthae	22
5	Clarke J. H., Clinical Repertory (English) - Clinical - M - mouth - aphthae	1
6	MOUTH - Aphthae	42
7	MOUTH - Palate - Aphthae hard palate	3
8	MOUTH - Throat (and gullet) - aphthae	2
9	MOUTH - Tongue - aphthae (cancer)	6
10	P - Palate - aphthae	4
11	T - Tongue - aphthae	7
12	T - Tongue - edges, of - aphthae	1
13	MOUTH - Palate - Aphthae	1
14	TONGUE - Aphthae	5
15	MIND - SENSITIVE - noise, to - aphthae; with	1
16	EYE - COMPLAINTS of eyes - accompanied by - Mouth; aphthae	1
17	MOUTH - APHTHAE	177
18	MOUTH - APHTHAE - Tongue - large aphthae	1
19	MOUTH - CRACKED - Tongue fissured - accompanied by - aphthae	1
20	MOUTH - SPEECH - difficult - accompanied by - Tongue - aphthae	1
21	THROAT - APHTHAE	20
22	THROAT - DIPHTHERIA - accompanied by - Tongue - aphthae	1
23	CHEST - PHTHISIS pulmonalis - incipient - accompanied by - Tongue; aphthae on	3
24	FEVER - TYPHUS FEVER - accompanied by - Tongue - aphthae on tongue	3
25	GENERALS - APHTHAE	25

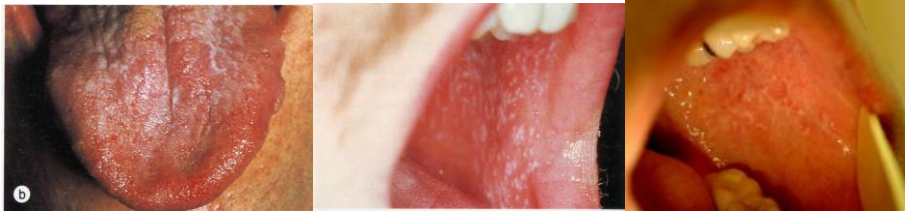### Repertorization-

borx.	sulph.	mur-ac.	nat-m.	spong.	merc.	kali-chl.	ars.	kali-bi.	sul-ac.
2435	1525	1055	989	925	860	825	730	719	709



**Lichen Planus**

This condition presents as a white lace like pattern (Psora/ Sycosis) on the inside of the cheeks. Often the condition is caused by a reaction to medications. Beta Blockers and oral hypoglycemics are the most common offending medications. Lichen Planus can also be associated with other conditions such as Hepatitis C.



**Rubrics related with Oral Lichen Planus in various repertories-**

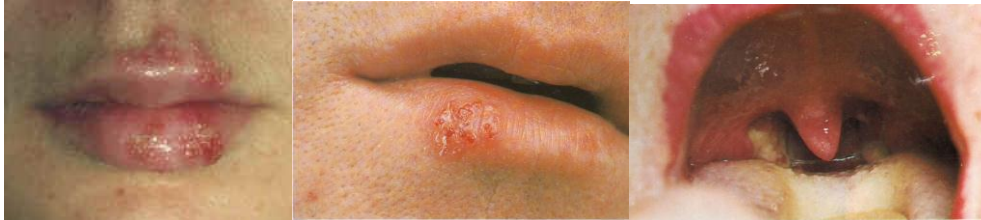1	Clarke J. H., Clinical Repertory (English) - Clinical - L - lichen - planus	1
2	MOUTH - ULCERS - Cheeks - Inside - lichen planus	4

**Repertorization-**

borx.	fl-ac.	merc.	nit-ac.	sul-i.					
100	100	100	100	100					

**Cold Sores**

Cold sores (Psora/ Syphilis) are caused by the Herpes Simplex Virus. Once infected, they plague the patient for life.



**Rubrics related with Cold sores in various repertories-**

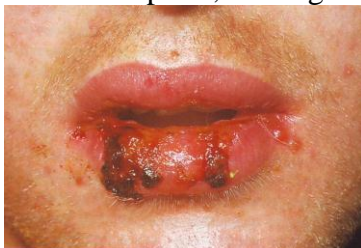1	C - Cold - sores	6
2	MOUTH - Lips - Cold sores, herpes, hydroa	14
3	FACE - Lips - vesicles, cold sores, etc.	5

**Repertorization-**

nat-m.	rhus-t.	ars.	sep.	hep.	phos.	caps.	agar.	calc-f.	dulc.
1125	444	419	325	200	200	125	100	100	100

**Erythema multiforme**

It is an acute eruption of macules, papules, or subdermal vesicles presenting a multiform appearance, the characteristic lesion being the target or iris lesion over the dorsal aspect of the hands and forearms; its origin may be allergic, seasonal, or from drug sensitivity, and the eruption, although usually self-limited (e.g., multiforme minor).



It may be recurrent or may run a severe course, sometimes with fatal termination. Sometimes, it may affect labial mucosa too.

**Rubrics related with Erythema multiforme in various repertories-**

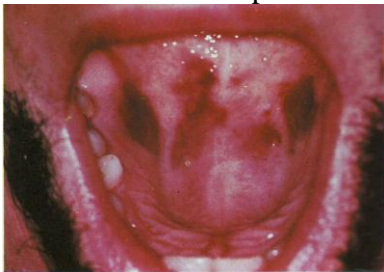1	Clarke J. H., Clinical Repertory (English) - Clinical - E - erythema	11
2	Clarke J. H., Clinical Repertory (English) - Clinical - F - face - erythema of	1
3	MOUTH - Throat (and gullet) - erythema in	1
4	E - Eruptions; tendency to - erythematous	3
5	FACE - Eruptions on face - Erythema	7
6	SKIN - Erythema - Erythema multiforme	4
7	SKIN - Eruptions; tendency to - erythematous	3
8	FACE - DISCOLORATION - red - erythema	9
9	FACE - ERUPTIONS - red - Cheeks - erythema	1
10	FACE - ERUPTIONS - red - Chin - erythema	1
11	FACE - ERUPTIONS - red - Lips; upper - erythema	1
12	THROAT - ERUPTIONS - erythema	1

**Repertorization-**

bell.	graph.	antip.	ars-i.	ars.	bor-ac.	cund.	echi.	euph.	kali-bi.
480	350	200	200	200	200	200	200	200	200

**Kaposi Sarcoma**

It is a multifocal malignant neoplasm of primitive vasoformative tissue, occurring in the skin and sometimes in lymph nodes or viscera, consisting of spindle cells and irregular small vascular spaces frequently infiltrated by hemosiderin-pigmented macrophages and extravasated red cells; clinically manifested by cutaneous lesions consisting of reddish-purple to dark blue macules, plaques, or nodules; seen most commonly in men over 60 years of age and as an opportunistic disease in AIDS patients. The figure below shows involvement of the palate in a homosexually active man.



**Rubrics related with Kaposi's Sarcoma in various repertories-**

1	GENERALS - CANCEROUS affections - sarcoma - Kaposi sarcoma	7
---	--	---

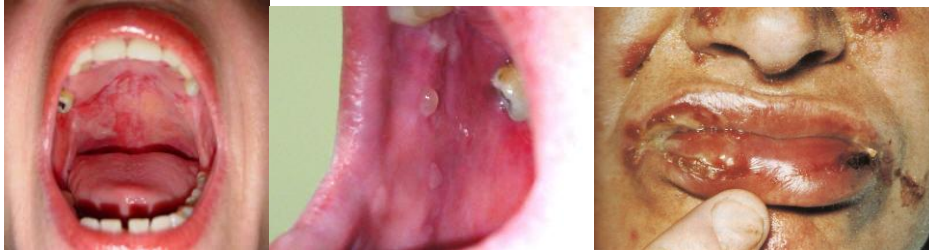**Repertorization-**

aur.	calc-f.	fl-ac.	med.	nit-ac.	syph.	thuj.			
100	100	100	100	100	100	100			

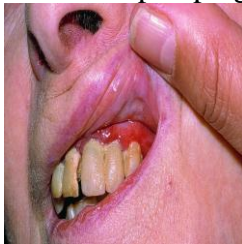**Pemphigoid**

Bullous pemphigoid is an auto-immune disease which causes blistering of the skin (Psora/ Sycosis). It can involve the mucous membranes in 10% to 25% of patients. Blisters form when antibodies attack proteins (Psora/ Syphilis) in the basement membrane of the skin (between the dermis and epidermis). Many cases are self limited and go into remission in five years or less. However, severe cases may require treatment.

Pemphigoid should not be confused with Pemphigus Vulgaris which is a much more aggressive disease. In Pemphigus Vulgaris antibodies attack proteins (Psora/ Syphilis) called desmogleins. Desmogleins are the proteins which hold the skin together. Diagnosis of Pemphigoid and Pemphigus requires biopsy.



The picture below shows Erosive gingivitis in a patient with epidermolysis bullosa acquisita. This is clinically indistinguishable from the gingivitis that may occur in cicatricial pemphigoid.



**Rubrics related with Pemphigoid in various repertories-**

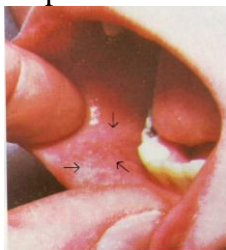
1	Clarke J. H., Clinical Repertory (English) - Clinical - P - pemphigus	15
2	E - Eruptions; tendency to - pemphigus	10
3	MOUTH - ERUPTIONS - pemphigus	1

**Repertorization-**

rhus-t.	dulc.	ran-b.	ran-s.	merc-c.	arum-t.	hep.	anac.	ars.	bufo
254	225	200	200	129	125	125	100	100	100

**Measles (Rubeola)**

It is an acute exanthematous disease, caused by measles virus, a member of the family *Paramyxoviridae*, and marked by fever and other constitutional disturbances, a catarrhal inflammation of the respiratory mucous membranes, and a generalized maculopapular eruption of a dusky red color.



The eruption occurs early on the buccal mucous membrane in the form of Koplik's spots, under spot, a manifestation utilized in early diagnosis.

**Rubrics related with Oral Complications of Measles in various repertories-**

1	Sudarshan S. R., Repertory of non malarial fevers - PATHOLOGICAL TYPES - measles - gangrene of mouth, vulva	3
---	---	---



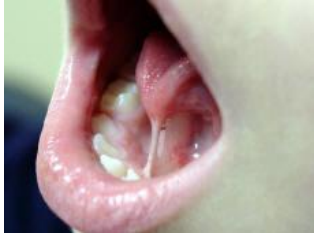2	Sudarshan S. R., Repertory of non malarial fevers - CONCOMITANTS TO FEVER - mouth - salivation - measles in	1
3	MOUTH - Throat (and gullet) - sore throat - measles, during	1
4	FEVER - Rubeola, measles - Concomitants - Gangrene of mouth, vulva	3
5	MOUTH - GANGRENOUS - accompanied by - measles	3
6	MOUTH - MEASLES; during	1
7	THROAT - DIPHTHERIA - accompanied by - measles	2
8	THROAT - PAIN - chronic - measles; during	1

**Repertorization-**

carb-v.	lach.	ars.	kali-chl.	merc-cy.	nat-m.				
1800	400	300	300	100	100				

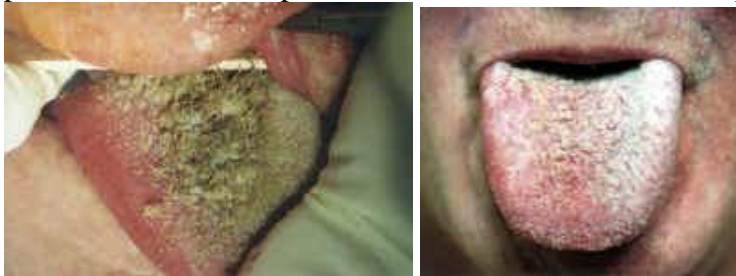**Ankyloglossia**

It is a persistent lingual frenulum (Syphilis/ Sycosis) is a congenital persistence of tissue which binds the tongue to the floor of the mouth. When severe, the frenulum should be cut to mobilize the tongue.

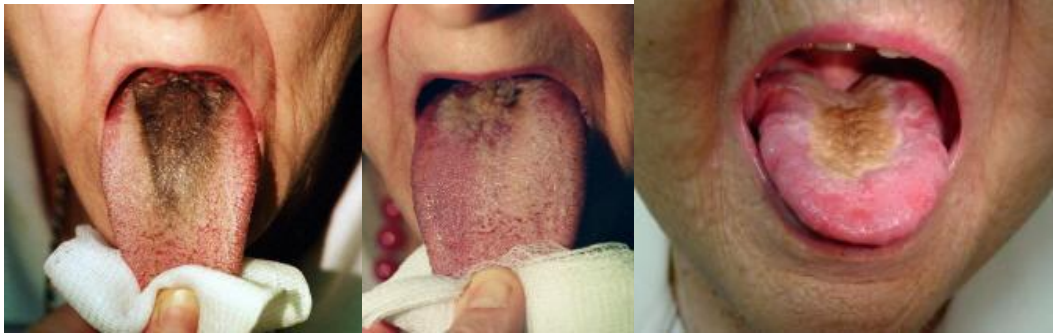

**Hairy Tongue**

This is a relatively rare condition which is caused by the elongation of the taste buds (Psora). This condition can be caused by poor oral hygiene (Psora), chronic oral irritation (Psora) or smoking (Psora). The below left photograph shows a patient who has been treated with radiation therapy for head and neck cancer and has chronic oral inflammation (Sycosis). Treatment will involve good oral hygiene, brushing of the tongue, mouth rinses and sometimes the trimming of the elongated papilla. The right picture is the same patient two months later after improvement in his oral hygiene.



Another patient with a Black Hairy Tongue- This patient had significant gastroesophageal reflux (Psora). Control of her reflux and brushing of her tongue resulted in a marked improvement in her condition. The pre-treatment picture is the picture on the left. The patient's tongue two months post treatment is shown on the right.



The patient shown above right has a combination of a geographic and hairy tongue (Psora/ Sycosis). This condition did not produce any symptoms.

**Rubrics related with Hairy tongue in various repertories-**

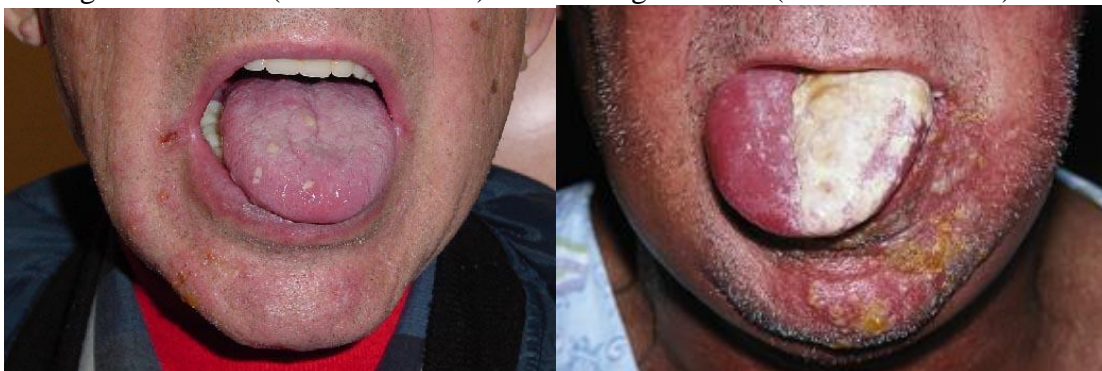1	T - Tongue - hair, on	5
2	Throat - Hair - on back part of tongue and velum	1
3	MOUTH - HAIRY tongue	1

**Repertorization-**

kali-bi.	sil.	all-s.	chloram.	nat-m.	nat-p.				
2	2	1	1	1	1				

**Shingles (Herpes Zoster)**

Shingles are caused by the Herpes Zoster Virus. They occur many years after an individual has had chicken pox (Psora). Once an individual has had chicken pox, he/she will carry, for life, the virus in a dormant state (Suppressed Psora) in the cell bodies of nerve tissue. Over the years, a patient's antibody levels fall (Syphilis) and the dormant virus emerges (Active Psora). The virus causes lesions to erupt on the skin (Psora) in which the nerve innervates. In the following picture on left, the lesions are seen on the patient's right jaw and right half of his tongue. This corresponds to the lower division of the trigeminal nerve (V cranial nerve) and the lingual nerve (XII cranial nerve).



In above figure on right, is shown Herpes zoster affecting the third division of the fifth cranial (trigeminal) nerve, including the lingual nerve, in an elderly patient, showing necrotic tissue.

**Rubrics related with Shingles in various repertories-**

1	FACE - Herpes and tetter - mouth, about	2
2	M - Mouth - herpes in, after sea-bathing	1
3	MOUTH - Lips - Cold sores, herpes, hydroa	14

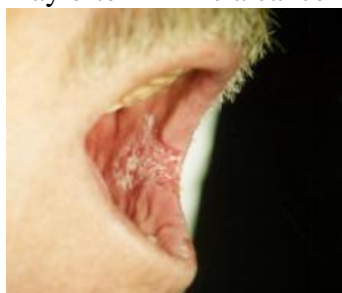4	MOUTH - ERUPTIONS - herpes	6
5	MOUTH - ERUPTIONS - vesicles - herpetic	1
6	MOUTH - ULCERS - herpetic	2
7	MOUTH - ULCERS - painless - eruptions on face; after suppressed brown herpetic	1

**Repertorization-**

nat-m.	cit-ac.	caps.	rhus-t.	sep.	agar.	ars-s-f.	ars.	bell-p.	borx.
825	200	125	125	125	100	100	100	100	100

**Leukoplakia**

It is a white patch in the oral cavity. It is often caused by chronic irritation (Psora) or infection but may also be a cancer (Psora/ Sycosis/ Syphilis). In this patient the leukoplakia has areas of redness called erythroplakia (Psora/ Syphilis). Erythroplakia more often represents a cancer (Psora/ Sycosis/ Syphilis). On biopsy, the patient was found to have a fungal infection (Psora/ Syphilis). Fungal infections of the oral cavity may often mimic a cancer both on gross appearance and sometimes even histologically.



**Rubrics related with Leukoplakia in various repertories-**

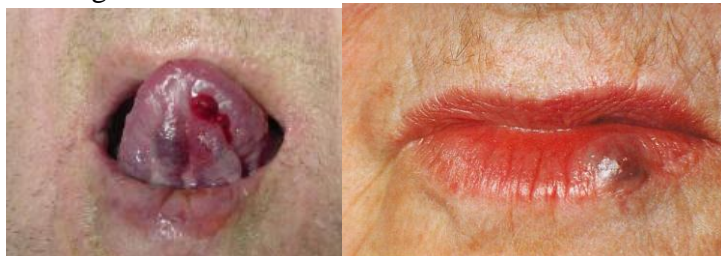1	MOUTH - LEUKOPLAKIA	3
---	---------------------	---

**Repertorization-**

borx.	ign.	nit-ac.							
100	100	100							

**Lingual Cavernous Hemangioma**

This is a benign lesion but one which is very hard (Psora/ Sycosis) to treat. Surgery is difficult. Angiography is often needed to outline the feeding vessels and to embolize the hemangioma.



**Rubrics related with Oral Hemangioma in various repertories-**

1	G - Growths new, tumours etc - angioma	3
2	THROAT - ERUPTIONS - angioneurotic edema	1
3	SKIN - ERUPTIONS - angioma	2
4	SKIN - SPIDER angioma	2

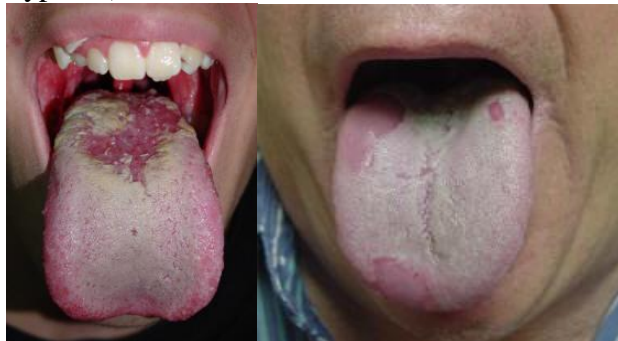5	GENERALS - TUMORS - angioma	41
6	GENERALS - TUMORS - hemangioma	8

**Repertorization-**

apis	lyc.	sulph.	abrot.	lach.	fl-ac.	vanad.	ars.	carb-an.	phos.
800	320	320	300	229	200	200	129	129	129

**Geographic Tongue**

This is a benign non-painful condition (Psora/ Syphilis) caused by the absence of taste bud papilla. The glassy patches move around the tongue and change shape (Psora/ Syphilis). The cause of this condition is unknown.



To the left above is a picture of a hairy and geographic tongue in an 18 yr old male.

**Rubrics related with Geographic Tongue in various repertories-**

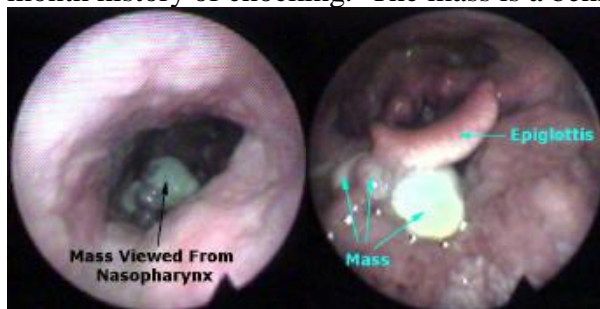1	Clarke J. H., Clinical Repertory (English) - Clinical - T - tongue - mapped	3
2	MOUTH - Tongue - patchy, mapped	35
3	T - Tongue - patchy, mapped, spots	15
4	TONGUE - Coating, color - Mapped	13
5	TONGUE - Patchy, mapped, spots, etc.	13
6	MIND - EXCITEMENT - tongue - mapped; with	2
7	MOUTH - MAPPED tongue	50
8	THROAT - DIPHTHERIA - accompanied by - Tongue - mapped tongue	1
9	FEMALE GENITALIA/SEX - MENSES - absent - accompanied by - Tongue - mapped tongue	1

**Repertorization-**

nat-m.	ars.	tarax.	ran-s.	merc.	kali-bi.	nit-ac.	rhus-t.	lach.	merc-c.
2145	800	795	714	694	600	575	575	539	469

**Mass on Base of Tongue**

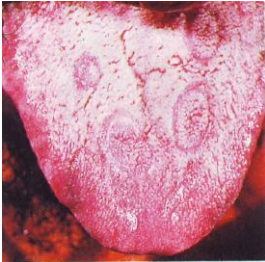This mushroom like mass (Psora/ Sycosis) presented on a 40 year old female with a one month history of choking. The mass is a benign vascular tumor (Psora/ Sycosis).





## Secondary Syphilis

It is an acute and chronic infectious disease caused by *Treponema pallidum* and transmitted by direct contact, usually through sexual intercourse. After an incubation period of 12 to 30 days, the first symptom is a chancre, followed by slight fever and other constitutional symptoms (*primary syphilis*), followed by a skin eruption of various appearances with mucous patches and generalized lymphadenopathy (*secondary syphilis*), and subsequently by the formation of gummas, cellular infiltration, and functional abnormalities usually resulting from cardiovascular and central nervous system lesions (*tertiary syphilis*).



The figure above shows mucous patches involving the tongue in secondary syphilis

### Rubrics related with Syphilis in various repertories-

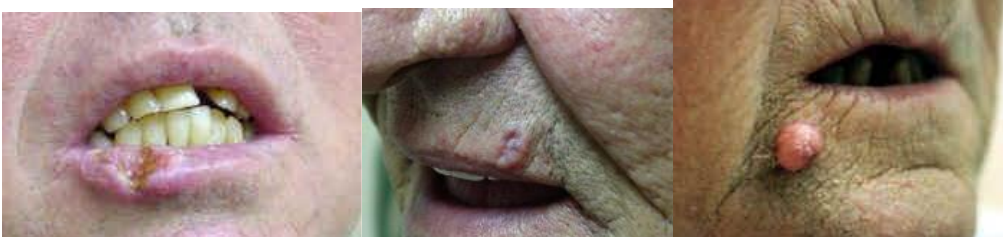1	MOUTH - Throat (and gullet) - syphilitic of	9
2	MOUTH - Ulcerations - Syphilitic mucous patches	9
3	MOUTH - PATCHES, syphilitic	16
4	MOUTH - STOMATITIS, ulcerative - syphilitic	1
5	MOUTH - ULCERS - syphilitic	22
6	MOUTH - ULCERS - Palate - syphilitic	9
7	MOUTH - ULCERS - Tongue - syphilitic	10

### Repertorization-

merc.	nit-ac.	kali-bi.	lach.	aur.	thuj.	kali-i.	syph.	merc-c.	cinnb.
1515	979	659	590	580	564	540	390	385	359

## Lip Cancer

Cancer of the lip (Psora/ Sycosis/ Syphilis) is a relatively common condition. Cancers of the lower lip have a better prognosis than those of the upper lip. Chronic sun exposure (Psora) is the most common cause, but smoking (Psora) can also be an etiology. The picture below left shows a T2 N0 (tumor size between 2 to 4 cm, with no lymph node spread) squamous cell carcinoma (Psora/ Sycosis/ Syphilis) of the lower lip.



Above middle and right patients have a basal cell carcinoma lip cancer (Psora/ Sycosis/ Syphilis). It is a less aggressive tumor than squamous cell carcinoma. Basal Cell Carcinoma spread and destroy tissue locally (Sycosis/ Syphilis), but do not metastasize (Psora) (spread by blood or lymphatics).

**Rubrics related with Lip Cancer in various repertories-**

1	Clarke J. H., Clinical Repertory (English) - Clinical - C - cancer - lip, of	4
2	Clarke J. H., Clinical Repertory (English) - Clinical - E - epithelioma - lip, of	2
3	Clarke J. H., Clinical Repertory (English) - Temperaments - lips, pallor of	1
4	Clarke J. H., Clinical Repertory (English) - Temperaments - pallor - lips of	1
5	Choudhury H., Hints for Treatment of Cancer - CANCER OF - lips	11
6	Choudhury H., Hints for Treatment of Cancer - CANCER OF - lower lips	17
7	Choudhury H., Hints for Treatment of Cancer - CANCER OF - lips due to pressure of pipe	2
8	Choudhury H., Hints for Treatment of Cancer - CANCER OF - lips due to smoking	1
9	Pulford A. and T. D., Repertory of Pneumonia - FACE - sordes on lips	2
10	FACE - Muscles - drawn - of lips	6
11	FACE - Sweat on - upper lip, on	4
12	FACE - Lips - lips	74
13	TEETH - Concomitants - lips, swelled	2
14	THIRST - Thirstlessness - dryness, with - of lips	10
15	SWEAT - Partial sweat - partial sweat - upper lip	7
16	F - Face - pain, neuralgia, prosopalgia, aching - lips, from	1
17	L - Licking - lips agg	1
18	L - Lips	9
19	N - Nausea - lips, touching on	2
20	MOUTH - Lips - Cracks, ulcerations - in middle of lower lip	6
21	FACE - Lips	9
22	FACE - Eruption - lips; about	3
23	FACE - ABSCESS - Lip	1
24	FACE - APHTHAE - Lips; on	22
25	FACE - BLEEDING of lips	36
26	FACE - BLEEDING of lips - Lower lips	2
27	FACE - BLEEDING of lips - Upper lips	1
28	FACE - BLOATED - Lips	2
29	FACE - BURNT look - Lips	2
30	FACE - BURNT; sensation as if - Lips	2
31	FACE - CANCER - epithelioma - Lips	17
32	FACE - CANCER - scirrhous - Lips	2
33	FACE - CANCER - Lips	35
34	FACE - CHAPPED - Lips	53
35	FACE - COLDNESS - Lips	11
36	FACE - COMPLAINTS of face - Lips	76
37	FACE - CONTRACTION - sensation of - Lips	1
38	FACE - CONTRACTION - Lips	5
39	FACE - CRACKED - Lips	156
40	FACE - DISCOLORATION - black - Lips	31
41	FACE - DISCOLORATION - bluish - purple - Lips	5
42	FACE - DISCOLORATION - bluish - purple-red - Lips	1

43	FACE - DISCOLORATION - bluish - Lips	97
44	FACE - DISCOLORATION - brown - Lips	17
45	FACE - DISCOLORATION - brown - Lips - spots - Upper lip	3
46	FACE - DISCOLORATION - brown - Lips - streak - Lower lip; along	1
47	FACE - DISCOLORATION - changing color - Lips	1
48	FACE - DISCOLORATION - cyanotic - Lips	3
49	FACE - DISCOLORATION - livid - Lips	1
50	FACE - DISCOLORATION - mottled - Lips	1
51	FACE - DISCOLORATION - pale - Lips	44
52	FACE - DISCOLORATION - red - bluish red - Lips	1
53	FACE - DISCOLORATION - red - Lips	43
54	FACE - DISCOLORATION - red - Lips - Lower - spots - Below - right lip	1
55	FACE - DISCOLORATION - red - Lips - Upper - spot - Above the upper lip red	1
56	FACE - DISCOLORATION - white - powdery - Lips	1
57	FACE - DISCOLORATION - white - Lips	2
58	FACE - DISCOLORATION - yellow - Lips	4
59	FACE - DISTORTION - Lips	7
60	FACE - DRAWN - Lips	14
61	FACE - DROPPING - Lips	3
62	FACE - DRYNESS - Lips	215
63	FACE - ERUPTIONS - blotches - Lips	12
64	FACE - ERUPTIONS - boils - Lips	4
65	FACE - ERUPTIONS - burning - Lips	15
66	FACE - ERUPTIONS - comedones - Chin - and upper lip	1
67	FACE - ERUPTIONS - comedones - Lips; upper	1
68	FACE - ERUPTIONS - crusty, scabby - Lips	30
69	FACE - ERUPTIONS - crusty, scabby - Nose - extending to - Down lip with deep fissure, very sore and sensitive to touch	1
70	FACE - ERUPTIONS - painful - Lip; upper	1
71	FACE - ERUPTIONS - papular - Lip, upper	2
72	FACE - ERUPTIONS - pimples - Lips	48
73	FACE - ERUPTIONS - pustules - Lips	17
74	FACE - ERUPTIONS - rough - Lips	4
75	FACE - ERUPTIONS - Lips	104
76	FACE - EVERTED lips	6
77	FACE - EXCORIATION - Lips	37
78	FACE - FORMICATION - Lips	15
79	FACE - FORMICATION - Lips - bugs running over lips; as if	2
80	FACE - FROTHY - Lips	2
81	FACE - GREASY - Lips	1
82	FACE - HANGING down - Lips	1
83	FACE - HEAT - Lips	59
84	FACE - HEAVY feeling - Lips	3
85	FACE - INDURATIONS - Lips	20
86	FACE - INDURATIONS - Lips - Fold of lips	1

87	FACE - INFLAMMATION - Lips	13
88	FACE - INVERTED lips	2
89	FACE - ITCHING - Lips	28
90	FACE - ITCHING - Lips - Margins of lips	1
91	FACE - LEATHER; like - Lips	1
92	FACE - LICKING - lips	17
93	FACE - MEMBRANE on - Lips	3
94	FACE - MUCUS - Lips	8
95	FACE - NODOSITIES - Lips	8
96	FACE - NUMBNESS - Lips	22
97	FACE - NUMBNESS - Lips - Upper - extending to - Lower lip	1
98	FACE - PAIN - Chin - Between the chin and lower lip	1
99	FACE - PAIN - Lips	112
100	FACE - PEELING off of lips	51
101	FACE - PICKING - Lips	23
102	FACE - POINTED - Lips	1
103	FACE - PULSATION - Lips	3
104	FACE - QUIVERING - Lips	8
105	FACE - RETRACTION of lips	10
106	FACE - SENSITIVE - Lips	11
107	FACE - SENSUAL - Lips	2
108	FACE - SHINY - Lips	3
109	FACE - SHRIVELLED - Lips	11
110	FACE - SLIMY lips	4
111	FACE - SMACKING lips	2
112	FACE - SORDES on the lips	22
113	FACE - STICKING - Lips	11
114	FACE - STICKING - Lips - moisture on lips; sticky	1
115	FACE - STIFFNESS - Lips	9
116	FACE - SWELLING - Lips	102
117	FACE - TENSION of skin - egg white were dried on the face; as if - Lips	2
118	FACE - TENSION of skin - Lips	12
119	FACE - THICK - Lips	13
120	FACE - THIN - Lips	1
121	FACE - TINGLING - Cheeks - and lips	5
122	FACE - TINGLING - Lips	30
123	FACE - TOUCH - agg. - Lips	1
124	FACE - TUMOR - cystic tumor - Lips; on	5
125	FACE - ULCERS - Lips	65
126	FACE - VEINS distended - Lips	4
127	FACE - WARTS - Lips	9
128	FACE - WEAKNESS - Lips; upper	1
129	FACE - WRINKLED - Lips	2
130	MOUTH - CONTRACTION - Tongue - cylindrical - spasmodically forced through lips; which is	1
131	MOUTH - DISCOLORATION - white - bluish white spots - Lips; inside of	1



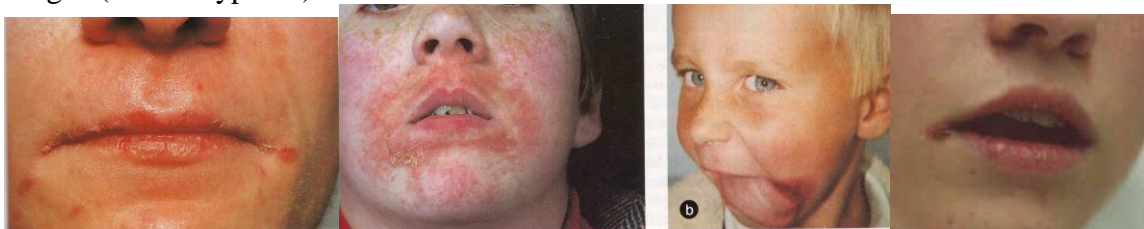132	MOUTH - ERUPTIONS - pimples - Cheeks - Inner - And lips	1
133	MOUTH - ERUPTIONS - pimples - Lips; inner side of	1
134	MOUTH - ERUPTIONS - scabs - Lip; upper	1
135	MOUTH - INDENTED - Lips	1
136	MOUTH - INFLAMMATION - Lips, inside of	1
137	MOUTH - ITCHING - Lip; inside upper	1
138	MOUTH - NUMBNESS - Lip; inside upper	1
139	MOUTH - ROUGHNESS - Lips	8
140	MOUTH - ROUGHNESS - Lips - Lower lip	2
141	MOUTH - ROUGHNESS - Lips - Upper lip	2
142	MOUTH - SALIVA - dries on palate and lips, becomes tough	1
143	MOUTH - SORDES - Lips	10
144	MOUTH - TASTE - altered - licking lips	1
145	MOUTH - TASTE - bitter - Lips	2
146	MOUTH - TASTE - saltish - Lips	4
147	MOUTH - TASTE - salty - Lips	4
148	MOUTH - TASTE - sour - Lips; on	2
149	MOUTH - TASTE - sweetish - Lips	2
150	MOUTH - TUMORS - Lip; inside right side of	1
151	MOUTH - ULCERS - Lips; inner side of	5
152	MOUTH - WETTING lips constantly	1
153	STOMACH - THIRST - accompanied by - Lips; dryness of	6
154	STOMACH - THIRSTLESS - accompanied by - Lips; dryness of	14
155	ABDOMEN - DISTENSION - accompanied by - Lips; thick	1
156	RESPIRATION - COMPLAINTS of respiration - accompanied by - Lips; red discoloration of	1

#### Repertorization-

ars.	sulph.	nat-m.	sep.	apis	con.	merc.	phos.	bell.	bry.
6805	3990	3945	3540	3269	3205	3190	3140	3075	2990

#### Chelitis

This is crusting and cracking which occurs in the corners of the mouth. It is caused by a fungus (Psora/ Syphilis).



#### Rubrics related with Chelitis in various repertories-

1	Clarke J. H., Clinical Repertory (English) - Clinical - L - lips - cracked	2
2	CORYZA - Concomitants - lips - cracked	3
3	FACE - Lips - cracked, fissured, chopped	54
4	L - Lips - upper - cracked	2
5	L - Lips - lower - cracked	1
6	L - Lips - corners - cracked	9

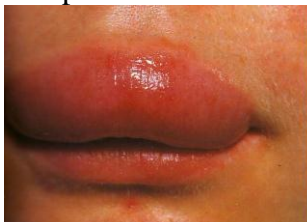7	L - Lips - cracked	22
8	MOUTH - Lips - Cracks, ulcerations	19
9	MOUTH - Lips - Cracks, ulcerations - in middle of lower lip	6
10	FACE - Lips - cracked	8
11	FACE - CRACKED - Lips	156
12	Clarke J. H., Clinical Repertory (English) - Clinical - M - mouth - cracks of	2
13	MOUTH - Throat (and gullet) - cracking, snapping in	5
14	J - Jaws - cracking - mouth, opening wide, on	1
15	M - Mouth - cracked	3
16	T - Throat, including inner mouth - fissures, cracks	4
17	MOUTH - External mouth, commissures in corners - Cracks, ulcerations	17
18	MOUTH AND THROAT - Fissures, cracks	3
19	EAR - NOISES in - cracking - opening the mouth	2
20	FACE - CRACKED - Mouth; corners of	65
21	FACE - CRACKING in articulation of jaw - opening mouth wide; when	4
22	MOUTH - CRACKED	21

#### Repertorization-

graph.	arum-t.	nat-m.	ars.	cham.	cund.	merc.	nit-ac.	bry.	ign.
1569	1309	1210	960	919	829	819	814	780	700

#### Angioedema

It is usually of systemic origin; it may be due to a state of hypersensitivity to foods or drugs, foci of infection, physical agents (heat, cold, light, friction), or psychic stimuli. The picture below shows angioedema of upper lip.



#### Rubrics related with Angioedema in various repertories-

1	FACE - ERUPTIONS - angioedema	1
2	FACE - SWELLING - Lips - angioedema	1
3	THROAT - SWELLING - angioedema	1
4	SKIN - ERUPTIONS - angioedema	14

#### Repertorization-

apis	anac.	agar.	antip.	bacls-7.	bol-lu.	calc-m.	hell.	hep.	kali-i.
1100	179	100	100	100	100	100	100	100	100

#### Conclusion

From above study, we could easily understand some common oral lesions and also see that Homoeopathy has its peculiar role in every oral condition including so called malignancies. There are numerous drugs that may cure certain corresponding lesions by root if prescribed on universal laws of cure adopted only by Homoeopathy.

#### Bibliography-

- A Comparison of the Chronic Miasms, Phillis Speight

- A Dictionary of Practical Materia Medica, Vol. I, II, III, John Henry Clarke
- An Introduction to the Symptoms and Signs of Surgical Diseases, Norman L. Browse
- Clinical Materia Medica, E. A. Farrington
- Clinical Repertory, J. H. Clarke
- Current Medical Diagnosis & Treatment, Lawrence M. Tierney, Stephen J. McPhee
- Davidson's Principles And Practice of Medicine
- Grant's anatomy
- Gray's anatomy
- Handbook of Human Physiology, Dr. Vidyaratana
- Homoeopathy, Introductory Lectures, M. L. Taylor
- How to Take The Case & To Find the Similimum, E. B. Nash
- Human Physiology, Dr. Chandi Charan Chatterjee
- Lectures on Homoeopathic Materia Medica, James Tyler Kent
- Miasmatic Diagnosis, Dr. S. K. Banerjee
- Organon Expositor, Dr. S. D. Sircar
- Organon Of Medicine, At A Glance, Part I & II, Dr. A. C. Gupta
- Organon of Medicine, Samuel Hahnemann
- Pathology, Virginia A. LiVolsi, Maria J. Merino, John S. J. Brooks, Scott H. Saul, John E.
- Pocket Manual of Homoeopathic Materia Medica, William Boericke
- Practice of Medicine, Dr. K. Chaudhury
- Principles of Internal Medicine Vol. I, II, Harrison
- Repertory Of Homoeopathic Materia Medica, J. T. Kent
- Roxburgh's Common Skin Diseases
- Stedman's Medical Dictionary
- Synthetic Repertory, Vols. I, II & III
- Taber's Cyclopedic Medical Dictionary
- Text Book Of Medical Physiology, Guyton
- The Genius of Homoeopathy Stuart Clause
- The Principles & Art of Cure By Homoeopathy, Herberts A. Roberts
- Therapeutic Pointers, E. A. Farrington
- Trauma & Healing Process