



# Cortically Fixed at Once Implants for the Treatment of the Atrophic Maxilla - A Case Report



Jimoh Olubanwo Agbaje<sup>1</sup> and Henri Diederich<sup>2\*</sup>

<sup>1</sup>UCLL Hoge School, Belgium

<sup>2</sup>Dental Clinic Henri Diederich, Luxembourg

Submission: May 17, 2019; Published: July 01, 2019

\*Corresponding author: Henri Diederich, Dental Surgeon, Dental Clinic Henri Diederich, 114 av. de la Faiencerie, L- 1511, Luxembourg

## Abstract

The CF@O, Cortically Fixed at Once, implant system is a recent innovation aimed at the rehabilitation of difficult and failed implant cases within a short period of time without the need for extensive surgical operation. The use of conventional intraosseous implants may be limited or inapplicable in restoring some edentulous spaces due to various anatomical reasons. The Cortically Fixed at Once approach uses the remaining cortical bone to fix specially designed implants. The Implant system consists of several types of components specifically developed for different locations in the jaw. The high fatigue strength of the solid titanium implants (without any welds or added parts) is particularly indicated for mechanically demanding situations (the canine and zygomatic sectors of the maxilla) and the mandibular ramus.

CF@O incorporates the whole range of treatment procedures available to the implantologist, and it is a reliable alternative where there is substantial bone resorption. The use of bone augmentation to enable placement of an enough and length of implants is usually not required with CF@O implants. The presented case report describes steps followed for the functional restoration of an edentulous patient with the CF@O implant system without bone grafts or sinus lift.

**Keywords:** Cortically Fixed at Once implants; Pterygoid implants; Hybrid plates; Atrophied maxilla; Rehabilitation

## Introduction

The CF@O, Cortically Fixed at Once, implant system is a recent innovation aimed at the rehabilitation of difficult and failed implant cases within a short period of time without the need for extensive surgical operation.

A severely atrophied maxilla usually presents limitations for conventional implant placement [1-5] due to various anatomical reasons that limit the use of the conventional implant for restoring edentulous spaces [2,3,6,7]. CF@O uses the concept of tricortical support anchorage where the available residual bone volume is used for support. The challenges of a severely atrophied jaw due to advanced posterior alveolar resorption combined with increased maxillary sinus pneumatization which often leaves insufficient bone for implant anchorage [8] can easily be managed.

CF@O is a reliable alternative where there is substantial bone resorption, and the use of conventional intraosseous implants is limited or inapplicable due to various anatomical reasons [1,7,9]. The implant system incorporates the whole range of treatment procedures and it encourages early loading which ensures that patient edentulism can be taken care of immediately with the restoration of function and aesthetics within a few days [10].

The use of bone augmentation to enable placement of a sufficient number and length of implants is usually not required with CF@O implants<sup>4,5</sup>. Extensive invasive procedures, such as Onlay grafts, free or microvascular bone grafts, transport distraction osteogenesis, apposition grafts with or without a Le Fort I osteotomy with their attendant comorbidity are avoided [11-15].

The Hybrid Plates are made of titanium Grade 2 which makes them thin, lightweight, highly flexible and strong. This characteristic allows the easy adaptability of the CF@O Plates to the jawbone anatomy. The plates are made of one-Piece solid titanium without any welds or added parts, the high fatigue strength of the Hybrid Plate is particularly indicated for mechanically demanding situations such as in the canine and zygomatic region of the maxilla and the mandibular ramus.

The CF@O approach incorporates the whole range of treatment procedures available to the implantologist, and it is a reliable alternative to bone grafts in situations where there is substantial bone resorption. No bone graft and no more sinus lift for the rehabilitation in cases of atrophied maxilla and mandible are needed. The CF@O Implant system consists of several types of components specifically developed for different locations in the jaw.

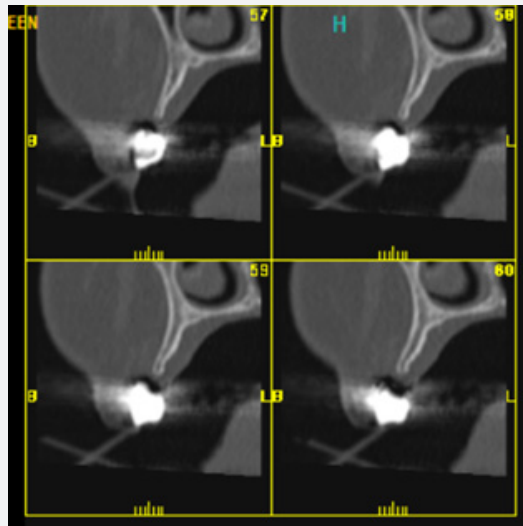
**Case Presentation**

A 53-year-old female patient wanted fixed teeth in the maxilla to replace her bridge of over 25 years. The patient had previously visited many doctors who proposed various treatment options such as sinus lifts or bone graft among others due to the jaw atrophy.

A clinical examination showed an upper arch with a resorbed ridge and few standing teeth, aesthetics was bad, patient had

mouth odour. The lower arch is dentulous with few missing teeth. Radiographic examination using an orthopantomogram showed a dentulous upper jaw with moderate vertical bone resorption in the front and severe vertical resorption in the premolar and molar region.

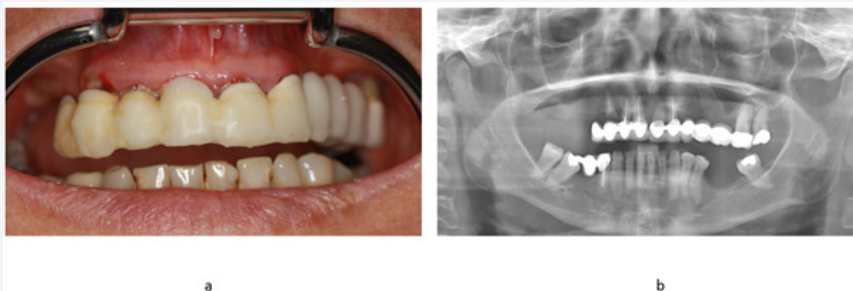
Figure 1 shows the cross section of the Cone Beam CT image of the maxilla. The image is used to estimate the amount of bone present and to view the surrounding structures.



**Figure 1:** Cross section of the Cone Beam CT image of the maxilla.

In the lower jaw, several teeth were present in the frontal region and in the right lateral region. Most of the teeth show a moderate to severe bone loss suggestive of chronic periodontitis.

Figure 2a & 2b show the clinical photograph and the panoramic radiograph of the patient at presentation.



**Figure 2:** The clinical photograph and panoramic radiograph of patient at presentation.

**Treatment plan**

In the upper jaw, a complete tooth extraction was advised. From a prosthetic point of view, the patient desired a fixed prosthetic solution. In the upper jaw, a combination of two pterygoids, five two-piece implants and three Hybrid Plates was proposed. The patient agreed to this treatment plan.

The periodontally involved teeth in the upper jaw were extracted and five two piece-implants from TRATE AG, ROOTT-Implants, 14mm length and 3.5mm diameter were directly placed in the extraction sockets.

An open flap was made from the left tuberosity along the crest till the canine region in the maxilla. The flap was reflected on the vestibular side in positions 26 and 27 of the zygomatic arch; the flap was also reflected in the palate. A Pterygoid implant C35/20mm (ROOTT - implant TRATE AG) was inserted at position 28 with a 50N torque. One Hybrid Plate HENGG-1 (Highly Efficient No Graft Gear) was adapted to the bone anatomy and fixed with osteosynthesis screws on the zygomatic bone at position 26. In the premaxillary region, a Hybrid Plate type HENGG-4 was adapted to the bone and fixed with osteosynthesis screws.

The procedure was quite similar for the right side. A plate HENGG-1 was installed in position 16 and one Pterygoid implant P35/20mm was inserted at the right pterygoid plate Figure 3.

The plate was fixed with osteosynthesis screws and covered with an antibiotic Metronidazole and bone material CerasobR (Figure 4). The configuration of HENGG-4 in form of a cross allows

a special strong fixation in the premaxilla as the bone quality in this region is poor. The flap was then closed on the right and left with polytetrafluoroethylene polymer (PTFE) monofilament absorbable suture. After an implant placement, the transfer coping was inserted, and an open tray impression was taken with silicone immediately after the surgery (Figure 5).

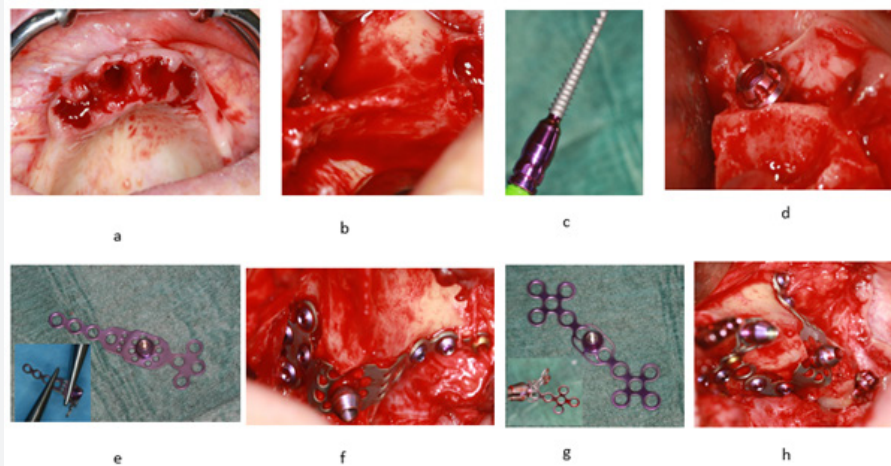


Figure 3: Surgical procedure and implant placement (a-h).

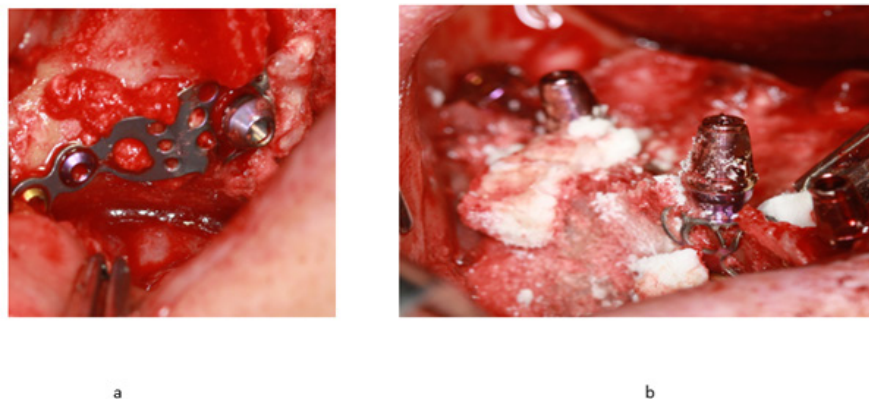


Figure 4: Surgical procedure - Plates covered with antibiotic (Metronidazol) and bone material.

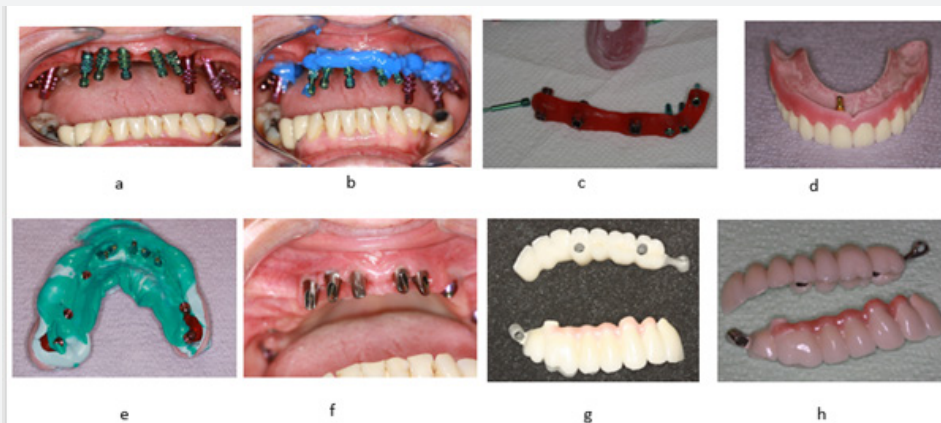
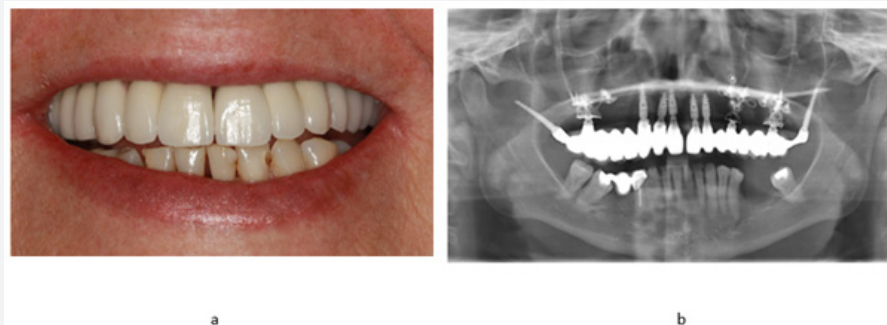


Figure 5: Laboratory steps- Bite registration, impression taken procedure and bridge fabrication.

A temporary resin bridge was made at the chairside and fixed on the maxilla with temporary cement, few days after a temporary bridge from the laboratory was inserted. After four months a definitive impression was done.

Few days after the framework, a try-in was done and a new bite registration was taken. A double impression was done over the future superstructure. A first try in with the future bridges was done, aesthetics and bite were also controlled.



**Figure 6:** Clinical photograph of patient after bridge delivery.

On the following appointment the try-in and prosthesis delivery was done. In the maxilla, the metal ceramic bridge was screwed and cemented with a temporary cement (Figure 6). The patient was reviewed after 2 weeks. Thereafter, patient was scheduled for follow-up at 3 months and then every 6 months.

### Discussion

The presented case report describes steps followed for the functional restoration of an edentulous patient with the CF@O implant system without bone grafts or sinus lift. Due to the above-described technique, the patient could receive in a short time fixed tooth using a minimally invasive procedure. Where traditional implant methods take several months to complete, the CF@O approach achieves the same result in days without the need for additional surgery. The high fatigue strength of the solid titanium implants (without any welds or added parts) is particularly indicated for mechanically demanding situations (the canine and zygomatic sectors of the maxilla) and the mandibular ramus.

The CF@O, Cortically Fixed at Once approach incorporates the whole range of treatment procedures available to the implantologist, and it is a reliable alternative to bone grafts in situations where there is a substantial bone resorption.

### References

1. Ali SA, Karthigeyan S, Deivanai M, Kumar A (2014) Implant rehabilitation for atrophic maxilla: a review. *J Indian Prosthodont Soc* 14(3): 196-207.
2. Bosse LP, Taylor TD (1998) Problems associated with implant rehabilitation of the edentulous maxilla. *Dent Clin North Am* 42(1): 117-127.
3. Candel E, Penarrocha D, Penarrocha M (2012) Rehabilitation of the atrophic posterior maxilla with pterygoid implants: a review. *J Oral Implantol* 38 Spec No: 461-466.
4. Jivraj S, Chee W, Corrado P (2006) Treatment planning of the edentulous maxilla. *Br Dent J* 201(5): 261-279.
5. Sevetz EB Jr (2006) Treatment of the severely atrophic fully edentulous maxilla: the zygoma implant option. *Atlas Oral Maxillofac Surg Clin North Am* 14(1): 121-136.
6. Candel-Martí E, Carrillo-García C, Peñarrocha-Oltra D, Peñarrocha-Diago M (2012) Rehabilitation of atrophic posterior maxilla with zygomatic implants: review. *J Oral Implantol* 38(5): 653-657.
7. Mericske-Stern RD, Taylor TD, Belser U (2000) Management of the edentulous patient. *Clin Oral Implants Res.* 11(Suppl 1): 108-25.
8. Peñarrocha-Oltra D, Candel-Martí E, Ata-Ali J, Peñarrocha-Diago M (2013) Rehabilitation of the atrophic maxilla with tilted implants: review of the literature. *J Oral Implantol* 39(5): 625-632.
9. Belser UC, Buser D, Hess D, Schmid B, Bernard JP, et al. (2000) Aesthetic implant restorations in partially edentulous patients--a critical appraisal. *Periodontol* 17: 132-150.
10. Diederich H, Marques AJ, Soares LG (2017) Immediate Loading of an Atrophied Maxilla Using the Principles of Cortically Fixed Titanium Hybrid Plates. *Advances in Dentistry & Oral Health* 3(3): 001-003.
11. Yaremchuk MJ (1989) Vascularized bone grafts for maxillofacial reconstruction. *Clin Plast Surg* 16(1): 29-39.
12. Sjoström M, Sennerby L, Nilson H, Lundgren S (2007) Reconstruction of the atrophic edentulous maxilla with free iliac crest grafts and implants: a 3-year report of a prospective clinical study. *Clin Implant Dent Relat Res* 9(1): 46-59.
13. Cheung LK, Zhang Q, Zhang ZG, Wong MC (2003) Reconstruction of maxillectomy defect by transport distraction osteogenesis. *Int J Oral Maxillofac Surg* 32(5): 515-522.
14. Nystrom E, Nilson H, Gunne J, Lundgren S (2009) Reconstruction of the atrophic maxilla with interpositional bone grafting/Le Fort I osteotomy and endosteal implants: a 11-16 year follow-up. *Int J Oral Maxillofac Surg* 38(1): 1-6.
15. Ugurlu F, Yildiz C, Sener BC, Sertgoz A (2013) Rehabilitation of posterior maxilla with zygomatic and dental implant after tumor resection: a case report. *Case Rep Dent* 2013: 930345.



This work is licensed under Creative Commons Attribution 4.0 License  
DOI: [10.19080/ADOH.2019.11.555803](https://doi.org/10.19080/ADOH.2019.11.555803)

**Your next submission with Juniper Publishers  
will reach you the below assets**

- Quality Editorial service
- Swift Peer Review
- Reprints availability
- E-prints Service
- Manuscript Podcast for convenient understanding
- Global attainment for your research
- Manuscript accessibility in different formats  
**( Pdf, E-pub, Full Text, Audio)**
- Unceasing customer service

**Track the below URL for one-step submission**  
<https://juniperpublishers.com/online-submission.php>