



Clinical case overview

President of the Open Dental Community in Russia

Dr. Igor Malinovskiy

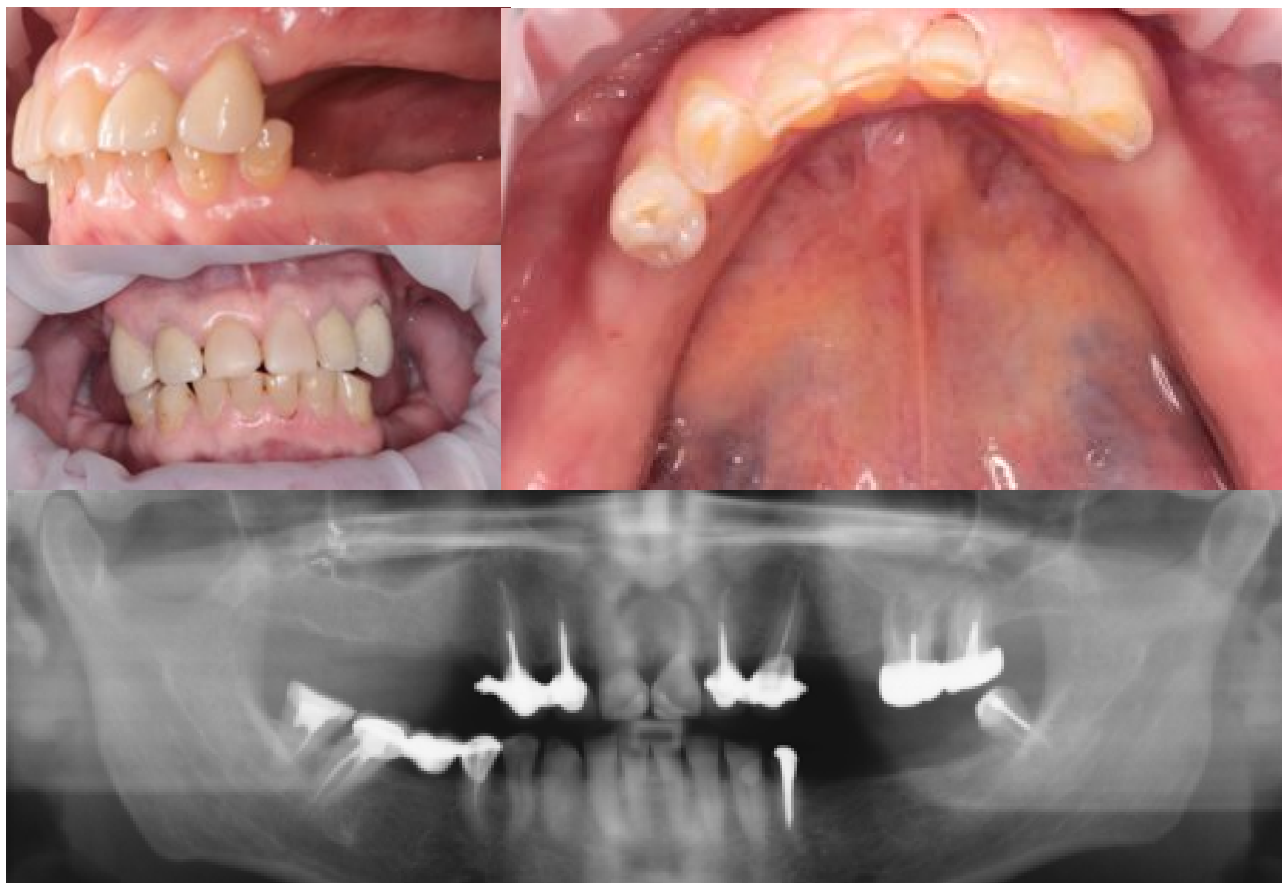THE SPACE FREE OF STEREOTYPES

opdeco.org

Clinical case overview

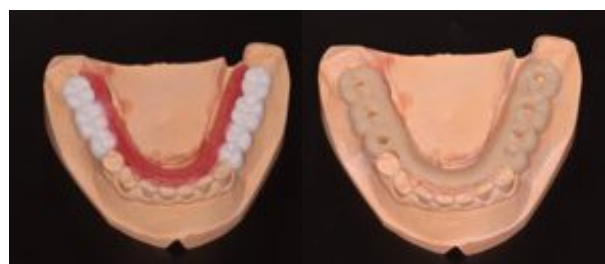Dr. Igor Malinovskiy

Female patient, 56 years old applied to the dental clinic complaining about edentia in the areas 1.4; 1.5; 1.6; 1.7; 2.4; 2.5; 3.5; 3.6; 3.7; 4.6. The patient also complained about feeling of discomfort while using removable dentures, especially in the lower jaw, 2.6; 2.7; 3.4; 4.5; 4.7 teeth mobility and intermittent pain in the areas 3.8 and 4.8.

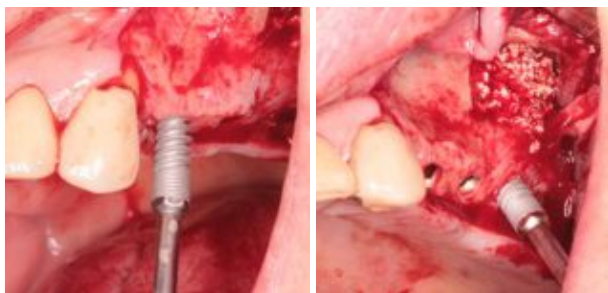


After intraoral examination and radiological examination the following treatment plan was proposed. Preliminary extraction of teeth 2.6; 2.7; 3.4; 4.5; 4.7; 3.8 and 4.8. Bilateral sinus elevation with immediate implant placement in the area 1.4; 1.5; 1.6; 1.7 2.4; 2.5; 2.6; 2.7 using two-stage surgical procedure.

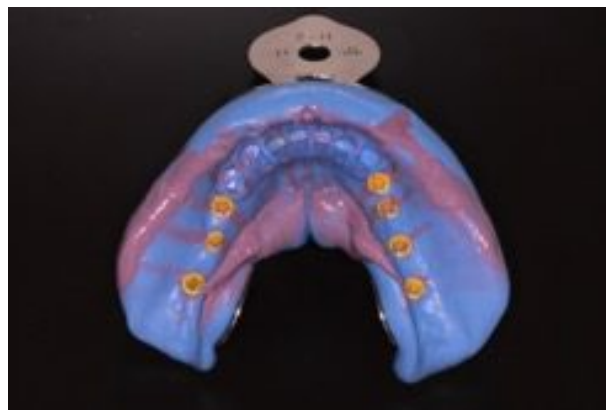
At the same time the patient has already had a removable acrylic denture installed in the upper jaw, that she could use after surgery in the upper jaw until implants integration. As for the lower jaw, she was proposed a non-submerged dental surgery with immediate loading for the following teeth areas: 3.4; 3.5; 3.6; 3.7; 4.5; 4.6; 4.7. Before the surgery the patient's lower jaw was subject to wax-up to further create a surgical guide



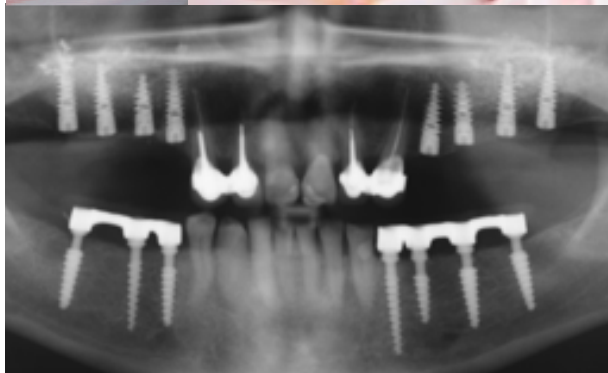
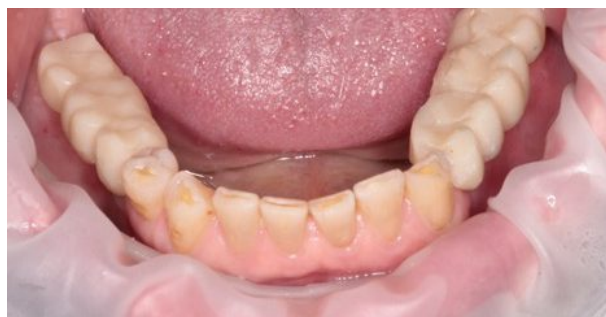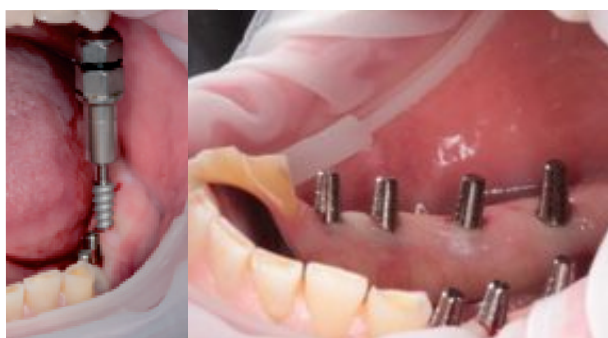Under local anesthesia the upper jaw of the patient was subjected to direct sinus elevation from the left and from the right. ROOT Implants RootForm by TRATE AG were placed in the area 1.4 - R3814; 1.5 - R3812; 1.6 - R3812; 1.7 - R3814; 2.4 - R3814; 2.5 - R 3814; 2.6 - R3814; 2.7 - R3814. The mucous membrane was sutured by PROLENE 4-0 thread.



Then according to surgical guide Compressive implants ROOTT by TRATE AG were placed transgingivally in the area 3.4 C3, 0-16; 3.5 C3,5-10; 3.6 C4,0-12; 3.7 C4,0-12; 4.5 C3,5-12; 4.6 C3,0-14; 4.7 C4,0-12. As the implants of the lower jaw were placed without gingivae incision, there is no need in suturing after implant placing

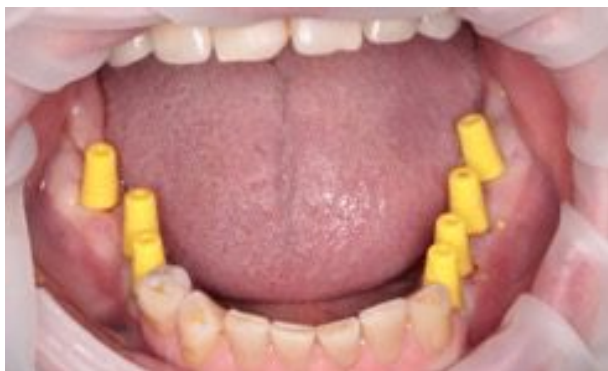
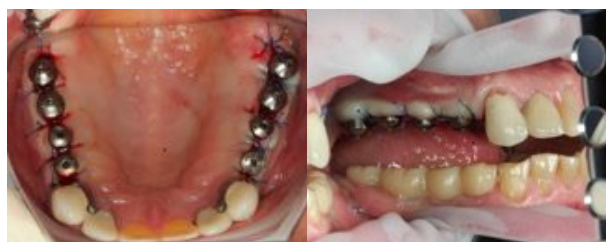
Later the laboratory specialists manufactured reinforced-plastic prostheses, fixed on the 3.4; 3.5; 3.6; 3.7; 4.5; 4.6; 4.7 implants using FUJI I permanent cement on the second day after surgery

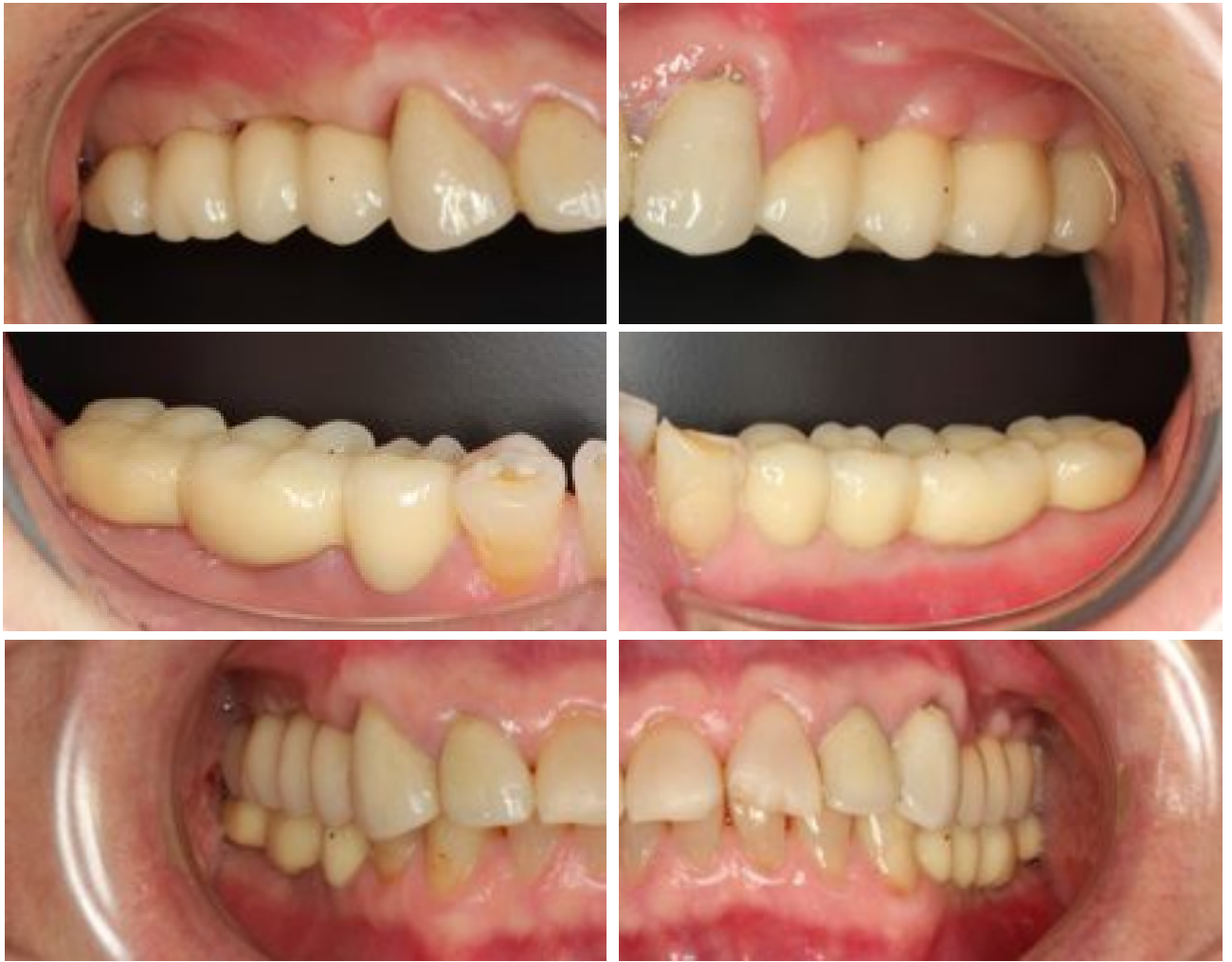

Postoperative period was unremarkable. Upper jaw stitches were removed on the seventh day after surgery. The wound was healed by primary union. After the stitches were removed the patient continued to use removable denture in the upper jaw . 4 months after dental surgery healing caps were installed on the implants in the upper jaw.

After the dental surgery casts of lower jaw implants were directly taken with the help of special plastic sleeve. Several hours later on the same day the try-in of dental backing was conducted.



Reinforced-plastic construction in the lower jaw was sawn and for the period of permanent reinforced-plastic construction manufacturing, the patient used elaborated plastic construction. In the upper jaw open tray impression with coping was made. Then the frame try-in in the upper and the lower jaws was conducted. Later, porcelain-fused-to-metal crowns were fixed on the implants using FUJI I cement.



Orthopantomography control 3 years later.

