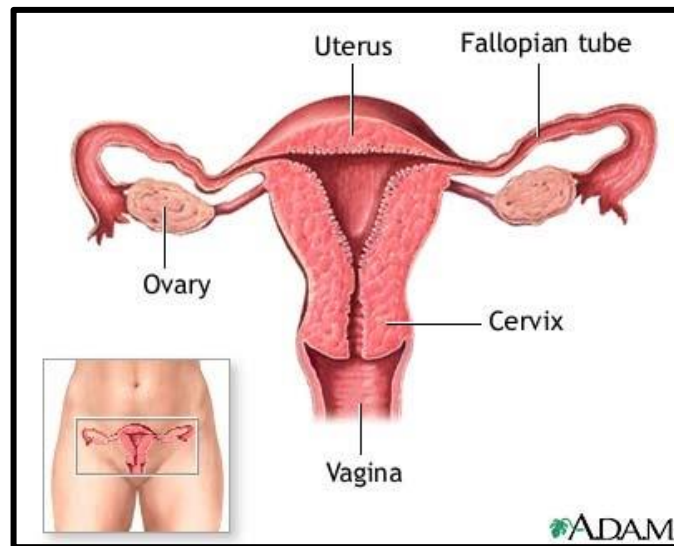


# Critical Review and Appraisal of the Latest FIGO/AJCC System of the Female Genital System



**Kyu-Rae Kim, M.D., Ph.D**

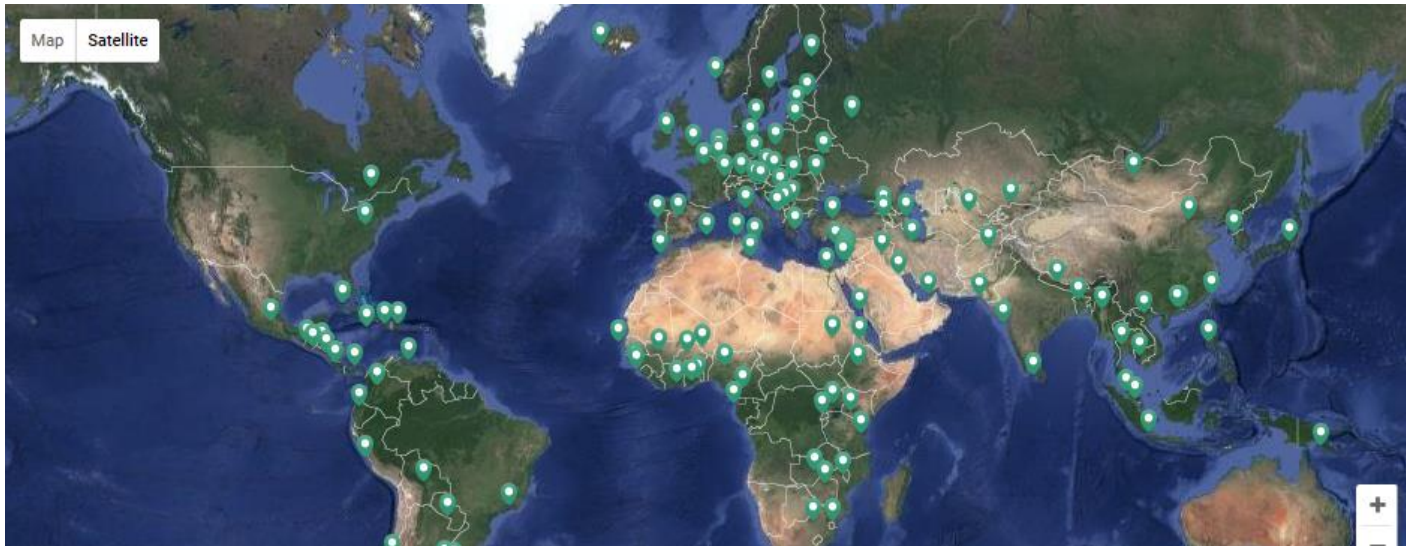Department of Pathology, Asan Medical Center,  
University of Ulsal College of Medicine, Seoul, Korea

# Major International Society of Gynecologic Oncologists

- **SGO:** Society of Gynecologic Oncology
- **ESGO:** European Society of Gynecologic Oncology
- **FIGO:** International Federation of Gynecology and Obstetrics

# Cancer Staging System

- **FIGO staging system**



- **The TNM system**  
(accepted by AJCC and UICC)

# FIGO/AJCC 8<sup>th</sup> Staging System

- Endometrial carcinoma
- Uterine sarcoma
- Cervical carcinoma
- Ovarian/Tubal carcinoma
- Vulva carcinoma
- Vaginal carcinoma
- Gestational Trophoblastic disease

# Endometrial Carcinoma

is a surgically/pathologically staged disease (1988), whereas cervical cancer is a clinically staged disease !!

# FIGO Staging of Endometrial Carcinoma (2009~ )

- I. Tumor confined to the corpus uteri
  - 1A. No or less than half of myometrial invasion. (T1a)
  - 1B. Invasion one half or more of the myometrial invasion. (T1b)
  
- II. Tumor invades cervical stroma, but not beyond uterus. (T2)
  
- III. Local or regional spread
  - IIIA. Tumor involves serosa and/or adnexa and/or cancer cells in ascites or peritoneal washings. (T3a)
  - IIIB. Vaginal and/or parametrial involvement. (T3b)
  - IIIC1. Pelvic lymph node involvement. (N1)
  - IIIC2. Para-aortic involvement. (N2)
  
- IV.
  - IVA. Tumor invades mucosa of the bladder and/or bowel mucosa. (T4)
  - IVB. Distant metastasis including abdominal mets and/or inguinal lymph nodes (M1)

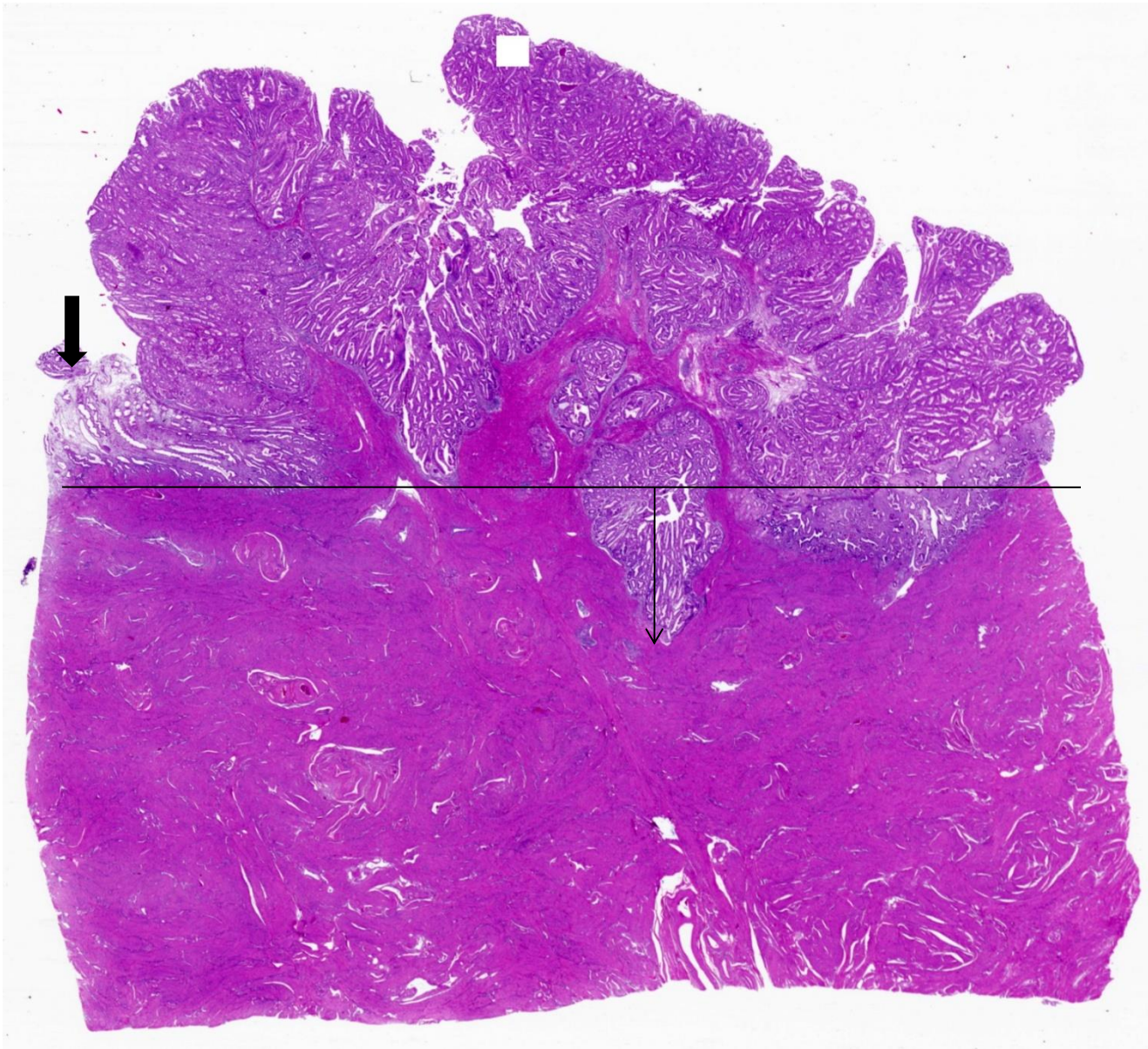
# Endometrial Carcinoma

## Summary of Changes in AJCC/ TNM<sup>8th</sup>

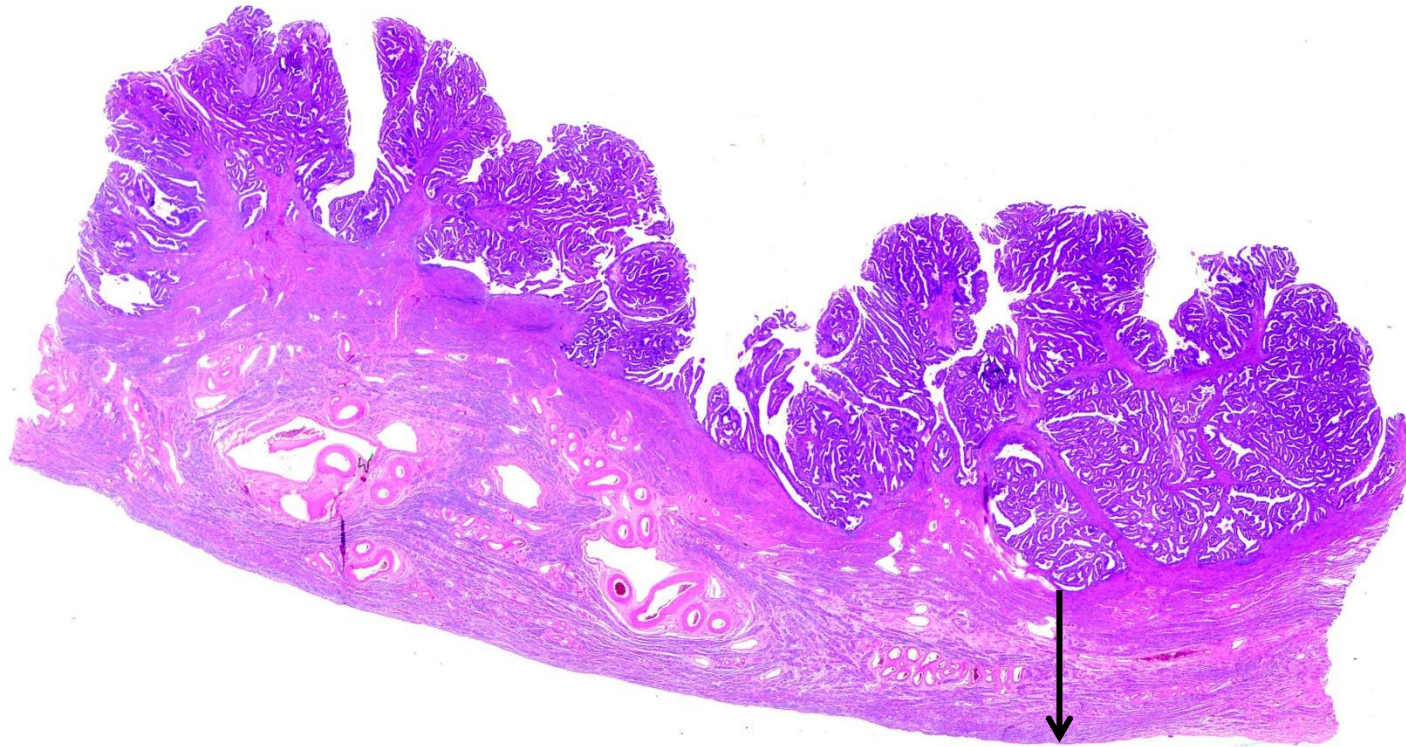
1. Uterine sarcomas (LMS, ESS) have been removed from the staging system (separate staging system).
2. Stage 0 and Tis (carcinoma in situ/ preinvasive carcinoma) have been removed.
3. Serous intraepithelial carcinoma of the endometrium is considered a T1 cancer.
4. ITCs ( $\leq 0.2$ m) and micrometastasis ( $\leq 2$  mm diameter) are reported as N0(+i) and N1mi/N2mi, respectively.

- There are difficult areas which are not specifically mentioned in the FIGO or AJCC staging system.
- It will be useful for the pathologist to know the correct staging in these scenarios.



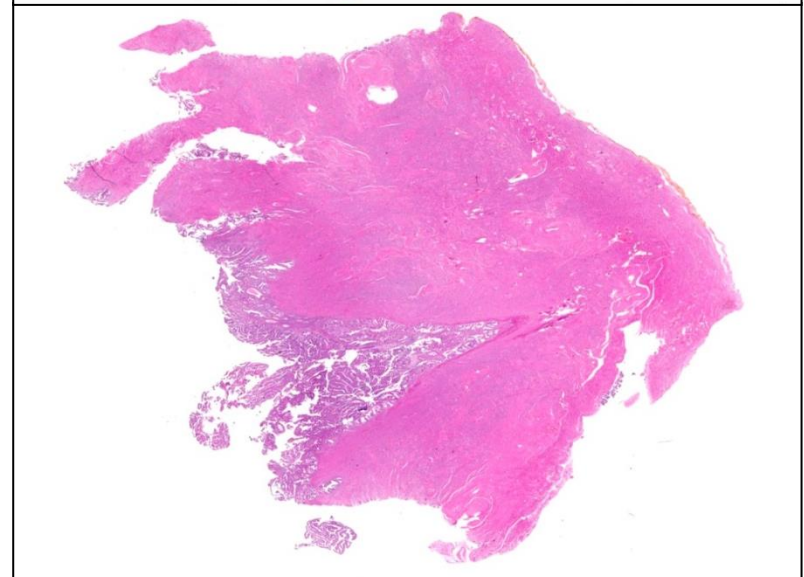
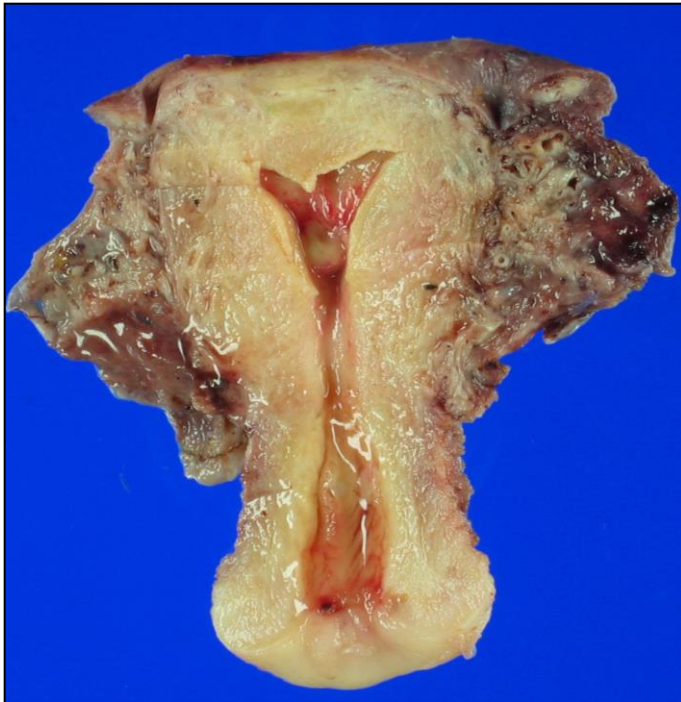
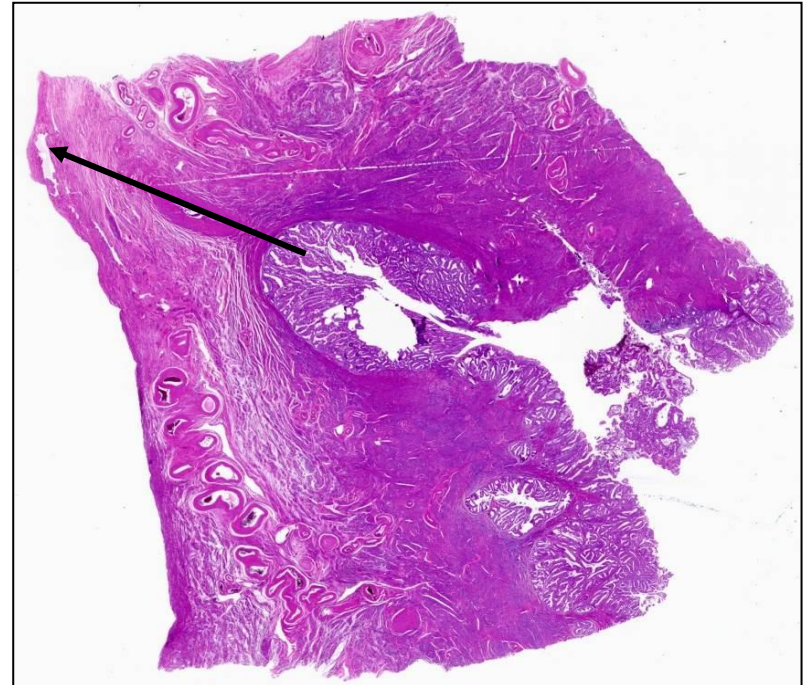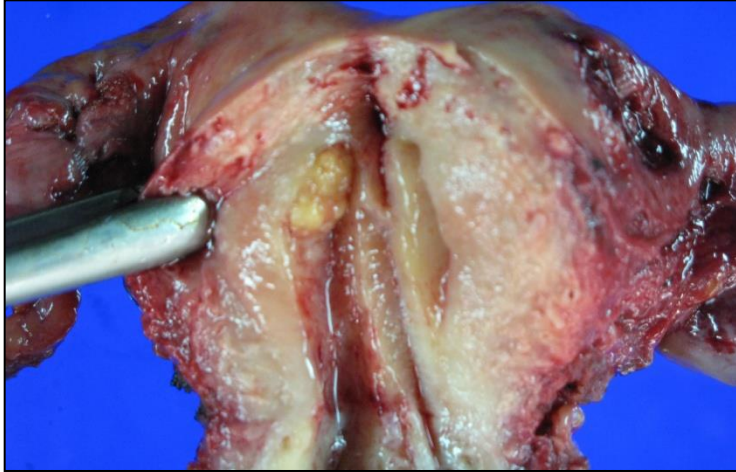


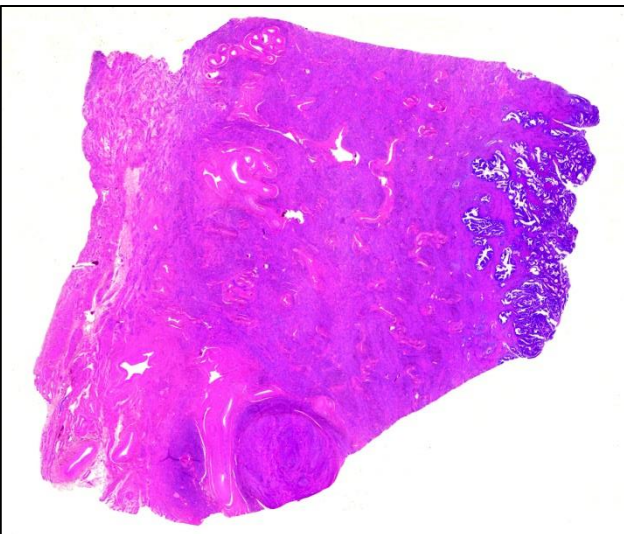
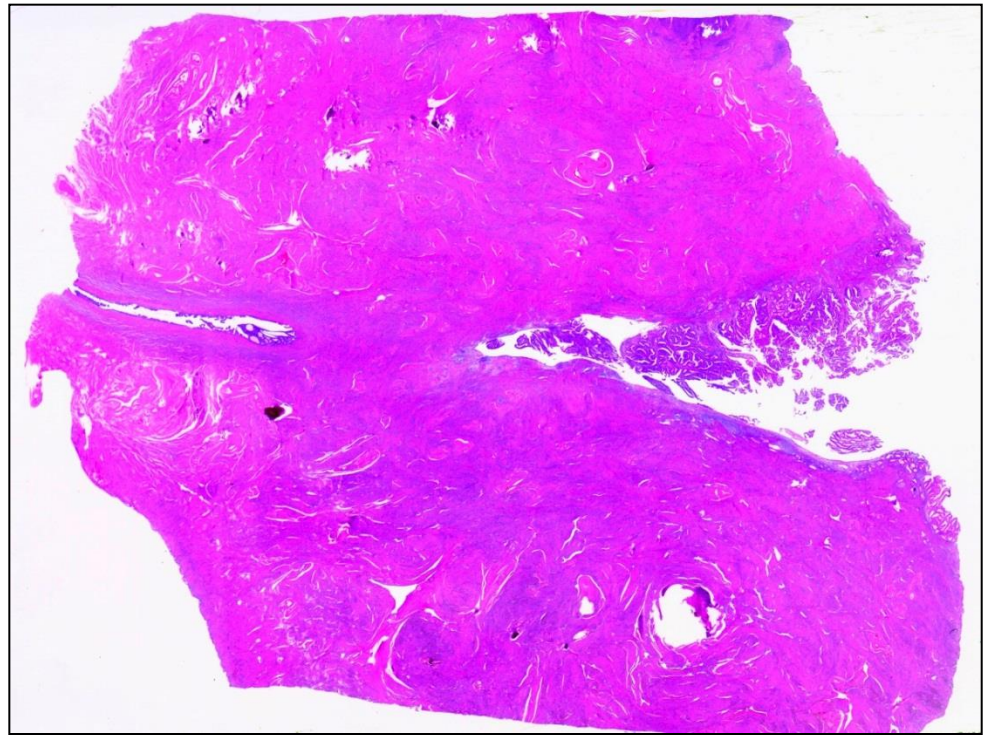
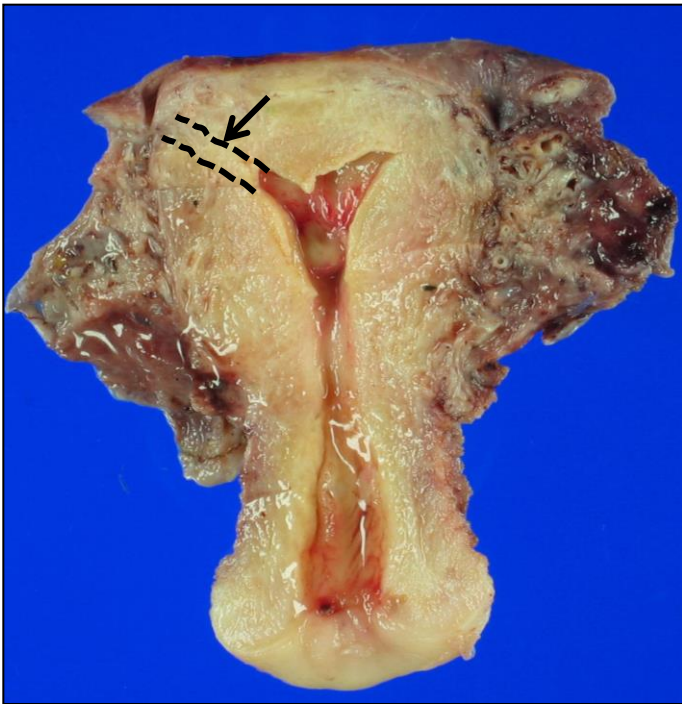- **Depth of invasion :** **Adjacent normal endomyometrial junction-deepest portion compared with overall myometrial thickness**



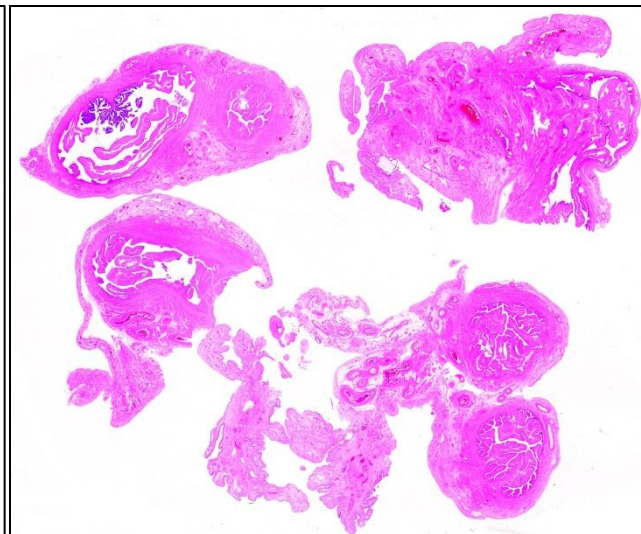
- **Tumor-free distance : Distance between the point of maximal myometrial invasion and the uterine serosa.**

# Tumors Involving the Uterine Cornu

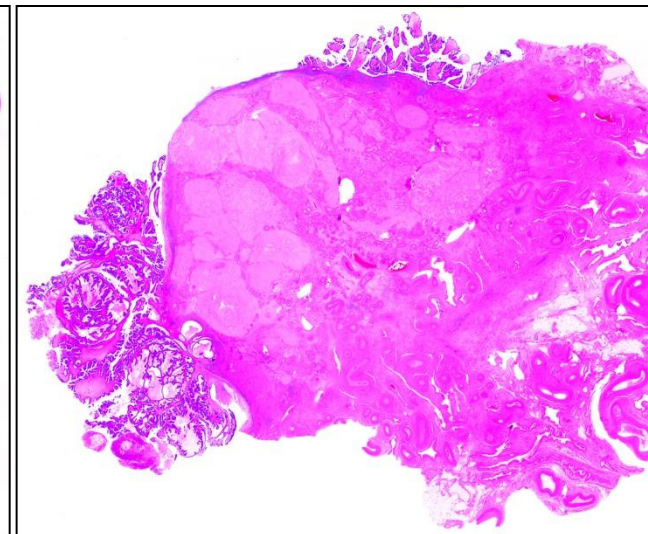




Myometrial invasion <1/2

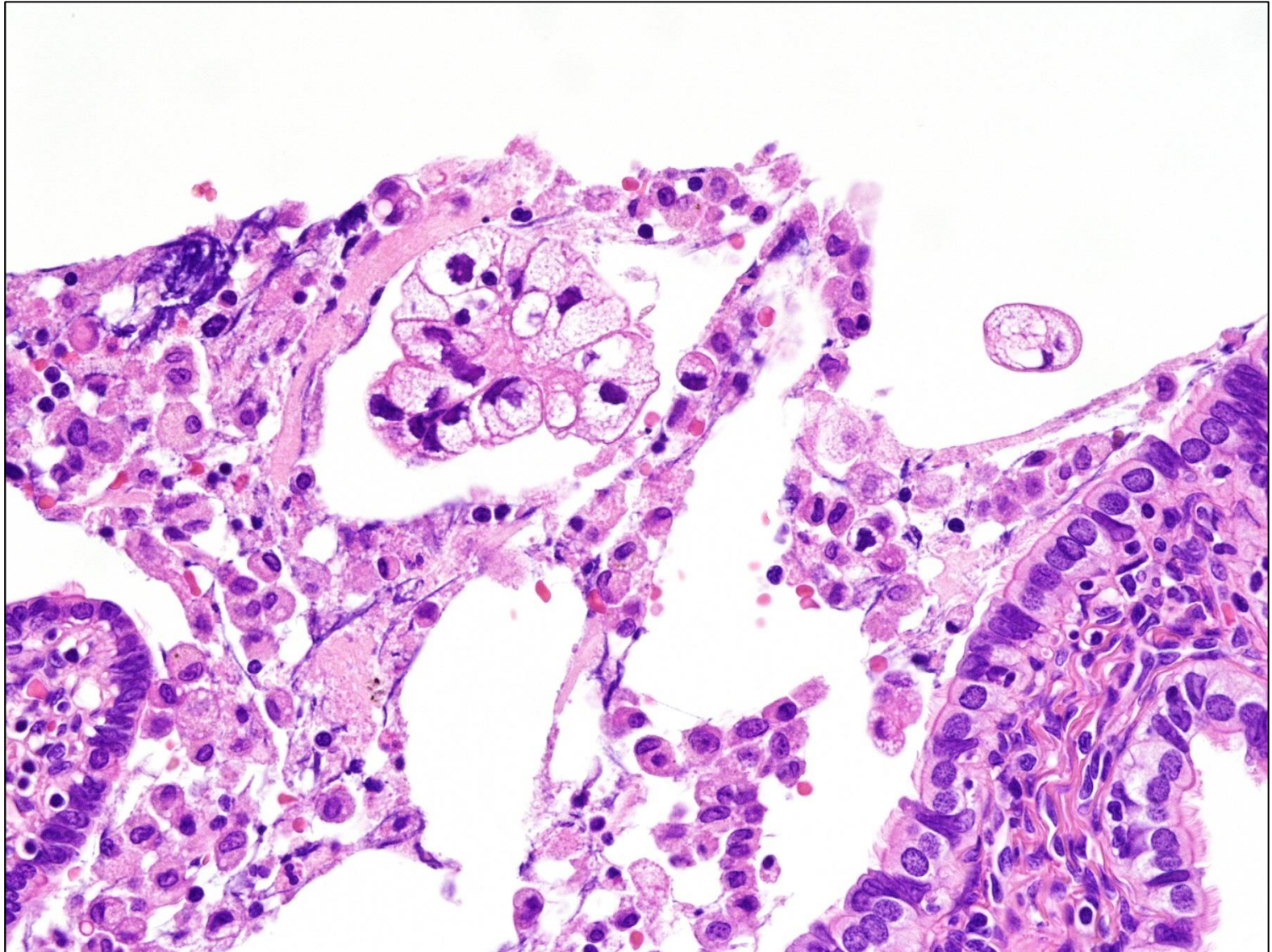


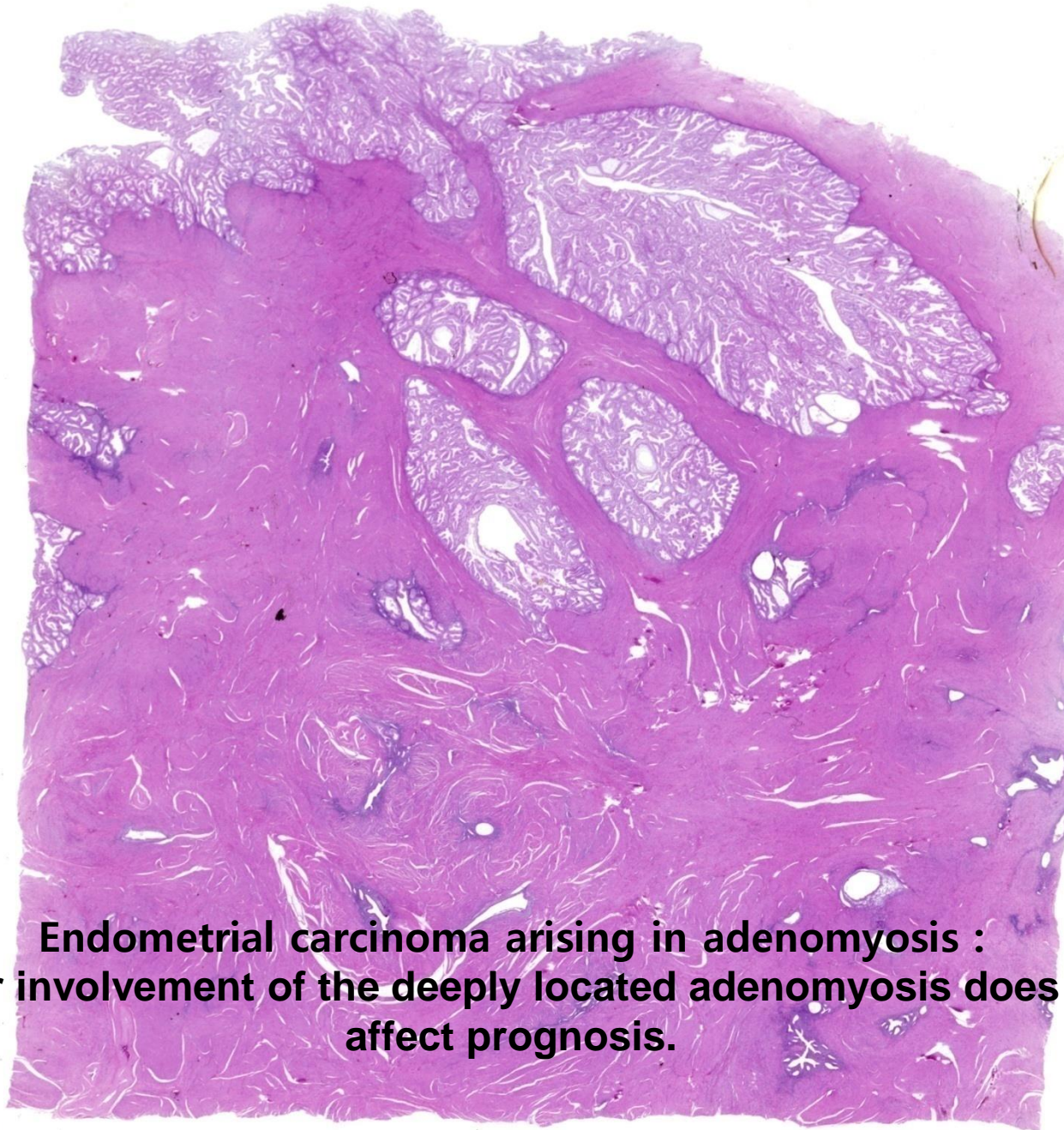
Tubal mucosal spread & floating nests



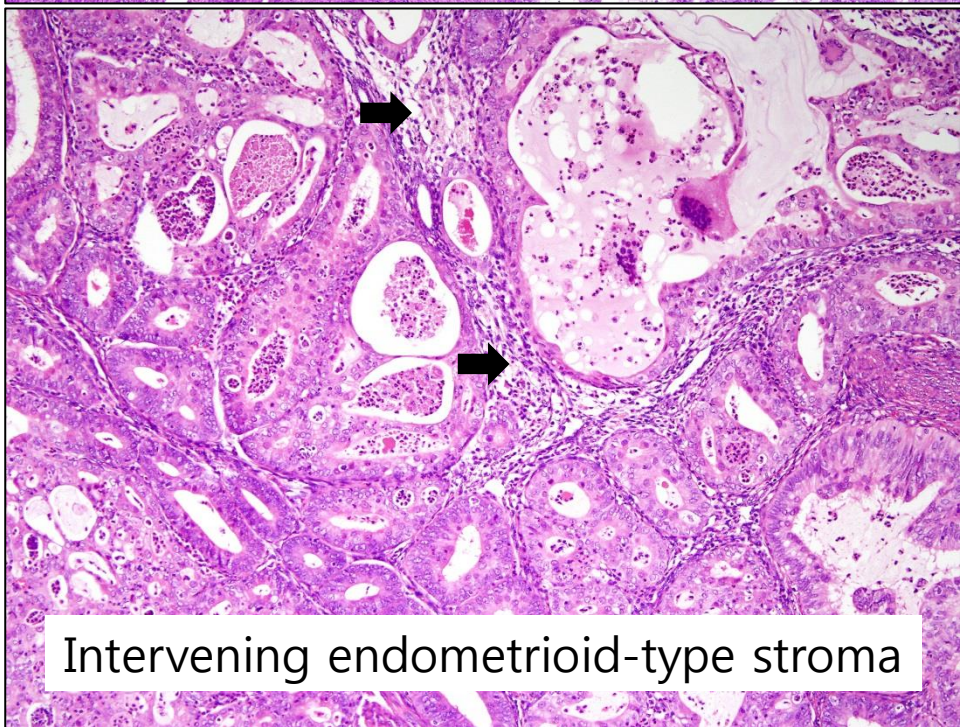
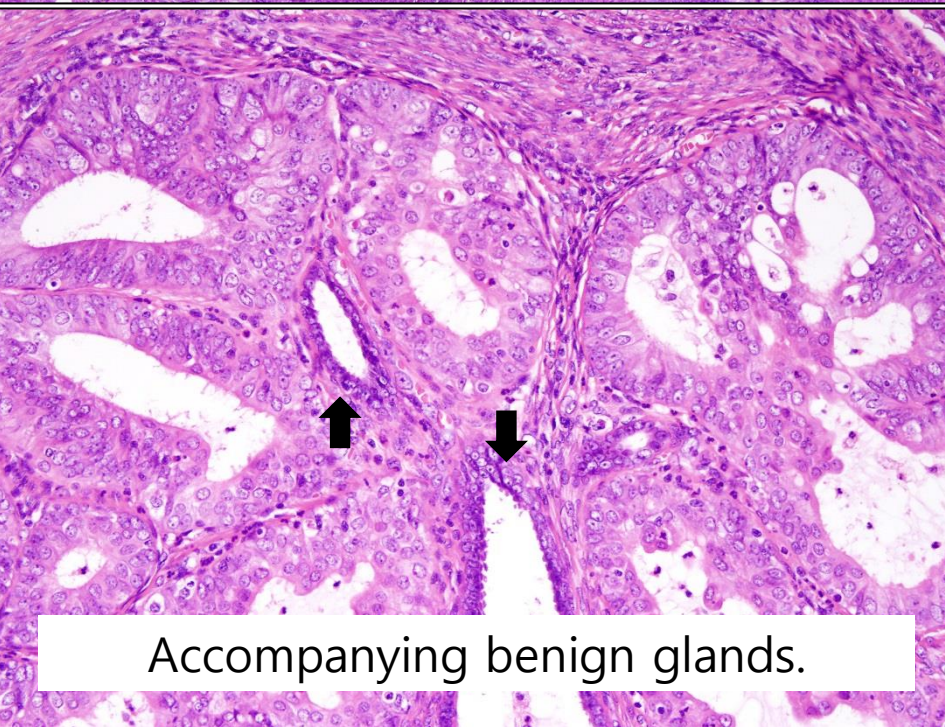
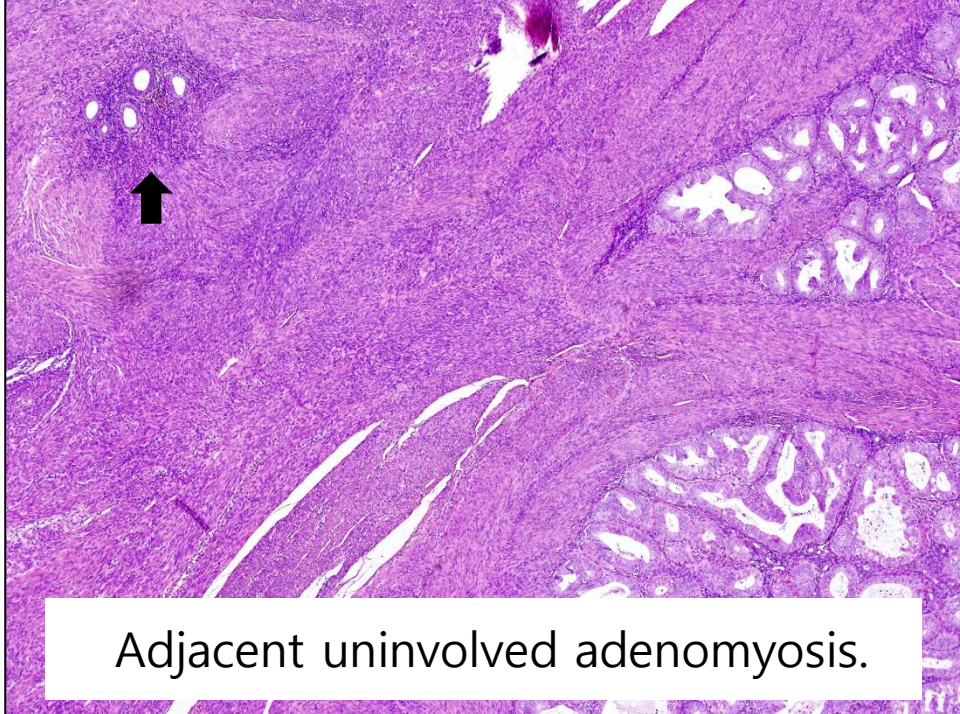
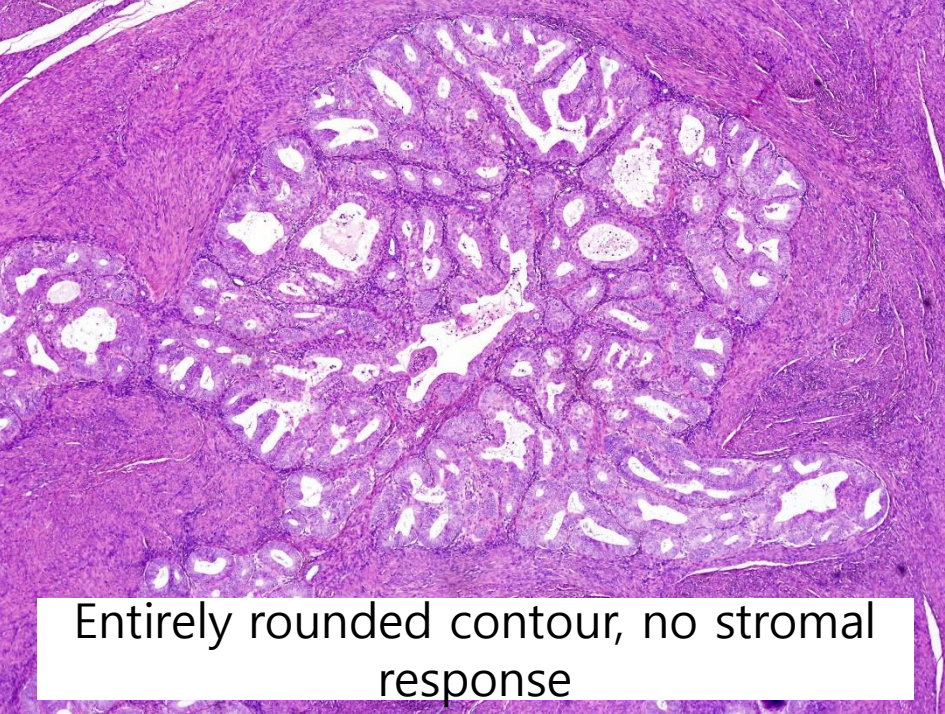Ovarian surface implants

# Free Floating Tumor Cells in FTs

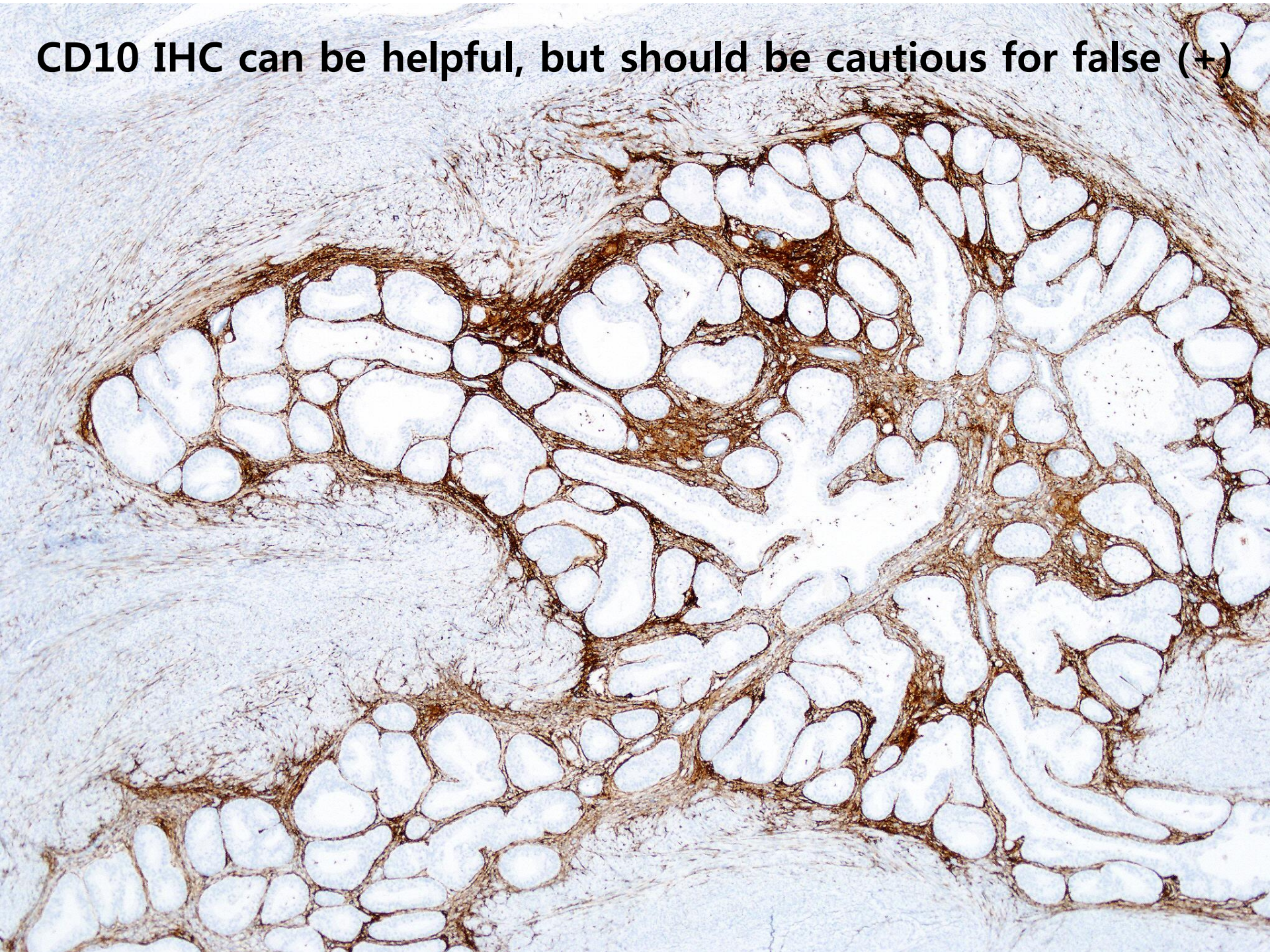



**Endometrial carcinoma arising in adenomyosis :  
tumor involvement of the deeply located adenomyosis does not  
affect prognosis.**

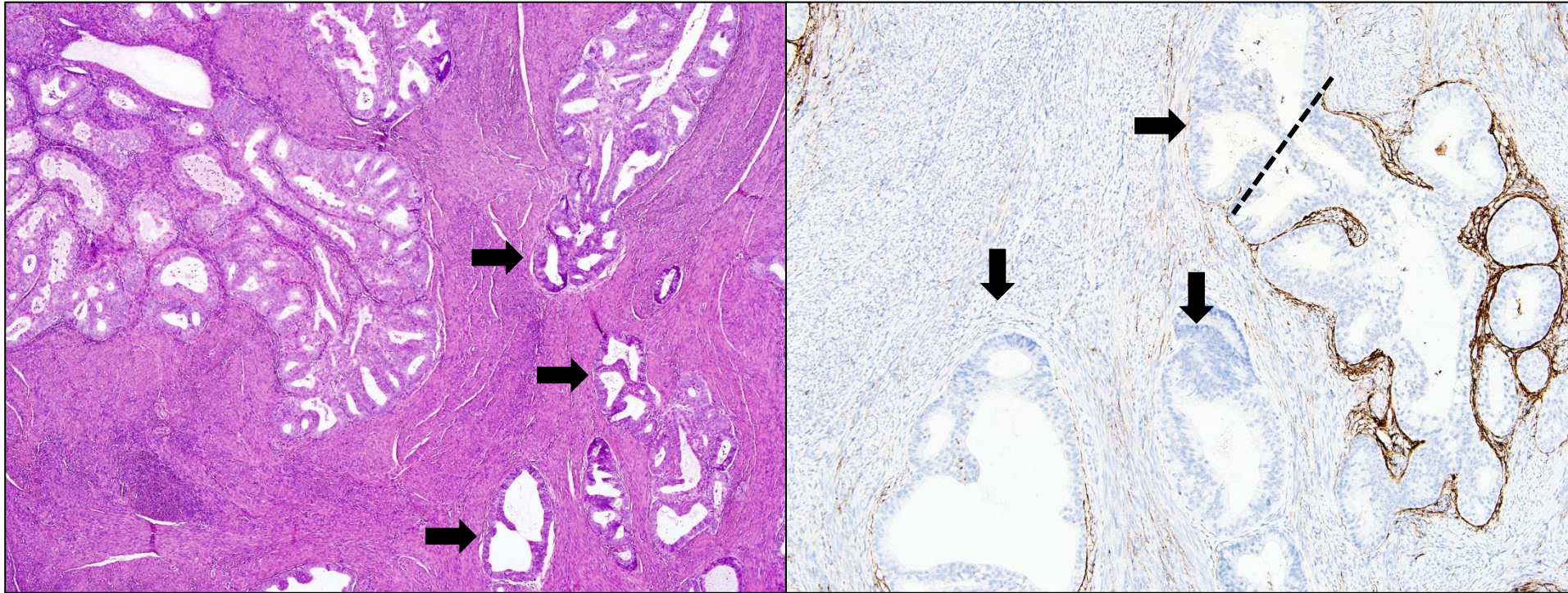


**CD10 IHC can be helpful, but should be cautious for false (+)**





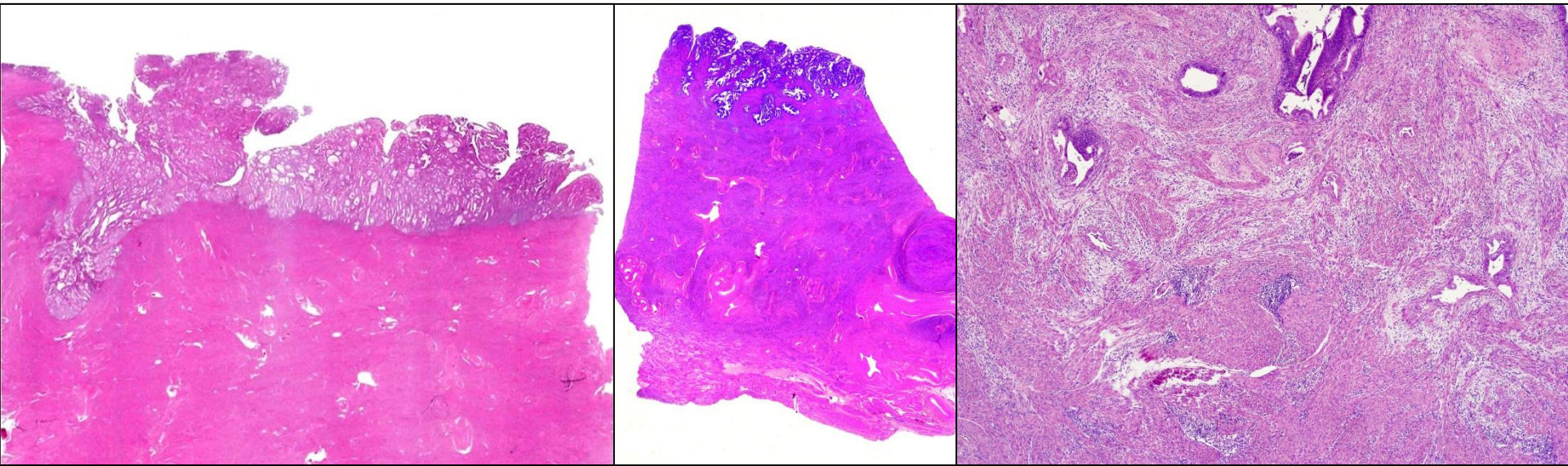
**EC involved adenomyosis with invasion into adjacent myometrium.**



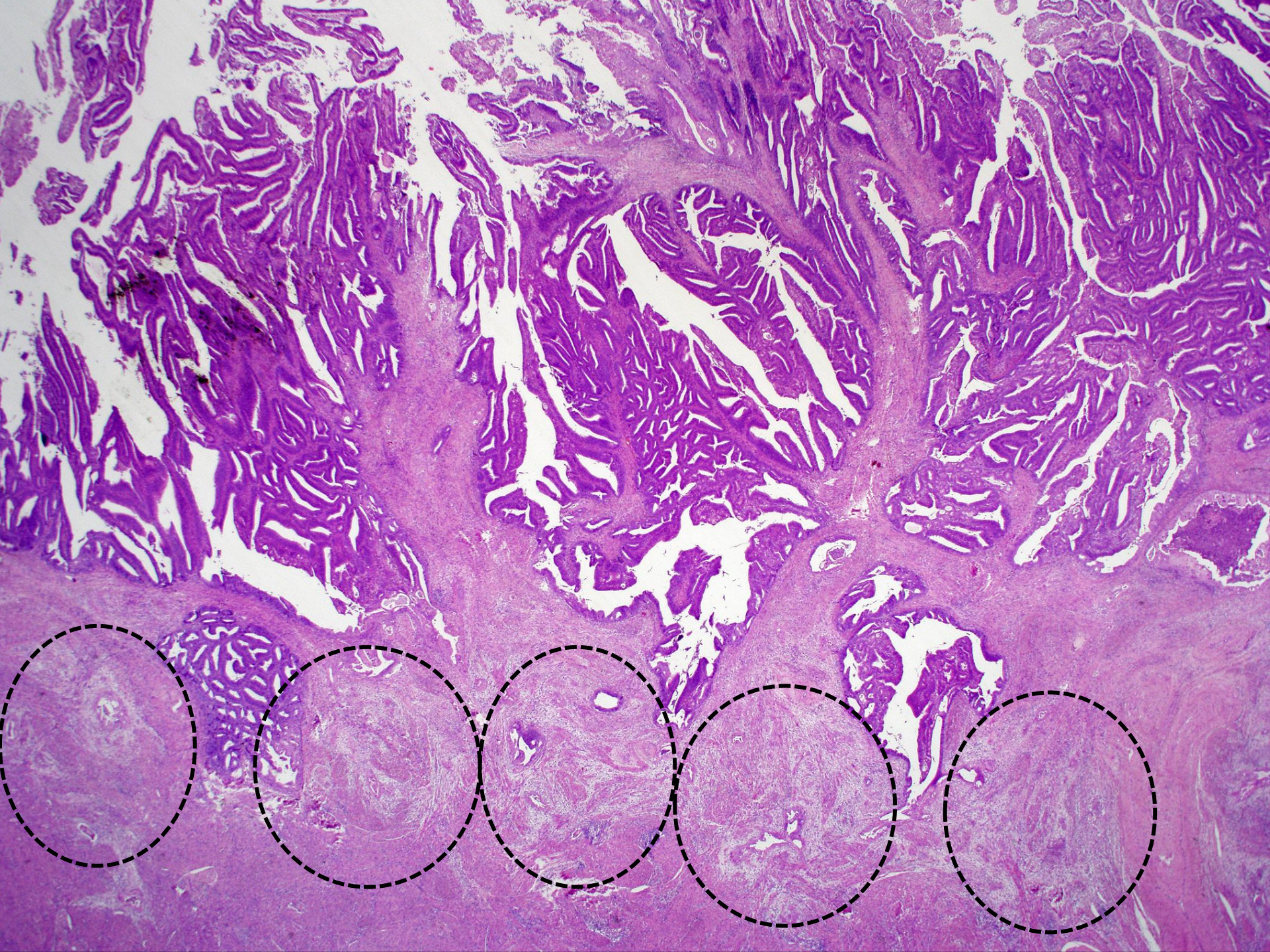
# Types of myometrial invasion :

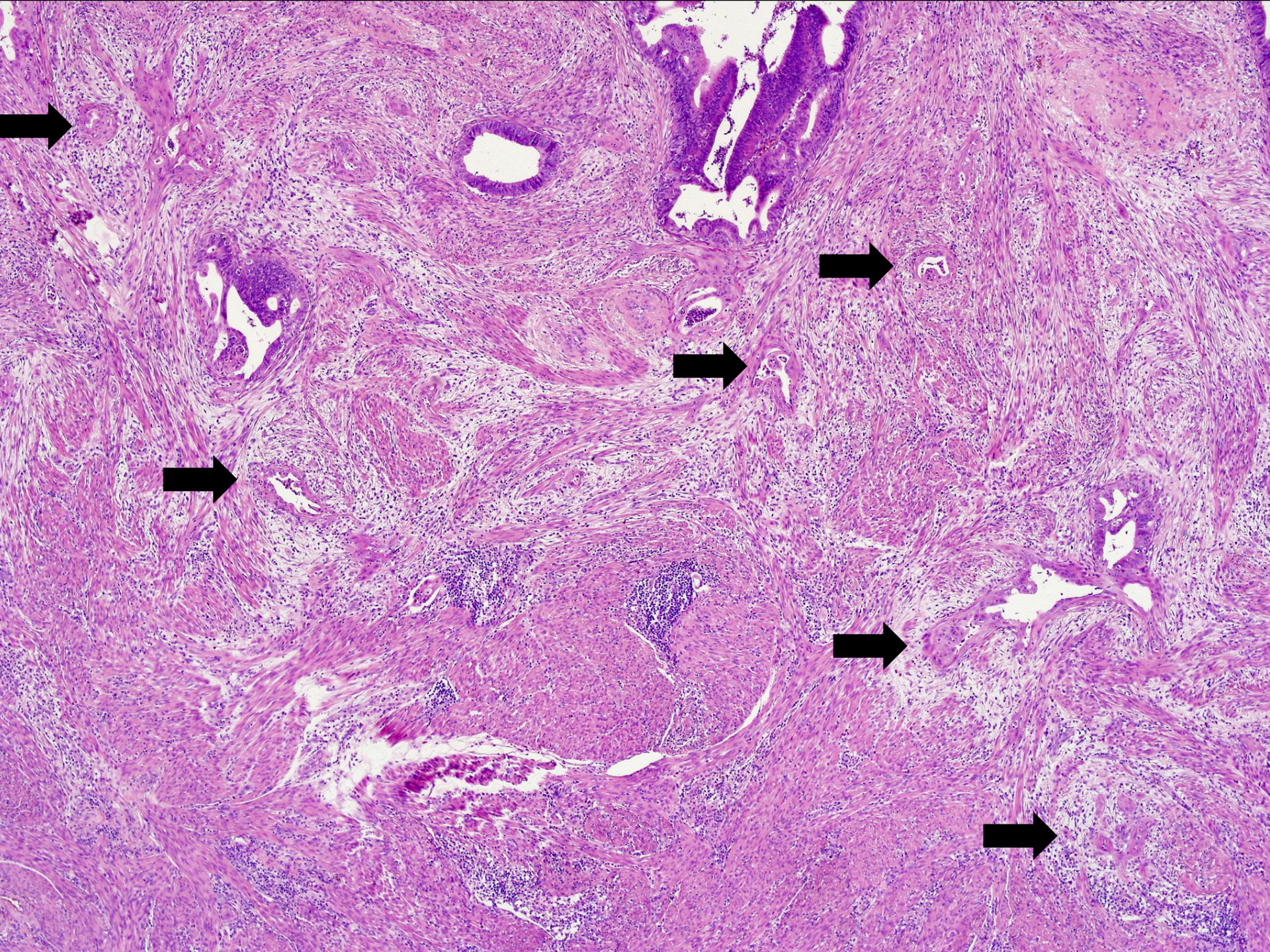
## Pushing vs. Infiltrative vs. "MELF"

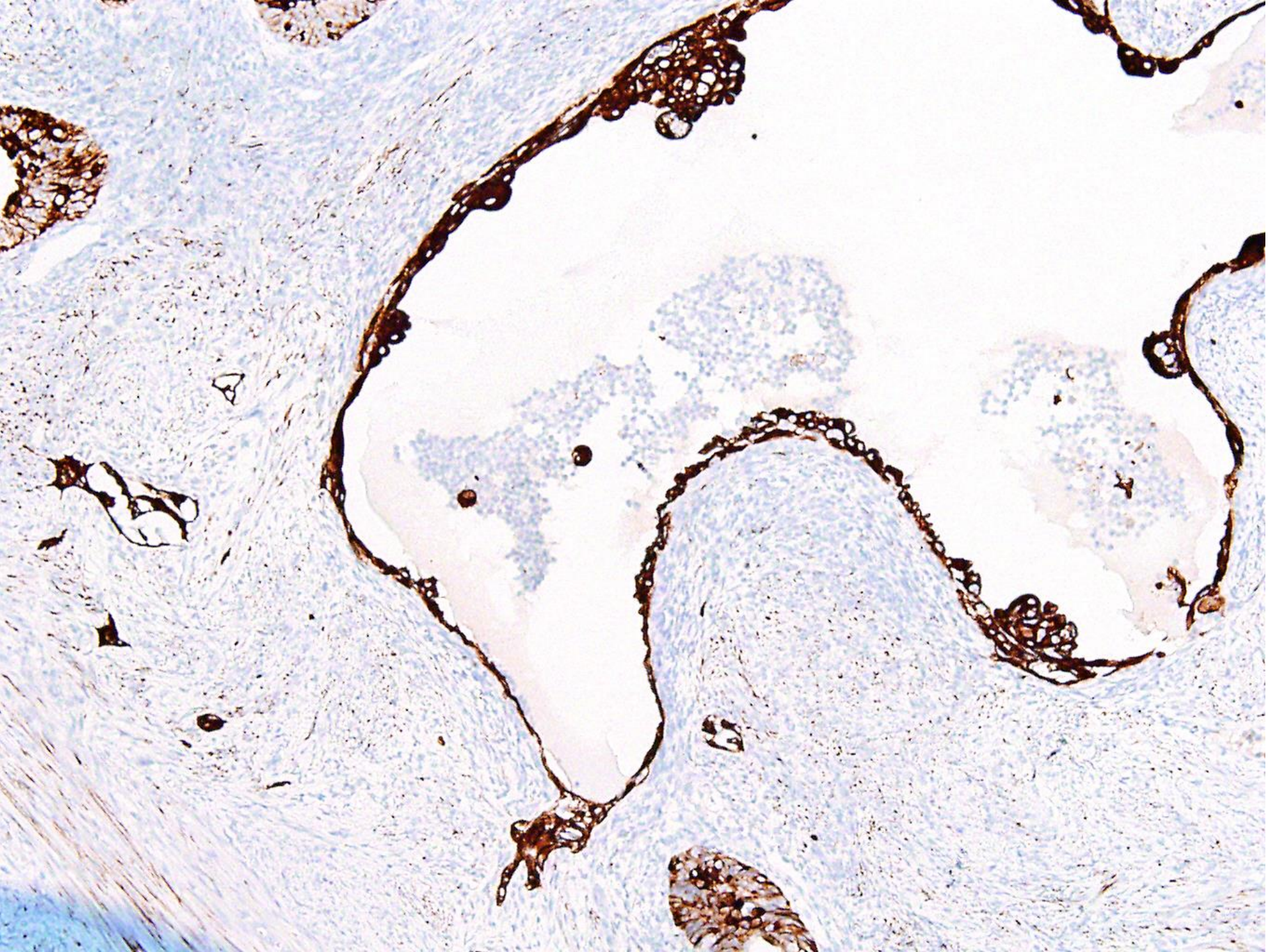
"MELF" type invasion in endometrial cancer as a risk factor for lymph node metastasis



"MELF" type : microcystic, elongated and fragmented/fibromyxoid.







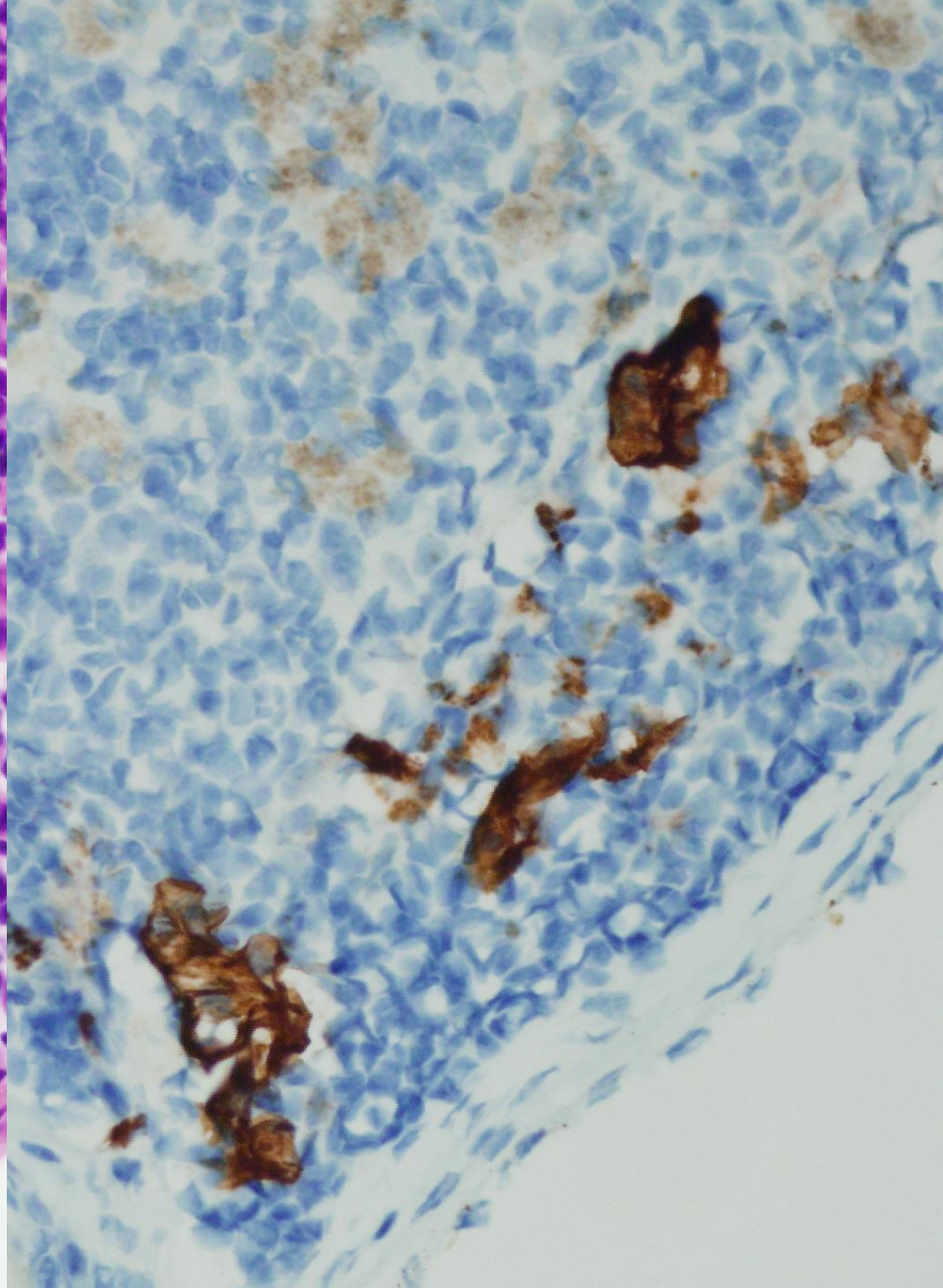
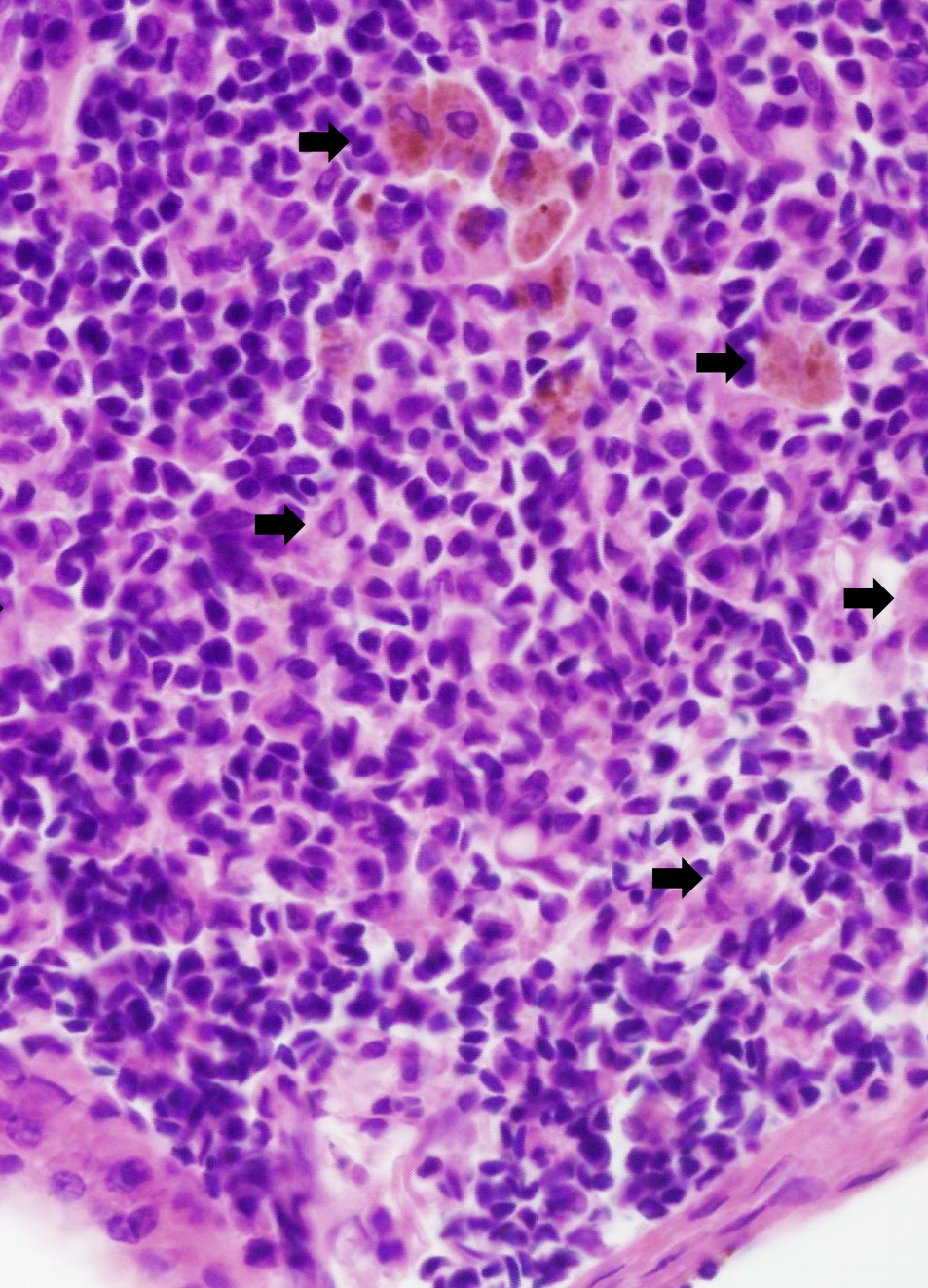
# Significance of "MELF"; controversial

**Associated with larger tumor size, deep MI, advanced stage, LVSI, LN mets, papillary architecture, mucinous differentiation, but recurrence and overall survival not affected by "MELF"**

- Kihara A et al. Am J Surg pathol 2017
- Goldberg A et al. Int J Gynecol pathol 2018
- Pelletier MP et al. Hum Pathol 2017

**Associated with increased LN mets, LVSI, and worse prognosis.**

- Park JY, Hong D, Park JY. Pathol Oncol Res. 2017
- Zinovkin DA, et al. J Pathol Transl Med. 2017
- Naki MM et al. J Turk Ger Gynecol Assoc 2017
- Espinosa I et al. Human Pathology 2017
- Sancı M et al. Int J Gynecol pathol 2018



**Isolated tumor cell clusters**

# Isolated tumor cell clusters

- **Isolated tumor cells** : individually scattered cells or in small clusters of cells measuring 0.2mm or less. (pN0(i+)).
- **Micrometastasis** : the tumor cell clusters measure more than 0.2mm and less than 2mm.
- **Macrometastasis** : 2mm or larger.

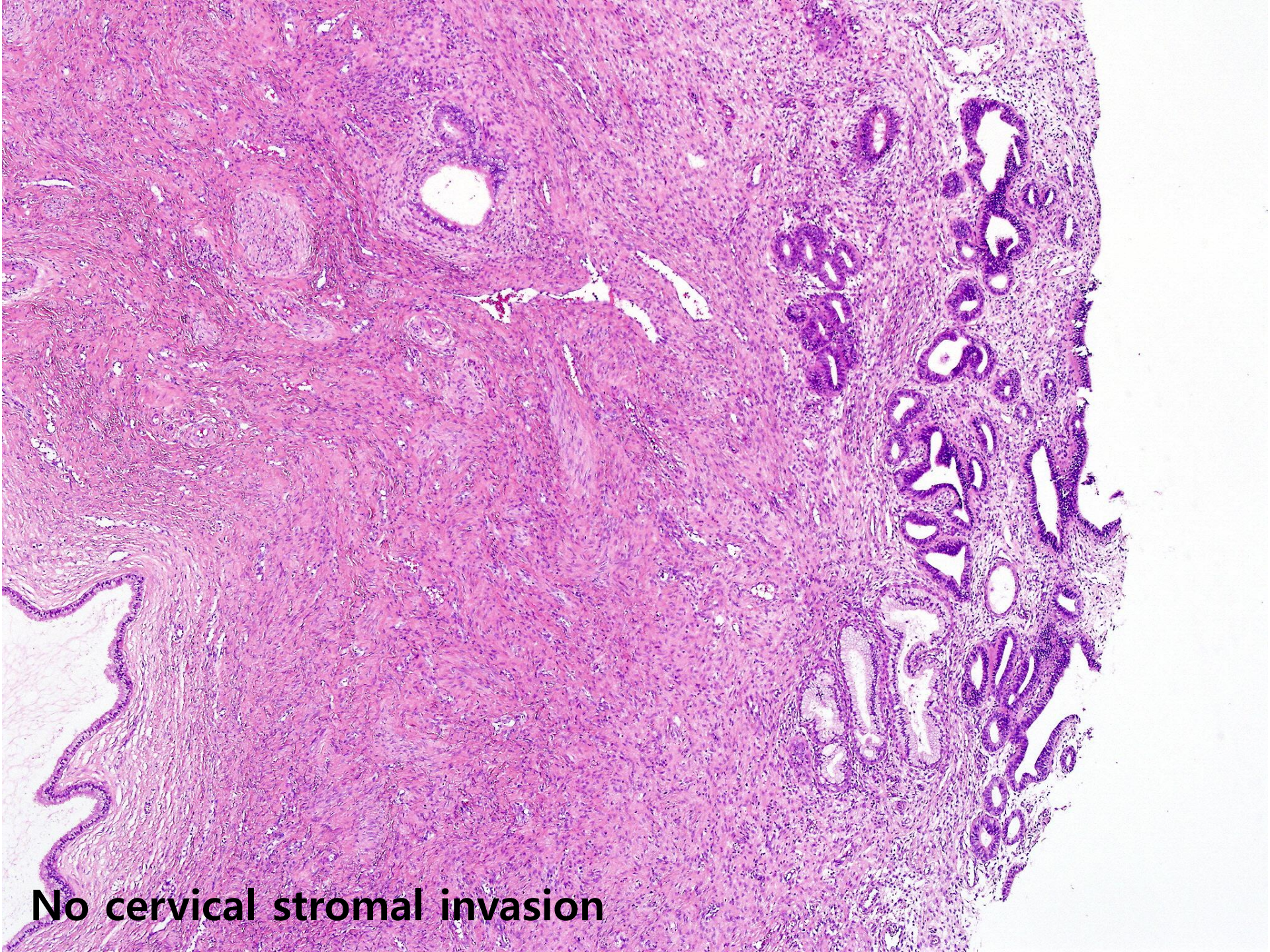


# 1989 vs. 2009 FIGO Stage of EC

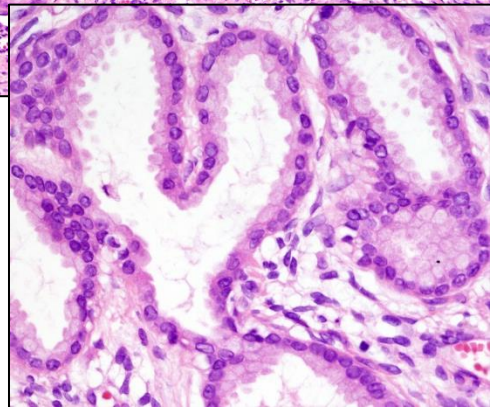
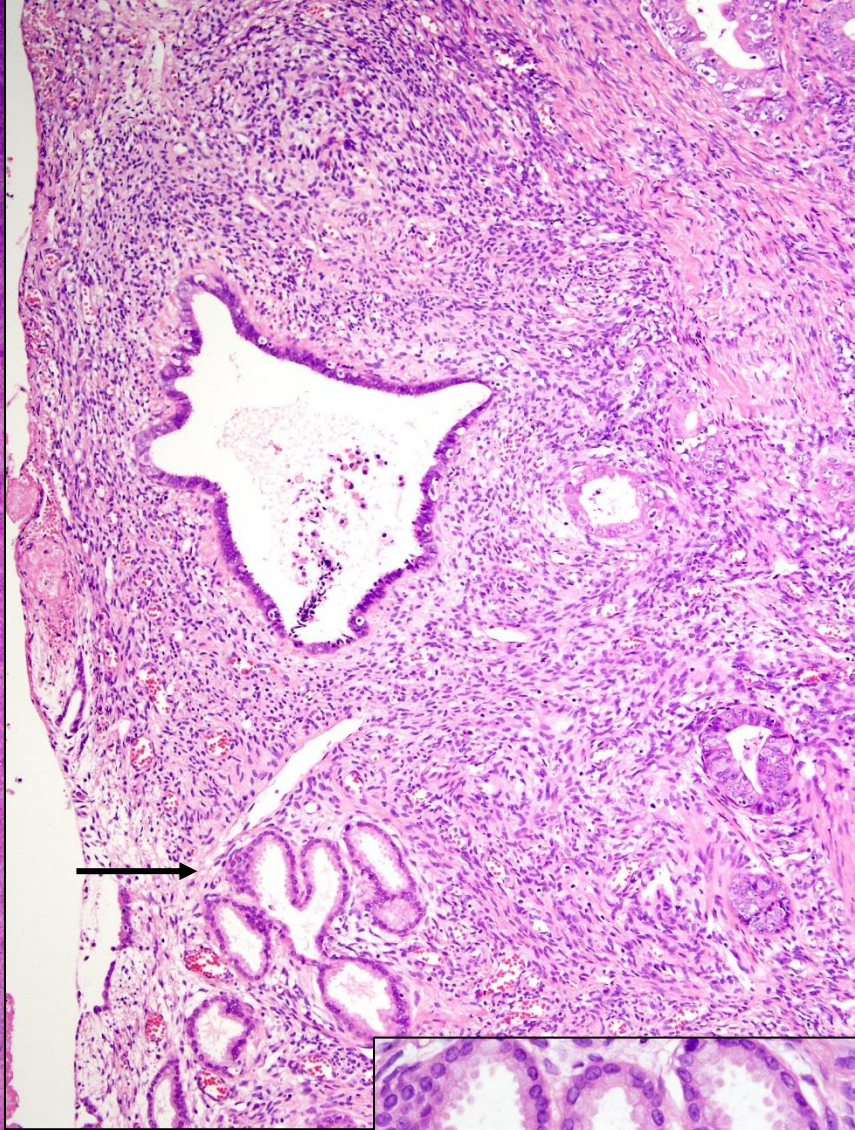
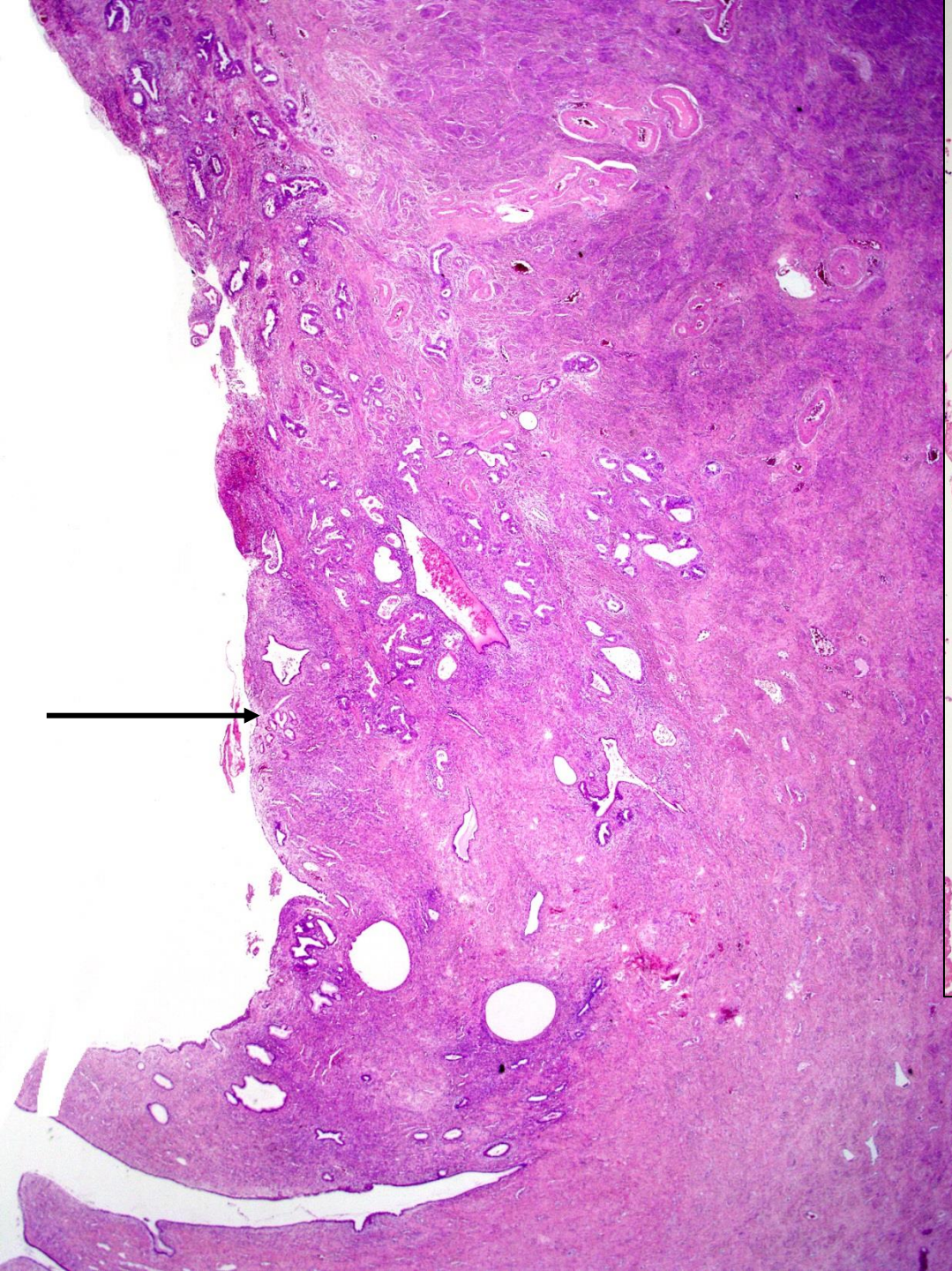
- IA Tumor limited to EM
- IB <1/2 myometrium.
- IC  $\geq$  1/2 myometrium.
- **IIA Endocervical glandular involvement only.**
- **IIB Uterine cervical stromal invasion.**
- IIIA Tumor invades serosa or adnexa or positive peritoneal cytology.
- IIIB Vaginal metastases.
- IIIC Metastases to pelvic or para-aortic LNs.
- IVA Tumor invasion bladder and/or bowel mucosa.
- IVB Distant metastases including abdominal and/or inguinal LNs.

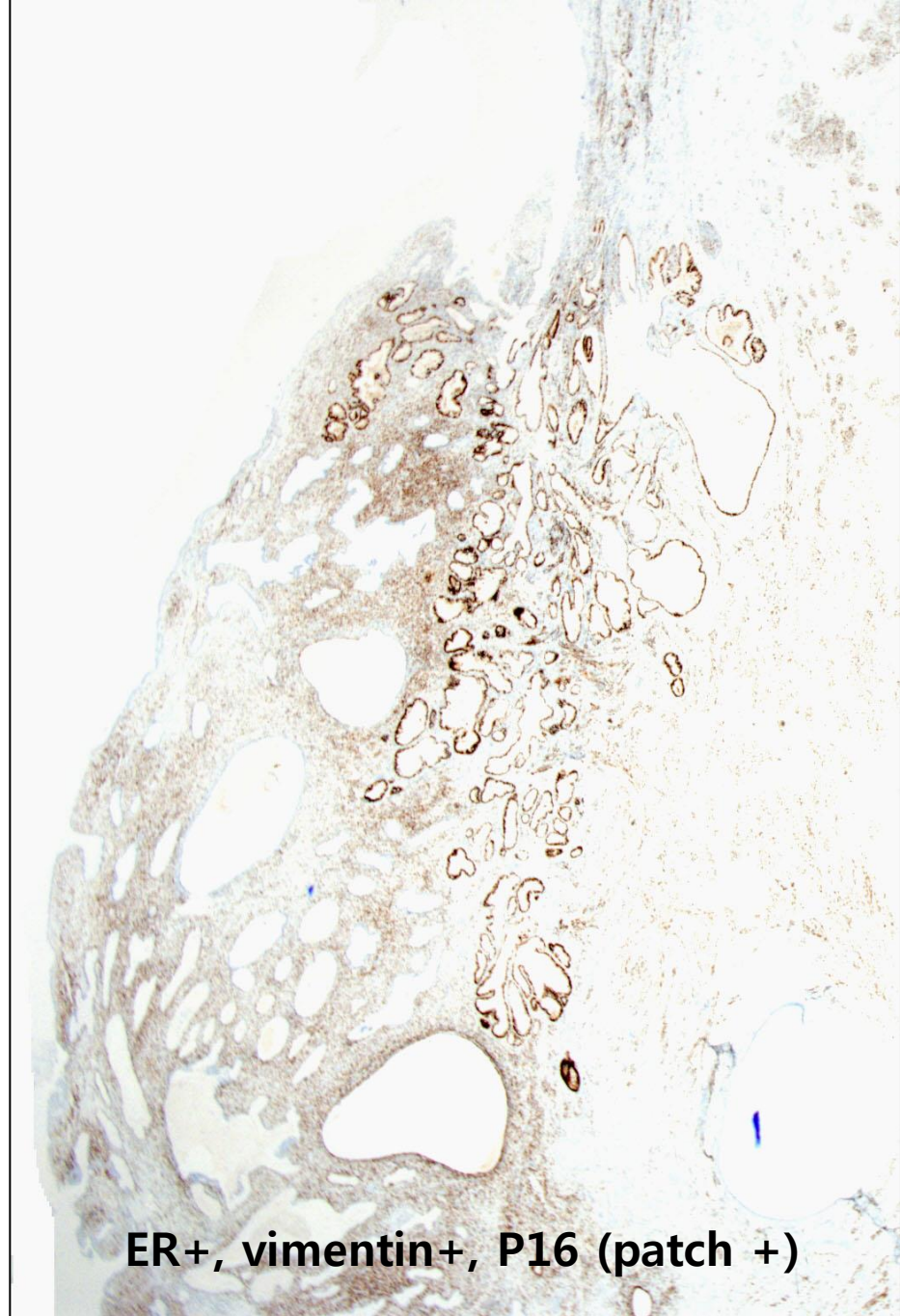
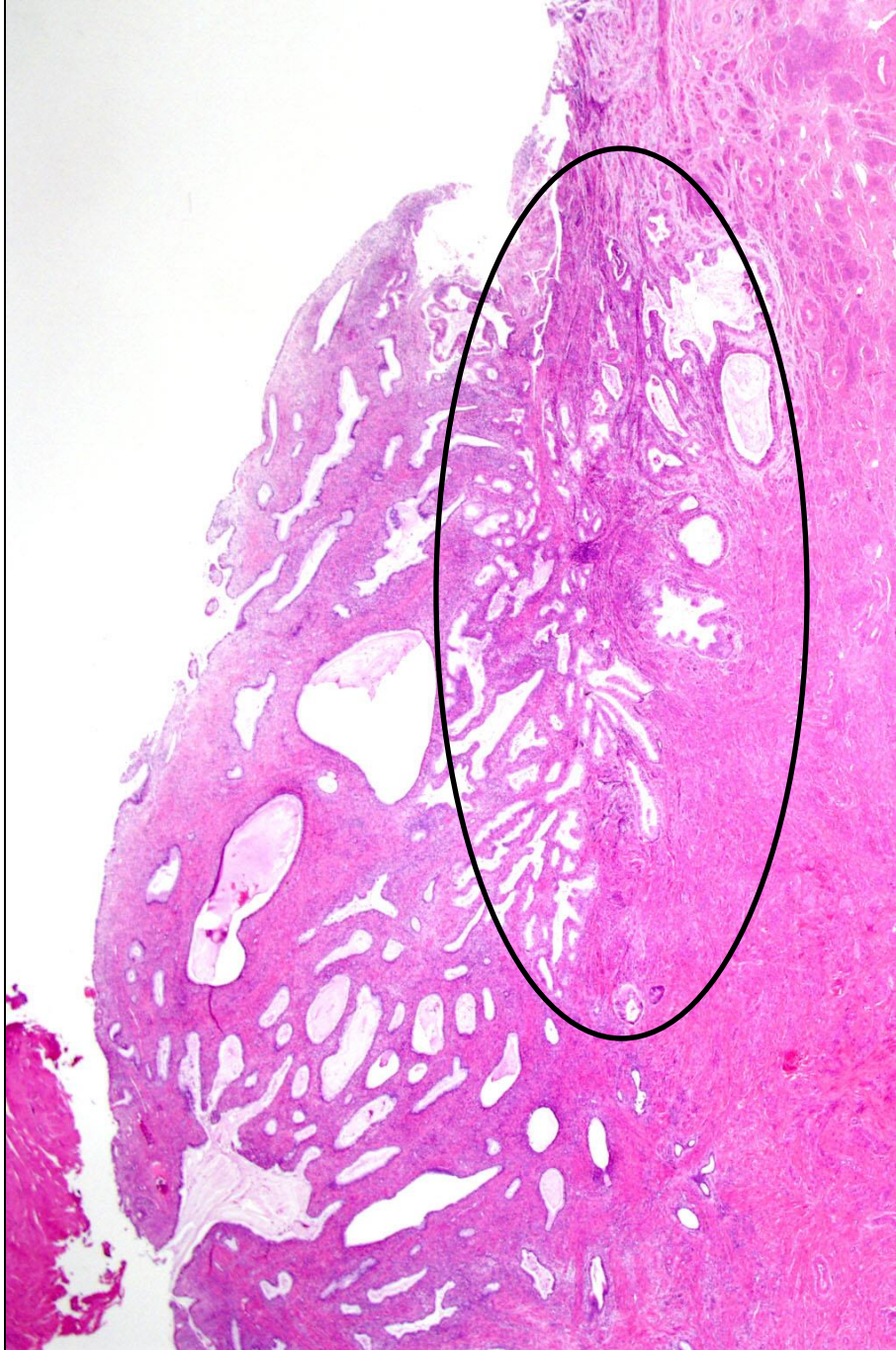


- IA Tumor confined to the uterus, no or < 1/2 myometrial invasion.
- IB Tumor confined to the uterus,  $\geq$  1/2 myometrium.
- **II Tumor involves the uterus and the cervical stroma.**
- IIIA Tumor invades serosa or adnexa.
- IIIB Vaginal and/or parametrial involvement.
- IIIC1 Pelvic LN involvement.
- IIIC2 Para-aortic LN involvement, with or without pelvic LN involvement.
- IVA Tumor invasion bladder mucosa and/or bowel mucosa.
- IVB Distant metastases including abdominal metastases and/or inguinal LNs



**No cervical stromal invasion**





**ER+, vimentin+, P16 (patch +)**

# Definition of Regional Lymph Node (N)

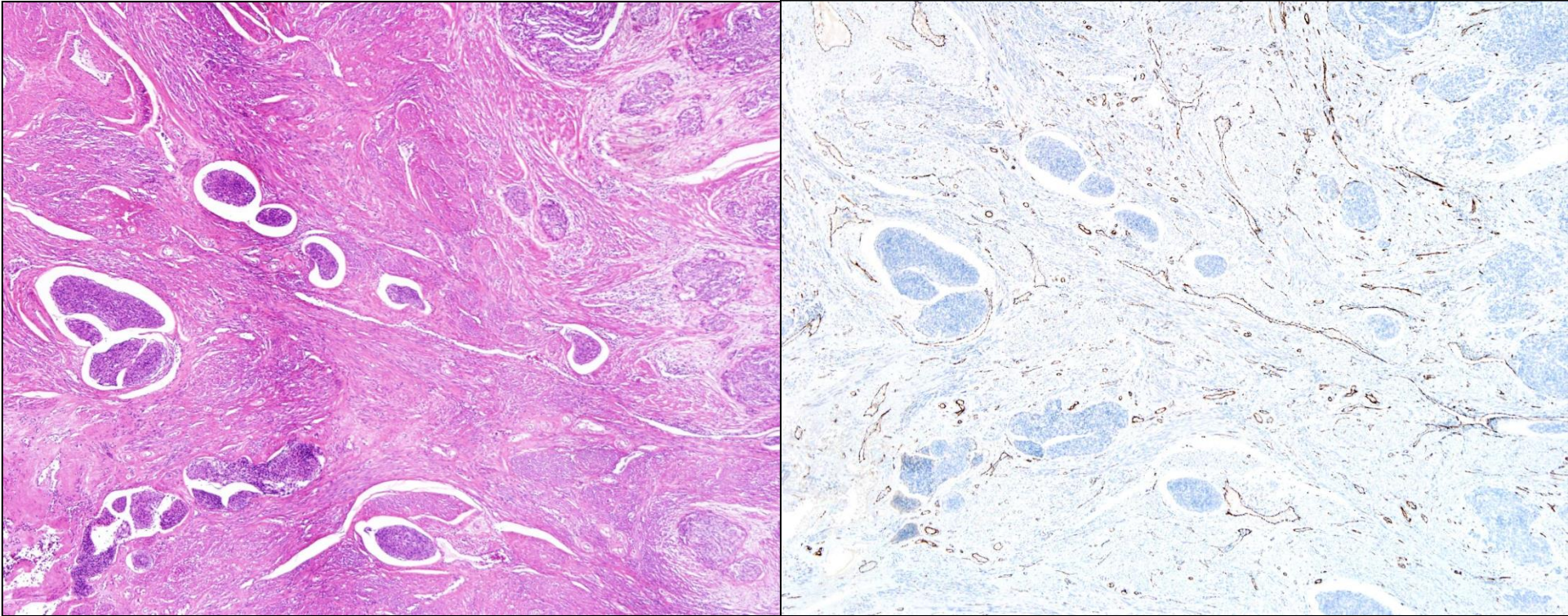
N	FIGO	N Criteria
NX		Regional LN cannot be assessed.
N0		No regional LN mets.
N0(i+)		<b>Isolated tumor cells (ITCs) in regional LNs no greater than 0.2 mm</b>
N1	<b>IIIC1</b>	Regional LN mets to pelvic LNs.
N1mi	<b>IIIC1</b>	Regional LN mets $>0.2$ mm, $\leq 2.0$ mm to pelvic LN.
N1a	<b>IIIC1</b>	Regional LN mets $\geq 2.0$ mm to pelvic LN.
N2	<b>IIIC2</b>	Regional LN mets to para-aortic LN, with or without pelvic LN (+).
N2mi	<b>IIIC2</b>	Regional LN mets $>0.2$ mm, $\leq 2.0$ mm to para-aortic LN.
N2a	<b>IIIC2</b>	Regional LN mets $>2.0$ mm to para-aortic LN.

- Uterine serosal involvement by full thickness myometrial invasion or by trans-tubal spread is regarded as FIGO Stage IIIA disease.
- Serosal LVSI is not considered as serosal involvement.

# Significance of LVSI

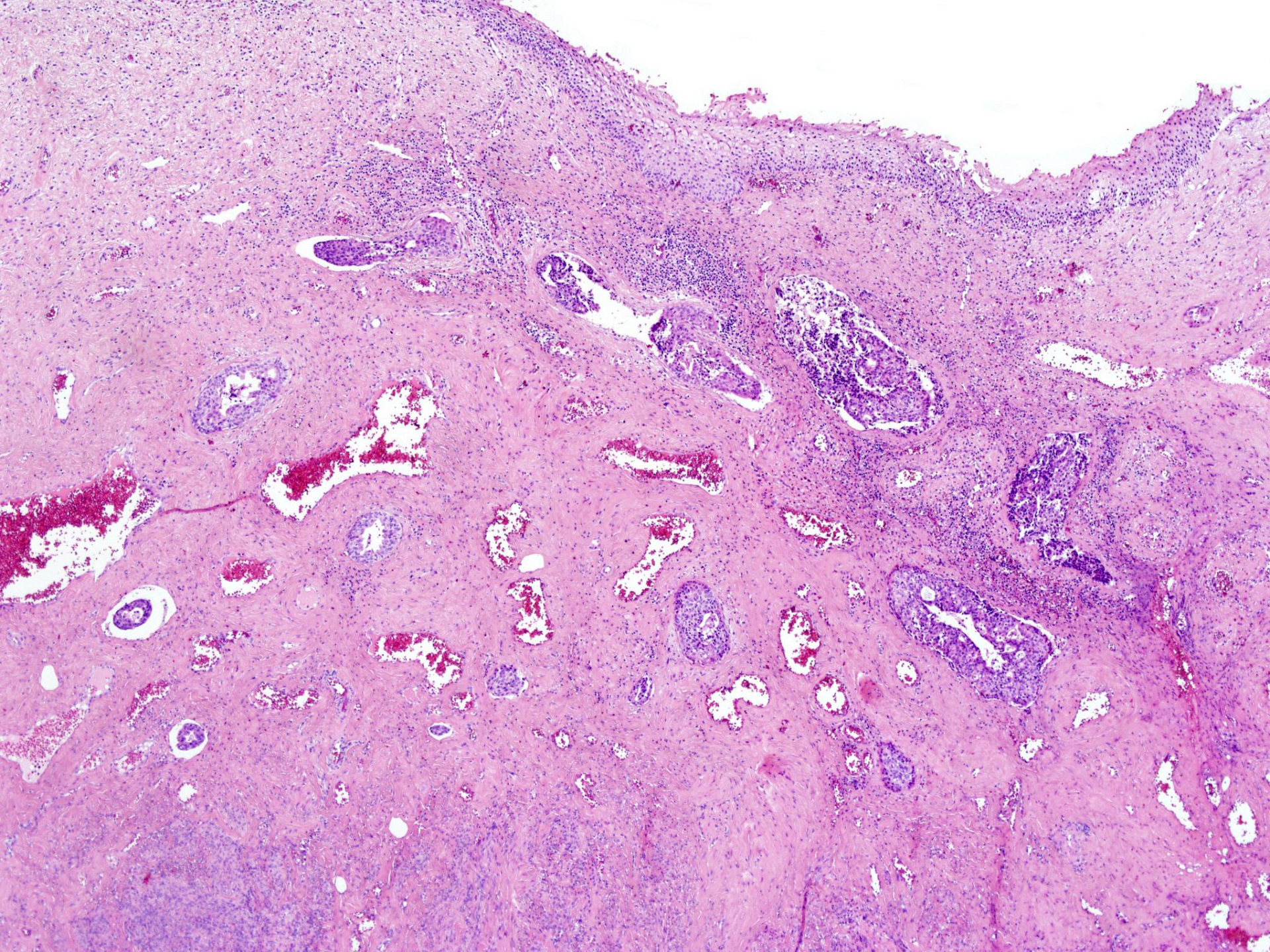
- LVSI is known as the strongest independent prognostic factor for pelvic regional recurrence, distant metastasis, and overall survival.
- Thus, the presence of LVSI should be recorded and considered for adjuvant therapy, or external beam RT.
- Nevertheless, tumors should not be upstaged based on the presence of LVSI only.

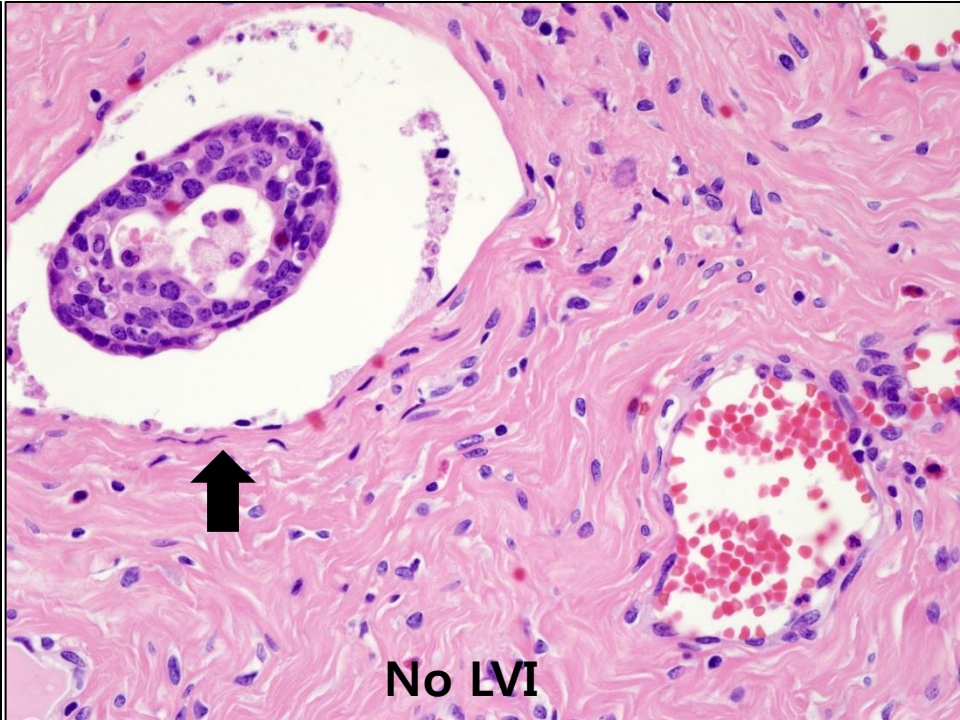
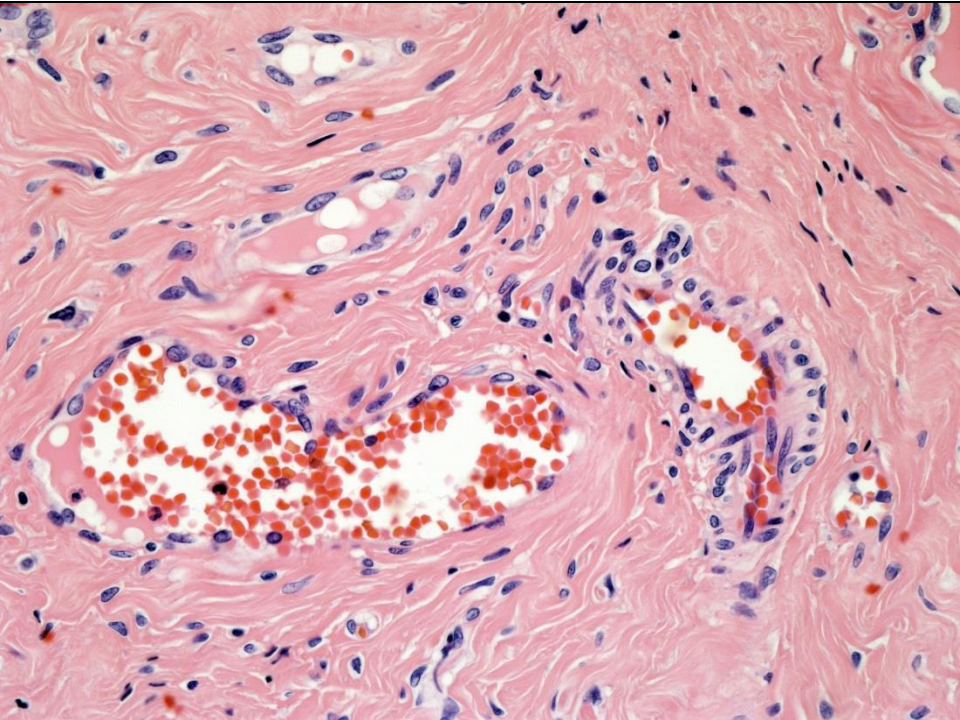
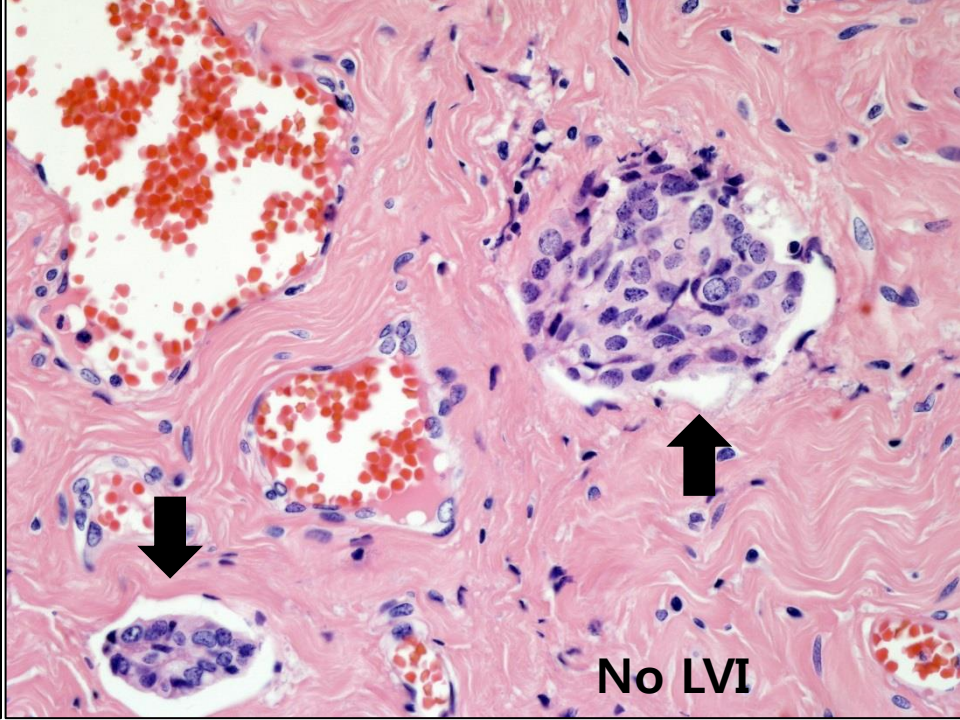
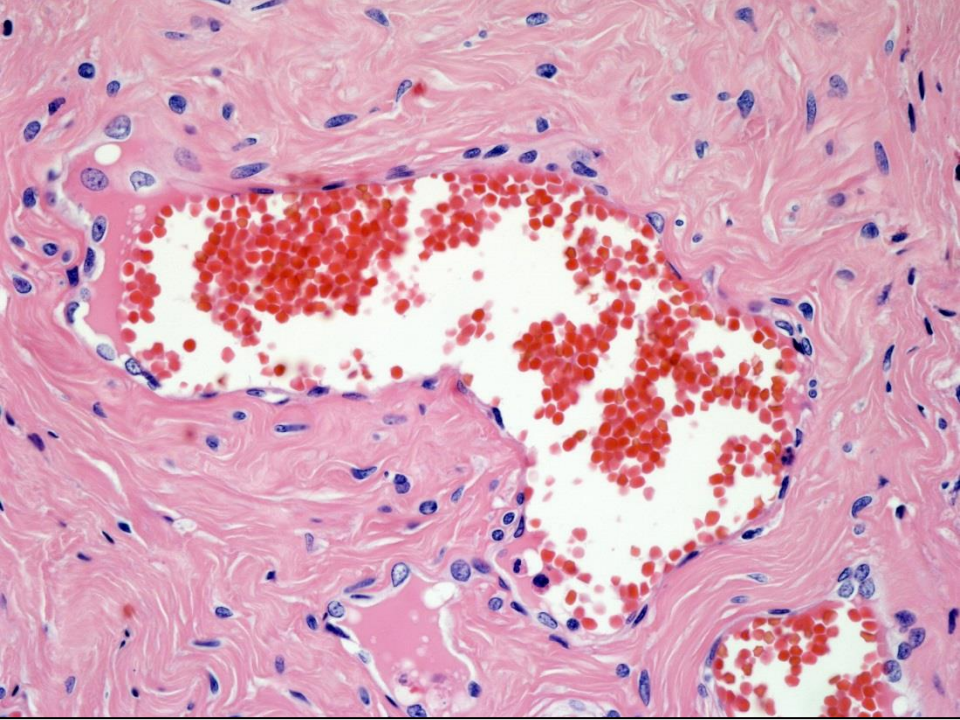
# H&E is good enough for LVSI.

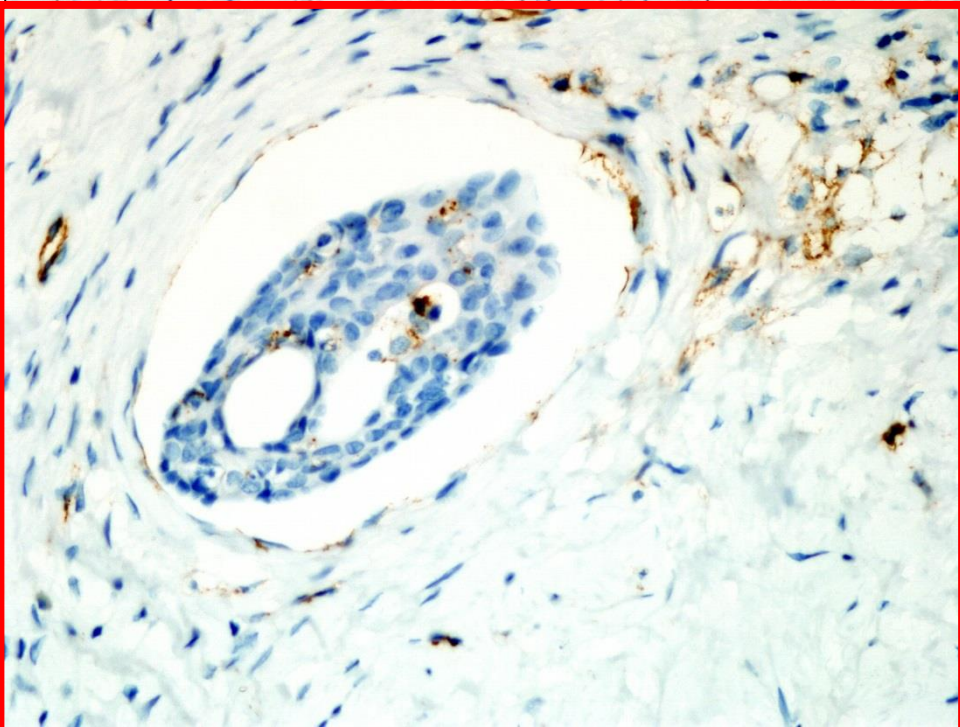
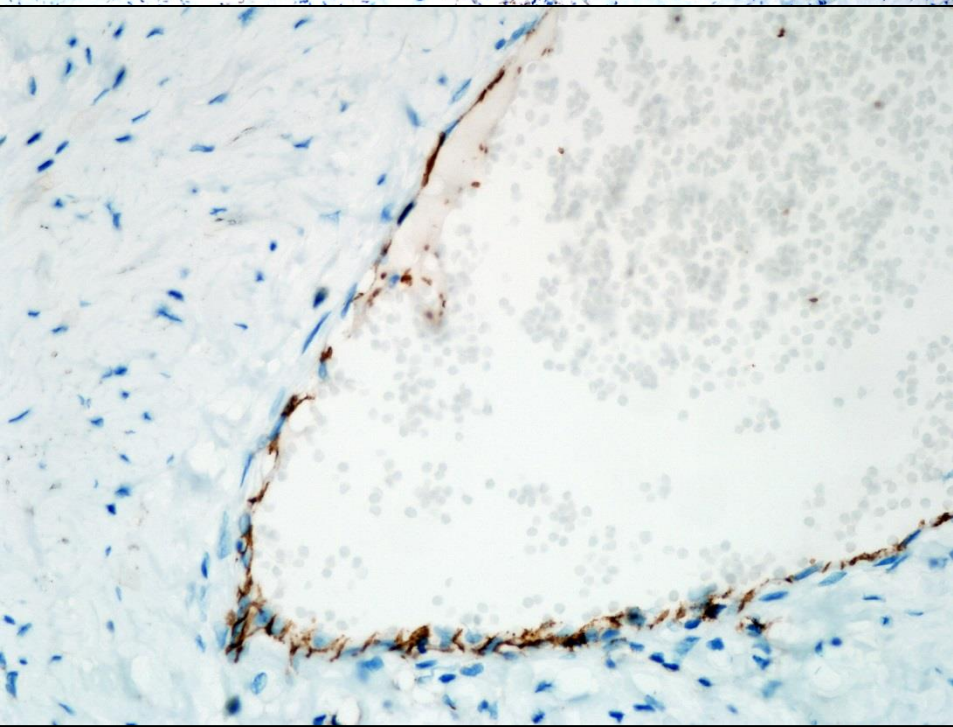
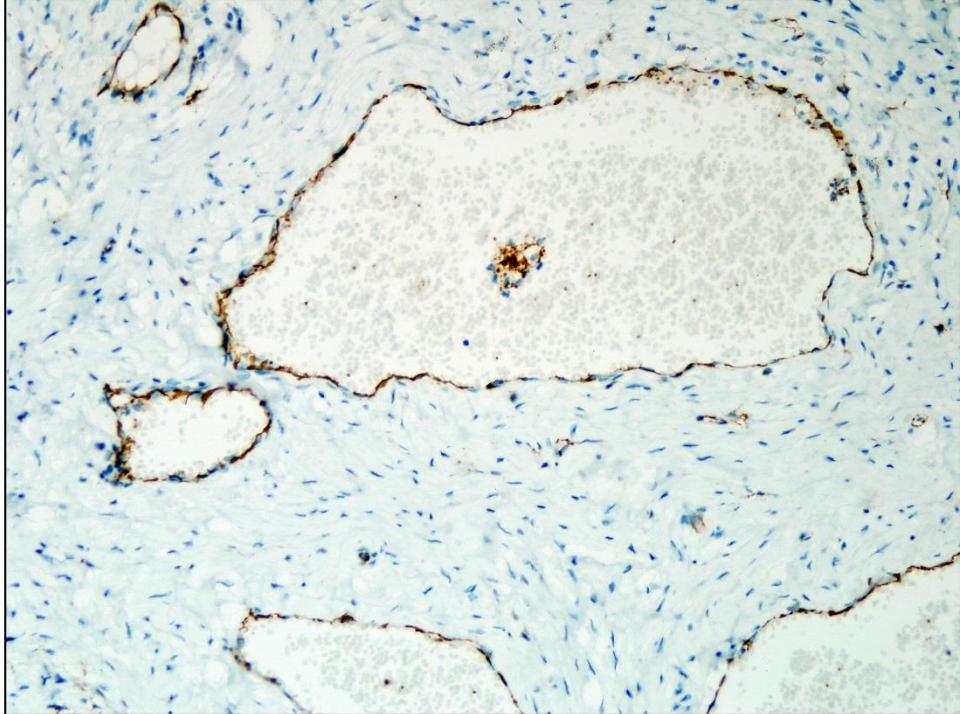
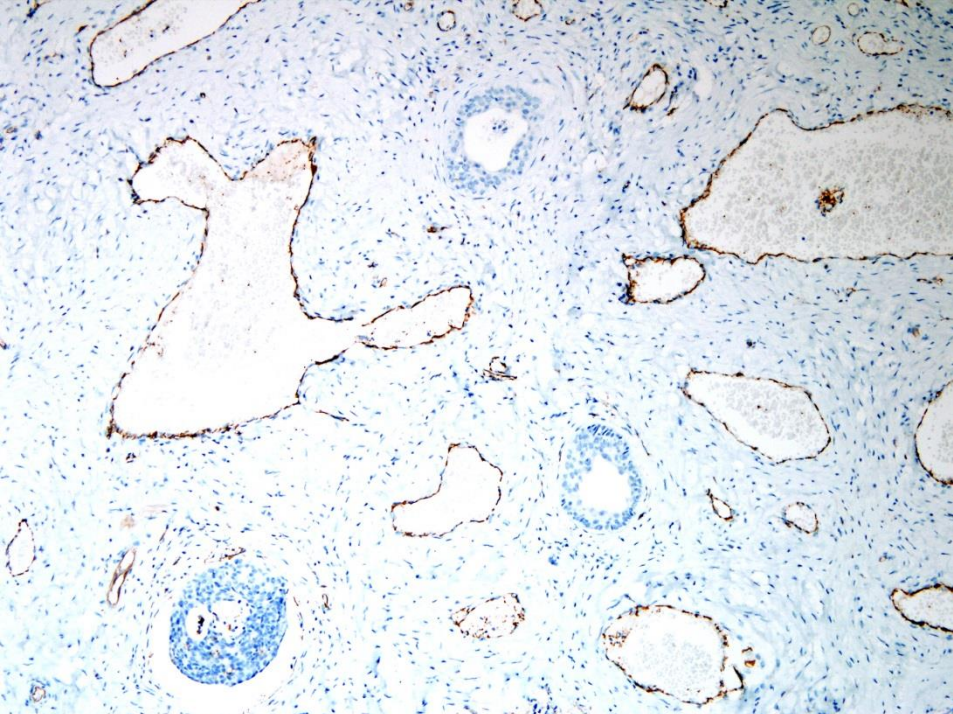


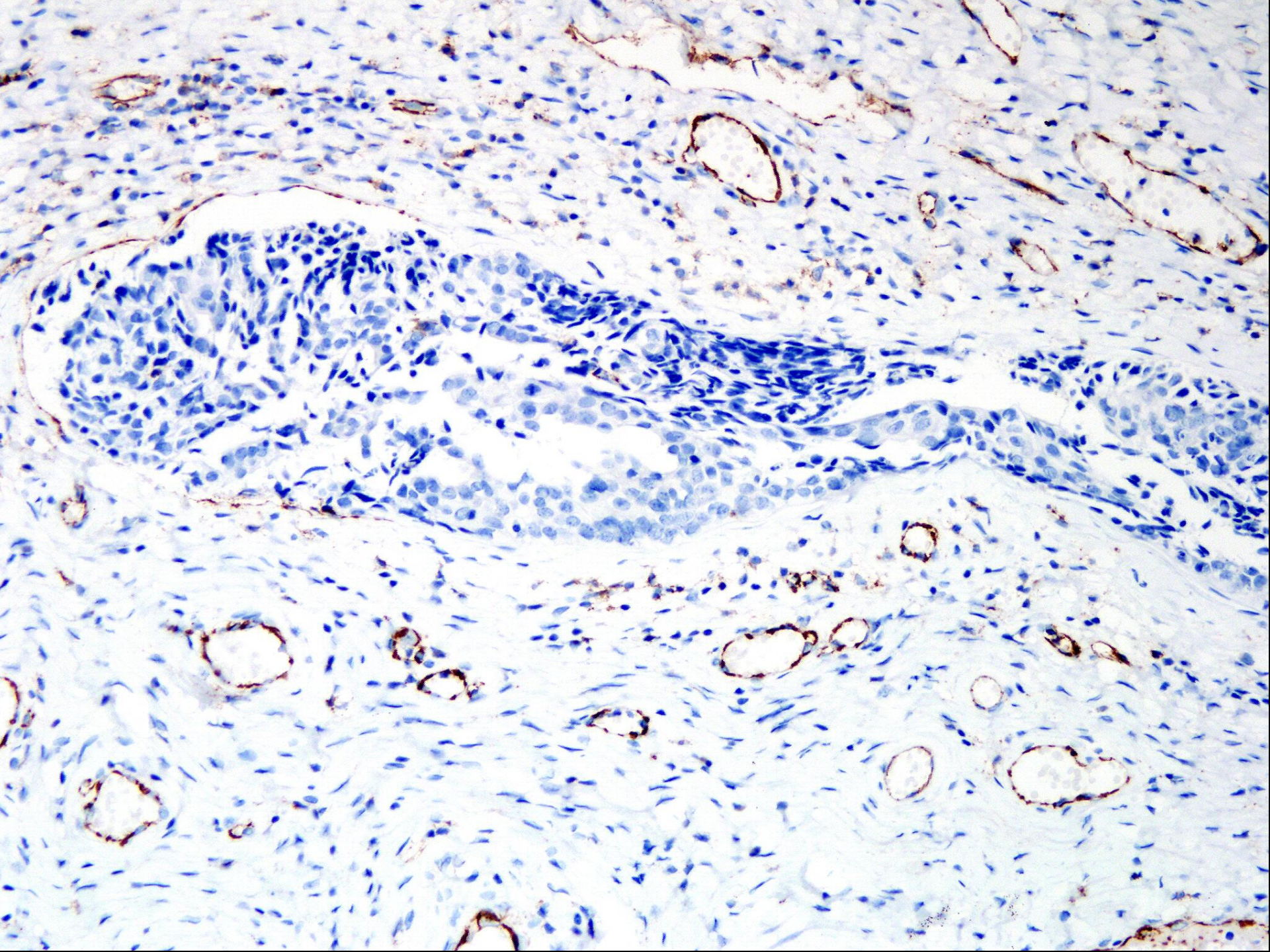
Often times, **LVSI** needs to be confirmed by endothelial marker CD31 IHC as well as histopathologic features.





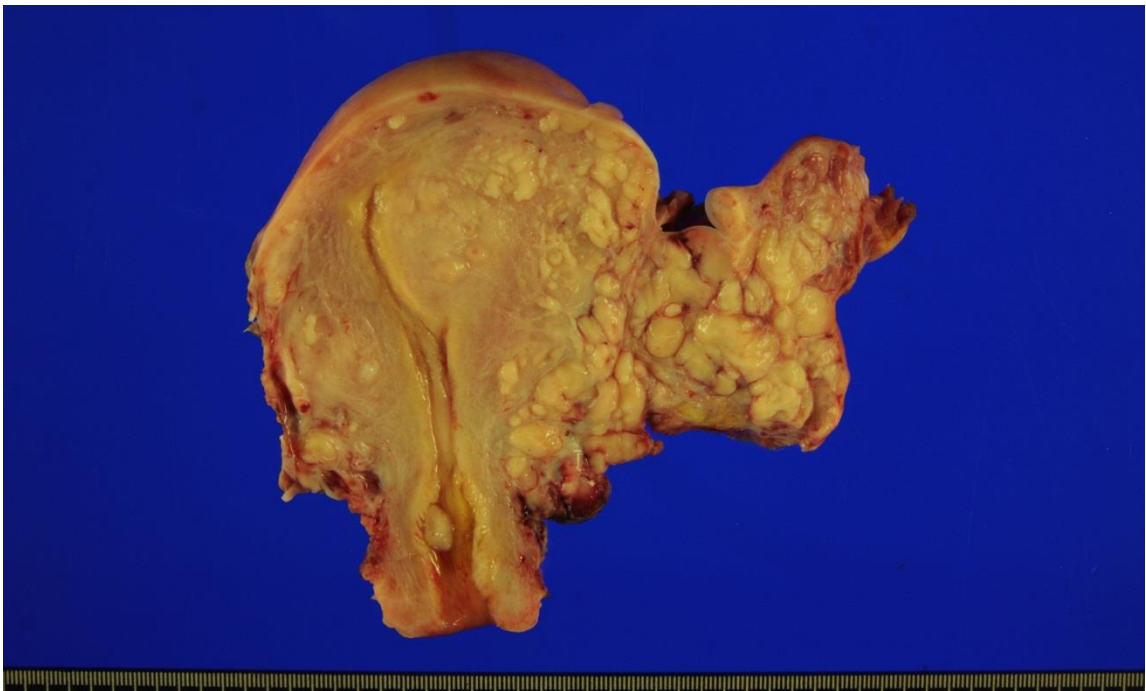
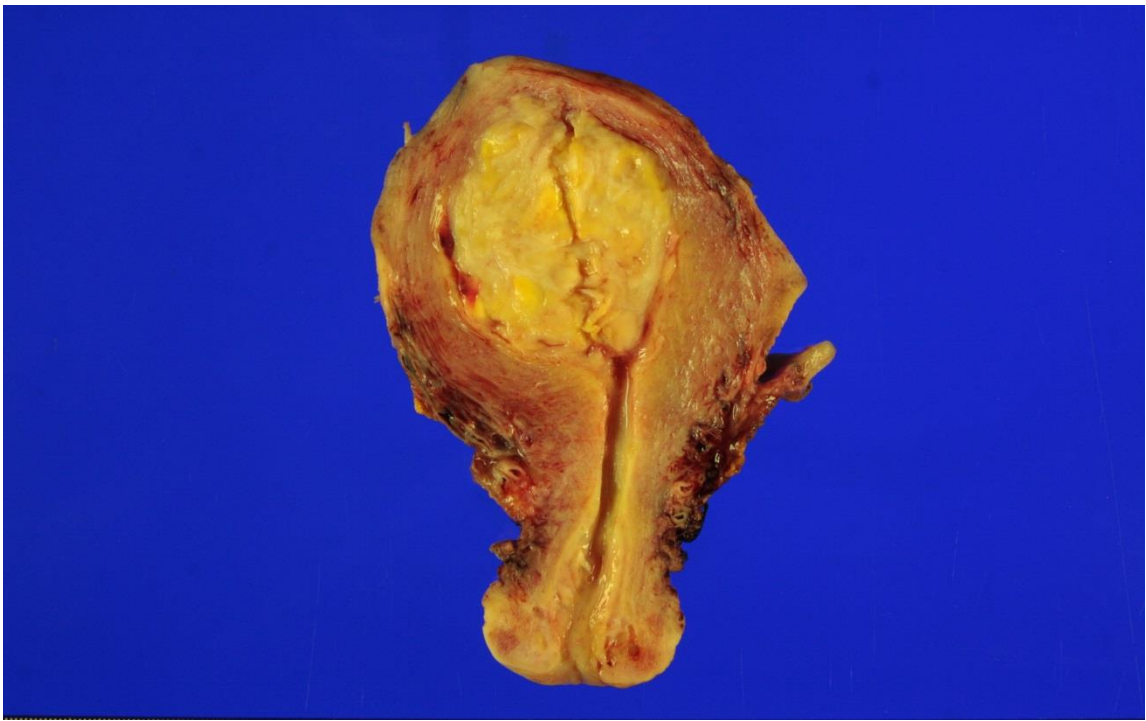






# Synchronous Uterine and Adnexal Adenocarcinomas

- Approximately 3-5% of patients with EC, and 10% of ovarian carcinoma associated with synchronous adenocarcinoma.
- Low grade, low stage, adjacent precursor lesion, no LVSI, and no deep myoinvasion.
- IHC for Vimentin; ovarian EC (-) 97%, endometrial EC (+) 82%.
- Different  $\beta$ -catenin, or MMR expression patterns.



## 2-2. Uterine Sarcoma Staging (2008)

- Uterine sarcomas were staged previously as endometrial cancers, which did not reflect clinical behavior.
- A new corpus sarcoma staging system was developed based on the criteria used in other soft tissue sarcomas.
- Data will need to be collected and evaluated for further revision.

# AJCC TNM <sup>8th</sup> for uterine sarcomas- LMS, ESS

T Category	FIGO Stage	T Criteria
TX		Primary tumor cannot be assessed
T0		No evidence of primary tumor
T1	I	Tumor limited to the uterus
T1a	IA	<b>Tumor 5cm or less</b> in greatest dimension
T1b	IB	<b>Tumor more than 5cm</b>
T2	II	Tumor extends beyond the uterus, within the pelvis
T2a	IIA	Tumor involves adnexa
T2b	IIB	Tumor involves other pelvic tissues
T3	III	Tumor infiltrates abdominal tissues
T3a	IIIA	One site
T3b	IIIB	More than one site
T4	IVA	Tumor invades bladder or rectum



# Mullerian adenosarcoma

<b>I</b>	<b>Tumor limited to uterus</b>
IA	<b>Tumor limited to endometrium/endocervix with no myometrial invasion</b>
IB	<b>Myometrial invasion to <math>&lt;1/2</math> myometrium or cervix</b>
IC	<b>Myometrial invasion to <math>\geq 1/2</math> myometrium or cervix</b>
<b>II</b>	<b>Tumor extends beyond the uterus, within the pelvis</b>
IIA	Adnexal involvement
IIB	Tumor extends to extrauterine pelvic tissue
<b>III</b>	<b>Tumor invades abdominal tissues (not just protruding into the abdomen).</b>
IIIA	One site
IIIB	More than one site
IIIC	Metastasis to pelvic and/or para-aortic lymph nodes
<b>IV</b>	
IVA	<b>Tumor invades bladder and/or rectum</b>
IVB	<b>Distant metastasis</b>

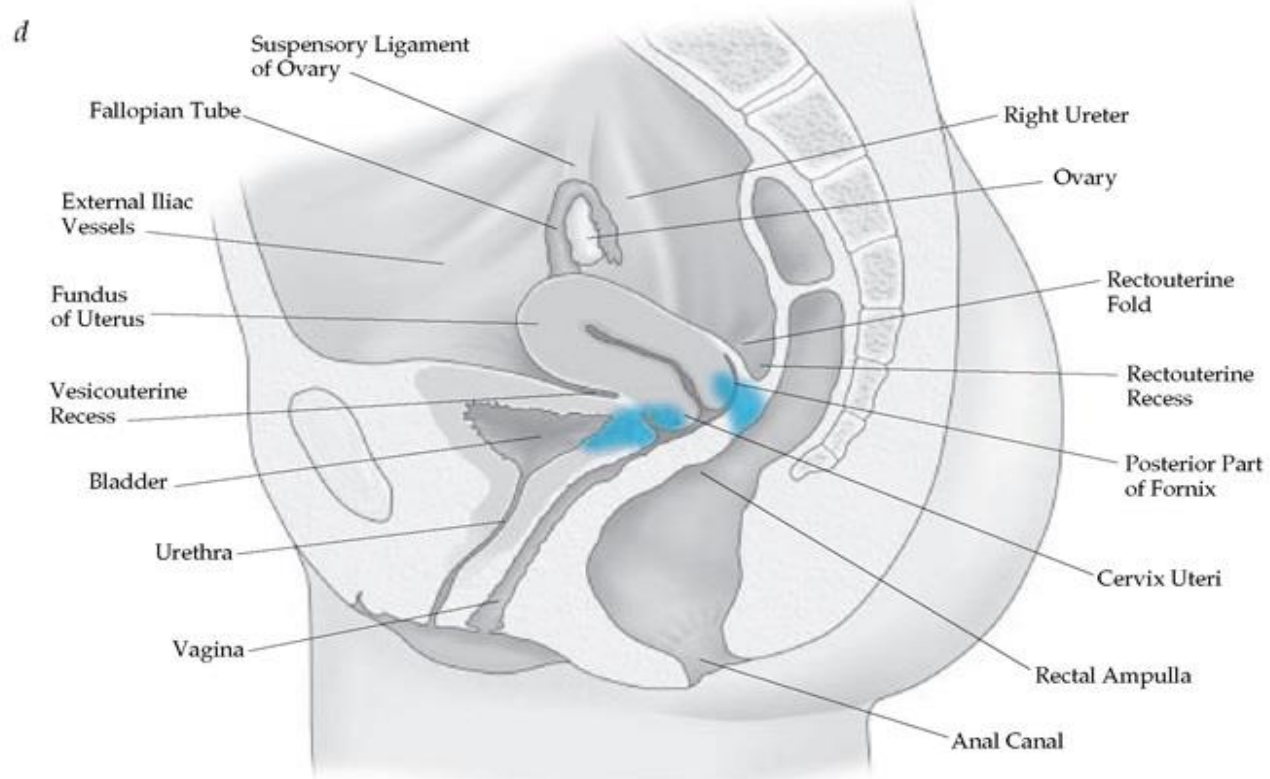
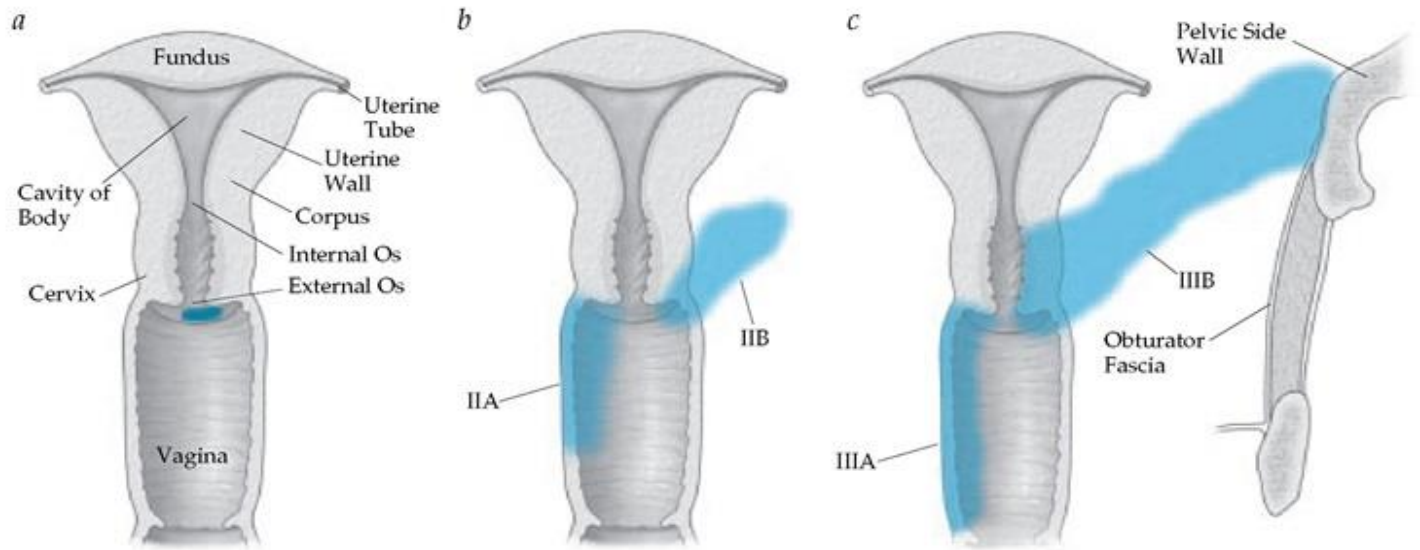
# **Carcinoma of the Uterine Cervix, clinically staged disease !!**

# Recommended examination

- Palpation
- Inspection
- Colposcopy
- Endocervical curettage
- Hysteroscopy
- Cystoscopy and/or biopsy
- Proctoscopy and/or biopsy
- Intravenous urography
- Chest X-ray
- If available, CT, MRI, or PET may replace some of the tests

# **Cervical cancer is a clinically staged disease !!**

- **The clinical stage should be determined prior to the start of treatment.**
- **It must not be changed because of subsequent findings.**
- **Many pts with cervical cancer are treated by RTX and never undergo surgery.**
- **Results of additional radiologic and histopathologic findings are not used to determine clinical staging, but used to develop a postop. treatment plan and prognostic information.**



# T category for AJCC TNM 8th

T Category	FIGO Stage	T Criteria
TX		Primary tumor cannot be assessed
T0		No evidence of primary tumor
T1	I	Cervical carcinoma confined to the uterus.
T1a	IA	Invasive carcinoma diagnosed only by microscopy
T1a1	IA1	DOI $\leq$ 3mm, Horizontal spread $\leq$ 7mm
T1a2	IA2	DOI $>$ 3mm, Horizontal spread $\leq$ 7mm
T1b	IB	All clinically visible lesion confined to the uterine cervix or microscopic lesion greater than T1a/1A2
T1b1	IB1	Clinically visible lesion $\leq$ 4.0cm
T1b2	IB2	Clinically visible lesion $>$ 4cm
T2	II	Cervical cancer beyond the uterus, but not to the pelvic wall
T2a	IIa	Tumor without parametrial invasion
	IIa1	Clinically visible lesion $\leq$ 4.0cm
	IIa2	Clinicly visible lesion $>$ 4.0 cm

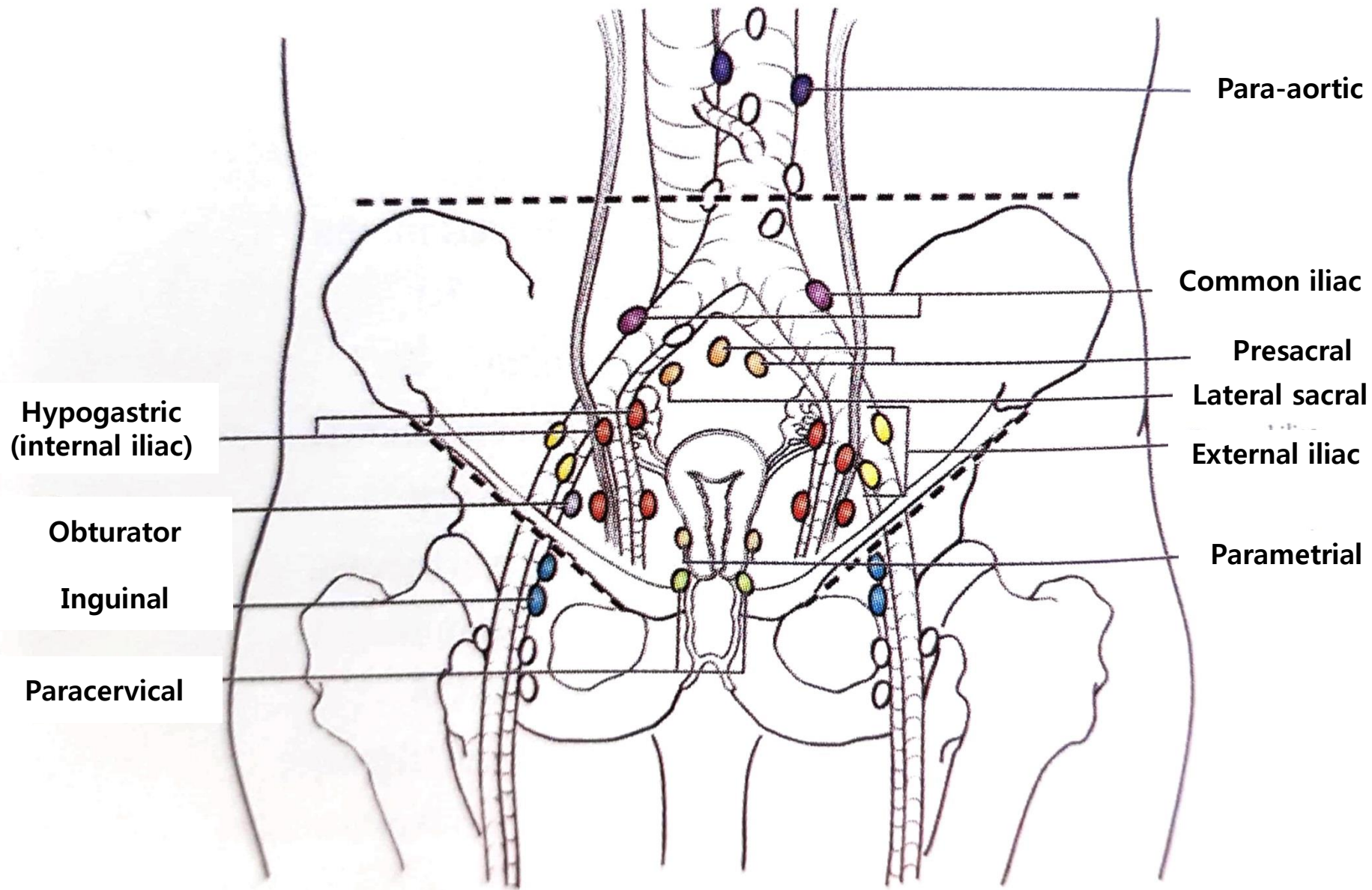
# N & M category for AJCC TNM 8th

<b>N Category</b>	<b>FIGO Stage</b>	<b>Criteria</b>
<b>NX</b>		<b>Regional LN cannot be assessed</b>
<b>N0</b>		<b>No regional LN metastasis</b>
<b>No (i+)</b>		<b>Isolated tumor cells in regional LN, no greater than 0.2 mm</b>
<b>N1</b>		<b>Regional LN metastasis</b>
<b>M0</b>		<b>No distant metastasis</b>
<b>M1</b>	<b>IVB</b>	<b>Distant metastasis including peritoneal spread or involvement of the supraclavicular, mediastinal or distant LN; lung, or bone</b>

# AJCC Prognostic Stage Grouping

<b>T Category</b>	<b>Any N is..</b>	<b>Stage Grouping</b>
<b>T1</b>	<b>Any N</b>	<b>I</b>
<b>T1a</b>	<b>Any N</b>	<b>IA</b>
<b>T1a1</b>	<b>Any N</b>	<b>IA1</b>
<b>T1a2</b>	<b>Any N</b>	<b>1A2</b>
<b>T1b</b>	<b>Any N</b>	<b>1B</b>
<b>T1b1</b>	<b>Any N</b>	<b>1B1</b>
<b>T1b2</b>	<b>Any N</b>	<b>1B2</b>
<b>T2</b>	<b>Any N</b>	<b>II</b>
<b>T2a</b>	<b>Any N</b>	<b>IIA</b>
<b>T2a1</b>	<b>Any N</b>	<b>IIA2</b>
<b>T2a2</b>	<b>Any N</b>	<b>IIA2</b>
<b>T3</b>	<b>Any N</b>	<b>III</b>
<b>T3a</b>	<b>Any N</b>	<b>IIIA</b>
<b>T3b</b>	<b>Any N</b>	<b>IIIB</b>
<b>T4</b>	<b>Any N</b>	<b>IVA</b>





# Regional LNs

- Parametrial
- Obturator
- Internal iliac (hypogastric)
- External iliac
- Sacral
- Presacral
- Common iliac
- **Para-aortic**

# AJCC 8<sup>th</sup>- Summary of changes

- N1 (pelvic LN mets) was removed from FIGO Stage IIIB
- Para-aortic nodes mets removed from M1 in AJCC stage
- Mediastinal or supraclavicular LN involvement is considered distant metastasis and is assigned M1.

# Stage 1A is diagnosed only by microscopy.

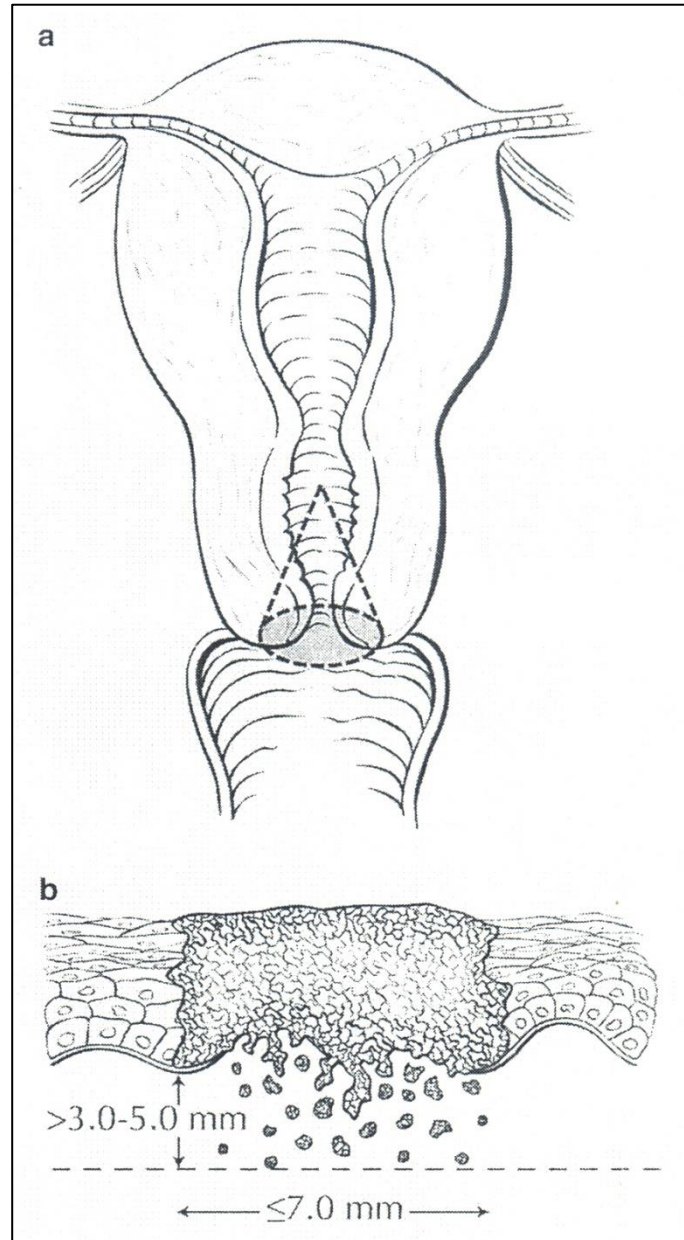
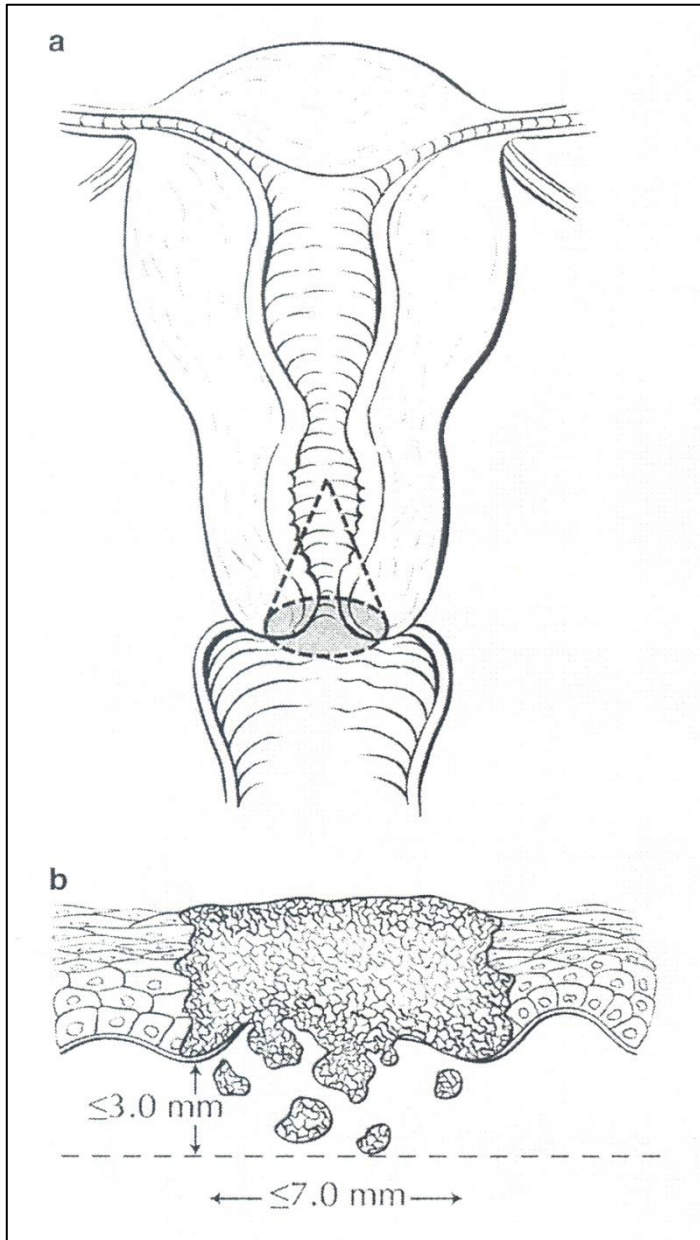
IA1. Depth <3 mm, less than 7mm in lateral spread

IA2. Depth 3-5mm, less than 7 mm in lateral spread.

## Pathology Report

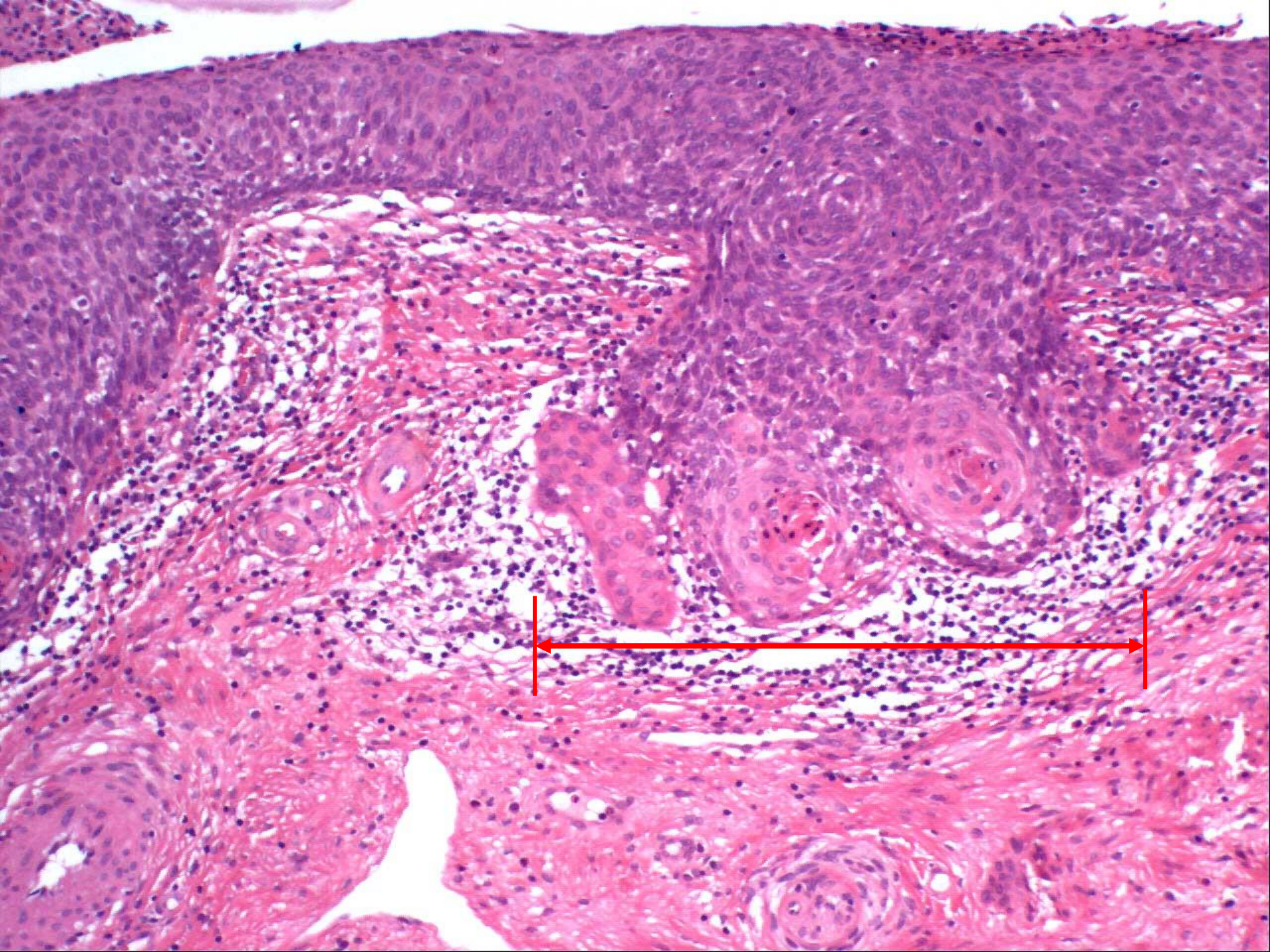
### Uterine cervix, LEEP conization :

- Superficially invasive squamous cell carcinoma, MD
- Depth of invasion
- Lateral (horizontal) spread or width
- LVI +/-
- Resection margin +/- ; endocervical, exocervical, and deep



**How to measure and stage  
in cases with multifocal stromal  
invasion ?**

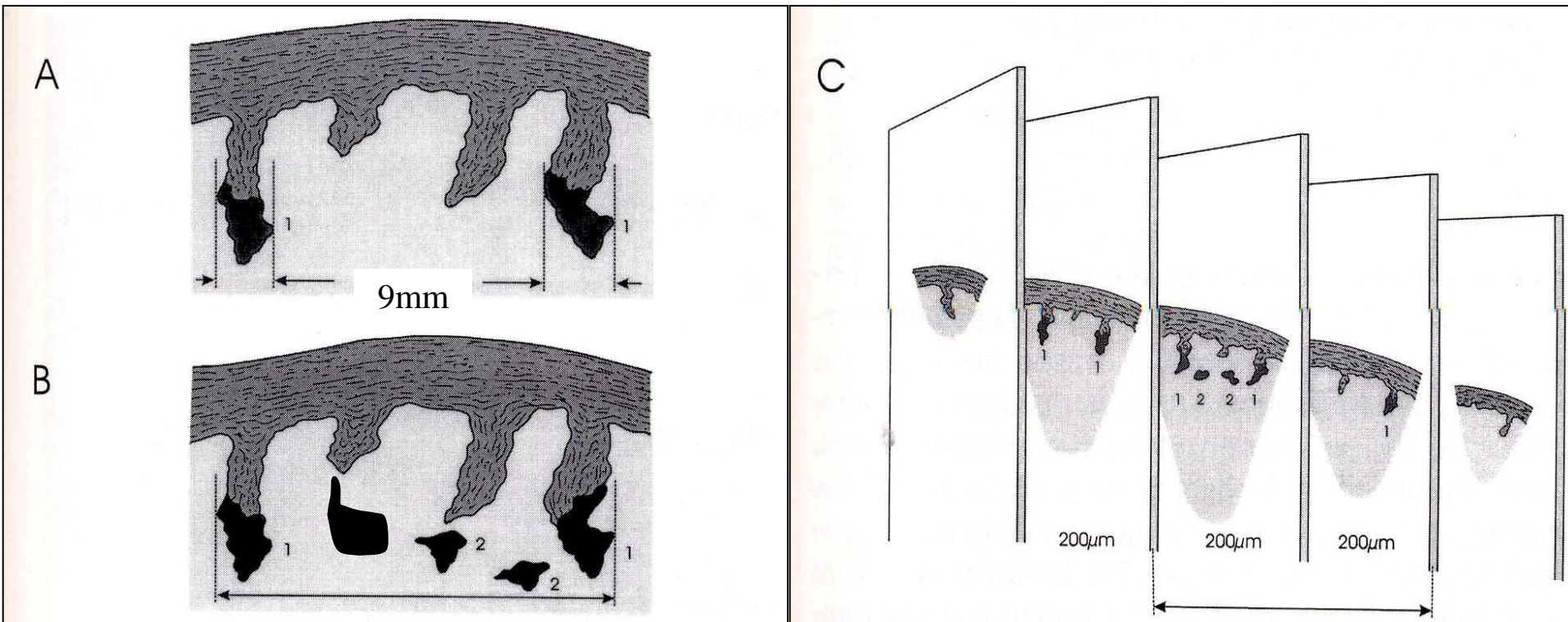
**FIGO definition provides NO detail on  
how to measure horizontal spread.**



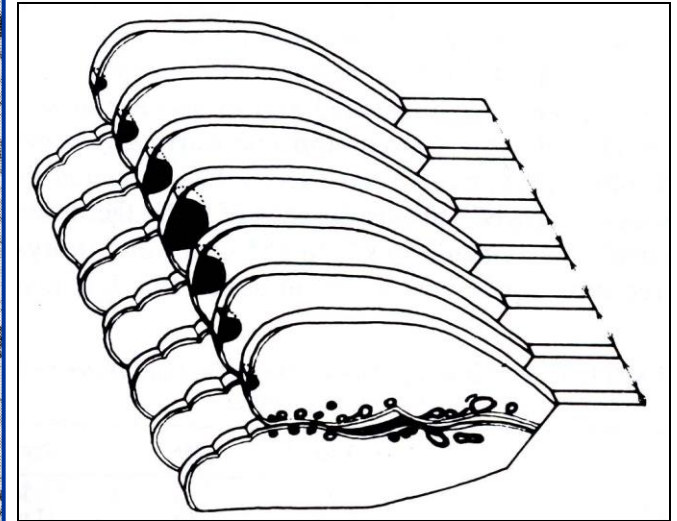
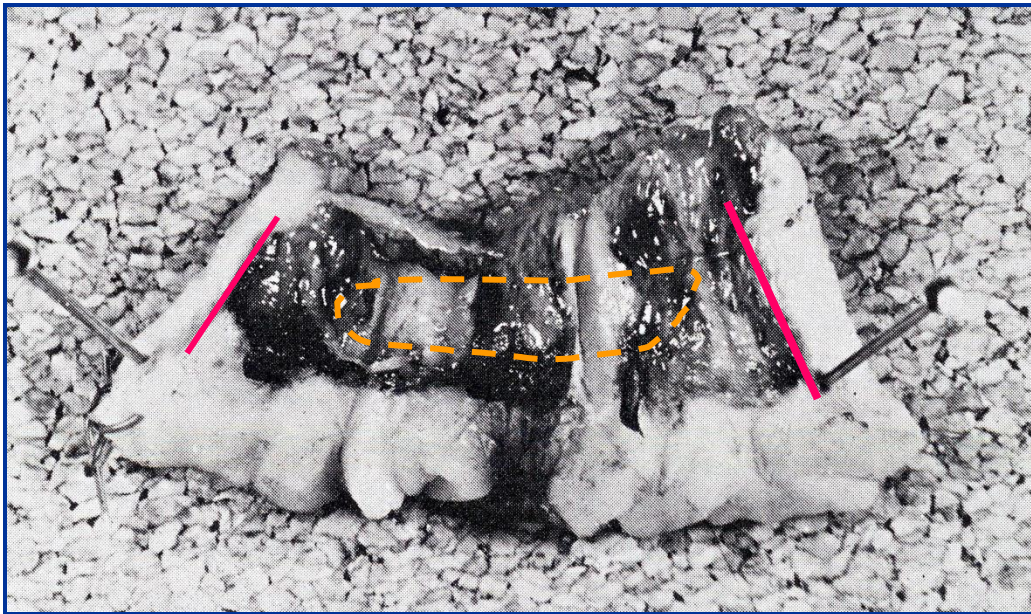
# Lateral extent

Are they FIGO Ia1, Ia2 or Ib ?

Is it “HSIL with multiple foci of microinvasion” ?



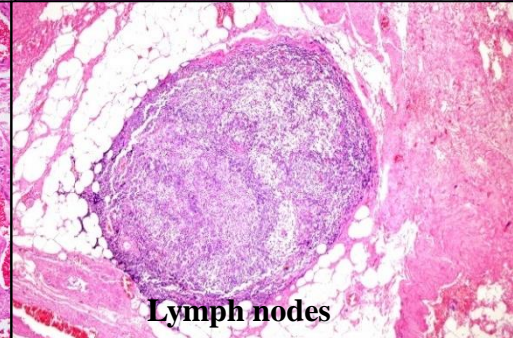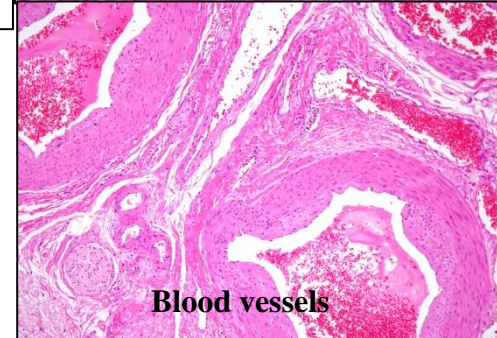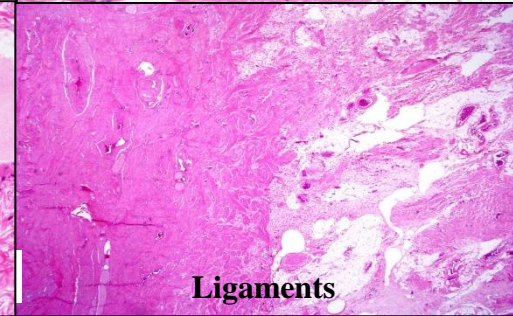
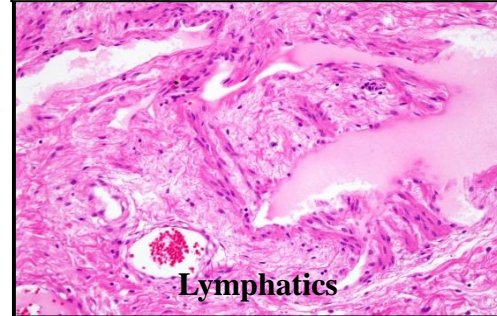
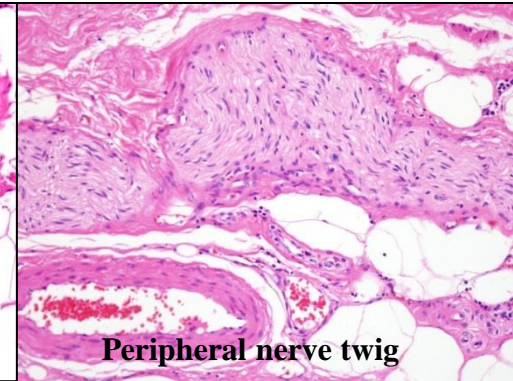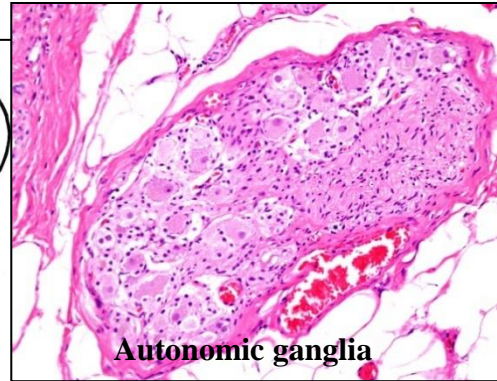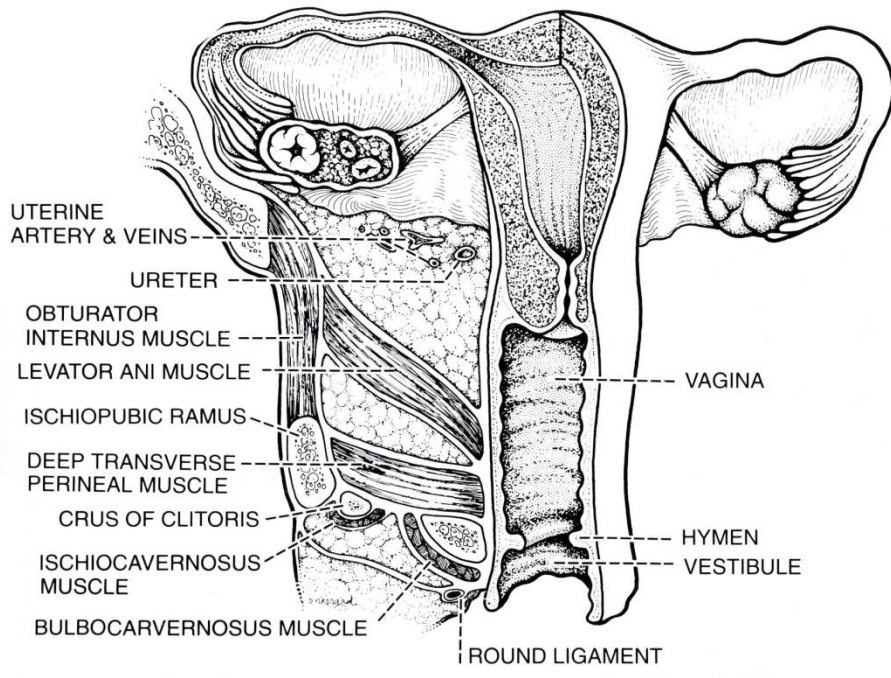




- ✓ **Width : number of involved sections x thickness of each section**
- ✓ **Measure the width of invasive carcinoma only.**

# Parametrium ( = Paracervix )

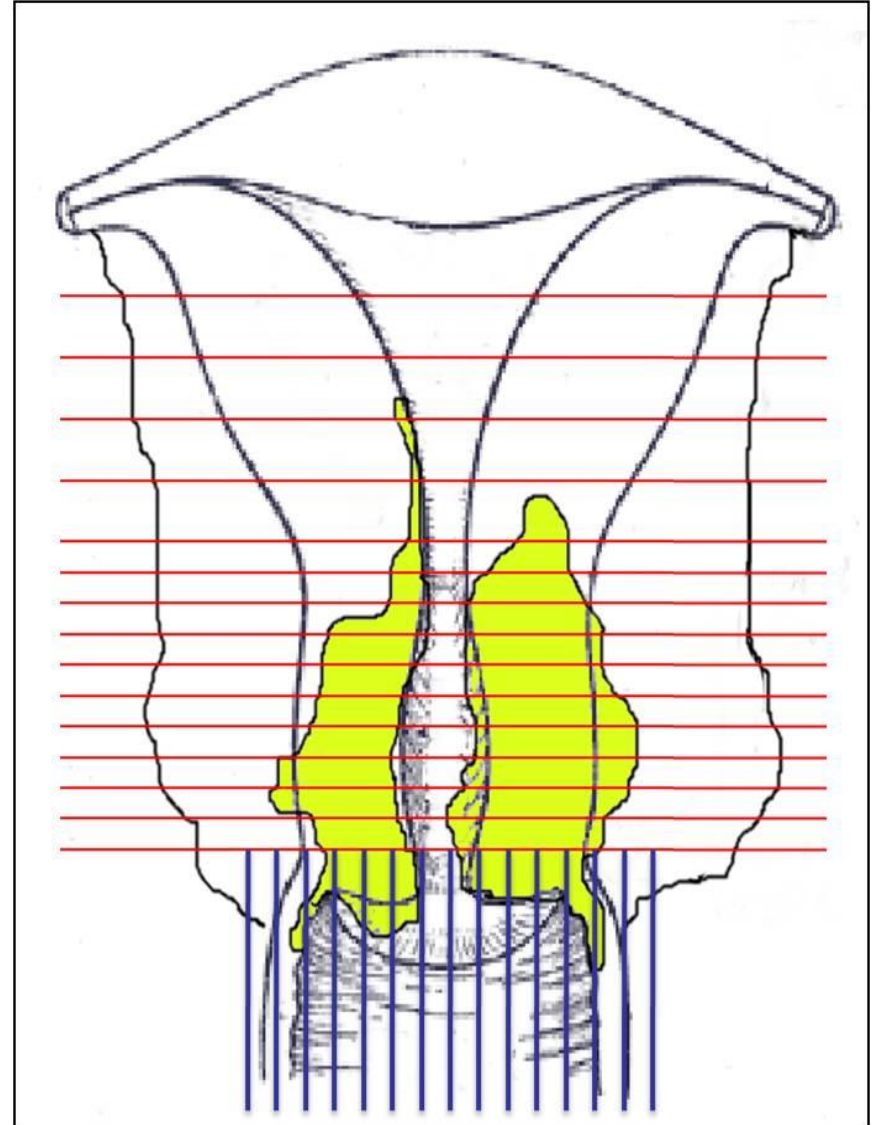
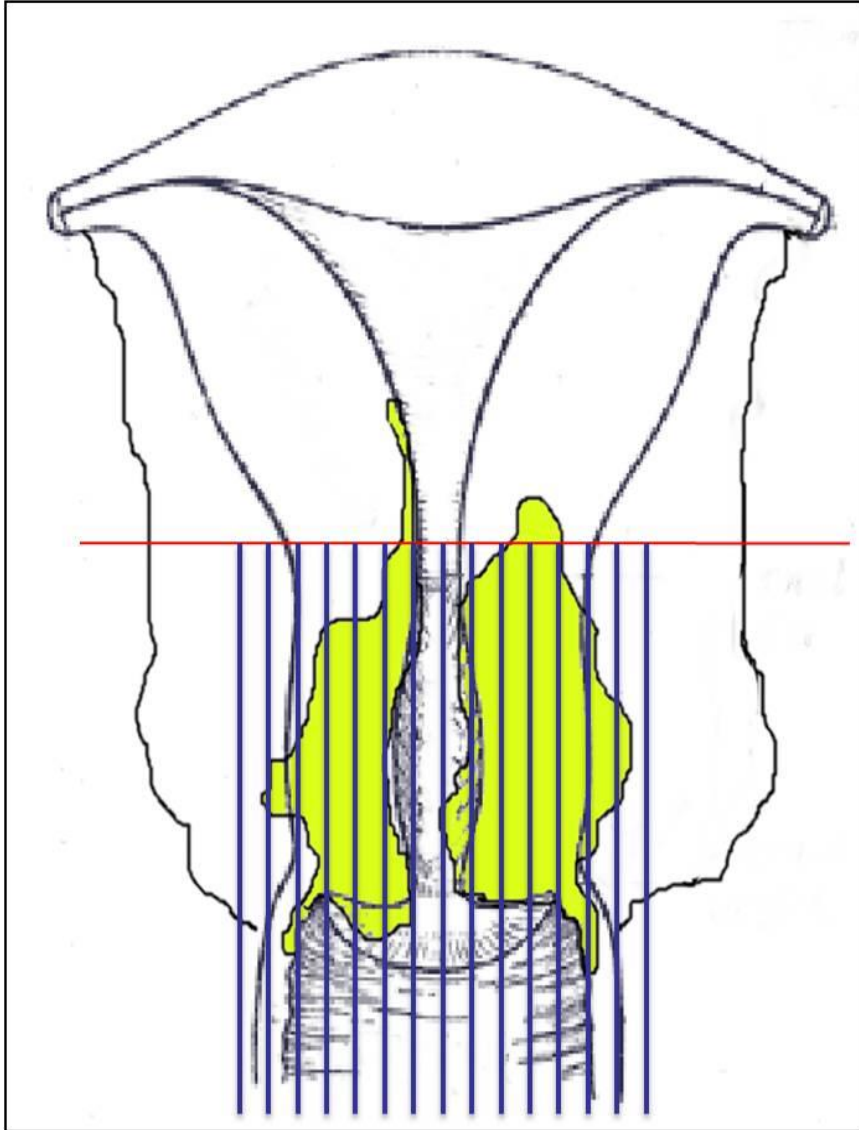
The extension of the subserous coat of the uterus laterally between the layers of the broad ligament.

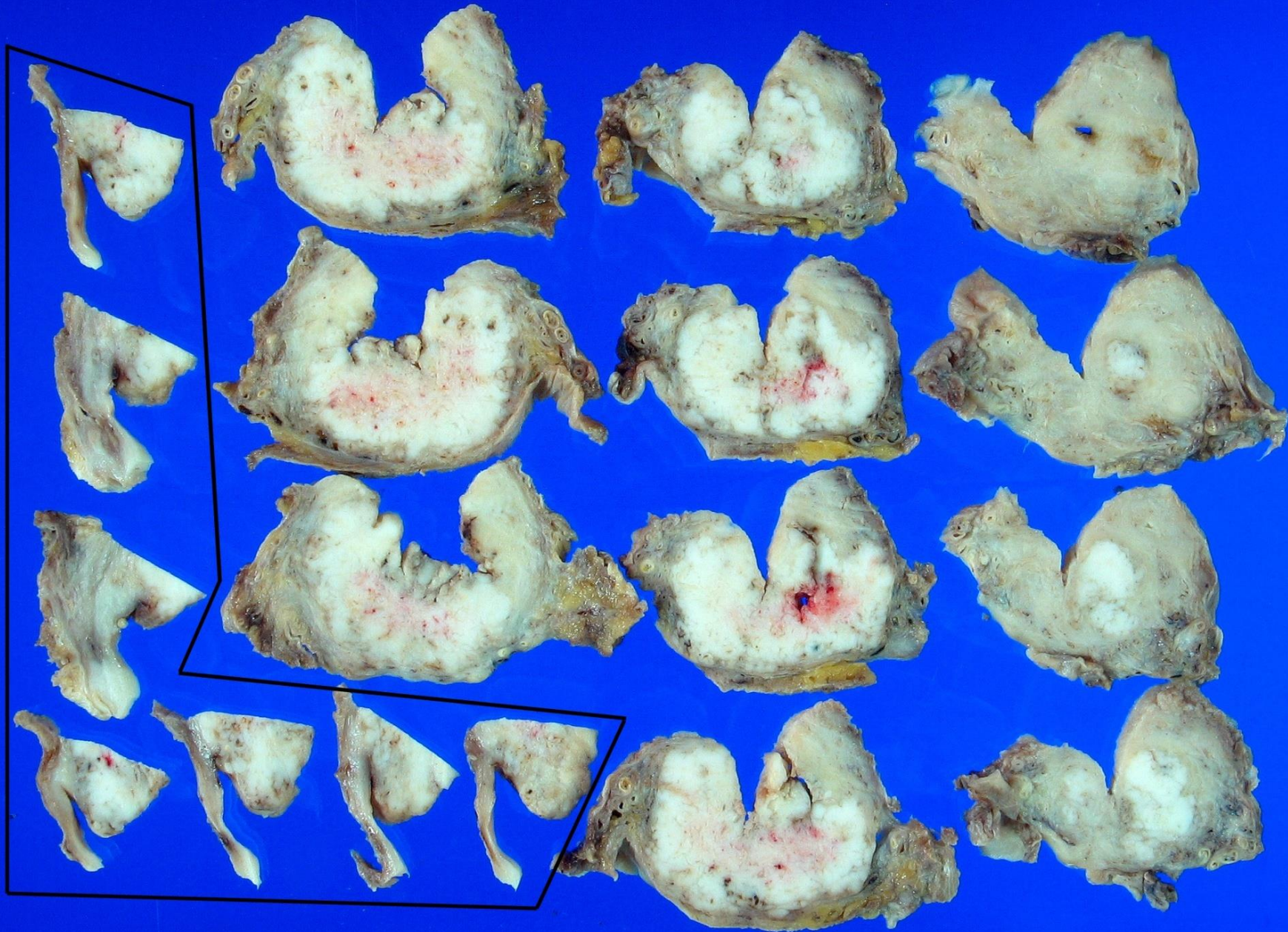


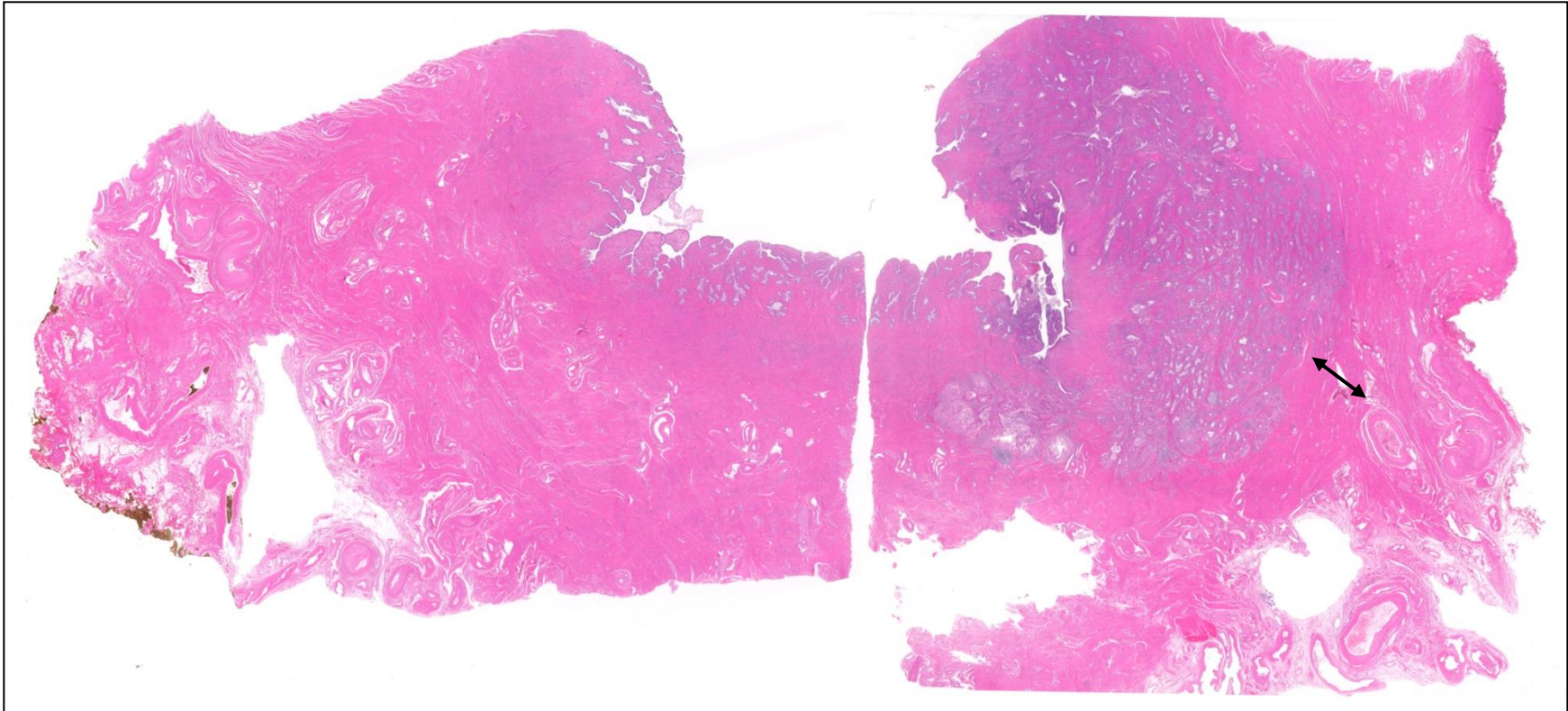
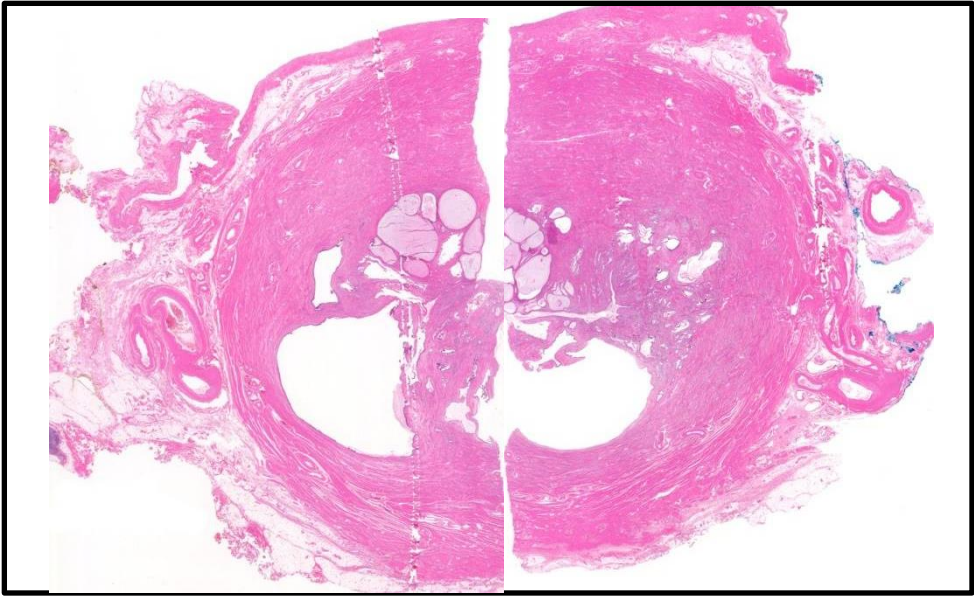
# Why is PI So Important ?

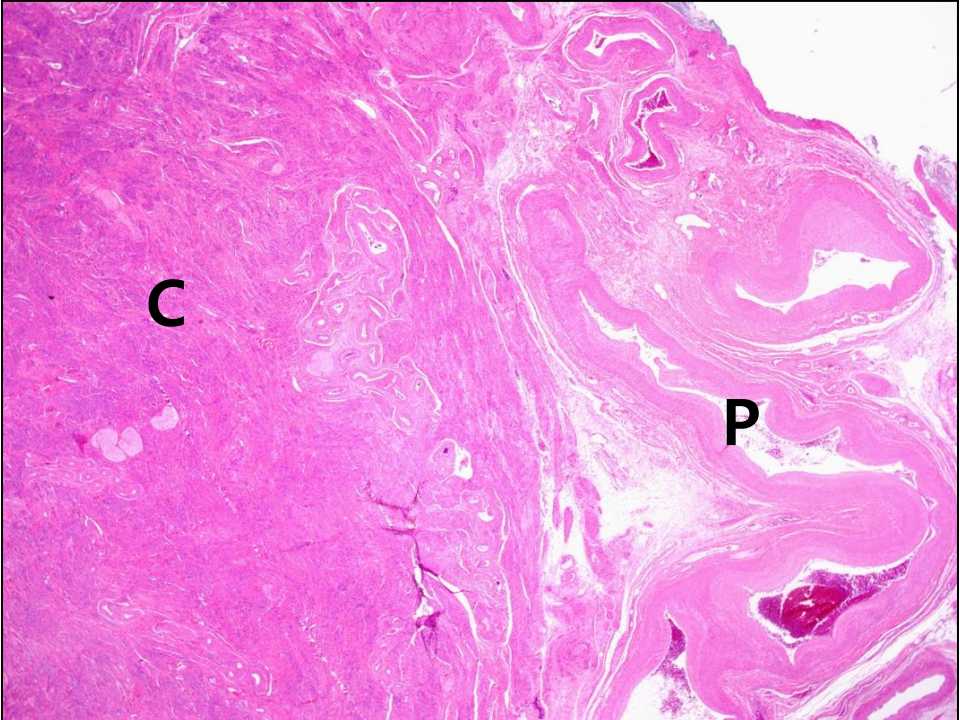
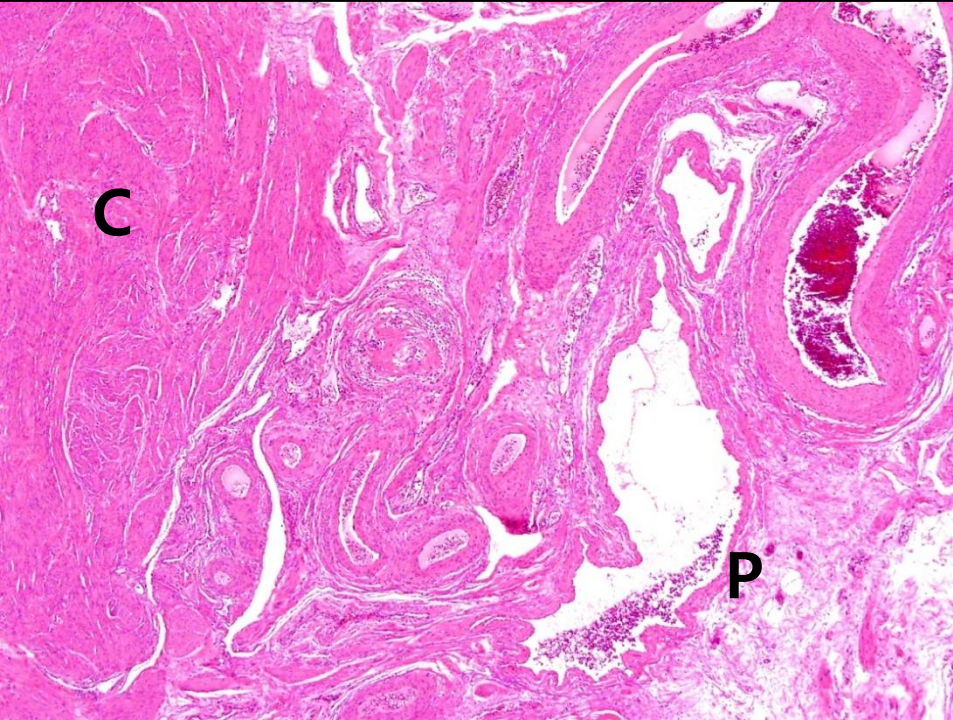
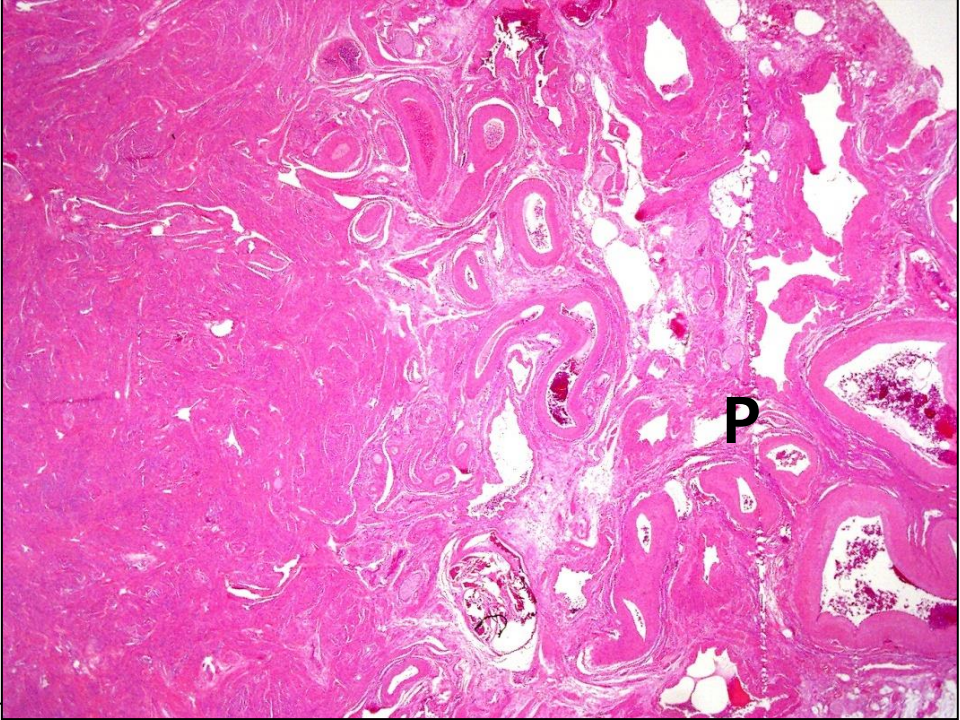
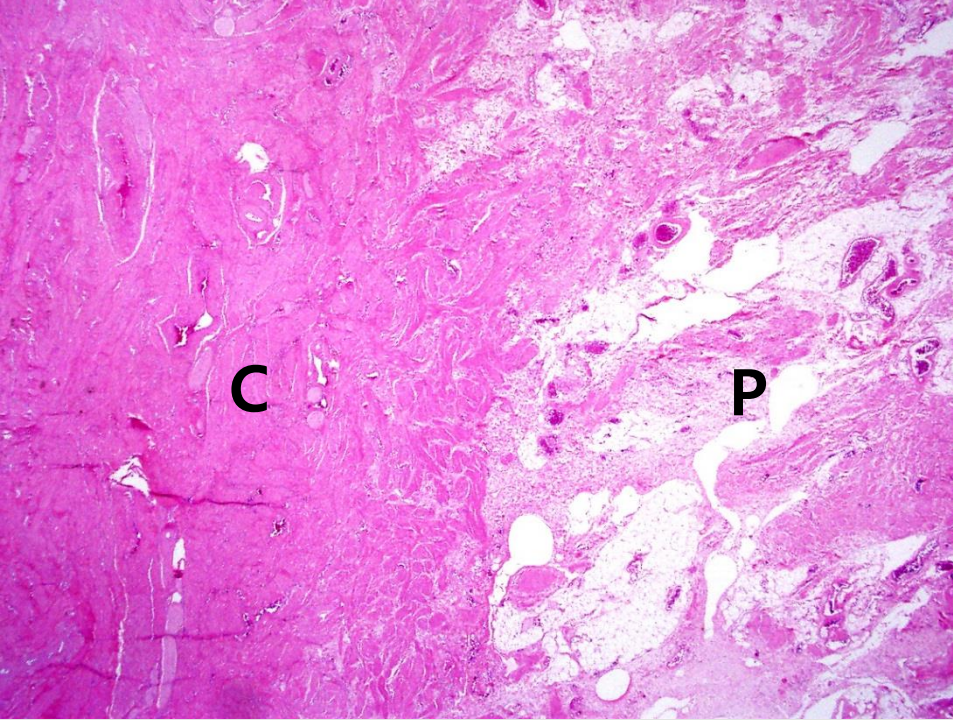
- Significantly associated with high histological grade, LVI, tumor size, advanced stage, uterine or vaginal involvement, and pelvic or para-aortic LN metastases.
- Early stage disease (I-IIa) can be treated with either radical surgery or radiation, **whereas advanced stage disease (IIb-IV) is best treated with chemotherapy and radiation Tx.**
- PI is closely related to tumor recurrence and survival rate.

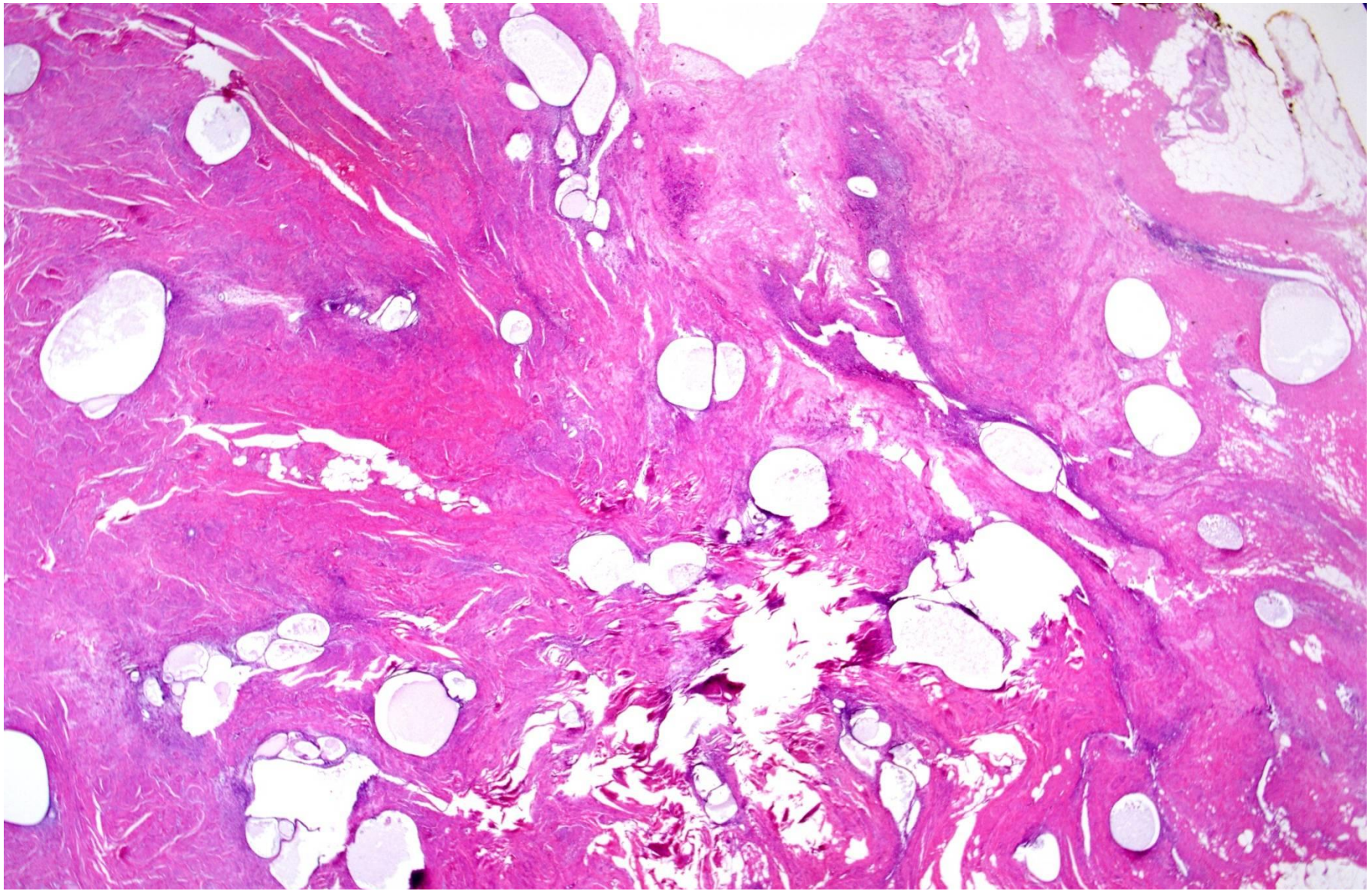
# Sectioning Methods





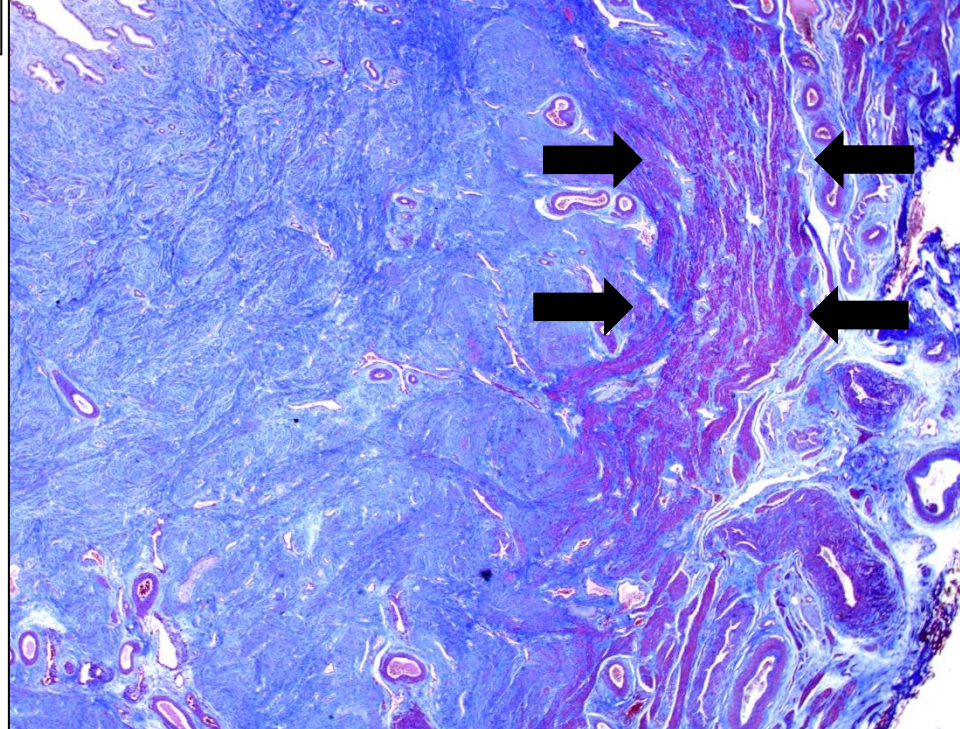
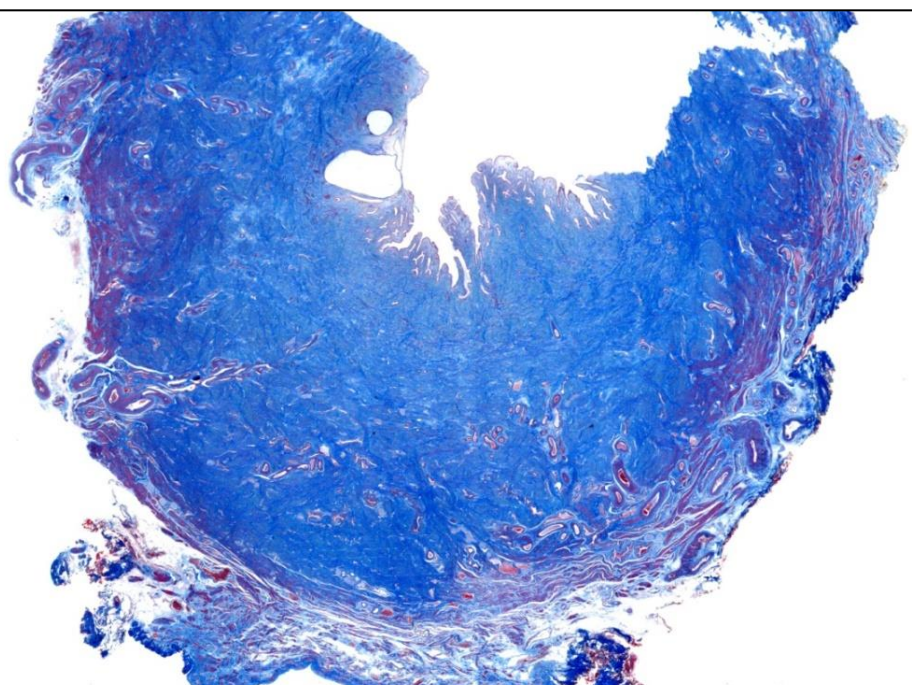
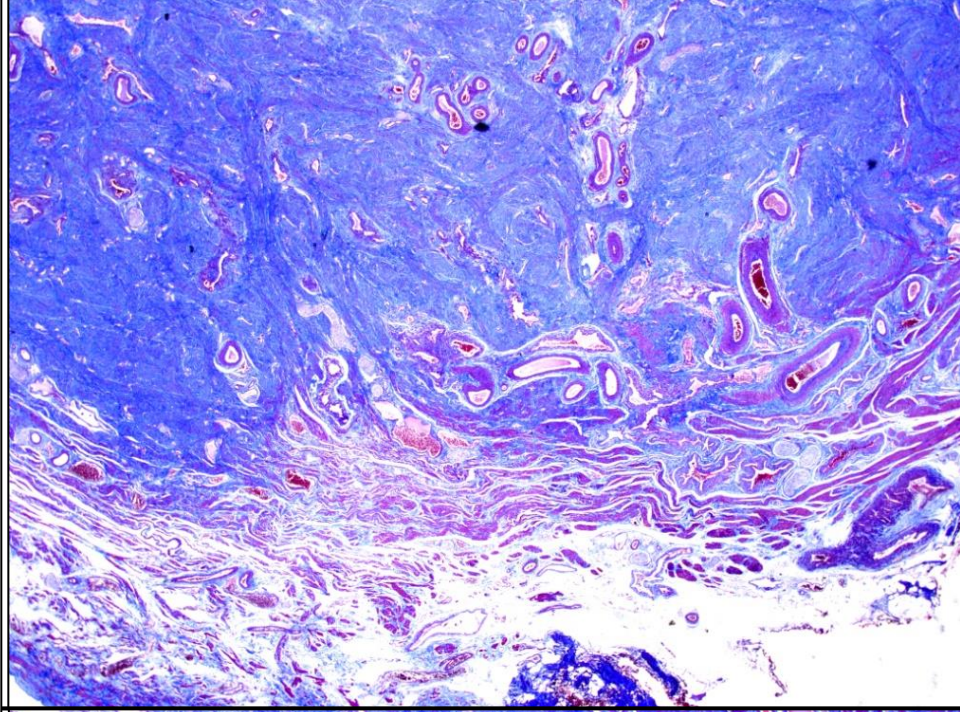
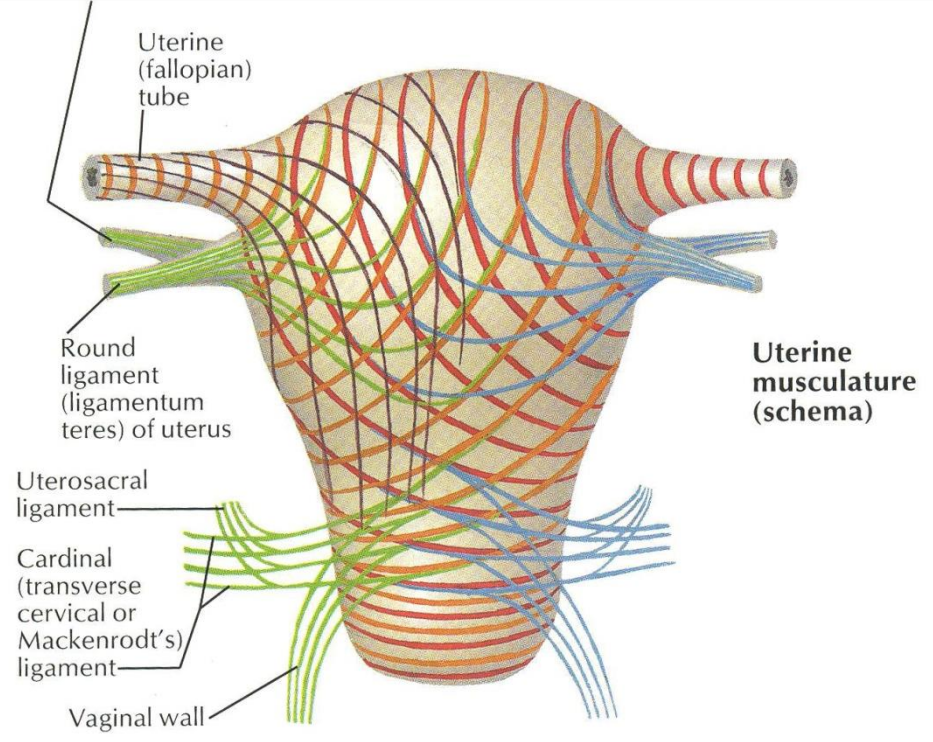


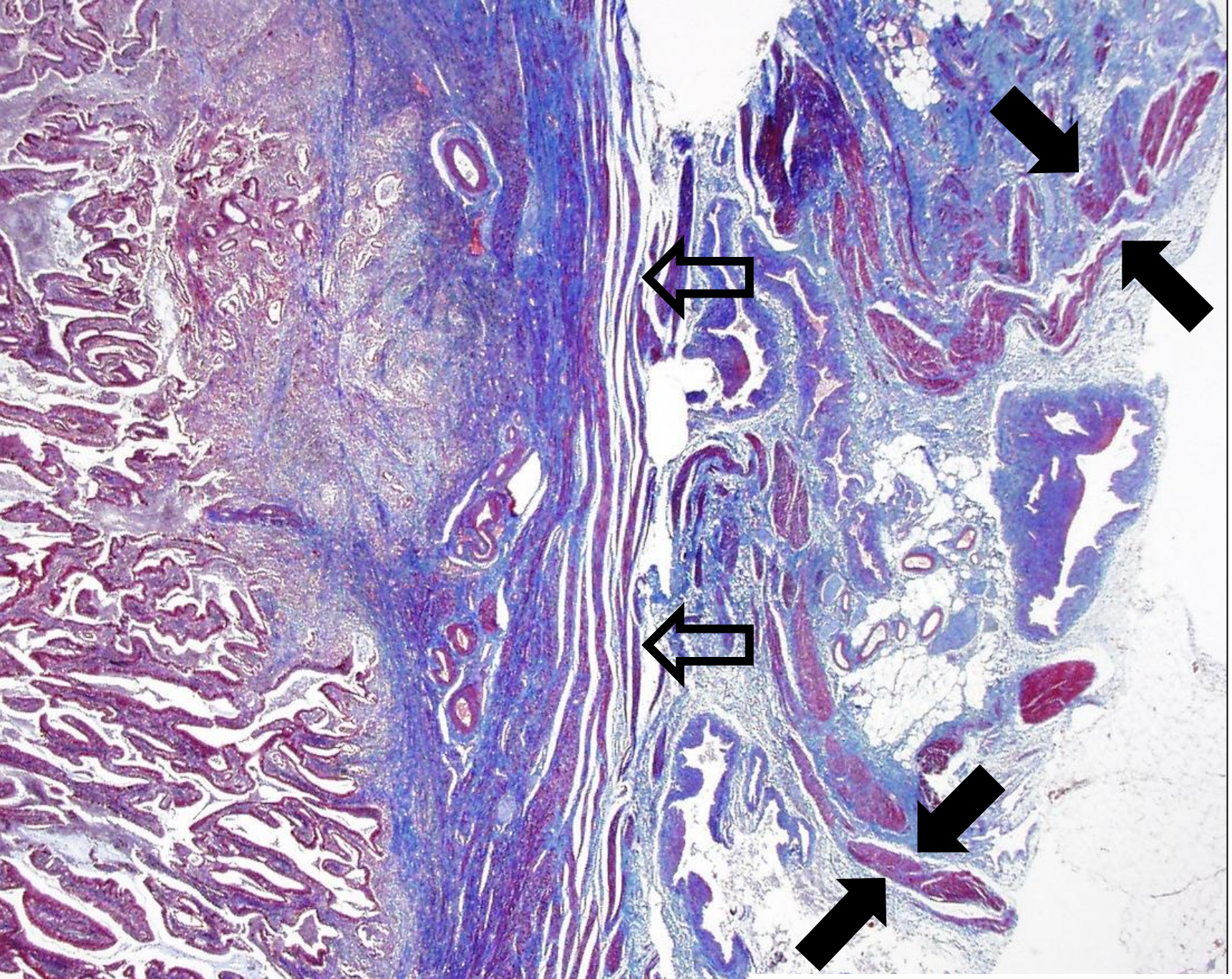


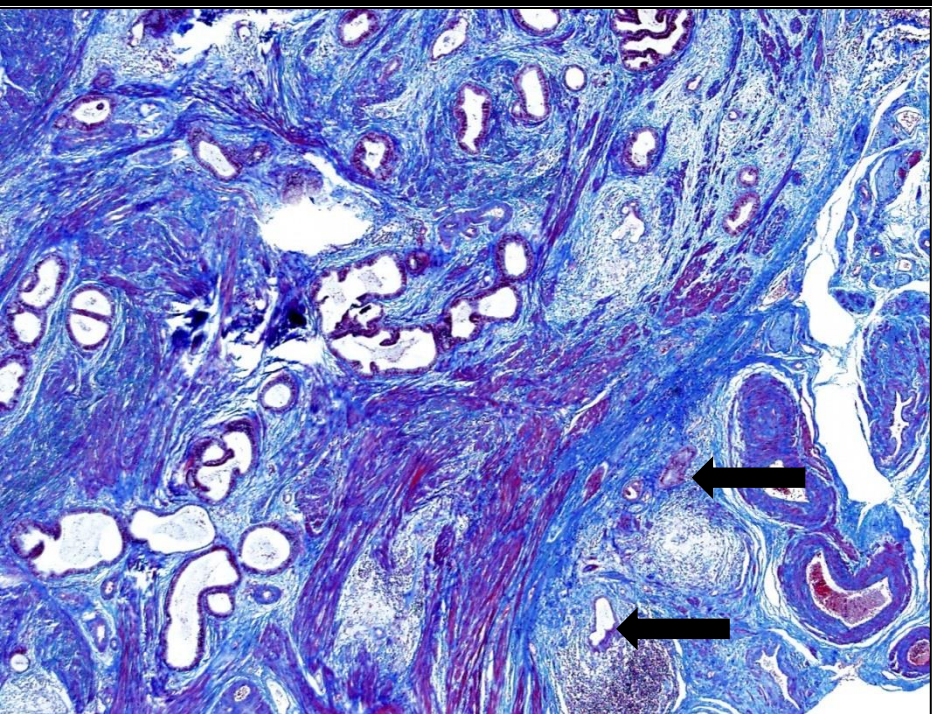
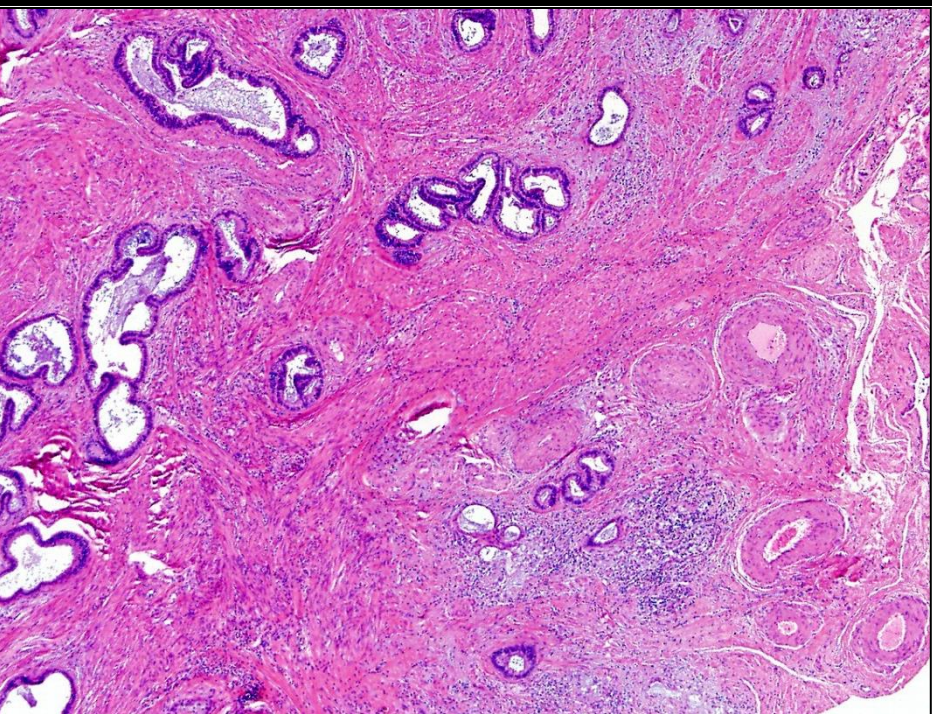
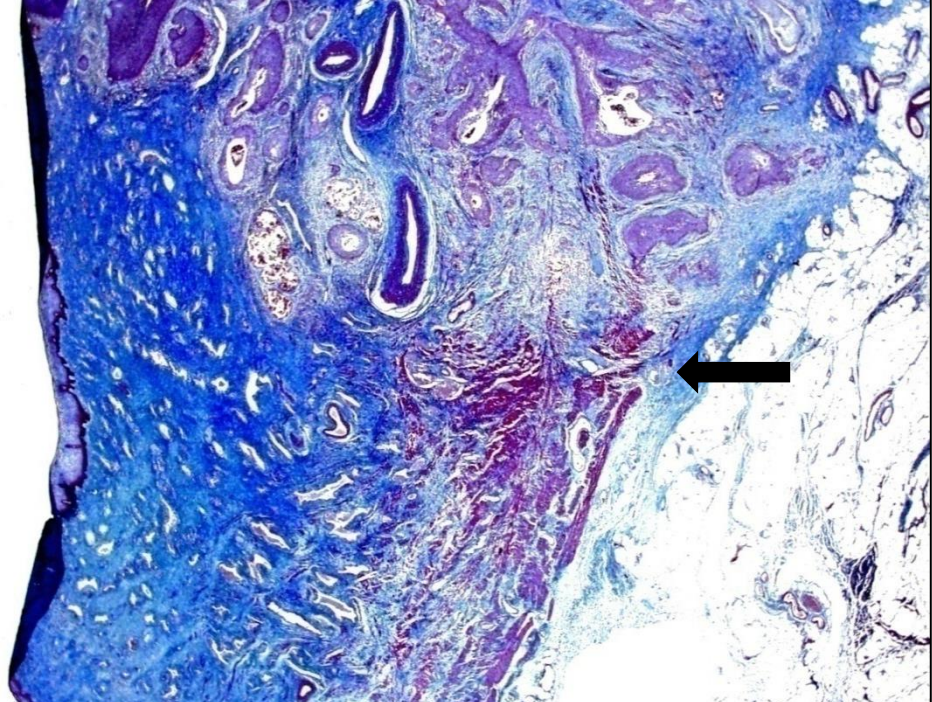
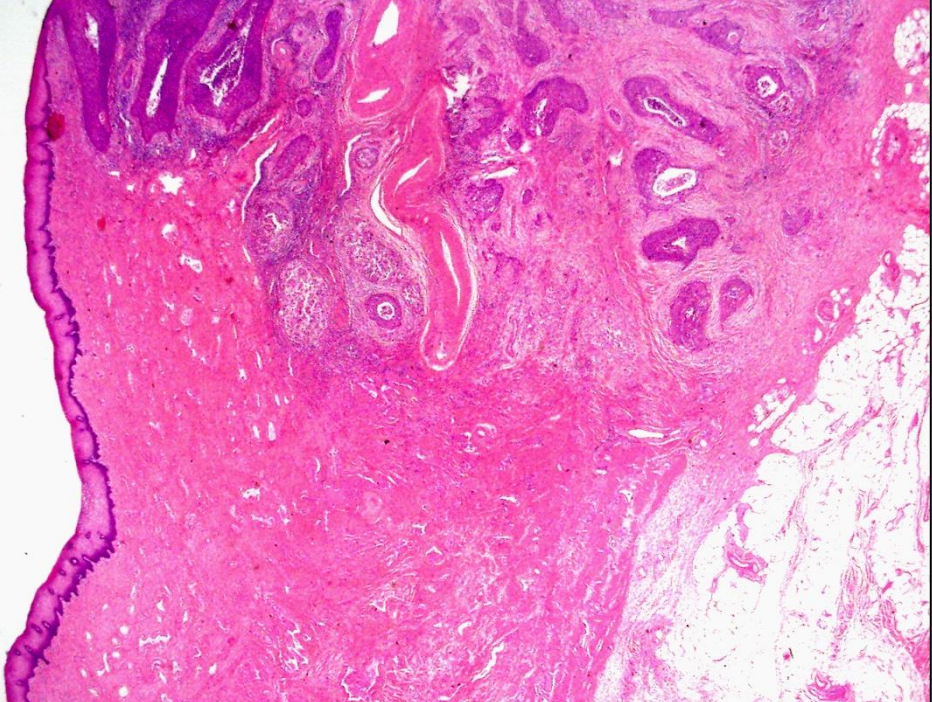


**Endometriosis obscuring cervico-parametrial junction.**







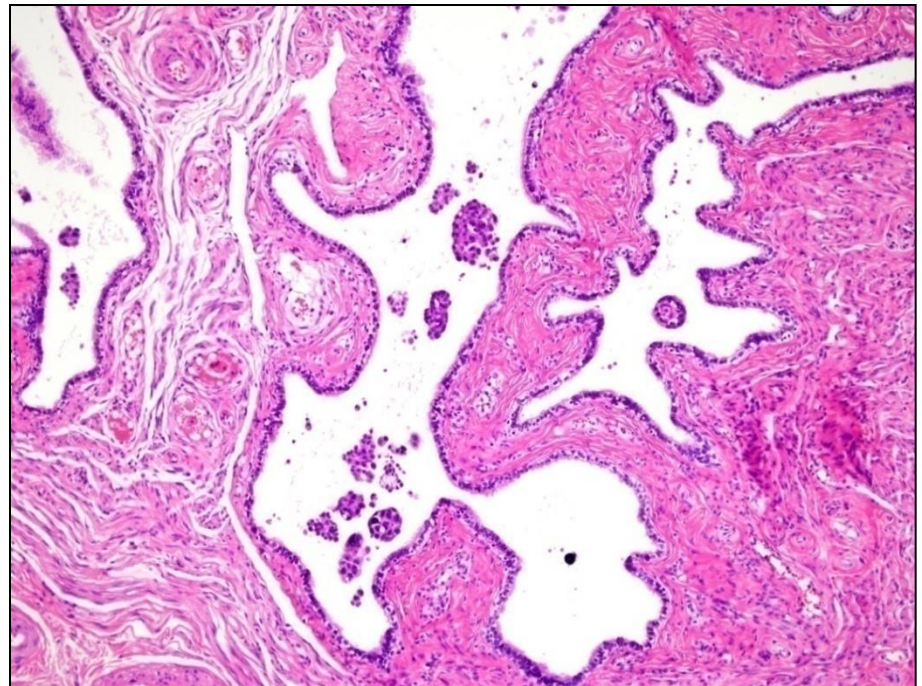
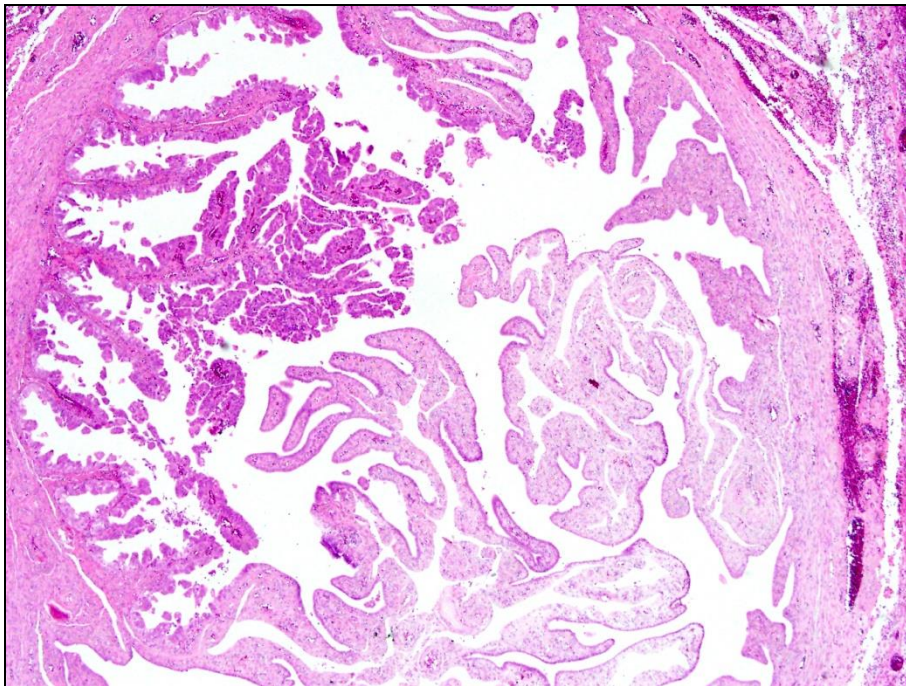
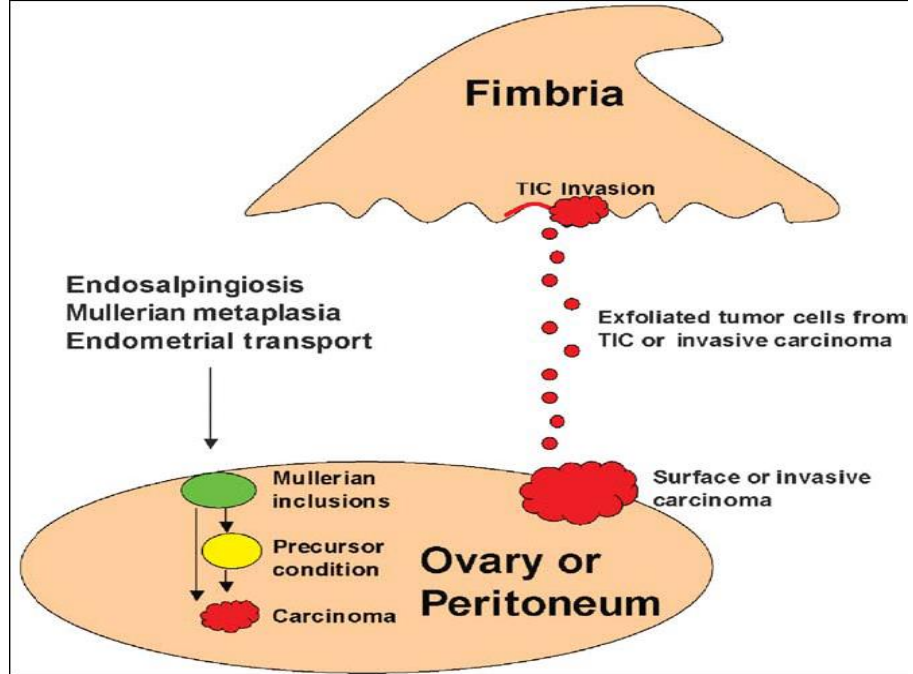


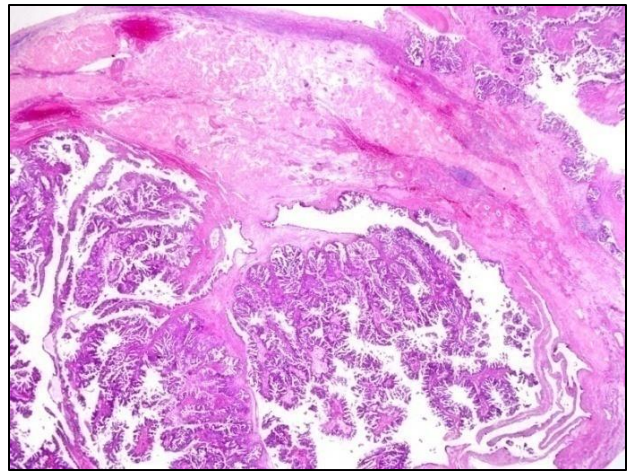
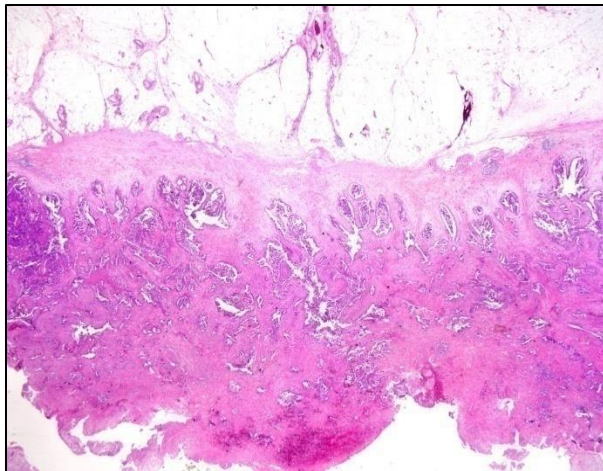
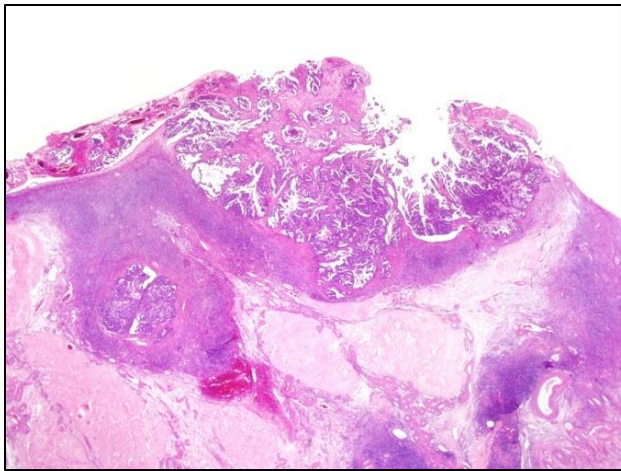
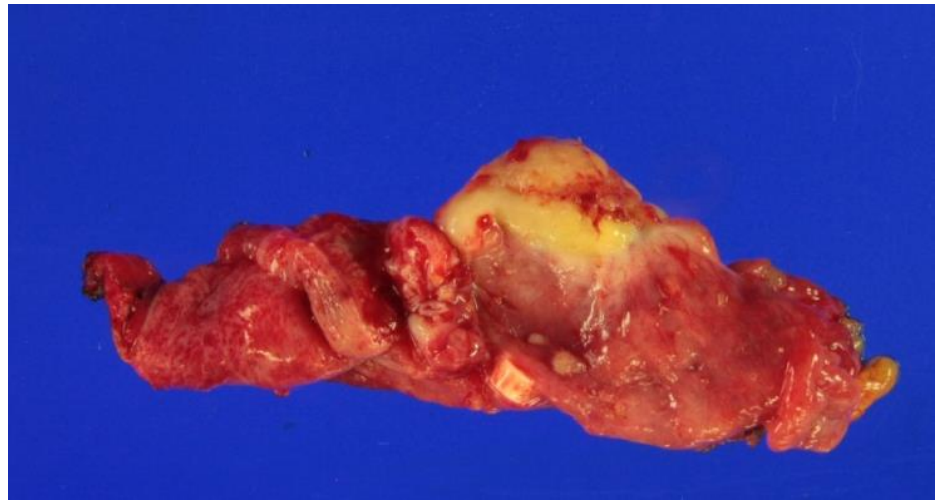
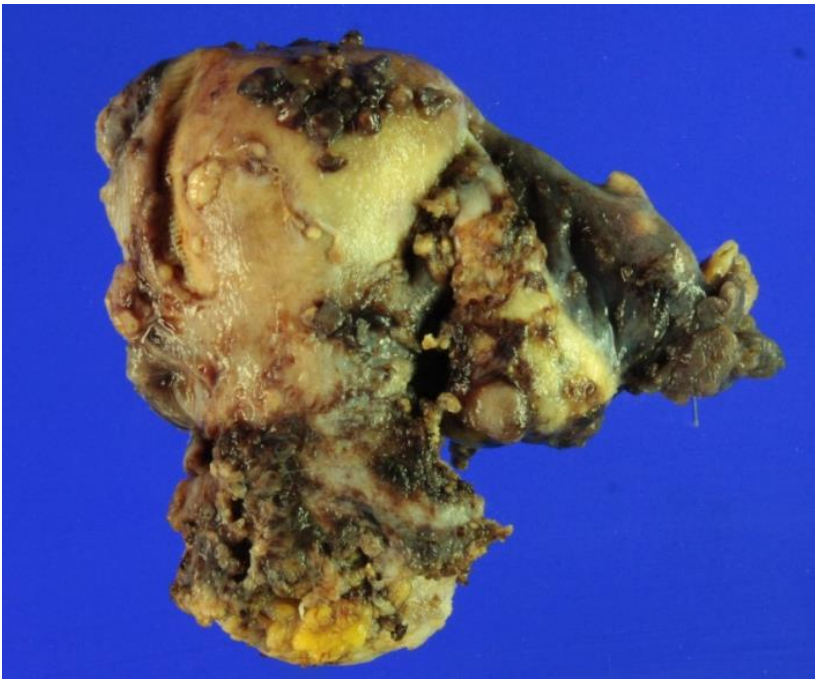
# Lymph node dissection and Sampling

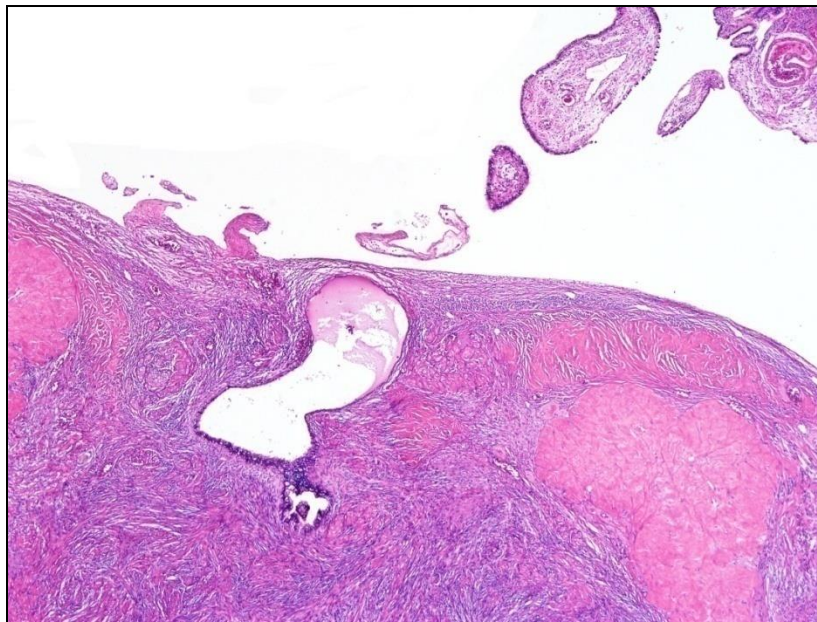
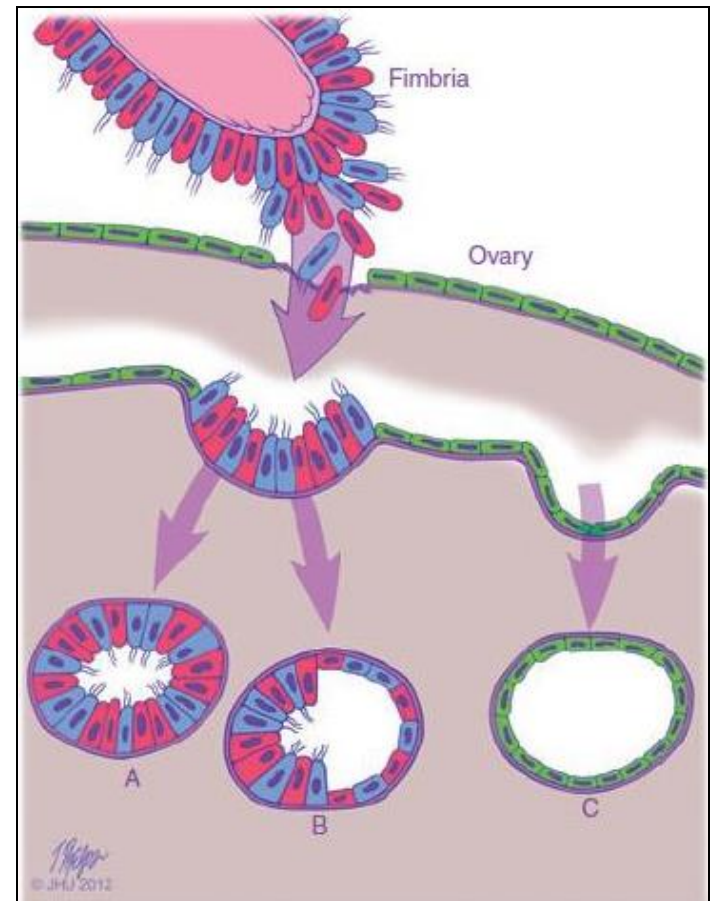
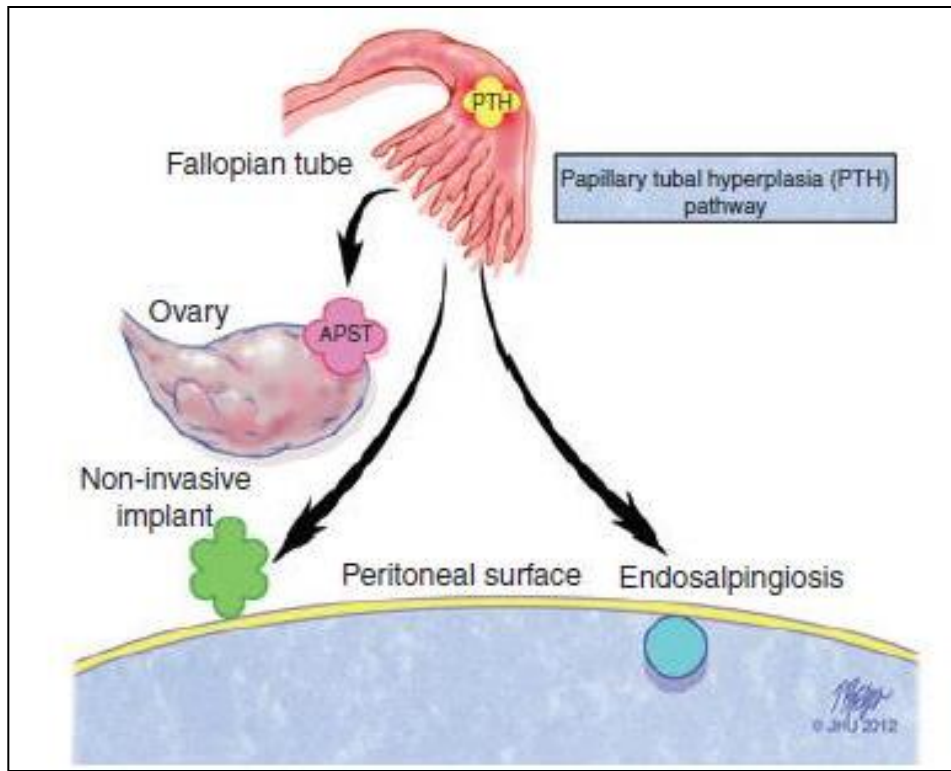
- Dissection : Pelvic LN dissection
- Dissection or sampling : Paraortic LN dissection, or sampling
- Regional LNs for cervical cancer : obturator, internal iliac, hypogastric, external iliac, common iliac para-aortic
- (+) LNs are important for decision of radiation field.

**Carcinomas of the ovary, fallopian tube,  
and pelvic peritoneum are  
surgically/pathologically staged disease !!**

**FIGO/AJCC stage is applied to all types of  
malignant tumors arising in the ovary,  
fallopian tube and primary peritoneum.**









# New FIGO Staging (2013)

- Although a significant number of HGSCs might not arise from the ovary, and the term “ovarian cancer” would not be pathogenically precise in every case, ovarian involvement is the rule in almost all cases. The term ‘HGSC of ovary’ should be kept until the different origins of ovarian tumors are better understood.

# New FIGO Staging (2013)

- The relative proportion of HGSCs of ovarian and tubal derivation is unknown, mainly because tumor growth in advanced stage cancers conceals the primary site.
- It is unlikely that all HGSCs originate in the fallopian tube.

# New FIGO Staging (2013)

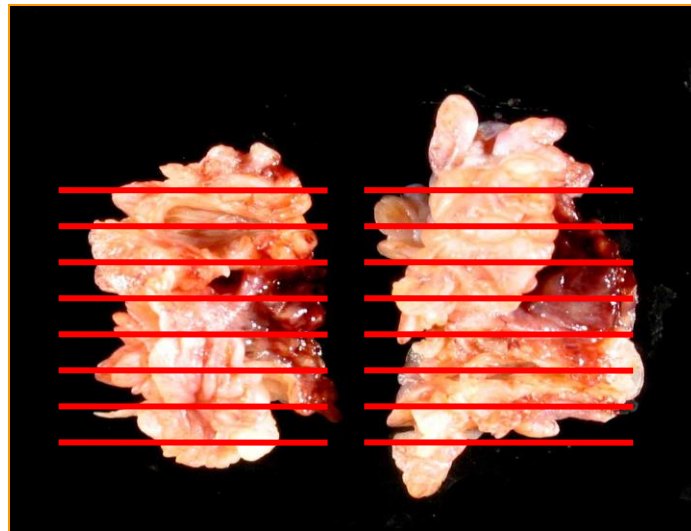
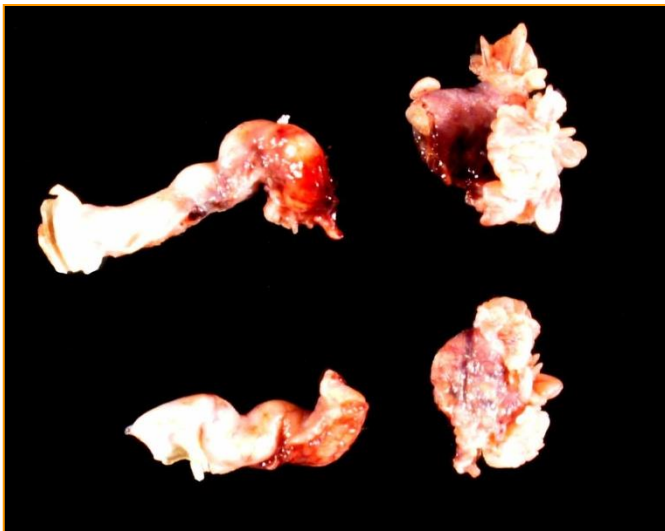
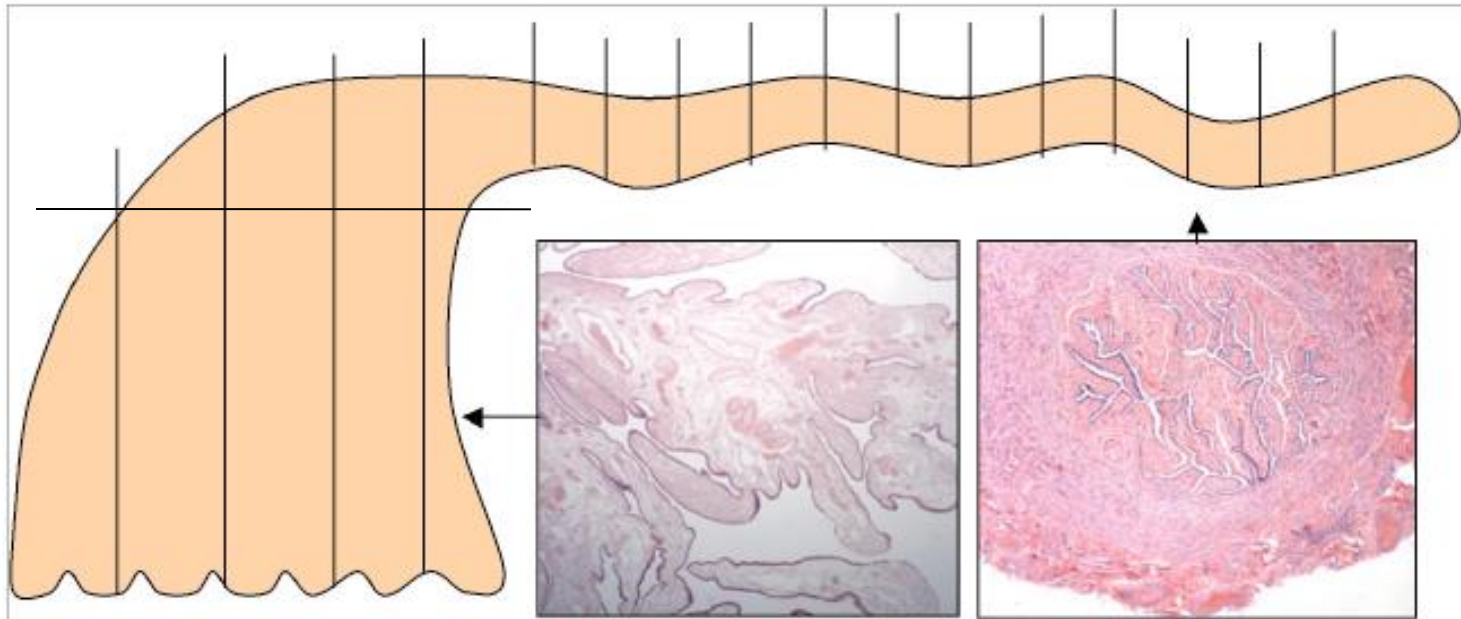
- FIGO staging of ovarian, peritoneal, and fallopian tube cancers should be considered collectively.
- The primary site (i.e. ovary, fallopian tube, or peritoneum) should be designated where possible.
- In some cases, it might not be possible to delineate the primary site clearly; such cases should be listed as “undesigned.”

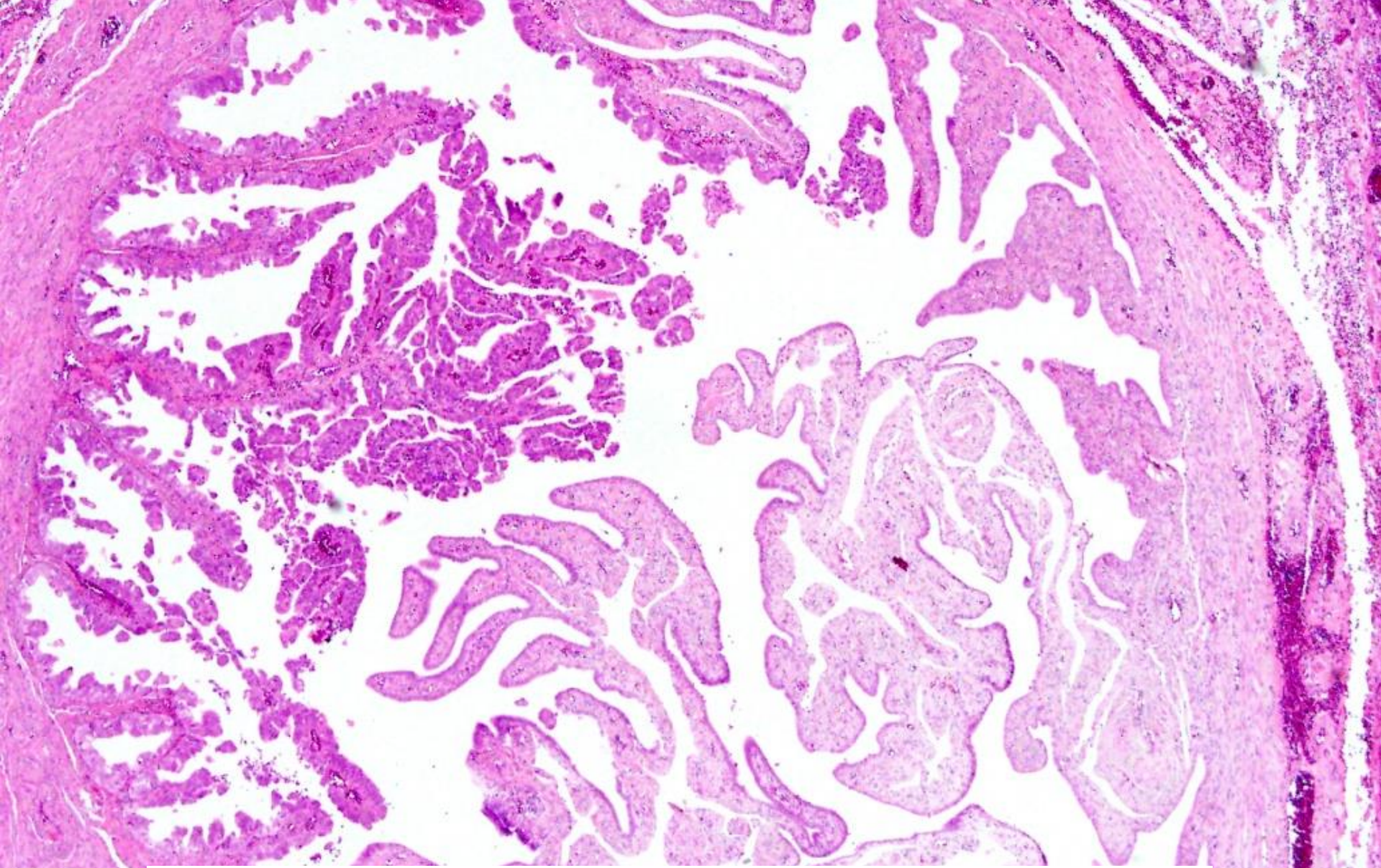
# Assignment of primary site in high-grade serous tubal, ovarian and peritoneal carcinoma: a proposal

- The fallopian tubes, or at least their fimbrial ends, should be totally sampled in all cases of HGSC by a **SEE-FIM-like protocol** to avoid missing this important site of disease, which probably represents the precursor lesion and tumor origin in the majority of cases.

# SEE-FIM Protocol

Sectioning and Extensively Examining the FIMbriated End





**Serous tubal intraepithelial carcinoma**

# Assignment of primary site in HGSC

- The presence of STIC without invasion or extratubal spread should be staged as **FIGO stage IA tubal carcinoma** but with an annotation that there is no invasive carcinoma.
- **Cases with only STIC**, ovarian surface involvement or parenchymal involvement not exceeding 5 mm, and widespread peritoneal involvement, should be classified as **tubal primaries**.

# Assignment of primary site in HGSC

- Cases with invasive HGSC located **within the mucosa of the fallopian tube**, including its fimbrial end, with or without STIC in any portion of the fallopian tube and with no, minimal or even substantial ovarian involvement, should be categorized as **tubal primaries**.



# Assignment of primary site in HGSC

- Cases with **dominant ovarian mass** and identifiable fallopian tubes **with STIC** should be classified as **tubal primaries**.
- Cases with **dominant ovarian mass** and identifiable fallopian tubes **without STIC** should be classified as **ovarian primaries**.

# Assignment of Primary Peritoneal Carcinoma

- **Only after complete examination** of the fallopian tubes (including the non-fimbrial portions).
- **Absence of STIC or a small HGSC** in fallopian tube.
- **Both ovaries must be normal in size** or enlarged by a benign process.
- The involvement in the extra-ovarian sites must be **greater** than the involvement on the surface of either ovary;
- The ovarian tumor involvement must be non-existent, confined to the ovarian surface **without stromal invasion**, or involve the cortical stroma with tumor **size less than 5 x 5mm**.

# Assignment of primary site in HGSC

- All cases classified as ‘undesignedated’ for FIGO staging purposes should be further described as ‘tubo-ovarian’ or ‘tubal/ovarian’ to distinguish them from serous carcinoma originating in the endometrium.

# Assignment of primary site in HGSC

Cases with **unilateral or bilateral HGSC** in the ovary and/or STIC or HGSC in the tube but with an **endometrial serous intra-epithelial or invasive carcinoma** should be evaluated carefully for an endometrial vs. a tubo-ovarian primary (as stated, WT1 staining may be of value); a majority of such cases will represent **adnexal metastases from an endometrial serous carcinoma**.

# FIGO Staging (2013) of ovarian, peritoneal, and fallopian tube cancers

- **Stage I:** Tumor **confined** to ovaries or fallopian tube(s).
- **Stage II:** Tumor involves 1 or both ovaries or fallopian tubes with **pelvic extension** (below pelvic brim) or primary peritoneal cancer.
- **Stage III:** Tumor involves 1 or both ovaries or fallopian tubes, or primary peritoneal cancer, with cytologically or histologically confirmed spread to the peritoneum **outside the pelvis** and/or metastasis to the retroperitoneal lymph nodes.
- **Stage IV:** **Distant** metastasis excluding peritoneal metastases.

Stage II: Tumor involves one or both ovaries or fallopian tubes with pelvic extension (below pelvic brim) or peritoneal cancer (Tp)

## **IIA**

- Extension and/or implants on the uterus and/or fallopian tubes/and/or ovaries

## **IIB**

- Extension to other pelvic intraperitoneal tissues

# Stage 1: Tumor confined to ovaries or fallopian tube(s)

## IA

- Tumor limited to one ovary(capsule intact) or fallopian tube.
- No tumor on ovarian or fallopian tube surface.
- No malignant cells in the ascites or peritoneal washings

## IB

- Tumor limited to both ovaries (capsules intact) or fallopian tubes.
- No tumor on ovarian or fallopian tube surface.
- No malignant cells in the ascites or peritoneal washings.

## IC

- Tumor limited to one or both ovaries or fallopian tubes, with any of the following:

IC1 : Surgical spill intraoperatively.

IC2 : Capsule ruptured before surgery or tumor on ovarian or fallopian tube surface.

IC3 : Malignant cells present in the ascites or peritoneal washings.

Stage III: Tumor involves one or both ovaries, or fallopian tubes, or primary peritoneal cancer, with **cytologically or histologically confirmed spread to the peritoneum outside the pelvis and/or metastasis to the retroperitoneal lymph nodes**



# Stage III: spread to the peritoneum outside the pelvis and/or metastasis to the retroperitoneal lymph nodes

- IIIA Metastasis to the retroperitoneal lymph nodes with or without microscopic peritoneal involvement beyond the pelvis.
  - IIIA1 Positive **retroperitoneal lymph nodes** only (cytologically or histologically proven)
    - IIIA1(i) Metastasis  $\leq 10$  mm in greatest dimension
    - IIIA1(ii) Metastasis  $> 10$  mm in greatest dimension
  - IIIA2 Microscopic **extrapelvic (above the pelvic brim) peritoneal** involvement with or without positive retroperitoneal lymph nodes.
- IIIB Macroscopic peritoneal metastases **beyond the pelvic brim  $\leq 2$  cm in greatest dimension**, with or without metastasis to the retroperitoneal lymph nodes.
- IIIC Macroscopic peritoneal metastases **beyond the pelvic brim  $> 2$  cm in greatest dimension**, with or without metastases to the retroperitoneal nodes.

# Stage IV: Distant metastasis excluding peritoneal metastases

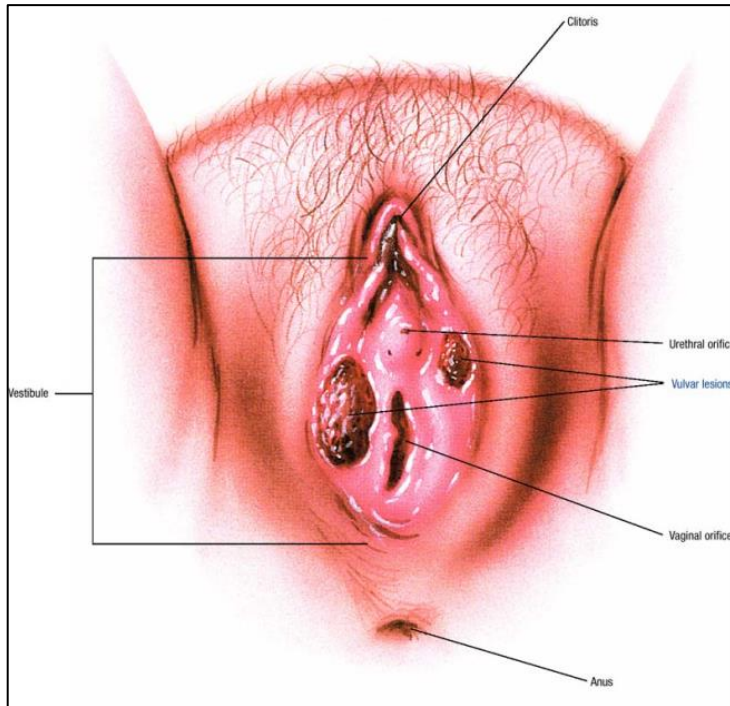
- IVA: Pleural effusion with positive cytology
- IVB: Metastases to extra-abdominal organs (including inguinal lymph nodes and lymph nodes outside of abdominal cavity).

**Parenchymal metastases** to liver or spleen.

# New FIGO Staging (2013)

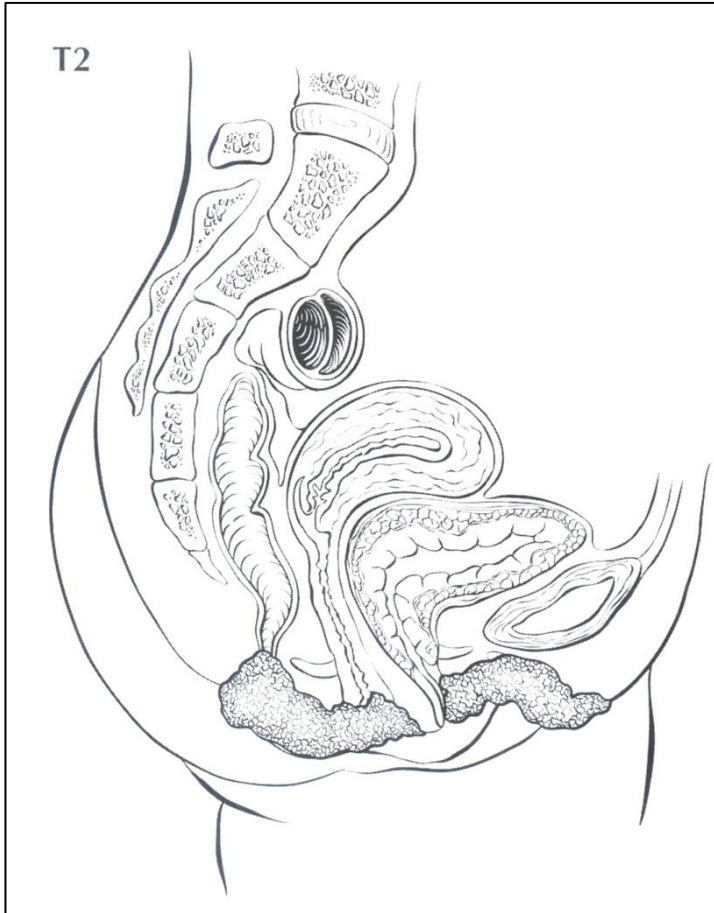
- Presented and approved by the American Joint Commission on Cancer (AJCC) and the International Union Against Cancer (UICC), in May 2013.
- Definitions of the T categories of AJCC 8<sup>th</sup> correspond to the FIGO stage.

# Carcinoma of the Vulva (Labia, Clitoris, Perineum)



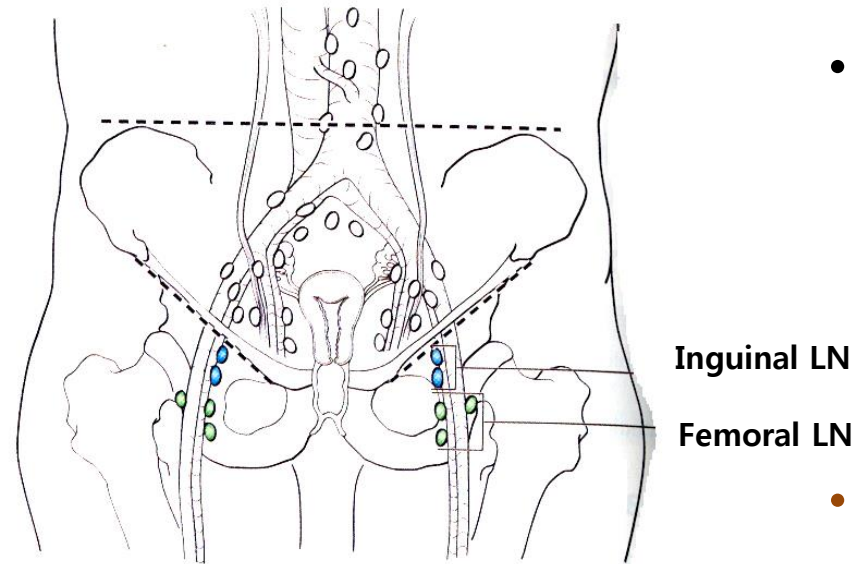
- **Stage I Tumor confined to the vulva.**
- **Stage II** Tumor of any size with extension to adjacent perineal structures with negative nodes.
- **Stage III** Tumor of any size with or without extension to adjacent perineal structures.
- **Stage IV** Tumor invades other regional (2/3 upper urethra, 2/3 upper vagina), or distant structures.

# Carcinoma of the Vulva (Labia, Clitoris, Perineum)



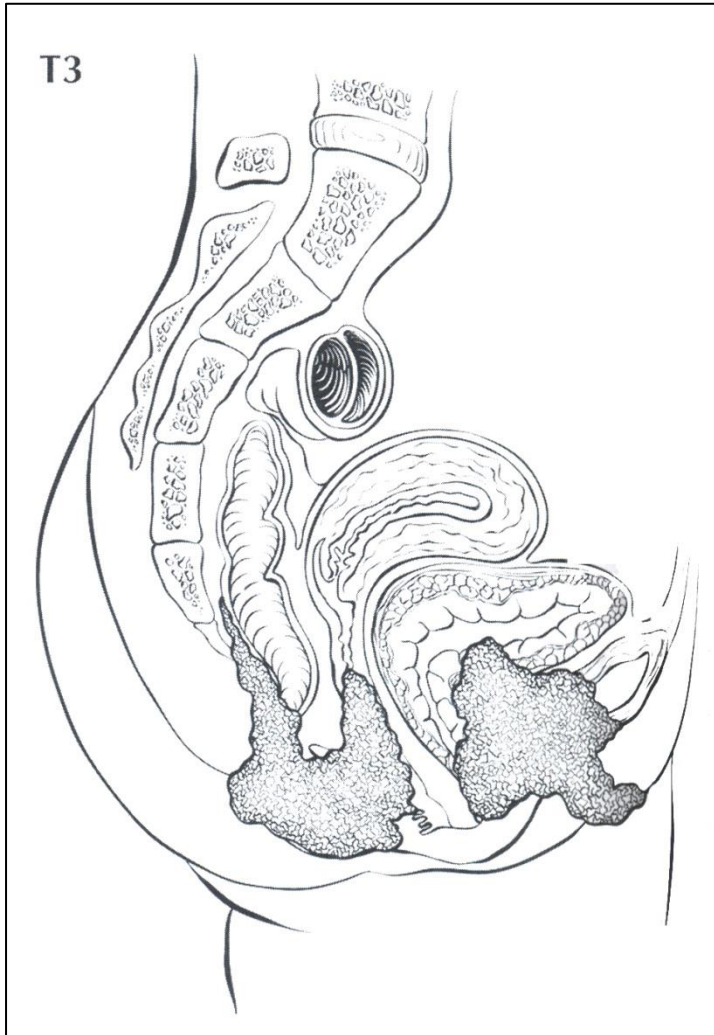
- Stage I. Tumor confined to the vulva.
- **Stage II. Tumor of any size with extension to adjacent perineal structures (lower/distal 1/3 of urethra, lower/distal 1/3 vagina, or anus) with negative nodes.**
- Stage III. stage II + (+) inguino-femoral LNs.
- Stage IV. Tumor invades other regional (2/3 upper urethra, 2/3 upper vagina), or distant structures.

# Carcinoma of the Vulva (Labia, Clitoris, Perineum)



- Stage I. Tumor confined to the vulva.
- Stage II. Tumor of any size with extension to adjacent perineal structures (lower/distal 1/3 of urethra, lower/distal 1/3 vagina, anus) with negative nodes.
- **Stage III. stage II with (+) inguino-femoral LNs.**
- Stage IV. Tumor invades other regional (2/3 upper urethra, 2/3 upper vagina), or distant structures.

# Carcinoma of the Vulva (Labia, Clitoris, Perineum)



- Stage I. Tumor confined to the vulva.
- Stage II. Tumor of any size with extension to adjacent perineal structures (lower/distal 1/3 of urethra, lower/distal 1/3 vagina, anus) with negative nodes.
- Stage III. stage II + (+) inguino-femoral LNs.
- **Stage IV. Tumor of any size with extension to adjacent structures (2/3 upper urethra, 2/3 upper vagina), bladder mucosa, rectal mucosa, or fixed to pelvic bone) or distant metastasis.**

# FIGO staging of the Vulvar Carcinoma (2009)

## I: Tumor confined to the vulva

1A: Lesions  $\leq 2$ cm in **size**, confined to the vulva or perineum and with stromal invasion  $\leq 1.0$ mm, no nodal metastases

1B: Lesions  $> 2$ cm in size or with **stromal invasion  $> 1.0$ mm**, confined to the vulva or perineum, with negative node

## II: Tumor of any size with adjacent perineal spread (lower/distal 1/3 urethra, lower/distal 1/3 vagina, anus), negative LNs.

## III: Tumor of any size with (+) inguino-femoral LNs.

IIIA: (i) **1 LN metastases ( $\geq 5$ mm)** , or

(ii) 1-2 LN metastases ( $< 5$ mm)

IIIB: (i) with 2 or more LN metastases ( $\geq 5$ mm), or

(ii) 3 or more LN metastases ( $< 5$ mm)

## IIIC: With positive nodes with **extracapsular spread**

## IV: Tumor invades other regional (2/3 upper urethra, 2/3 upper vagina), or distant structures

### IVA: Tumor invades any of the following:

(i) upper urethral and/or vaginal mucosa, bladder mucosa, rectal mucosa, or fixed to pelvic bone, or

(ii) fixed or ulcerated inguino-femoral lymph nodes

### IVB: Any distant metastasis including pelvic lymph nodes



# Parameters required for the Staging of Vulva Cancer

- Size of tumor ( $\leq 2\text{cm}$ ,  $> 2\text{cm}$ ).
- Depth of stromal invasion ( $1\text{ mm} >$ ,  $\leq 1\text{mm}$ ).
- Number of positive LNs.
- Metastatic tumor size in the LNs.
- Extracapsular extension.
- Extent of invasion in adjacent structures; urethra, vagina, bladder, rectum, and anus.

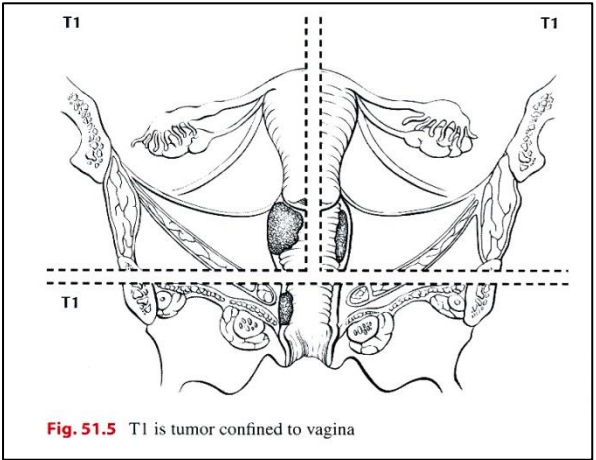
# Vulvar cancers

- All vulvar carcinomas are staged using FIGO or AJCC.
- Vulvar melanoma is considered in a separate staging system as though it were a cutaneous melanoma.
- Stage should be assigned at the time of definitive surgery (**Surgically staged disease**).
- If CTx, RTx, or a combination of both modalities is the initial mode of therapy, **clinical staging** should be used.
- The femoral and inguinal nodes are the **regional LNs**, whereas **pelvic LNs involvement** (internal iliac, external iliac, and common iliac LNs) is considered **distant** metastasis.

# FIGO staging of the Vaginal Carcinoma (2009)

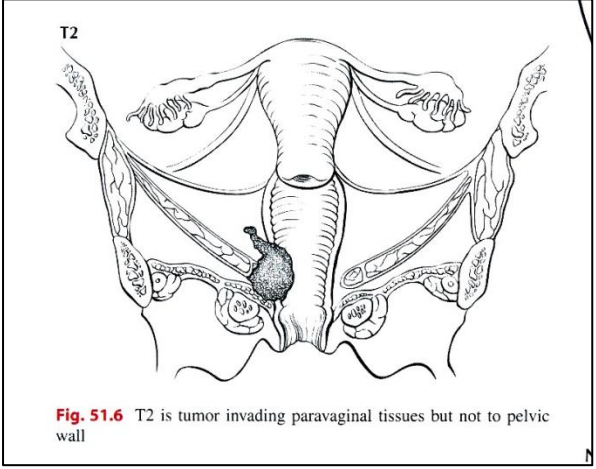
- I:** Tumor confined to the vagina
- II:** Tumor invading paravaginal tissue, but not to pelvic wall, measuring  $>2.0\text{cm}$ .
- III:** Tumor extending to the pelvic side wall and/or involving the lower third of the vagina and/or causing hydronephrosis or nonfunctioning kidney
- IV:** Tumor invading the mucosa of the bladder or rectum and/or extending beyond the true pelvis or distant metastasis

**FIGO Stage I**



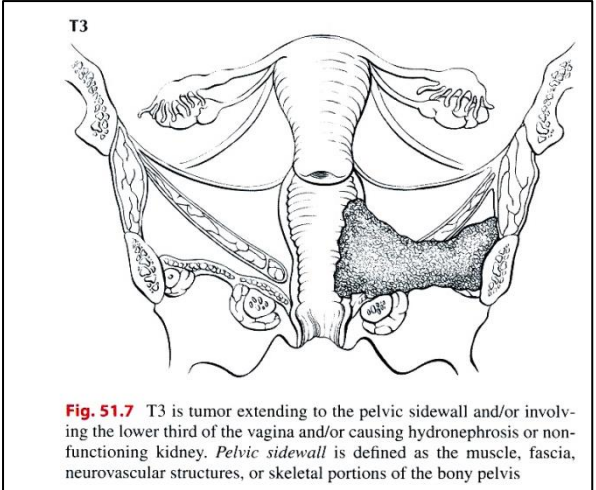
**Fig. 51.5** T1 is tumor confined to vagina

**FIGO Stage II**



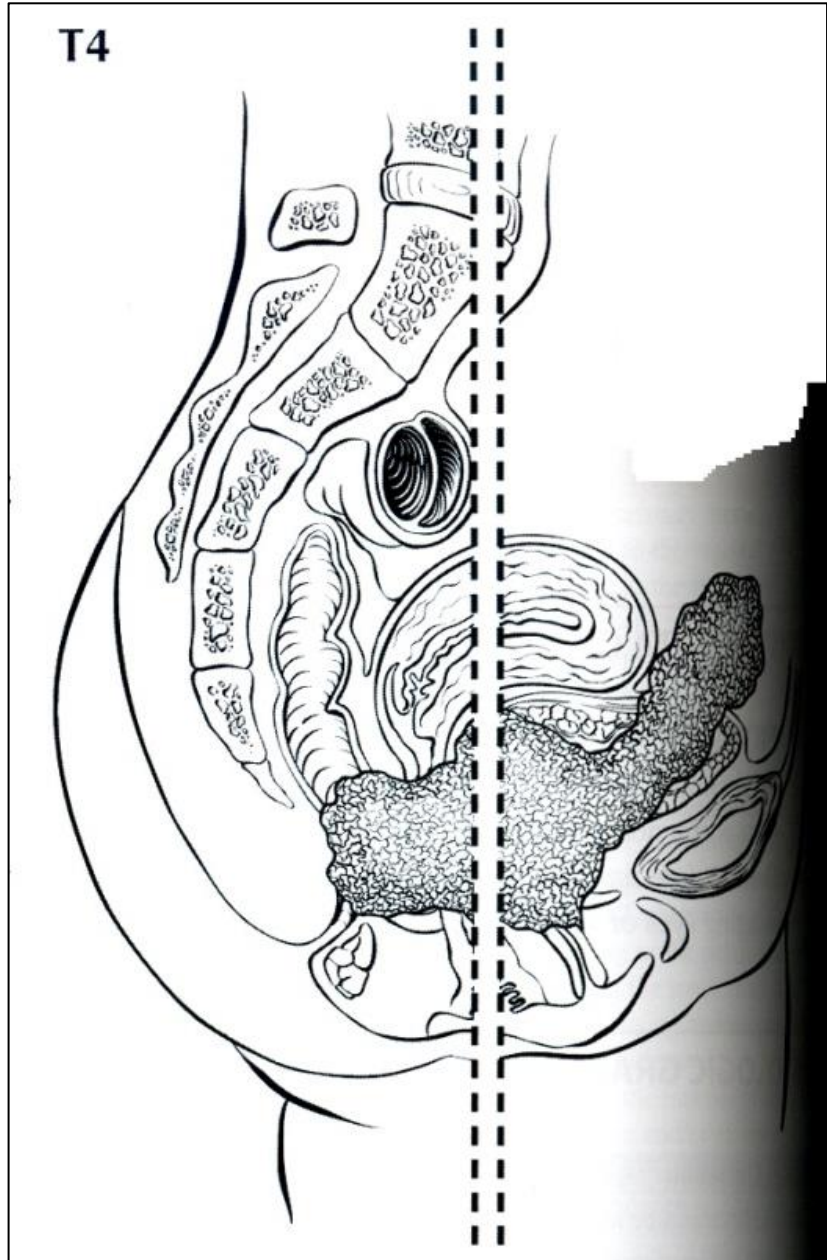
**Fig. 51.6** T2 is tumor invading paravaginal tissues but not to pelvic wall

**FIGO Stage III**



**Fig. 51.7** T3 is tumor extending to the pelvic sidewall and/or involving the lower third of the vagina and/or causing hydronephrosis or non-functioning kidney. *Pelvic sidewall* is defined as the muscle, fascia, neurovascular structures, or skeletal portions of the bony pelvis

**T4**



**Fig. 51.8** T4 is tumor invading the mucosa of the bladder or rectum and/or extending beyond the true pelvis (bullous edema is not sufficient evidence to classify a tumor as T4)

# **Vaginal carcinoma**

## Summary of Changes in AJCC 8<sup>th</sup>

- T1 and T2 subcategories were added with a size cutoff of 2.0 cm.

# 4. Gestational Trophoblastic Disease

- **Pure anatomical staging:**

- ✓ Not universally accepted.
- ✓ Prognosis of patients in the same anatomical stage varies greatly.
- ✓ Prognosis affected by many clinical features.

- **WHO risk factor scoring system (8 items);**

age, antecedent pregnancy, interval from index pregnancy, pretreatment hCG titer, largest tumor size, site of metastases, number of mets, previous failed chemotherapy

## 5. FIGO (2002) Anatomical Staging System for GTN

- I: Disease confined to the uterus.
- II: GTN extends outside of the uterus, but is limited to the genital structures (adnexa, vagina, broad ligament)
- III: GTN extends to the lungs, with or without known genital tract involvement.
- IV: All other metastatic sites.

# FIGO (2002) Clinical Risk Factor Score

Scores	0	1	2	4
Age	<40	≥40	-	-
Antecedent pregnancy	Mole	Abortion	Term	-
Interval months from index pregnancy	<4	4-<7	7 ~ <13	≥13
Pre-treatment serum hCG (IU/ ml)	<10 <sup>3</sup>	10 <sup>3</sup> ~ <10 <sup>4</sup>	10 <sup>4</sup> ~ <10 <sup>5</sup>	≥10 <sup>5</sup>
Largest tumor size (including uterus)	-	3 ~ <5cm	≥5cm	-
Site of metastases	Lung	Spleen, kidney	Gastro-intestinal	Liver Brain
Number of metastases	-	1 ~ 4	5 ~ 8	>8
Previous failed chemotherapy	-	-	Single Drug	2 or more drugs



# Revised FIGO/WHO classification system for GTN (2002)

- Combined anatomical stage and risk factor score
- **i.e. Stage II: 4, stage IV: 9**
- Stage I~III, Risk score  $<6$  : single agent CTx (non-metastatic or low risk metastatic disease) (Low risk) : single agent CTx.
- Stage IV, score  $\geq 7$  (High risk) : multiple combination CTX.

A close-up photograph of a hand holding a green pencil over a light blue card. The card has the words "Thank You" written in a black cursive font. The card is placed on a brown paper envelope. The background is a grey surface.

Thank You