

Follicular Lymphoma Diagnostic Caveats and Updates

Sarah M. Choi, MD, PhD; Bryan L. Betz, PhD; Anamarija M. Perry, MD

• **Context.**—Follicular lymphoma is a common small B-cell lymphoma, likely to be encountered by any practicing pathologist, regardless of specialty. Although the features of typical follicular lymphoma are well known and in most instances easily identifiable, there are lesser-appreciated morphologic appearances that can raise alternative diagnostic possibilities. The limited tissue available in core needle biopsies can make it additionally challenging to thoroughly evaluate those features in the context of architecture. Furthermore, ancillary testing including immunohistochemistry and molecular/genetic analysis do not always show classic findings and may pose additional challenges to interpretation.

Objectives.—To review the morphologic features of follicular lymphoma with a discussion of morphologic variants and mimics; to discuss pitfalls of ancillary testing and provide the practicing pathologist with an appropriate

context for interpretation of immunohistochemical and molecular/genetic studies when follicular lymphoma is part of the differential diagnosis; and to propose diagnostic strategies when there is limited tissue for evaluation.

Data Sources.—We used examples of follicular lymphoma from our institution as well as a review of the literature, with a focus on the diagnostic aspects that are broadly relevant to a general pathology practice.

Conclusions.—Follicular lymphoma can occasionally present with atypical morphologic, immunohistochemical, or molecular/genetic features. In particular, those findings can be difficult to interpret in the setting of a limited tissue sample. Awareness of those possibilities will help guide the pathologist to a more accurate and precise diagnosis.

(*Arch Pathol Lab Med.* 2018;142:1330–1340; doi: 10.5858/arpa.2018-0217-RA)

Follicular lymphoma represents 20% to 30% of all non-Hodgkin lymphomas in Western countries and is the most common small B-cell lymphoma in the United States. It usually presents in a patient's fifth to sixth decade with similar incidence in men and women.¹

The morphology of follicular lymphoma is classically described as an effacement of normal lymph node architecture by back-to-back neoplastic follicles that show attenuated mantle zones, loss of polarization, and absence of tingible body macrophages that are usually present in nonneoplastic follicles (Figure 1, A through C). The neoplastic cells comprise a mixture of centrocytes, which are small and have cleaved or angular nuclear contours, and centroblasts, which are large cells with ovoid nuclei and multiple peripheral nucleoli. Cytologic evaluation enables grading of follicular lymphoma based on the number of centroblasts per high-power field (HPF). Grade 3 follicular lymphoma is defined by the presence of more than 15 centroblasts per HPF (within areas with follicular architecture). Further designation depends on whether centrocytes

are present (grade 3A) or not (grade 3B). Although a standard HPF is defined as 0.159 mm², the centroblast count per HPF can vary from microscope to microscope.² Instructions for determining the appropriate number of centroblasts per HPF for a grade 3 follicular lymphoma diagnosis are depicted in Figure 2.

Immunophenotypically, follicular lymphoma typically demonstrates coexpression of CD10, BCL6, and BCL2 within the follicles (Figure 3, A through L). Follicular lymphomas also have characteristic t(14;18)/IGH-BCL2 and/or BCL6 rearrangements, which can most optimally be detected by fluorescence in situ hybridization (FISH).^{3–5}

Although the pattern of involvement is classically follicular, a diffuse pattern can also be seen, which is defined as an area devoid of follicles without any follicular dendritic meshwork highlighted by CD21 or CD23.² The presence of grade 3 cytology with a diffuse pattern constitutes a diagnosis of diffuse large B-cell lymphoma.

Outside of lymph nodes, involvement of spleen, bone marrow (70%–80% of cases),⁶ peripheral blood, and other extranodal sites (gastrointestinal tract, liver, testicle) can also be seen. Transformation occurs in 25% to 35% of patients, most frequently to diffuse large B-cell lymphoma.²

MORPHOLOGIC VARIANTS OF FOLLICULAR LYMPHOMA

A number of morphologic variants of follicular lymphoma have been described and are listed in Table 1. The most frequently encountered variant is follicular lymphoma with marginal zone differentiation, seen in approximately 10% of cases (Figure 4, A through F).⁷ Plasmacytic differentiation has also been reported⁸ and can even

Accepted for publication May 9, 2018.

Published online September 17, 2018.

From the Department of Pathology, University of Michigan, Ann Arbor.

The authors have no relevant financial interest in the products or companies described in this article.

Presented in part at the New Frontiers in Pathology meeting; October 19–21, 2017; Ann Arbor, Michigan.

Corresponding author: Sarah M. Choi, MD, PhD, Department of Pathology, University of Michigan, 5242A Medical Science Bldg 1, 1301 Catherine St, Ann Arbor, MI 48109 (email: choism@med.umich.edu).

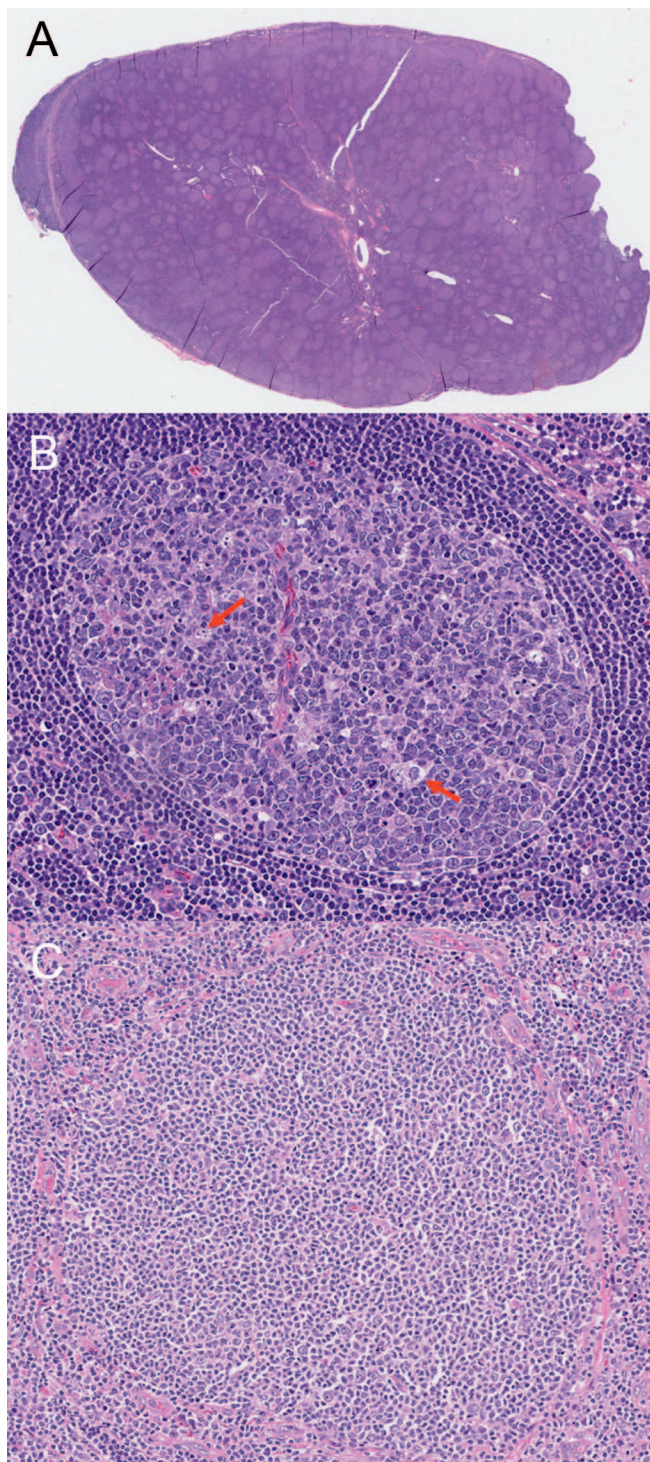


Figure 1. Morphologic features of follicular lymphoma. *A*, Classical example of follicular lymphoma. Numerous back-to-back neoplastic follicles. *B*, Reactive follicle comprising a polarized germinal center containing light and dark zones, a well-defined mantle zone, and tingible body macrophages (red arrows). *C*, Neoplastic follicle exhibiting lack of polarization with haphazard distribution of centrocytes and centroblasts, loss of well-defined mantle zone, and absence of tingible body macrophages (hematoxylin-eosin, original magnifications $\times 1$ [A] and $\times 200$ [B and C]).

demonstrate features such as nuclear pseudoinclusions (Dutcher bodies) and accompanying paraprotein.^{9,10} Both of these variants create the potential for misclassification as a marginal zone lymphoma or another B-cell lymphoma with plasmacytic differentiation. Positivity for germinal center markers, CD10 and BCL6, is helpful, but both are occasionally negative or difficult to interpret. Other germinal center markers such as HGAL, GCET2, and LMO2, could aid in identifying residual reactive versus neoplastic follicles,^{11–13} although those markers are less widely available. In some instances, distinction from marginal zone lymphoma may not be possible on morphologic and immunophenotypic grounds, in which case additional FISH analysis looking for characteristic gene rearrangements can be performed.

Other less commonly seen variants include floral variant,^{14,15} which describes the appearance of the follicles (flower-shaped) rather than the cytologic features of the cells, and follicular lymphoma with Hodgkin and Reed-Sternberg-like cells, which can suggest a differential diagnosis of Hodgkin lymphoma.¹⁶ Variants containing numerous epithelioid cells and signet-ring cells have also been described and can mimic metastatic carcinoma.¹⁷

IMMUNOPHENOTYPIC PITFALLS

The classic immunophenotype of follicular lymphoma, as described above, shows abnormal follicles composed of B cells with coexpression of CD10, BCL6, and BCL2. However, several pitfalls can lead to misdiagnosis and are worth discussing.

Interpretation of BCL2 Immunohistochemical Stain

Although BCL2 coexpression in germinal center B cells that express CD10 and BCL6 is abnormal, B cells in primary follicles normally express BCL2 (Figure 5, A through D). Therefore, CD20 and BCL2 coexpression within a follicle should not be interpreted as neoplastic and establishing germinal center marker derivation is essential to a diagnosis of follicular lymphoma. The frequency of BCL2 expression varies depending on the grade of follicular lymphoma. Although low grade (grade 1–2) follicular lymphomas stain positively for BCL2 in 85% to 90% of cases, grade 3 follicular lymphomas stain positive in only 50% to 70% of cases overall (Table 2).^{18–20} The BCL2 antibodies can also show variable positivity from case to case because of mutations in the *BCL2* gene and subsequent alteration of epitopes.^{21–23} BCL2 negativity should not be used to exclude a diagnosis of follicular lymphoma if the other features are present.

CD10 Expression by Immunohistochemistry and Flow Cytometry

Similar to BCL2, CD10 expression by immunohistochemistry can also be scant or absent, which is more frequently observed in the setting of grade 3 disease (Table 2).^{18,20,24–26} Furthermore, even grade 1 and 2 cases with strong CD10 expression in the follicles often show diminished to absent staining in the interfollicular areas.^{24,27} This can be especially problematic in a core needle biopsy, in which interfollicular involvement can be quite extensive and can be the primary area sampled.

Detection of CD10⁺ monotypic B cells by flow cytometry, combined with morphologic features that exclude other germinal center-derived B-cell lymphomas (ie, diffuse large

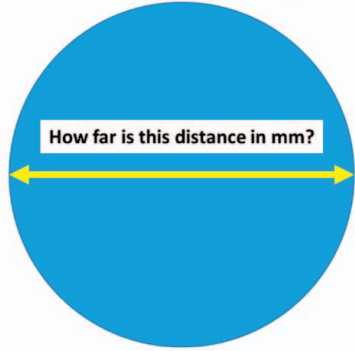
Figure 2. Determination of appropriate field of view (FOV) for grading follicular lymphoma. Abbreviation: HPF, high-power field.

Defining a high power field (HPF)

METHOD 1:


The instructions below apply to microscopes with a 10x ocular:

Examine a transparent ruler or micrometer under a 10x objective.



METHOD 2:

Look on your ocular.



Some oculars indicate the field of view (FOV) number [22 in above picture]. Use the FOV in chart below.

10x Measured Distance:	Field of view (FOV) number	Number of centroblasts/HPF for grade 3 (10 HPF counted)
1.8 mm	18	>15/HPF
2.0 mm	20	>18/HPF
2.2 mm	22	>22.5/HPF

B-cell lymphoma and Burkitt lymphoma), can provide compelling evidence for a diagnosis of follicular lymphoma. Moreover, such features also argue against other small B-cell lymphomas, which only rarely express CD10.²⁸ However, clonal CD10⁺ B-cell populations can occasionally be detected in nonneoplastic and reactive settings, such as florid follicular hyperplasia.^{29,30} Furthermore, the 2017 World Health Organization (WHO) classification,² as discussed later, contains a new provisional entity—*in situ follicular neoplasia*—which phenotypically would be indistinguishable from follicular lymphoma. Thus, it is essential to use morphologic correlation to properly interpret the presence of a clonal population found by flow cytometry.

CYTOGENETIC AND MOLECULAR PITFALLS

The characteristic t(14;18)(q32;q21) translocation, which places *BCL2* expression under the control of the immunoglobulin (Ig) heavy locus (*IGH@*) enhancer, is seen in most cases of follicular lymphoma (Figure 6, A). However, the frequency of this translocation can vary greatly depending on the grade of the disease (Table 2). Although t(14;18) can be detected in up to 90% of grades 1 and 2 follicular lymphomas, it is detected in only 60% to 70% of grade 3A and 15% to 30% of grade 3B follicular lymphoma cases (Table 2).^{25,31} Variant *BCL2* translocations t(2;18) and t(18;22) have also been described. Follicular lymphomas

can also have *BCL6* rearrangements (Figure 6, B and C), which has a frequency that shows an inverse pattern to *BCL2* rearrangements and are more frequently seen in grade 3A and 3B cases.^{18,25,26,32,33} Consequently, the absence of a *BCL2* rearrangement in a suspected low-grade follicular lymphoma is unusual and would warrant further consideration of the diagnosis. In contrast, the absence of such a rearrangement in grade 3 cases should not be interpreted as evidence against a diagnosis of follicular lymphoma. If the diagnosis is in doubt, FISH studies for *BCL6* rearrangements can be performed. Examples of FISH analysis for *IGH-BCL2* (dual-fusion assay) and *BCL6* (a break-apart assay) rearrangements are depicted in Figure 6, A and B.

The new WHO classification recognizes a new entity—*high-grade B-cell lymphoma with MYC and BCL2 and/or BCL6 rearrangements*—the so-called double-hit or triple-hit lymphomas. Follicular lymphomas can occasionally carry *MYC* and *BCL2* and/or *BCL6* rearrangements but should not be classified in this new high-grade B-cell lymphoma category unless they undergo transformation because, otherwise, they appear to demonstrate indolent behavior similar to conventional follicular lymphoma.^{2,34} However, those cases are very rare and additional larger studies are needed to determine prognostic significance of concurrent *MYC* and *BCL2* or *BCL6* rearrangements in follicular lymphoma. Follicular lymphomas can also acquire a *MYC* rearrange-

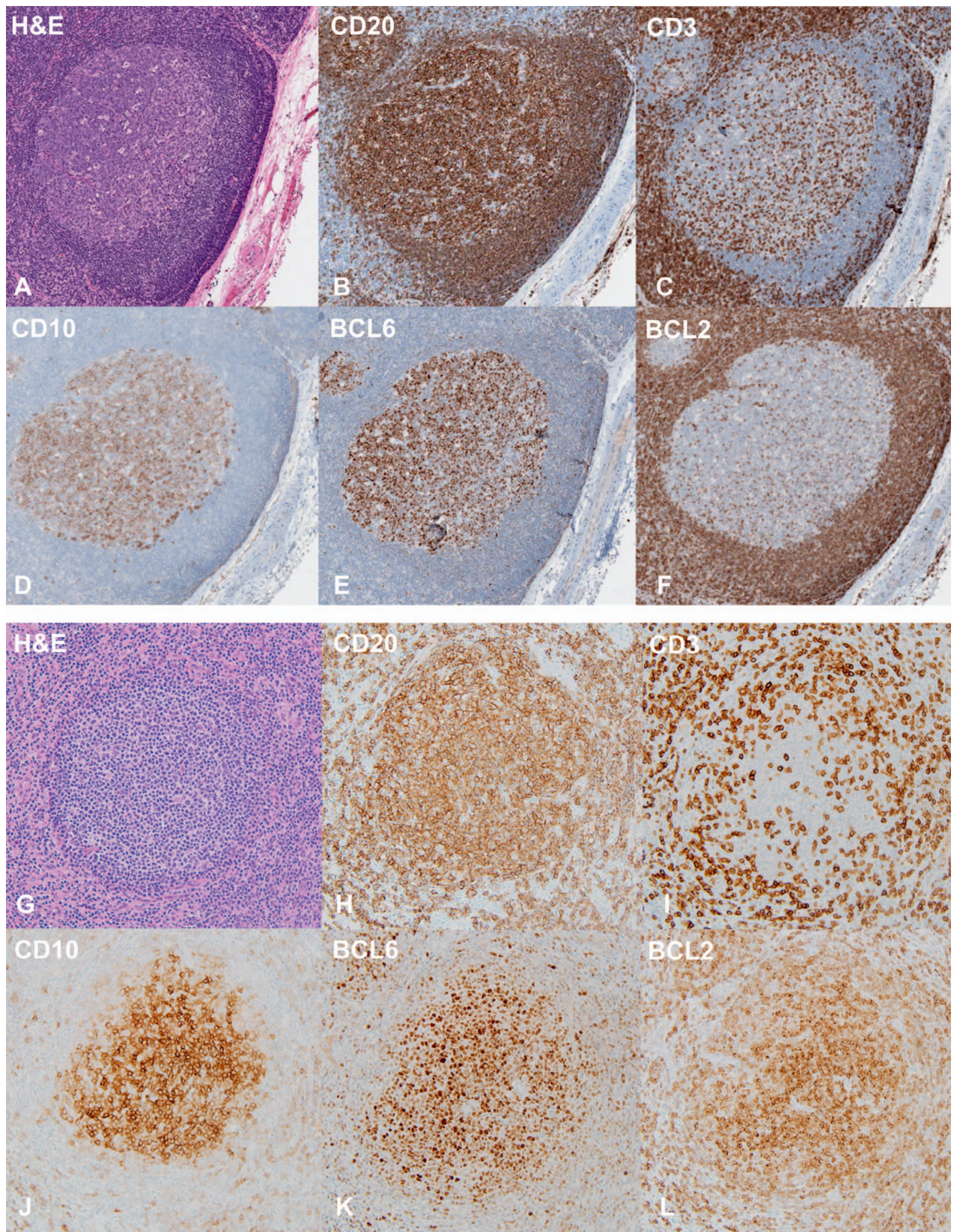


Figure 3. Immunophenotype of reactive follicle and follicular lymphoma. A through F, Reactive follicle immunohistochemical profile shows absence of BCL2 expression in germinal centers stained with hematoxylin-eosin (A), CD20 (B), CD3 (C), CD10 (D), BCL6 (E), and BCL2 (F). G through L, Neoplastic follicle in follicular lymphoma shows coexpression of CD20, CD10, BCL6, and BCL2 when stained with hematoxylin-eosin (G), CD20 (H), CD3 (I), CD10 (J), BCL6 (K), and BCL2 (L) (original magnification $\times 200$ [A through L]).

Table 1. Morphologic Variants of Follicular Lymphoma	
Morphologic Variant	Differential Diagnostic Consideration
Marginal zone differentiation	Marginal zone lymphoma
Plasmacytic differentiation	Marginal zone lymphoma Lymphoplasmacytic lymphoma
Floral variant	Nodular lymphocyte-predominant Hodgkin lymphoma Progressive transformation of germinal centers Marginal zone lymphoma
Reed-Sternberg-like cells	Hodgkin lymphoma
Epithelioid variant	Granulomatous inflammation Other B-cell lymphomas
Signet-ring cell variant	Carcinoma

neoplastic progenitors rather than in later subclones.^{44,45} Consequently, gene rearrangement studies have somewhat limited value and should be interpreted with the above features in mind. Situations in which clonality studies could potentially be beneficial are if matching rearrangements between an initial diagnostic sample and a subsequent histopathologically different sample can confirm a clonal relationship between the two.

NEW PROVISIONAL WHO ENTITIES

The 2017 revised WHO classification² discusses 3 new “variants” under the larger umbrella category of *follicular lymphoma* as well as the entity *in situ follicular neoplasia*.

In Situ Follicular Neoplasia

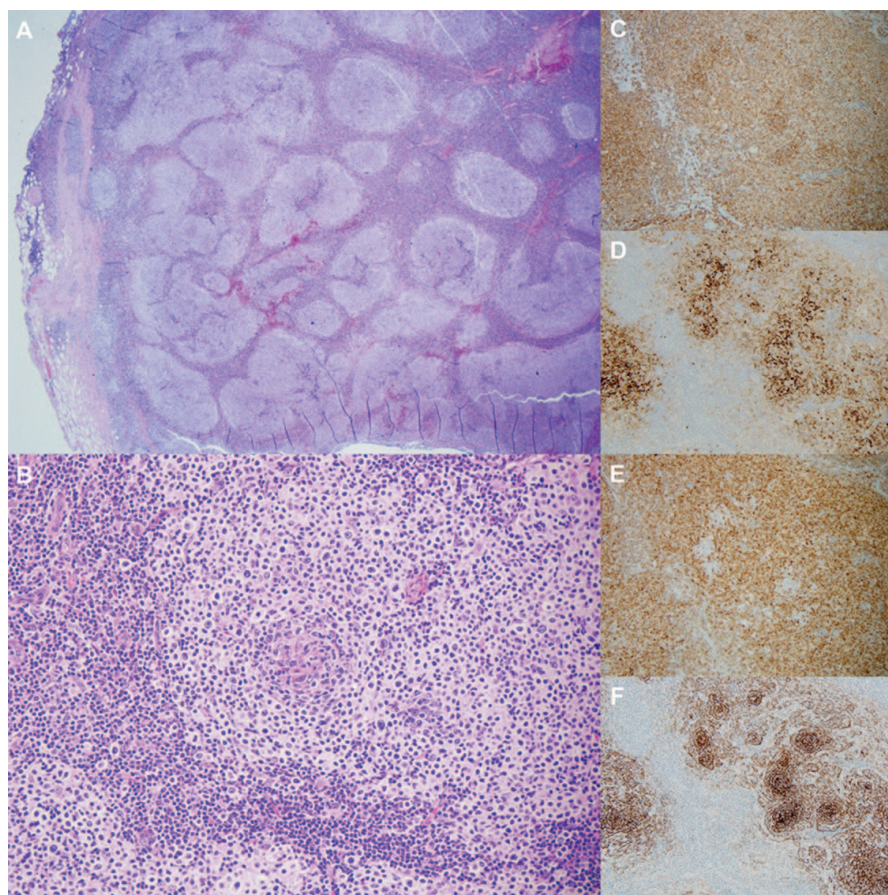
Previously designated *follicular lymphoma in situ*, *in situ follicular neoplasia* refers to an entity that has the immunophenotypic and genetic features of follicular lymphoma but does not represent actual systemic involvement by lymphoma. The architecture in these cases should be preserved and the abnormal follicles are not usually readily appreciated on hematoxylin and eosin sections. Consequently, many of these cases are likely identified incidentally, with an estimated prevalence of approximately 2% to 3%.^{46,47} Immunohistochemical features that have been described include focal follicles that exhibit strong, intense staining for CD10 and BCL2. These follicles can even show positivity for t(14;18) by FISH.

When one encounters a case that may fit into this diagnostic category, it is important to communicate to caregivers that the patient should be evaluated for systemic

ment during lymphoblastic transformation, a rare event with a poor outcome.^{35–38} Similarly, those cases should not be classified as high-grade B-cell lymphomas.²

Gene rearrangement (or B-cell clonality) studies (with BIOMED-2 primer sets in multiplex polymerase chain reaction) for IGH and/or IGK have positive results in most cases of follicular lymphoma.³⁹ Follicular lymphoma demonstrates somatic hypermutation,^{40,41} similar to healthy germinal-center B cells, and is often associated with multiple subclones, which can wax and wane during the disease course.^{42,43} Transformation may occur in earlier

Figure 4. Marginal zone differentiation in follicular lymphoma. A and B, Neoplastic cells show extensive monocytoid features with abundant cytoplasm associated with expanded follicular dendritic meshwork. The neoplastic cells show coexpression of CD20 (C), CD10 (D), and BCL2 (E); very small residual BCL2⁻ follicles highlighted by CD21 (F) are present. Flow cytometric immunophenotyping demonstrated a CD10⁺ λ-restricted B-cell population and fluorescence in situ hybridization was positive for both IGH-BCL2 translocation and BCL6 rearrangement (not shown) (hematoxylin-eosin, original magnifications ×20 [A] and ×200 [B]; original magnification ×100 [C through F]).



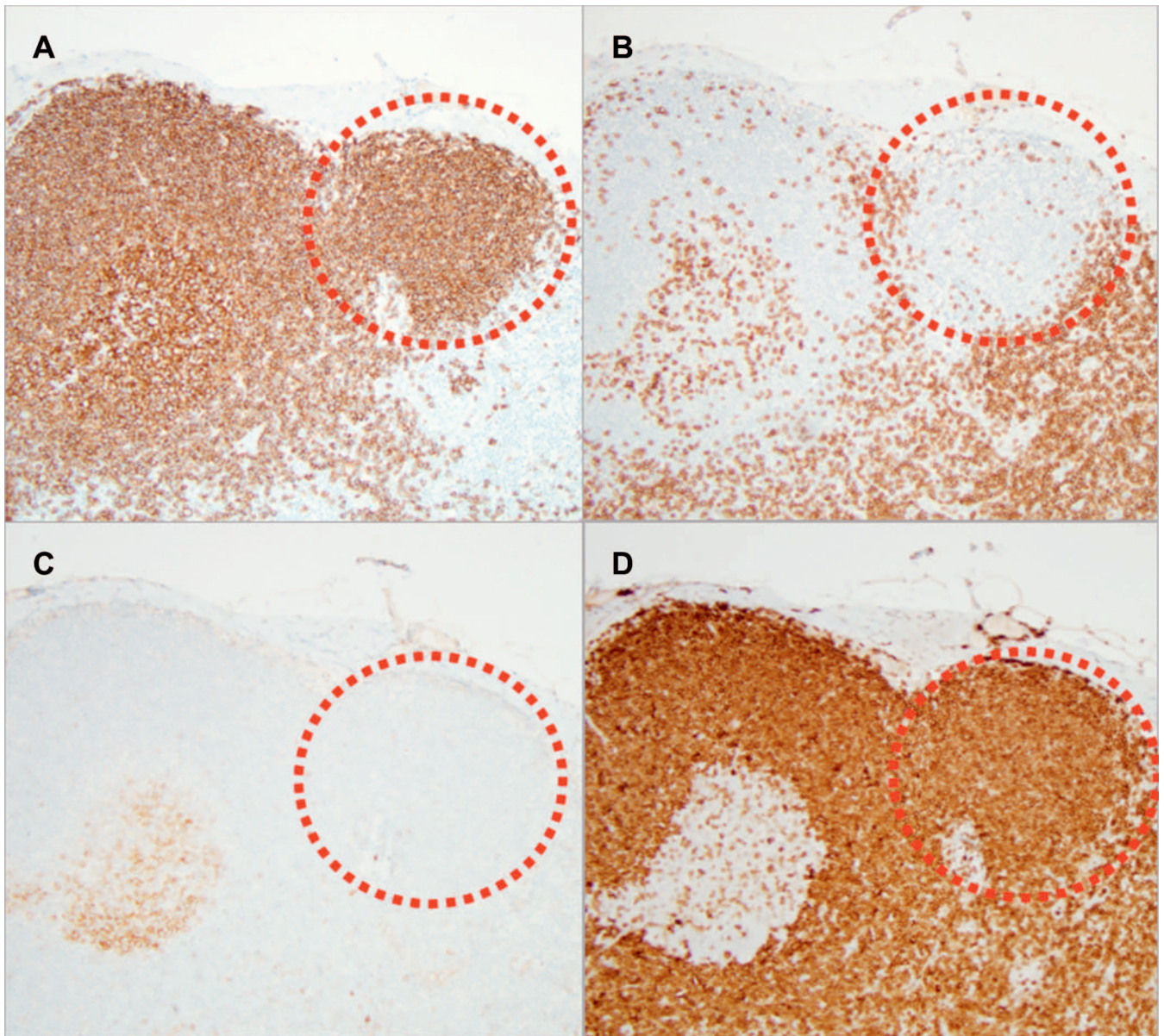


Figure 5. *BCL2* staining pattern in primary versus secondary follicles. CD20 (A) highlights B cells predominantly within follicles. CD3 (B) stains T cells. A primary follicle (red circle) is positive for *BCL2* (D) but shows no staining for germinal center markers CD10 (C) or *BCL6* (not shown). A secondary follicle (adjacent left of red circle), in contrast, is usually negative for *BCL2* and demonstrates expression of germinal center markers. *BCL2*⁺ cells within the secondary follicle likely represent T cells (original magnification $\times 200$ [A through D]).

involvement and the stage of disease needs to be determined because approximately 25% to 40% of patients will have a prior or concurrent lymphoma that is not always follicular lymphoma.^{48,49} In patients who do not have evidence of systemic involvement, the risk of developing subsequent follicular lymphoma appears to be 5% or less.^{46,48}

Duodenal-Type Follicular Lymphoma

The duodenal-type variant of follicular lymphoma shows a female predominance and most frequently occurs in the small intestine, typically with involvement of the duodenum.^{50–53} The morphologic features include abnormal follicles located in the mucosa and submucosa, composed of centrocytes with only rare centroblasts (low-grade cytology).⁵⁰ The immunohistochemical profile largely paral-

els that of systemic follicular lymphoma and demonstrates extension of neoplastic B cells into the surrounding lamina propria (Figure 7, A through D). As with in situ follicular neoplasia, clinical evaluation and staging is warranted to exclude systemic follicular lymphoma. In particular, atypical morphologic features, such as more extensive involvement, high-grade cytology, or infiltration into the muscularis propria, should raise concern about systemic disease. Without evidence of systemic disease, patients generally have excellent survival without therapy although local recurrences can occur.^{50,51,53,54}

Testicular Follicular Lymphoma

The testicular variant of follicular lymphoma is rare and is therefore less well understood. It was initially described in children⁵⁵ but has been rarely reported in adults.^{56–60} It

Table 2. Immunohistochemical and Genetic Features of Follicular Lymphoma That Vary With Grade

Grade	IHC		FISH	
	CD10, %	BCL2, %	t(14;18), %	BCL6, %
Grade 1–2	95–100	85–90	80–90	3
Grade 3A	80–95	50–75	60–70	30–40
Grade 3B	40–85	45–75	15–30	40–50

Abbreviations: FISH, fluorescence in situ hybridization; IHC, immunohistochemistry.

typically demonstrates high-grade cytology but has a good prognosis.^{57–59} Unlike classic follicular lymphoma, this entity does not possess a t(14;18)(q32;q21) translocation and does not demonstrate BCL2 expression.^{55–60}

Diffuse Follicular Lymphoma Variant

The diffuse variant of follicular lymphoma presents primarily in the inguinal region as a large mass.⁶¹

Morphologically, the infiltrate comprises a mixture of centrocytes and centroblasts. As the name suggests, it demonstrates a diffuse growth pattern but contains very small reactive-appearing follicles in the background, which are negative for BCL2.⁶² CD23 expression on the lymphocytes has been reported as a universal finding in the few cases described.⁶² Similar to testicular follicular lymphoma, it also does not, in most cases, contain the t(14;18)(q32;q21) translocation but instead most cases show a deletion in 1p36.^{61,62} That deletion is not specific to this entity, and it can be seen in other lymphomas, including classic follicular lymphoma.^{61,62}

BONE MARROW BIOPSY EVALUATION

A bone marrow biopsy is typically performed at diagnosis as part of the patient's staging evaluation. Bone marrow involvement is quite common in follicular lymphoma, occurring in up to 70% to 80% of patients. The typical pattern of involvement is paratrabeular (Figure 8), although other patterns can sometimes be seen.^{6,63,64} Immunohistochemical staining for CD20 (in the absence of rituximab

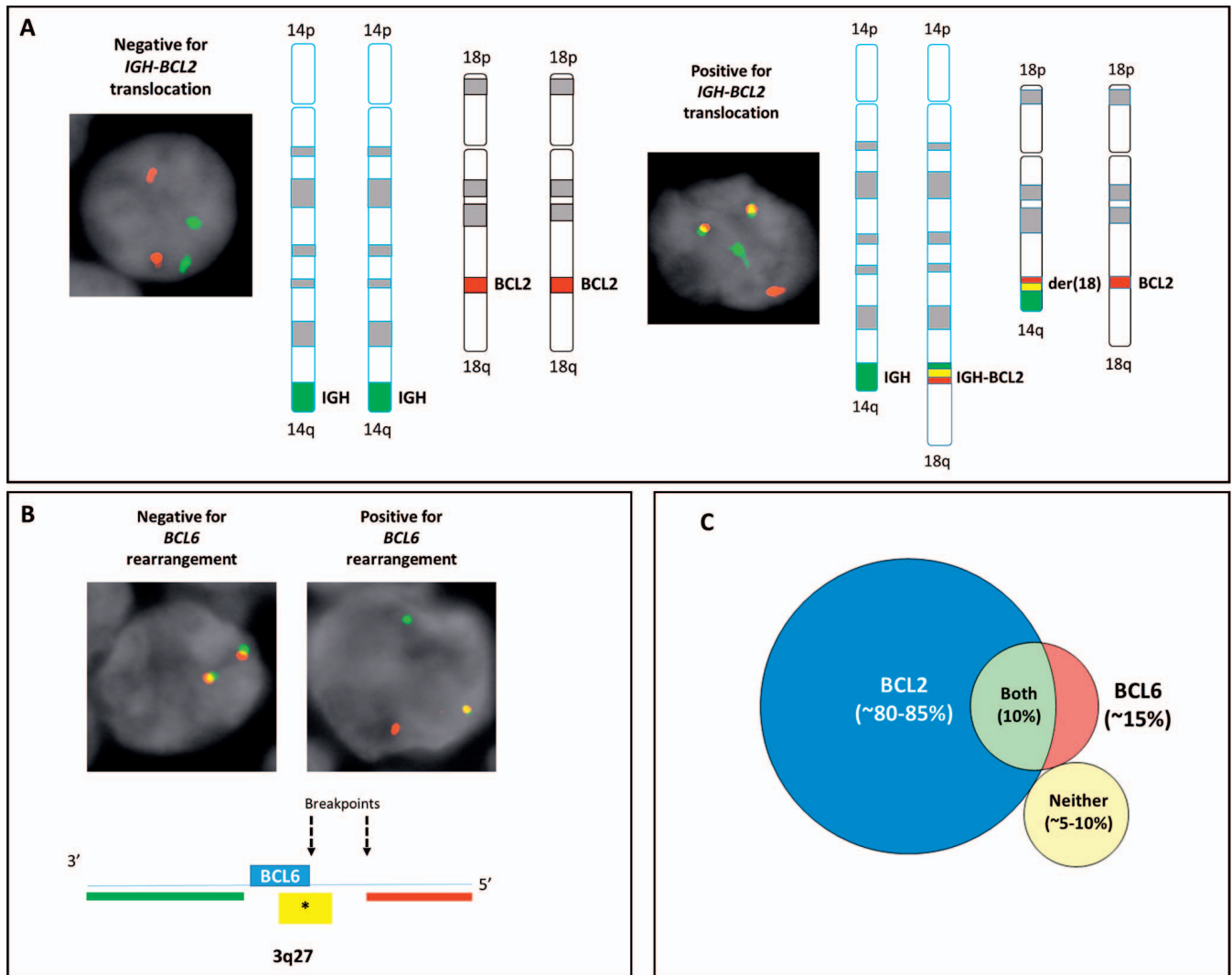


Figure 6. Examples of fluorescence in situ hybridization analysis results. *A*, Dual-color, dual-fusion assay for IGH and BCL2. *B*, Break-apart assay for BCL6 rearrangement. Usual results are depicted on the left, and abnormal cells are on the right. *C*, Frequency of BCL2 and BCL6 rearrangements in follicular lymphoma.

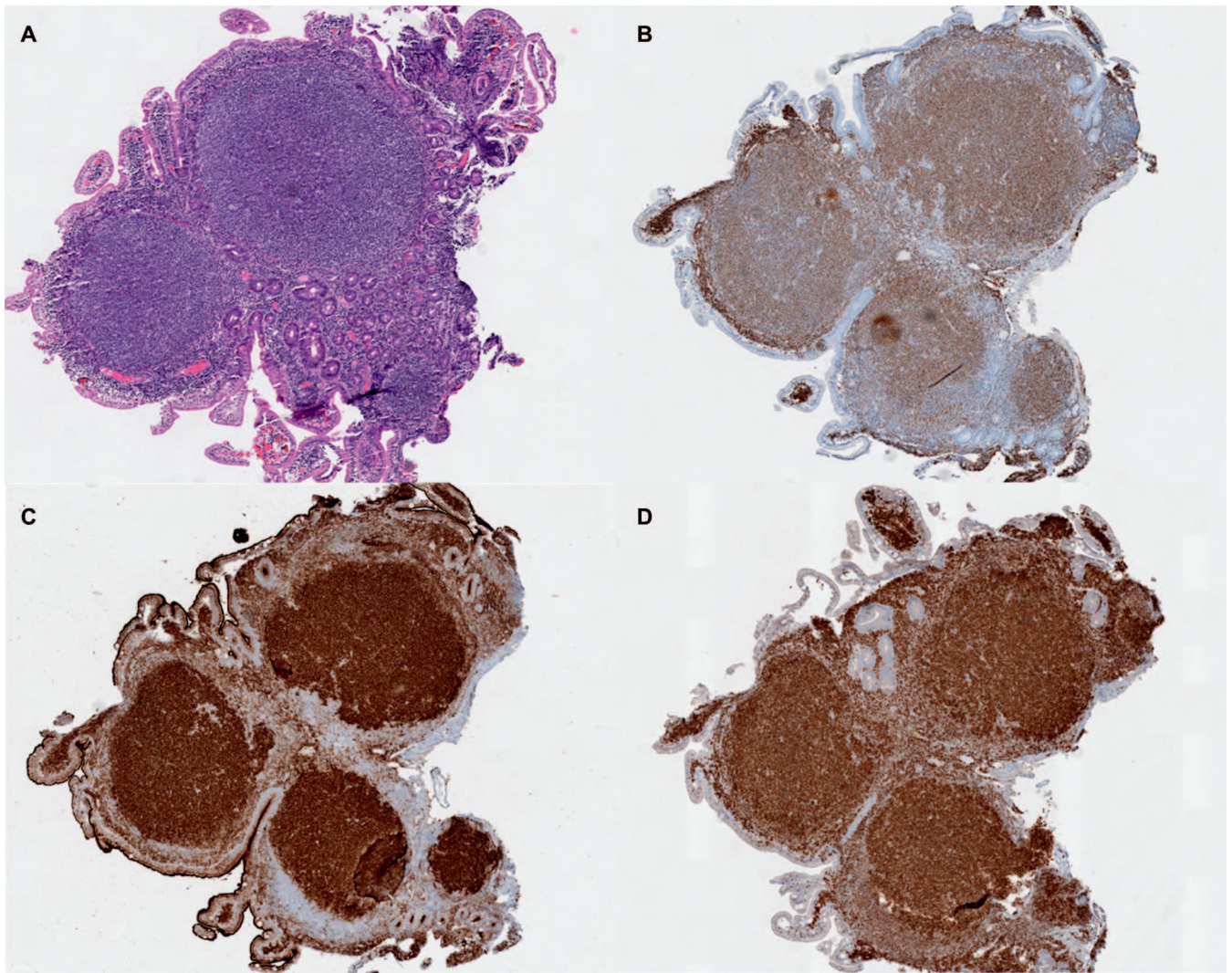


Figure 7. Duodenal-type follicular lymphoma. A, A polypoid lesion in the small intestine was biopsied and showed a nodular infiltrate with low-grade cytologic features. Coexpression of CD20 (B), CD10 (C), and BCL2 (D) was identified, and immunohistochemical stains demonstrate the extension of neoplastic B cells into the surrounding lamina propria (hematoxylin-eosin, original magnification $\times 40$ [A]; original magnification $\times 40$ [B through D]).

therapy) can help identify subtle paratrabeular aggregates. Unfortunately, CD10 and BCL6 immunohistochemical staining in the bone marrow can have negative results in up to 40% of cases.^{11,65} Flow cytometric detection of a CD10⁺ B-cell clone is supportive evidence of follicular lymphoma, but because of sampling variability can sometimes also have negative results.⁶⁶ Furthermore, as with immunohistochemistry, the frequency of CD10 positivity in the blood and bone marrow is decreased compared with the lymph nodes.⁶⁵ BCL2 immunohistochemistry can occasionally be helpful; however, results should be interpreted in the correct context because many other small B-cell lymphomas are also BCL2⁺, and some aggregates, particularly in treated patients, can be composed extensively of T cells.⁶⁷ Discordant morphologic features (eg, nodal diffuse large B-cell lymphoma with low-grade follicular lymphoma in the bone marrow) are seen in approximately 40% to 60% of cases,^{6,63} and therefore grading is not recommended on bone marrow biopsy specimens.⁶⁸

APPROACH TO SMALL NEEDLE CORE BIOPSIES

Based on our own institutional experience in the past 5 years, approximately 80% of follicular lymphoma diagnoses are currently being made on core needle biopsies (data not shown). Although some studies examining the effectiveness of core needle biopsies have suggested a reasonably high rate of definitive diagnosis of lymphoma (overall 80%–85%),^{69–71} others have suggested that follicular lymphoma may have a lower diagnostic rate in smaller tissue samples, along with 2 of its main differential diagnoses: marginal zone lymphoma and reactive lymphoid hyperplasia.^{72,73} Furthermore, core needle biopsies may have potential limitations in detecting areas of histologic transformation.⁷⁴ That is not particularly surprising given how critical architectural pattern factors into the diagnosis. Caveats to accurate diagnosis, including those that are particularly relevant to small biopsies, are summarized in Table 3. Morphologically, cases that have features that could suggest either marginal zone lymphoma or follicular lymphoma are especially difficult. Distinction between in situ follicular

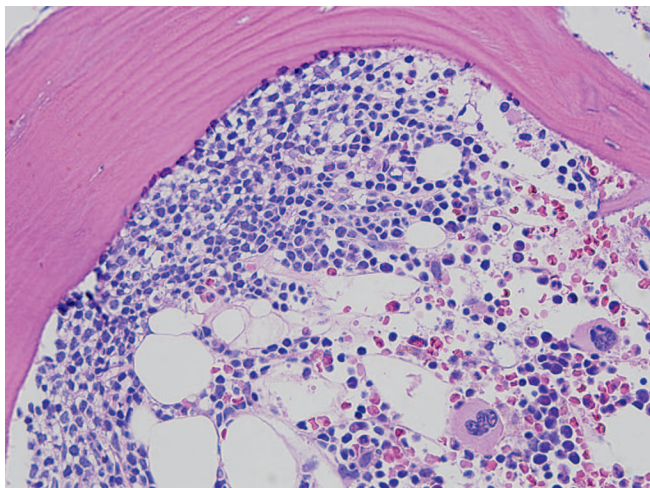


Figure 8. Bone marrow involvement by follicular lymphoma showing characteristic paratrabecular infiltrate (hematoxylin-eosin, original magnification $\times 400$).

neoplasia, partial involvement, and classic follicular lymphoma may be impossible to make on a core needle biopsy. Cytologic features can overlap as discussed above, and colonization of germinal centers is not necessarily evaluable on a small sample, which may not even contain affected follicles. Immunohistochemical interpretation can also be problematic because CD10 can be diminished in interfollicular areas, and it is not inconceivable that some biopsies will predominantly sample those areas.^{24,27} Flow cytometric interpretation can also be subject to sampling error, as previously discussed. In cases in which the distinction is not possible on histopathologic grounds and when the distinc-

tion affects clinical management, FISH analysis should be able to assist in the diagnosis in most cases.

Grading is another common dilemma because many samples will not have the recommended 10 follicles for sufficient evaluation. Ki-67 proliferative index usually correlates with histologic grade, but imperfectly so, and is currently recommended as an adjunct to grading, rather than a substitute.⁷⁵⁻⁷⁷ Although most cases of grade 1 and 2 follicular lymphoma have a Ki-67 index of less than 20%, some cases show higher Ki-67 staining and reportedly behave more aggressively.^{75,76}

Although the WHO classification² recommends that the pattern of involvement be indicated in the diagnostic report of excisional biopsies, because of the aforementioned, potential sampling artifacts, that practice performed on a small biopsy would provide limited useful information and therefore, in our opinion, may be omitted in cases of scant/small tissue.

Lastly, in cases in which a definitive diagnosis remains elusive, a discussion with the treating physician is recommended. When clinical management rests on further classification, an excisional biopsy of an accessible site should be considered if feasible.

CONCLUSIONS

Although many cases of follicular lymphoma demonstrate classic and straightforward histopathologic features, an accurate diagnosis of follicular lymphoma requires knowledge of morphologic variants and pitfalls in interpretation of ancillary studies. Furthermore, new diagnostic categories have been introduced recently, which merit additional consideration. Awareness of those diagnostic caveats and updates will be particularly useful in the setting of small tissue biopsies.

Table 3. Caveats in Diagnostic Workup of Follicular Lymphoma

Diagnostic Workup	Caveat
Morphology	
Grading	Small core biopsies may not have the necessary 10 follicles for grading
Ki-67	Variation in thresholds for clinical significance; used as an adjunct to grading only
Pattern	Small core biopsies can be subject to sample error Diffuse pattern may actually represent interfollicular involvement
IHC	
CD3	T cells within follicles can stain with BCL2 and should not be mistaken for neoplastic B cells
CD20	Can be negative in the setting of rituximab therapy; PAX5 or CD79a can be used instead
CD5	Rarely can be positive in follicular lymphoma; must exclude other CD5 ⁺ B-cell lymphomas
CD10	Shows decreased staining in interfollicular areas and in bone marrow
BCL6	Helpful in cases with CD10 negativity in establishing GC origin; other GC markers include HGAL, LMO2, and GCET2
BCL2	Variable frequency of positivity depending on grade of follicular lymphoma
CD21 or CD23	Can be helpful in distinguishing diffuse and follicular areas
CD43	Almost always negative in follicular lymphoma; can help in differential diagnosis with other small B-cell lymphomas
Cyclin D1	Negative in follicular lymphoma; histiocytes and endothelial cells can potentially stain positive
FISH	
t(14;18)	Higher frequency of detection in low-grade follicular lymphomas
BCL6	Lower frequency of detection in low-grade follicular lymphomas
MYC	Can be seen in cases of conventional follicular lymphoma and lymphoblastic transformation; those cases should NOT be classified as high-grade B-cell lymphoma with MYC and BCL2 and/or BCL6 rearrangements

Abbreviations: IHC, immunohistochemistry; FISH, fluorescence in situ hybridization; GC, germinal center.

References

- Chan WC, Armitage JO, Gascoyne R, et al. A clinical evaluation of the International Lymphoma Study Group classification of non-Hodgkin's lymphoma: the Non-Hodgkin's Lymphoma Classification Project. *Blood*. 1997;89(11):3909–3918.
- Swerdlow SH, Campo E, Harris NL, et al, eds. *WHO Classification of Tumours of Haematopoietic and Lymphoid Tissues*. Revised 4th ed. Lyon, France: International Agency for Research on Cancer; 2017. *World Health Organization Classification of Tumours*; vol 2.
- Espinete B, Bellosillo B, Melero C, et al. FISH is better than BIOMED-2 PCR to detect IgH/BCL2 translocation in follicular lymphoma at diagnosis using paraffin-embedded tissue sections. *Leuk Res*. 2008;32(5):737–742.
- Einerson RR, Kurtin PJ, Dayharsh GA, Kimlinger TK, Remstein ED. FISH is superior to PCR in detecting t(14;18)(q32;q21)-IgH/bcl-2 in follicular lymphoma using paraffin-embedded tissue samples. *Am J Clin Pathol*. 2005;124(3):421–429.
- Espinete B, Bellosillo B, Gregori E, et al. FISH is the best method to detect BCL2/IgH translocation in follicular lymphoma at diagnosis: a comparative study with conventional cytogenetics, FISH and PCR (Biomed-2 Primers) techniques. *Blood*. 2004;104(11):1377–1377.
- Arber DA, George TI. Bone marrow biopsy involvement by non-Hodgkin's lymphoma: frequency of lymphoma types, patterns, blood involvement, and discordance with other sites in 450 specimens. *Am J Surg Pathol*. 2005;29(12):1549–1557.
- Goodlad JR, Batstone PJ, Hamilton D, Hollowood K. Follicular lymphoma with marginal zone differentiation: cytogenetic findings in support of a high-risk variant of follicular lymphoma. *Histopathology*. 2003;42(3):292–298.
- Gradowski JF, Jaffe ES, Warnke RA, et al. Follicular lymphomas with plasmacytic differentiation include two subtypes. *Mod Pathol*. 2009;23(1):71–79.
- Schmid U, Karow J, Lennert K. Follicular malignant non-Hodgkin's lymphoma with pronounced plasmacytic differentiation: a plasmacytoma-like lymphoma. *Virchows Arch A Pathol Anat Histopathol*. 1985;405(4):473–481.
- Vago JF, Hurtubise PE, Redden-Borowski MM, Martelo OJ, Swerdlow SH. Follicular center-cell lymphoma with plasmacytic differentiation, monoclonal paraprotein, and peripheral blood involvement: recapitulation of normal B-cell development. *Am J Surg Pathol*. 1985;9(10):764–770.
- Younes SF, Beck AH, Ohgami RS, et al. The efficacy of HGAL and LMO2 in the separation of lymphomas derived from small B cells in nodal and extranodal sites, including the bone marrow. *Am J Clin Pathol*. 2011;135(5):697–708.
- Dyhdalo KS, Lanigan C, Tubbs RR, Cook JR. Immunoarchitectural patterns of germinal center antigens including LMO2 assist in the differential diagnosis of marginal zone lymphoma vs follicular lymphoma. *Am J Clin Pathol*. 2013;140(2):149–154.
- Menter T, Gasser A, Juskevicius D, Dirnhofer S, Tzankov A. Diagnostic utility of the germinal center-associated markers GCET1, HGAL, and LMO2 in hemolymphoid neoplasms. *Appl Immunohistochem Mol Morphol*. 2015;23(7):491–498.
- Goates JJ, Kamel OW, LeBrun DP, Benharroch D, Dorfman RF. Floral variant of follicular lymphoma: immunological and molecular studies support a neoplastic process. *Am J Surg Pathol*. 1994;18(1):37–47.
- Osborne BM, Butler JJ. Follicular lymphoma mimicking progressive transformation of germinal centers. *Am J Clin Pathol*. 1987;88(3):264–269.
- Bayerl MG, Bentley G, Bellan C, Leoncini L, Ehmans WC, Palutke M. Lacunar and reed-Sternberg-like cells in follicular lymphomas are clonally related to the centrocytic and centroblastic cells as demonstrated by laser capture microdissection. *Am J Clin Pathol*. 2004;122(6):858–864.
- Navas-Palacios JJ, Valdes MD, Lahuerta-Palacios JJ. Signet-ring cell lymphoma. ultrastructural and immunohistochemical features of three varieties. *Cancer*. 1983;52(9):1613–1623.
- Horn H, Schmelter C, Leich E, et al. Follicular lymphoma grade 3B is a distinct neoplasm according to cytogenetic and immunohistochemical profiles. *Haematologica*. 2011;96(9):1327–1334.
- Maeshima AM, Taniguchi H, Nomoto J, et al. Prognostic implications of histologic grade and intensity of Bcl-2 expression in follicular lymphomas undergoing rituximab-containing therapy. *Hum Pathol*. 2013;44(11):2529–2535.
- Wahlin BE, Yri OE, Kimby E, et al. Clinical significance of the WHO grades of follicular lymphoma in a population-based cohort of 505 patients with long follow-up times. *Br J Haematol*. 2012;156(2):225–233.
- Masir N, Campbell LJ, Goff LK, et al. BCL2 protein expression in follicular lymphomas with t(14;18) chromosomal translocations. *Br J Haematol*. 2009;144(5):716–725.
- Masir N, Jones M, Abdul-Rahman F, Florence CS, Mason DY. Variation in BCL2 protein expression in follicular lymphomas without t(14;18) chromosomal translocations. *Pathology*. 2012;44(3):228–233.
- Adam P, Baumann R, Schmidt J, et al. The BCL2 E17 and SP66 antibodies discriminate 2 immunophenotypically and genetically distinct subgroups of conventionally BCL2-“negative” grade 1/2 follicular lymphomas. *Hum Pathol*. 2013;44(9):1817–1826.
- Eshoa C, Perkins S, Kampalath B, Shidham V, Juckett M, Chang CC. Decreased CD10 expression in grade III and in interfollicular infiltrates of follicular lymphoma. *Am J Clin Pathol*. 2001;115(6):862–867.
- Bosga-Bouwer AG, van Imhoff GW, Boonstra R, et al. Follicular lymphoma grade 3B includes 3 cytogenetically defined subgroups with primary t(14;18), 3q27, or other translocations: t(14;18) and 3q27 are mutually exclusive. *Blood*. 2003;101(3):1149–1154.
- Guo Y, Karube K, Kawano R, et al. Low-grade follicular lymphoma with t(14;18) presents a homogeneous disease entity otherwise the rest comprises minor groups of heterogeneous disease entities with Bcl2 amplification, Bcl6 translocation or other gene aberrances. *Leukemia*. 2005;19(6):1058–1063.
- Dogan A, Du MQ, Aiello A, et al. Follicular lymphomas contain a clonally linked but phenotypically distinct neoplastic B-cell population in the interfollicular zone. *Blood*. 1998;91(12):4708–4714.
- Xu Y, McKenna RW, Kroft SH. Assessment of CD10 in the diagnosis of small B-cell lymphomas: a multiparameter flow cytometric study. *Am J Clin Pathol*. 2002;117(2):291–300.
- Zhao XF, Cherian S, Sargent R, et al. Expanded populations of surface membrane immunoglobulin light chain-negative B cells in lymph nodes are not always indicative of B-cell lymphoma. *Am J Clin Pathol*. 2005;124(1):143–150.
- Kussick SJ, Kalnoski M, Brazier RM, Wood BL. Prominent clonal B-cell populations identified by flow cytometry in histologically reactive lymphoid proliferations. *Am J Clin Pathol*. 2004;121(4):464–472.
- Ott G, Katzenberger T, Lohr A, et al. Cytomorphologic, immunohistochemical, and cytogenetic profiles of follicular lymphoma: 2 types of follicular lymphoma grade 3. *Blood*. 2002;99(10):3806–3812.
- Diaz-Alderete A, Doval A, Camacho F, et al. Frequency of BCL2 and BCL6 translocations in follicular lymphoma: relation with histological and clinical features [published correction appears in *Leuk Lymphoma*. 2008;49(3):598]. *Leuk Lymphoma*. 2008;49(1):95–101.
- Bhagwat VM, Ramachandran BV, Malathion A and B esterases of mouse liver-I. *Biochem Pharmacol*. 1975;24(18):1713–1717.
- Miyaoka M, Kikuti YY, Carreras J, et al. Clinicopathological and genomic analysis of double-hit follicular lymphoma: comparison with high-grade B-cell lymphoma with MYC and BCL2 and/or BCL6 rearrangements [published online ahead of print October 65, 2017]. *Mod Pathol*. 2018;31(2):313–326.
- Geyer JT, Subramaniam S, Jiang Y, et al. Lymphoblastic transformation of follicular lymphoma: a clinicopathologic and molecular analysis of 7 patients. *Hum Pathol*. 2015;46(2):260–271.
- Gauverky CE, Hoxie J, Nowell PC, Croce CM. Pre-B-cell leukemia with a t(8; 14) and a t(14; 18) translocation is preceded by follicular lymphoma. *Oncogene*. 1988;2(5):431–435.
- Kroft SH, Domiati-Saad R, Finn WG, et al. Precursor B-lymphoblastic transformation of grade I follicle center lymphoma. *Am J Clin Pathol*. 2000;113(3):411–418.
- De Jong D, Voetdijk BM, Beverstock GC, van Ommen GJ, Willemze R, Kluin PM. Activation of the c-myc oncogene in a precursor-B-cell blast crisis of follicular lymphoma, presenting as composite lymphoma. *N Engl J Med*. 1988;318(21):1373–1378.
- Evans PAS, Pott C, Groenen PJTA, et al. Significantly improved PCR-based clonality testing in B-cell malignancies by use of multiple immunoglobulin gene targets: report of the BIOMED-2 concerted action BHM4-CT98-3936. *Leukemia*. 2006;21(2):207–214.
- Cleary ML, Meeker TC, Levy S, et al. Clustering of extensive somatic mutations in the variable region of an immunoglobulin heavy chain gene from a human B cell lymphoma. *Cell*. 1986;44(1):97–106.
- Levy S, Mendel E, Kon S, Avnur Z, Levy R. Mutational hot spots in Ig V region genes of human follicular lymphomas. *J Exp Med*. 1988;168(2):475–489.
- Aarts WM, Bende RJ, Bossenbroek JG, Pals ST, van Noesel CJ. Variable heavy-chain gene analysis of follicular lymphomas: subclone selection rather than clonal evolution over time. *Blood*. 2001;98(1):238–240.
- Aarts WM, Bende RJ, Steenbergen EJ, et al. Variable heavy chain gene analysis of follicular lymphomas: correlation between heavy chain isotype expression and somatic mutation load. *Blood*. 2000;95(9):2922–2929.
- Green MR, Gentles AJ, Nair RV, et al. Hierarchy in somatic mutations arising during genomic evolution and progression of follicular lymphoma. *Blood*. 2013;121(9):1604–1611.
- Green MR, Alizadeh AA. Common progenitor cells in mature B-cell malignancies: implications for therapy. *Curr Opin Hematol*. 2014;21(4):333–340.
- Bermudez G, González de Villambrosia S, Martínez-López A, et al. Incidental and isolated follicular lymphoma in situ and mantle cell lymphoma in situ lack clinical significance. *Am J Surg Pathol*. 2016;40(7):943–949.
- Henopp T, Quintanilla-Martinez L, Fend F, Adam P. Prevalence of follicular lymphoma in situ in consecutively analysed reactive lymph nodes. *Histopathology*. 2011;59(1):139–142.
- Jegalian AG, Eberle FC, Pack SD, et al. Follicular lymphoma in situ: clinical implications and comparisons with partial involvement by follicular lymphoma. *Blood*. 2011;118(11):2976–2984.
- Pillai RK, Surti U, Swerdlow SH. Follicular lymphoma-like B cells of uncertain significance (in situ follicular lymphoma) may infrequently progress, but precedes follicular lymphoma, is associated with other overt lymphomas and mimics follicular lymphoma in flow cytometric studies. *Haematologica*. 2013;98(10):1571–1580.
- Misdraji J, Harris NL, Hasserjian RP, Lauwers GY, Ferry JA. Primary follicular lymphoma of the gastrointestinal tract. *Am J Surg Pathol*. 2011;35(9):1255–1263.
- Shia J, Teruya-Feldstein J, Pan D, et al. Primary follicular lymphoma of the gastrointestinal tract: a clinical and pathologic study of 26 cases. *Am J Surg Pathol*. 2002;26(2):216–224.
- Yoshino T, Miyake K, Ichimura K, et al. Increased incidence of follicular lymphoma in the duodenum. *Am J Surg Pathol*. 2000;24(5):688–693.

53. Sato Y, Ichimura K, Tanaka T, et al. Duodenal follicular lymphomas share common characteristics with mucosa-associated lymphoid tissue lymphomas. *J Clin Pathol*. 2008;61(3):377–381.
54. Damaj G, Verkarre V, Delmer A, et al. Primary follicular lymphoma of the gastrointestinal tract: a study of 25 cases and a literature review. *Ann Oncol*. 2003;14(4):623–629.
55. Finn LS, Viswanatha DS, Belasco JB, et al. Primary follicular lymphoma of the testis in childhood. *Cancer*. 1999;85(7):1626–1635.
56. Bacon CM, Ye H, Diss TC, et al. Primary follicular lymphoma of the testis and epididymis in adults. *Am J Surg Pathol*. 2007;31(7):1050–1058.
57. Heller KN, Teruya-Feldstein J, La Quaglia MP, Wexler LH. Primary follicular lymphoma of the testis: excellent outcome following surgical resection without adjuvant chemotherapy. *J Pediatr Hematol Oncol*. 2004;26(2):104–107.
58. Liu Q, Salaverria I, Pittaluga S, et al. Follicular lymphomas in children and young adults: a comparison of the pediatric variant with usual follicular lymphoma. *Am J Surg Pathol*. 2013;37(3):333–343.
59. Lones MA, Raphael M, McCarthy K, et al. Primary follicular lymphoma of the testis in children and adolescents. *J Pediatr Hematol Oncol*. 2012;34(1):68–71.
60. Pileri SA, Sabattini E, Rosito P, et al. Primary follicular lymphoma of the testis in childhood: an entity with peculiar clinical and molecular characteristics. *J Clin Pathol*. 2002;55(9):684–688.
61. Katzenberger T, Kalla J, Leich E, et al. A distinctive subtype of t(14;18)-negative nodal follicular non-Hodgkin lymphoma characterized by a predominantly diffuse growth pattern and deletions in the chromosomal region 1p36. *Blood*. 2009;113(5):1053–1061.
62. Siddiqi IN, Friedman J, Barry-Holson KQ, et al. Characterization of a variant of t(14;18) negative nodal diffuse follicular lymphoma with CD23 expression, 1p36/TNFRSF14 abnormalities, and STAT6 mutations. *Mod Pathol*. 2016;29(6):570–581.
63. Sovani V, Harvey C, Haynes AP, McMillan AK, Clark DM, O'Connor SR. Bone marrow trephine biopsy involvement by lymphoma: review of histopathological features in 511 specimens and correlation with diagnostic biopsy, aspirate and peripheral blood findings. *J Clin Pathol*. 2014;67(5):389–395.
64. Torlakovic E, Torlakovic G, Brunning RD. Follicular pattern of bone marrow involvement by follicular lymphoma. *Am J Clin Pathol*. 2002;118(5):780–786.
65. West RB, Warnke RA, Natkunam Y. The usefulness of immunohistochemistry in the diagnosis of follicular lymphoma in bone marrow biopsy specimens [published correction appears in *Am J Clin Pathol*. 2002; 118(1):145]. *Am J Clin Pathol*. 2002;117(4):636–643.
66. Merli M, Arcaini L, Boveri E, et al. Assessment of bone marrow involvement in non-Hodgkin's lymphomas: comparison between histology and flow cytometry. *Eur J Haematol*. 2010;85(5):405–415.
67. Jaffe ES, Arber DA, Campo E, Harris NL, Quintanilla-Martinez L, eds. *Hematopathology*. 2nd ed. Philadelphia, PA: Elsevier; 2017.
68. Knowles DM. *Neoplastic Hematopathology*. 2nd ed. London, England: Lippincott Williams & Wilkins; 2014.
69. Hu Q, Naushad H, Xie Q, Al-Howaidi I, Wang M, Fu K. Needle-core biopsy in the pathologic diagnosis of malignant lymphoma showing high reproducibility among pathologists. *Am J Clin Pathol*. 2013;140(2):238–247.
70. de Larrinoa AF, del Cura J, Zabala R, Fuertes E, Bilbao F, Lopez JL. Value of ultrasound-guided core biopsy in the diagnosis of malignant lymphoma. *J Clin Ultrasound*. 2007;35(6):295–301.
71. Amador-Ortiz C, Chen L, Hassan A, et al. Combined core needle biopsy and fine-needle aspiration with ancillary studies correlate highly with traditional techniques in the diagnosis of nodal-based lymphoma. *Am J Clin Pathol*. 2011; 135(4):516–524.
72. Farmer PL, Bailey DJ, Burns BF, Day A, LeBrun DP. The reliability of lymphoma diagnosis in small tissue samples is heavily influenced by lymphoma subtype. *Am J Clin Pathol*. 2007;128(3):474–480.
73. Frederiksen JK, Sharma M, Casulo C, Burack WR. Systematic review of the effectiveness of fine-needle aspiration and/or core needle biopsy for subclassifying lymphoma. *Arch Pathol Lab Med*. 2015;139(2):245–251.
74. Johl A, Lengfelder E, Hiddemann W, Klapper W, German Low-Grade Lymphoma Study Group (GLSG). Core needle biopsies and surgical excision biopsies in the diagnosis of lymphoma—experience at the Lymph Node Registry Kiel. *Ann Hematol*. 2016;95(8):1281–1286.
75. Wang SA, Wang L, Hochberg EP, Muzikansky A, Harris NL, Hasserjian RP. Low histologic grade follicular lymphoma with high proliferation index: morphologic and clinical features. *Am J Surg Pathol*. 2005;29(11):1490–1496.
76. Koster A, Tromp HA, Raemaekers JM, et al. The prognostic significance of the intra-follicular tumor cell proliferative rate in follicular lymphoma. *Haematologica*. 2007;92(2):184–190.
77. Martin AR, Weisenburger DD, Chan WC, et al. Prognostic value of cellular proliferation and histologic grade in follicular lymphoma. *Blood*. 1995;85(12): 3671–3678.