

Our Experience on the Association of a New Physical and Medical Therapy in Patients Suffering from Induratio penis plastica

V. Mirone C. Imbimbo A. Palmieri F. Fusco

Department of Urology of Naples 'Federico II', Italy

Key Words

Induratio penis plastica · Physical therapy · Extracorporeal shock waves treatment · Verapamil · Minilith SL1

Abstract

Objectives: To check the efficiency of shock waves in the treatment of induratio penis plastica. The Minilith SL1, successfully used in orthopedic or salivary stones because of its lithotriptic power, can be used to break plaques in Peyronie's disease. **Methods:** A total of 130 patients affected with Peyronie's disease were entered into a prospective trial. Patients with completely calcified plaques as determined by ultrasound evaluation were excluded. We divided the patients into three treatment groups: (A) shock waves alone in 21 patients; (B) a combination of shock waves and verapamil (perilesional injection) in 36 patients, and (C) verapamil alone in 73 patients. First, we treated all groups A and B patients 3 times, 20 min each time, with a Minilith SL1, and then only the patients of the second group received a complete cycle of twelve injections of verapamil (10 mg) every 2 weeks for 6 months. The group of 73 patients (group C) treated during the previous 2 years with a medical therapy (only injection of verapamil) was used as a control group. **Results:** Ultrasound evaluation showed a reduction of plaque in 11/21 group A patients and 7/36 group B patients. The treatment was tolerated very well

and only 11 petechiae in some patients were noticed after ESW treatment. **Conclusions:** The therapeutic association of shock waves with verapamil injection is an effective nonoperative treatment for the stabilization of Peyronie's disease.

Introduction

At the present time, Peyronie's disease is still an unknown disorder and both the pathophysiology and therapeutic approach of this disease are not well established [1, 2]. Calcium antagonists increase the extracellular matrix collagenase activity and also decrease collagen, fibronectin synthesis and secretion, therefore altering the fibroblastic metabolism.

We attempted to determine whether calcium antagonists, particularly verapamil, were effective in stimulating the remodelling and degradation of Peyronie's plaque as they have been found to be in stimulation of extracellular matrix changes in other systems [2-6].

Recently, the use of shock waves in the treatment of some diseases as atherosclerotic plaques, bone corns and osteogenetic alterations allowed to cure the patients affected by the Peyronie's disease through an original technique which consists of a combination of medical treatment and shock waves supplied by a Minilith SL1 lithotripter.




Fig. 1. The balloon probe.

Materials and Methods

We attempted to demonstrate the effectiveness of shock waves alone or of a therapeutic combination of shock waves and verapamil (perilesional injection) in patients with stable disease.

All patients had been affected by several sexual dysfunctions (reduction of penile rigidity, penile recurvatum, painful erections), but for no longer than 12 months. Patients were excluded with large plaques or still at an initial stage of degeneration, because in both cases the ultrasound results were very difficult to interpret. A total of 130 patients (mean age 49 years, range 28–61) were divided into three treatment groups: (A) shock waves alone in 21 patients; (B) a combination of shock waves and verapamil (perilesional injection) in 36 patients, and (C) verapamil alone in 73 patients.

The group of 73 patients (group C) treated during the previous 2 years with a medical therapy, injection of verapamil (first with 10 mg intraplaque: 52 patients, then with perilesional technique: 21 patients), was used as a control group to compare the results obtained.

First, we treated all groups A and B patients 3 times a week for 20 min and then only the patients of the second group received a complete cycle of twelve injections of verapamil (10 mg) every 2 weeks for 6 months.

The shock waves are produced by a therapeutic source and focused by a paraboloid reflector. The focal point is 40 mm from the edge of the therapeutic source (fig. 1). The aperture is 85.5°, its focus expands changing the energetic level; the ranges are 25 × 2.4 × 2.4 mm. The waves are therefore extracorporeal and they hit the patient's body passing throughout an interface and some superficial gelatin.

The patients lied quietly in the supine position with flexed legs. The penis was placed on a support that can be vertically adjusted (fig. 2). The treatment was not concentrated only on one specific point, but with an oscillatory movement of the equipment along the border of the plaque. A painful erection was reported in 21 patients of the first group and 23 of the second group. Twelve patients of group A and 9 of group B had no erection for a period that varied from 7 to 16 months. Fourteen group A patients showed recurvatum during erection.

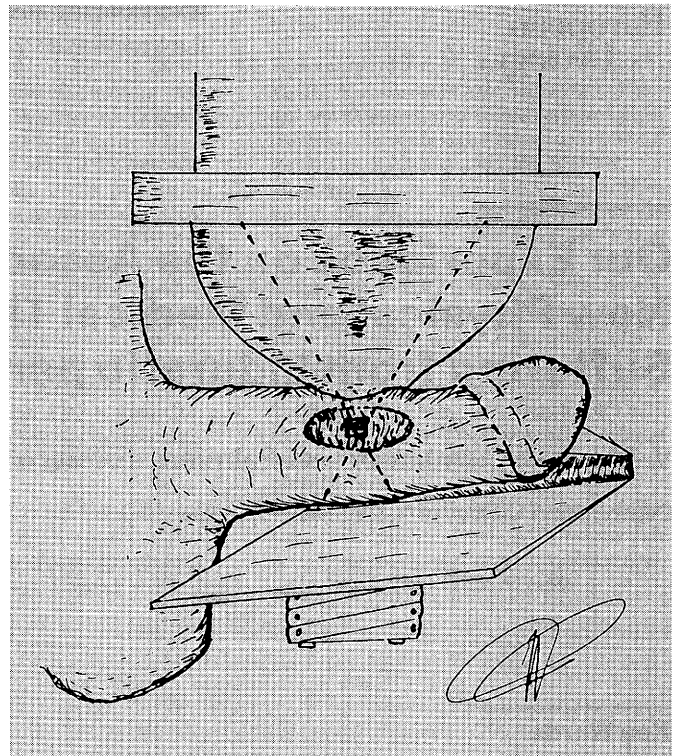


Fig. 2. A graphic representation of the treatment.

Results

The efficacy of treatments in improving plaque volume, pain and penile deformity has been evaluated. The frequency of side effects and patient satisfaction have been noted in table 1. At the end the study, the volume and consistency of plaques were estimated by ultrasound (probe 10 MHz). A reduction of plaque was found in 11/21 group A patients and 22/36 group B patients (fig. 3, 4). Neither local or systemic adverse effects nor acute and chronic toxicity were evident; only 11 petechiae were localized along the waves' direction on the penile surface, but they all disappeared after 24 h. Painful erection cleared up in 16/21 group A patients and 19/23 group B patients.

We interviewed the patients to examine the subjective improvement of sexual performance and discovered that it had improved in 74.9% of group A and 77.7% of group B (fig. 5, 6).

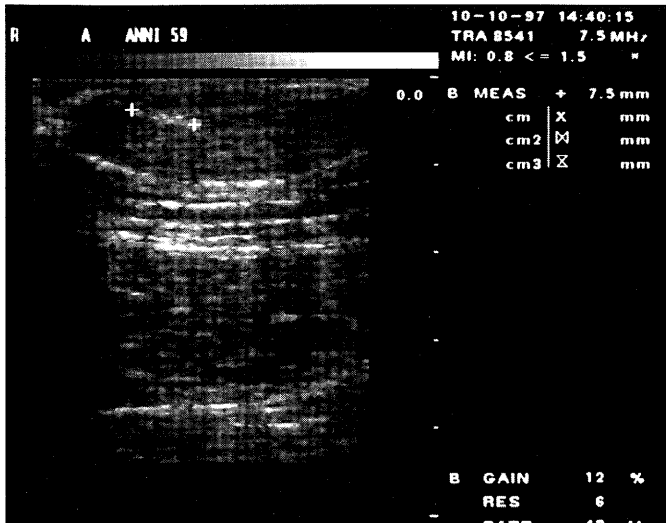


Fig. 3. Ultrasound before treatment.

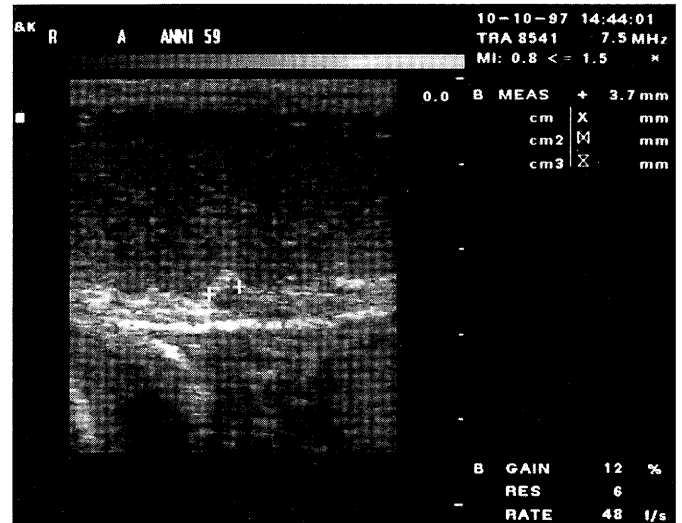


Fig. 4. Ultrasound after treatment.

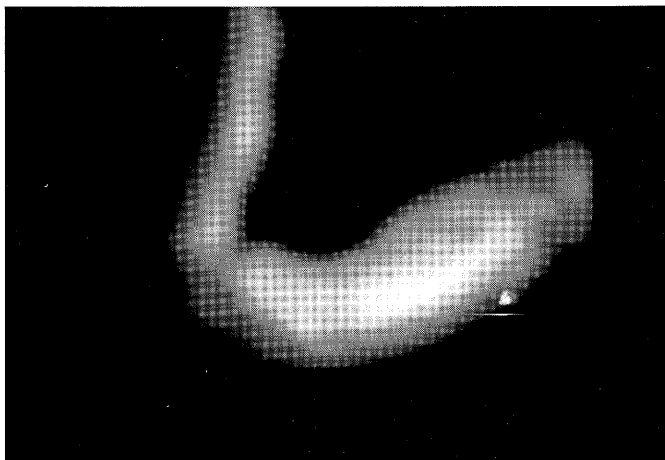


Fig. 5. Penile recurvatum before treatment.

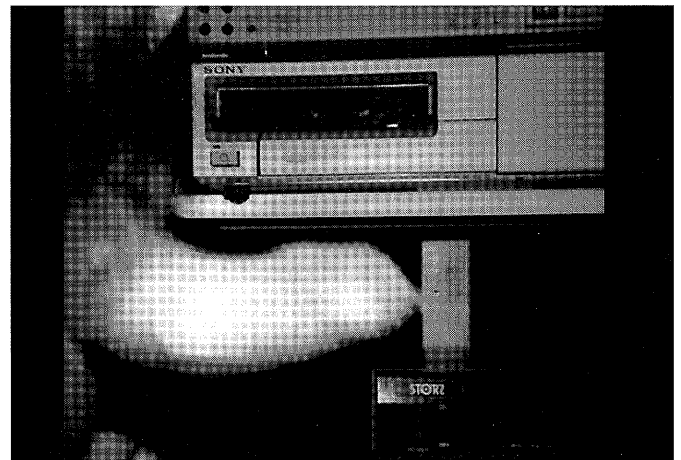


Fig. 6. Penile recurvatum disappeared after treatment.

Table 1. Our results

	Group A ESWT alone		Group B verapamil+ESWT		Group C verapamil alone	
	n	%	n	%	n	%
Ultrasound plaque volume reduction	11/21	52.3	22/36	61.1	31/73	42.4
Pain alleviation	16/21	76.1	19/23	82.6	36/61	59
Improvement in penile narrowing	3/5	60	3/4	75	3/12	25
Curvature reduction	11/14	78.5	16/21	76.2	33/51	64.7
Subjective improvement in intercourse	9/12	74.9	7/9	77.7	31/56	55.3

Discussion

Peyronie's disease is a localized disorder of the connective tissue, affecting the tunica albuginea of the penis. Hyalinization of collagen fibers and alteration of elastin fibers are some crucial steps of a still unknown pathogenetic mechanism. The collagen bundles inside Peyronie's plaque are typically thickened, disorganized and packed [7-9]. Previous studies have showed the importance of calcium in the metabolism of fibroblasts and in the neosynthesis of collagen. Therefore, calcium antagonists as verapamil were particularly studied for their antifibrotic power. Furthermore, the Minilith SL1, successfully used in orthopedic or salivary stones because of its lithotriptic power, can be used to break the plaques in Peyronie's disease. The suggestion of a synergism between mechanical and biochemical plaque disintegrating actions, of ESWT and verapamil, respectively, has been supported by our results.

Indeed this controlled nonrandomized study suggests that mixed therapy can improve the symptoms of disease. In particular, the fast resolution of pain might suggest the quick stabilization of the plaques' metabolism. The mechanism of interaction of the ESWT and post-ESWT verapamil injection cycle is not clear. Probably a softened and partially shattered plaque represents a better target for verapamil, offering a more extensive surface of action. Furthermore, the ESWT could facilitate the stretching effect of fluid injection. On the other hand, the verapamil injection cycle could consolidate the effects of ESWT, preventing a restart of collagen neosynthesis following the microtrauma of ESWT. A better explanation of this mechanism should be founded on histopathological data concerning plaques from the three different groups of treatment.

In conclusion, we can say that the therapeutic association could be an effective nonoperative treatment to stabilize the progression of Peyronie's disease.

References

- 1 Gelbard MK, Dosey F, James K: The natural history of La Peyronie's disease. *J Urol* 1990; 144:1376.
- 2 Schubert GE: Anatomy and pathophysiology of La Peyronie's disease and congenital deviation of the penis. *Urol Int* 1991;47:231.
- 3 Fitscha P, Keiler A, et al: The diminished extracellular matrix production induced by isradipine, a calcium channel blocker, is completely abolished by cyclooxygenase inhibition. *Prostaglandins Leukot Essent Fatty Acid* 1992; 45:289.
- 4 Lee RC, Doong HS, Jellema A: The response of burn scar to intralesional verapamil: Report of five cases. *Arch Surg* 1994;129:107.
- 5 Levine LA, Merrick PF, Lee RC: Intralesional verapamil injection for the treatment of La Peyronie's disease. *J Urol* 1994;151:1522.
- 6 Lee RC, Ping JA: Calcium antagonists retard extracellular matrix production in connective tissue equivalent. *Surg Res* 1990;49:463.
- 7 Luangknot R, Rutchick S, Agarwal V, et al: Collagen alteration in the corpus cavernosum of men with sexual dysfunction. *J Urol* 1992; 148:467-471.
- 8 Brock G, Hsu GL, Nunes L, von Heyden B, Lue TF: The anatomy of the tunica albuginea in the normal penis and Peyronie's disease. *J Urol* 1997;157:276-281.
- 9 Akkus E, Carrier S, Baba K, et al: Structural alterations in the tunica albuginea of the penis: Impact of Peyronie's disease, ageing and impotence. *Br J Urol* 1997;79:47-53.